

Acta Medica Okayama

Volume 25, Issue 4

1971

Article 5

AUGUST 1971

Induction of intracranial tumors in mice by human adenovirus type 12. II. Enhancement by N,N'-dimethylnitrosourea

Tsuyoshi Murao*

*Okayama University,

Copyright ©1999 OKAYAMA UNIVERSITY MEDICAL SCHOOL. All rights reserved.

Induction of intracranial tumors in mice by human adenovirus type 12. II. Enhancement by N,N'-dimethylnitrosourea*

Tsuyoshi Murao

Abstract

Newborn mice of C3Hf/Bi (Zb) strain were divided into three groups and injected, intracranially with adenovirus type 12 alone, subcutaneously with 20 mg/kg of N, N'-dimethylnitrosourea following intracranial inoculation of adenovirus type 12, and subcutaneously with 20 mg/kg of N, N'-dimethylnitrosourea alone at 10 days of age, respectively. With adenovirus type 12 alone, intracranial tumors were induced in 12 out of the 25 effective animals. With N, N'-dimethylnitrosourea following adenovirus type 12, intracranial tumors were produced in 19 out of the 21 effective animals and these tumors were virus-induced ones. With N, N'-dimethylnitrosourea alone, no intracranial tumors were induced. In control mice, administered subcutaneously with 20 mg/kg of N, N'.dimethylnitrosourea within 24 hr after birth, necrosis of the external granular cells and hypoplasia of the granular layer of the cerebellum was observed.

*PMID: 4263560 [PubMed - indexed for MEDLINE] Copyright ©OKAYAMA UNIVERSITY MEDICAL SCHOOL

Acta Med. Okayama 25, 261-268 (1971)

**INDUCTION OF INTRACRANIAL TUMORS IN MICE BY
HUMAN ADENOVIRUS TYPE 12 II. ENHANCEMENT
BY N,N'-DIMETHYLNITROSOUREA**

Tsuyoshi MURAO

*Department of Pathology, Okayama University Medical School, Okayama, Japan
(Director: Prof. K. Ogawa)*

Received for publication, July 2, 1971

In 1936, Rous *et al.* reported on the cocarcinogenic effect of Shope papilloma virus with tar in rabbits (1). Thereafter, combined effects of oncogenic or non-oncogenic viruses and chemicals have been studied extensively in experimental animals (2, 3, 4, 5, 6, 7, 8). Human adenovirus type 12 was reported to produce intracranial tumors in mice. However, the incidence was low as reported by OGAWA *et al.* (9). The author observed increased tumor formation in the brains of mice administered subcutaneously with N,N'-dimethylnitrosoarea - a carcinogen with capacity to produce neurogenic tumors in rats (10) - following intracranial inoculation of adenovirus type 12. The present paper reports this enhancing effect and the histological changes of the brain caused by administration of N,N'-dimethylnitrosoarea.

MATERIALS AND METHODS

Animals: Inbred mice of C₃Hf/Bi (Zb) strain, obtained from the Mouse Colony of Okayama University Medical School, were used.

Carcinogen: N,N'-Dimethylnitrosoarea was supplied kindly by Dr. S. YASUI of the Nippon Kanko Shikiso Laboratory. It was dissolved in physiological saline at the concentration of 1 mg/ml and used.

Virus: Adenovirus type 12, Huie strain, supplied by the courtesy of Dr. Y. YABE, was propagated in HeLa cells, and a pool titering 10^{3.0}TCID₅₀/0.1 ml in HeLa cells was used.

Groups and Treatment: The animals were divided into three experimental and one control groups and treated as follows:

Group 1: Twenty-seven mice, within 24 hr after birth, were intracranially inoculated with 0.015 ml of virus fluid.

Group 2: Twenty-three mice, within 24 hr after birth, were intracranially inoculated with 0.015 ml of virus fluid, and 10 days later the surviving animals were injected subcutaneously with N,N'-dimethylnitrosoarea solution in a dose of 20 mg/kg body weight.

Group 3: Eighteen mice, 10 days old, were subcutaneously injected with N,

N¹-dimethylnitrosourea solution in a dose of 20 mg/kg body weight.

Control group: Six mice, within 24 hr after birth, were subcutaneously injected with N,N¹-dimethylnitrosourea solution in a dose of 20 mg/kg body weight.

Preparation of Tissue Sections: The animals manifesting symptoms (blepharoptosis, ataxia, disturbance of development, etc.) were sacrificed immediately under ether anesthesia and all the organs were examined macroscopically. The brains and spinal cords were fixed in 4 per cent formaldehyde solution. Serial sagittal sections of them were prepared. All the animals surviving more than 180 days after the treatment were also sacrificed and serial sections of the brains were prepared. Specimens of the other organs were also prepared, if necessary. In control group, 2 animals were sacrificed on the 2nd, 30th and 60th day after the treatment, respectively, and the histological sections were made of brains. The specimens were usually stained with Hematoxylin and eosin, and sometimes with Klüver-Barrera Myelin stain and Bodian's Nerve Fiber stain.

In addition to the histological observation of tumors, it was tested whether the tumors produced in group 2 mice had the tumor antigen (T-antigen). For this purpose, cryostat sections were prepared from the tumors which were produced in 2 cases of group 2 animals. The sections were fixed in cooled carbon tetrachloride and stained with fluorescein labeled γ -globulin prepared from serum of hamsters bearing tumors induced by adenovirus type 12.

RESULTS

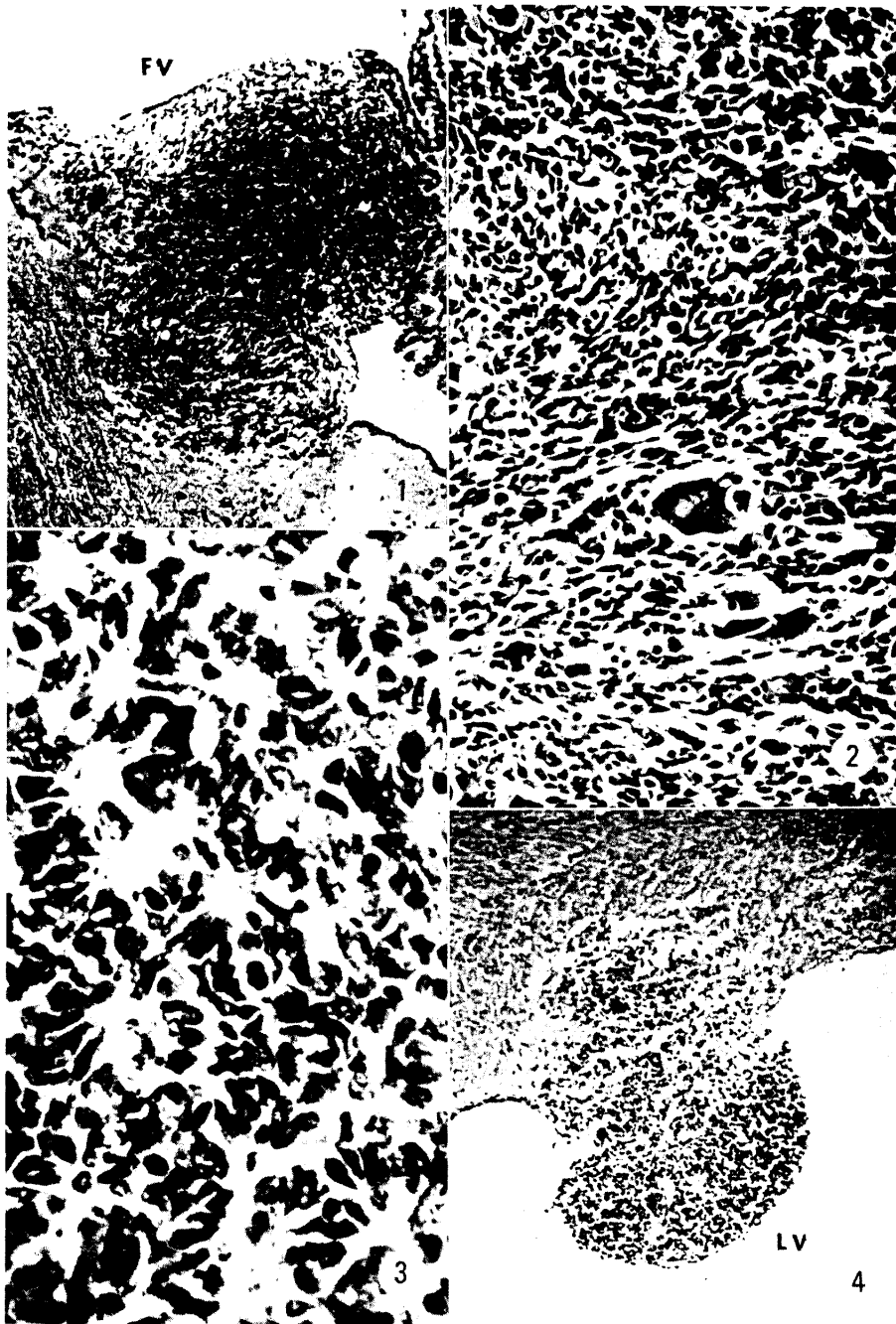
The incidences of intracranial tumors were 12/25 (48 per cent) in group 1 and 19/21 (90 per cent) in group 2, as shown in Table 1. The average latent periods were 124 days (95-150) in group 1 and 108 days (83-144) in group 2. As shown in Text-fig. 1 and Table 2, there was no significant difference in the distribution of the intracranial tumors between group 1 and group 2. All the tumors were observed in the regions associated with ventricles and in the meninges. Predilection sites were the wall of olfactory ventricle, the floor of the fourth ventricle and the tapetum which was contact with hippocampus. In one case of group 1 animals, the tumor was so large that it couldn't be decided from what region it had originated. In group 3, two animals developed liver cell

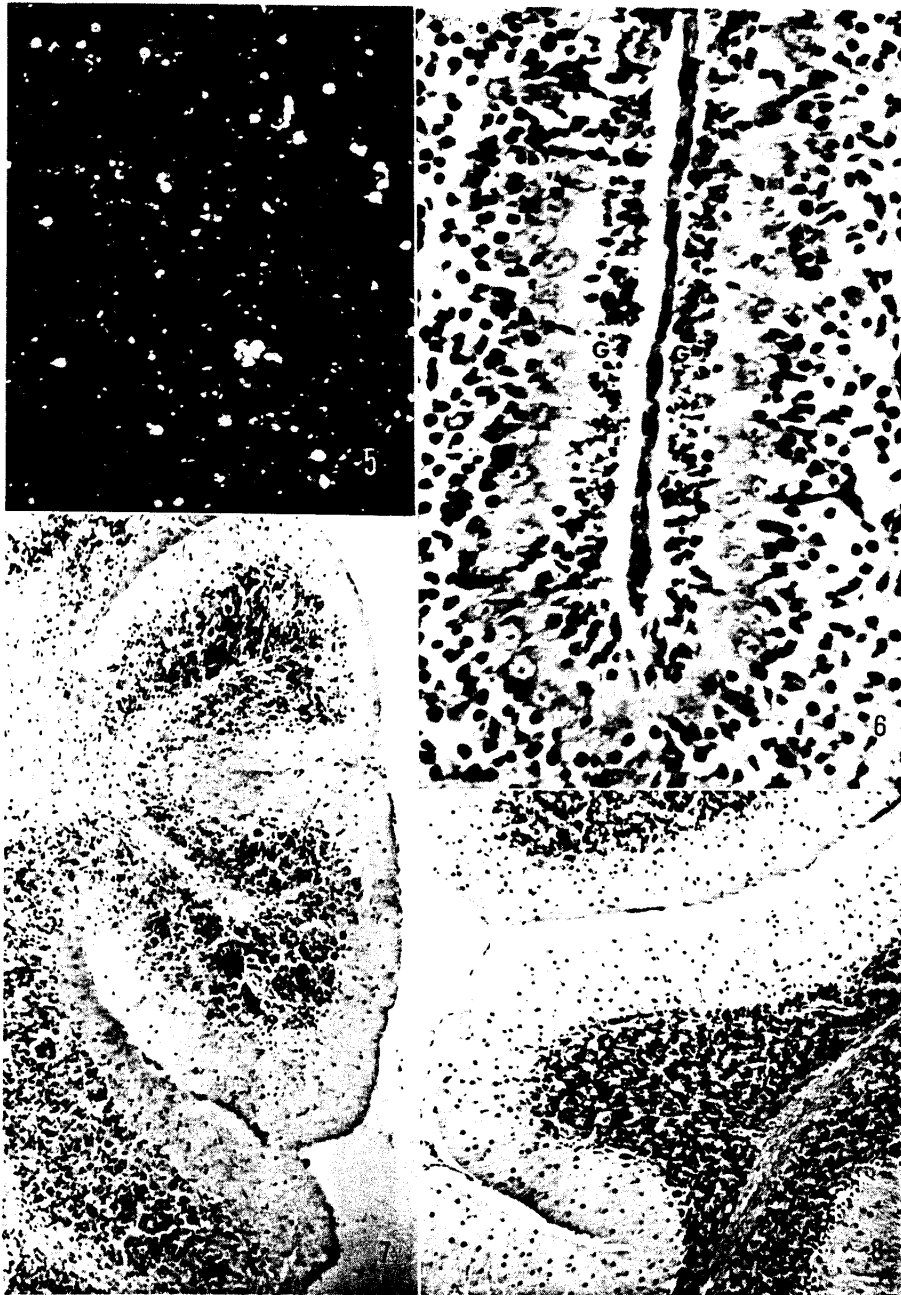
Fig. 1 Tumor protruding into the fourth ventricle (FV). From a mouse in group 2 killed on the 128th day. Hematoxylin and eosin. $\times 150$.

Fig. 2 Tumor developing in the olfactory bulb. Pleomorphic cells arranged irregularly. From a mouse in group 1. Hematoxylin and eosin. $\times 350$.

Fig. 3 Tumor developing in the floor of the fourth ventricle. Note rosette-like arrangement of the tumor cells. From a mouse in group 1. Hematoxylin and eosin. $\times 600$.

Fig. 4 A small tumor nodule composed of round cells protruding into the lateral ventricle (LV). From a mouse in group 1. Hematoxylin and eosin. $\times 150$.





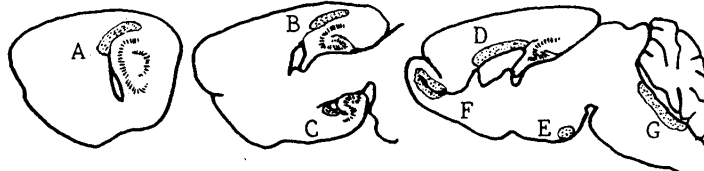
Enhancement of AV12 Tumor Formation

TABLE 1 INCIDENCE OF TUMORS

Group no.	Effective no. of animals*	Sex	Latent period (days)	No. of animals with tumor	Intracranial tumor	Liver tumor
1	10	♂	126 (93—150)	4		
	15	♀	122 (95—149)	8		
2	13	♂	109 (83—136)	12		
	8	♀	106 (84—144)	7		
3	10	♂	>180			2
	8	♀				

* Effective no. of animals excludes the mice which died within 2 weeks after birth.

Text-fig. 1 Schematic representation of predilection sites for tumor development in the brain.



A: Tapetum. B: Medial region of A. C: Ventral wall of the inferior horn of the lateral ventricle. D: Upper roof of the lateral ventricle. E: Infundibular recess. F: Wall of the olfactory ventricle. G: Floor of the fourth ventricle.

TABLE 2 DISTRIBUTION OF TUMORS IN THE BRAINS OF C₃H₁/Bi MICE

	No. of tumor-bearing mice	Sites of tumors							
		A ^{a)}	B	C	D	E	F	G	H ^{b)}
Group 1	11	2 ^{c)} (1) ^{d)}	2	1	3(2)	1	4(1)	5(2)	
Group 2	19	7(1)	3(1)	2	2	2	8(3)	9(3)	1

a) Alphabets refer to corresponding alphabets in Text-fig. 1.

b) H indicates meninges.

c) Numerals mean the total number of mice developing the tumor.

d) Parentheses enclose the number of mice developing the tumor only in that region.

Fig. 5 Intracranial tumor developing in one of group 2 mice, stained with anti-T conjugate. Note many cells with fluorescent dots and flecks. $\times 300$.

Fig. 6 Nuclear debris of the cells of the external granular layer (G), 2 days after administration of N,N'-dimethylnitrosourea into a mouse within 24 hr after birth. Hematoxylin and eosin. $\times 600$.

Fig. 7 Cerebellum, 30 days after administration of N,N'-dimethylnitrosourea into a mouse within 24 hr after birth. Granular cells are scanty in number and Purkinje cells are scattered among them. Hematoxylin and eosin. $\times 150$.

Fig. 8 Cerebellum of normal mouse of 30 days old. Hematoxylin and eosin. $\times 150$.

carcinoma, however, no tumor was found in the central nervous system.

There was no difference in the histomorphological appearances of tumors between group 1 and group 2. In most cases, the tumor cells were spindle shaped and arranged irregularly with scanty stroma. There were many mitotic figures and giant cells (Fig. 2). In some cases, the tumor cells appeared in rosette-like arrangement (Fig. 3). In one case of group 1, a small tumor nodule, composed of round cells with scanty cytoplasm and round nuclei, protruded in the lateral ventricle (Fig. 4).

Fluorescent microscopic examination revealed the presence of T-antigen in the tumors produced in group 2 mice (Fig. 5).

In mice of control group, histopathological changes were found in the cerebellum. On the second day after the treatment, degenerated cells and nuclear debris were observed in the external granular layer (Fig. 6). On the 30th day, the external granular layer had disappeared. The internal granular cells were scanty in number and Purkinje cells were scattered among them (Fig. 7). A similar change was observed on the 60th day after the treatment.

DISCUSSION

OGAWA *et al.*, in a study of the histogenesis of the adenovirus type 12-induced tumors, expressed the belief that the intracranial tumor was originated from the embryonic matrix cell remaining in the subependymal region of newborn animals (9). In a previous study of the mice inoculated intracranially with adenovirus type 12, in which the location of the cells with fluorescent T-antigen and also the primary site of tumor development were clarified, the author confirmed their opinion (11).

It is noteworthy that after the administration of adenovirus type 12 plus N,N'-dimethylnitrosourea, intracranial tumors were about 2 times more frequent than after adenovirus type 12 alone. Because of the presence of fluorescent T-antigen and the peculiar sites of tumor development, it is obvious that the tumors produced in group 2 mice are virus-induced ones. On the other hand, the cytotoxic effects of alkylating agents are usually observed in organs which have rapid cell division (12). The result of the present experiment revealed that in the brain of newborn mice, the cytotoxic effect of N,N'-dimethylnitrosourea, one of alkylating agents, was also restricted to the rapidly proliferating cells, and the necrosis of the external granular cells of the cerebellum occurred. This action of N,N'-dimethylnitrosourea is similar to that of cycasin (13). Though cerebellar lesions were produced in the mice administered with 20 mg/kg of N,N'-

dimethylnitrosourea within 24 hr after birth, neither lesions nor tumors of the brain were found in the mice treated with this chemical agent alone at 10 days of age.

The enhanced tumor production can be explained by the immunosuppressive effect of N, N'-dimethylnitrosourea. However, another possibility that oncogenic process of the adenovirus type 12-infected cells might be directly promoted by the administration of N, N'-dimethylnitrosourea is also suspected because there is a cellular specificity in the effects of N, N'-dimethylnitrosourea on the mouse, and also because it is considered that adenovirus type 12-induced tumors originate from immature neurogenic cells.

Further studies will be required to clarify the phenomenon of increased tumor production.

SUMMARY

Newborn mice of C₃Hf/Bi (Zb) strain were divided into three groups and injected, intracranially with adenovirus type 12 alone, subcutaneously with 20 mg/kg of N, N'-dimethylnitrosourea following intracranial inoculation of adenovirus type 12, and subcutaneously with 20 mg/kg of N, N'-dimethylnitrosourea alone at 10 days of age, respectively. With adenovirus type 12 alone, intracranial tumors were induced in 12 out of the 25 effective animals. With N, N'-dimethylnitrosourea following adenovirus type 12, intracranial tumors were produced in 19 out of the 21 effective animals and these tumors were virus-induced ones. With N, N'-dimethylnitrosourea alone, no intracranial tumors were induced.

In control mice, administered subcutaneously with 20 mg/kg of N, N'-dimethylnitrosourea within 24 hr after birth, necrosis of the external granular cells and hypoplasia of the granular layer of the cerebellum was observed.

ACKNOWLEDGEMENT

The author is grateful to Prof. K. OGAWA for his valuable advice and useful suggestions.

REFERENCES

1. ROUS, P. and KIDD, J. G.: The carcinogenic effect of a virus upon tarred skin. *Science* **83**, 468, 1936
2. ROUS, P. and KIDD, J. G.: The carcinogenic effect of a papilloma virus on the tarred skin of rabbits. I. Description of the phenomenon. *J. exp. Med.* **67**, 399, 1938

3. ROUS, P. and KIDD, J. G.: The carcinogenic effect of a papilloma virus on the tarred skin of rabbits. II. Major factors determining the phenomenon. *J. exp. Med.* **68**, 529, 1938
4. DURAN-REYNALS, M. L. and STANLEY, B.: Vaccinia dermal infection and methylcholanthrene in cortisone-treated mice. *Science* **134**, 1984. 1961
5. MARTIN, C. M. *et al.*: Common human viruses as carcinogen vectors. *Science* **134**, 1985, 1961
6. ROWSON, K. E. K. *et al.*: Induction of tumours by polyoma virus: Enhancement by chemical agents. *Nature* **191**, 893, 1961
7. TANAKA, S. and SOUTHAM, C. M.: Joint action of West Nile virus and chemical carcinogens in production of papillomas in mice. *J. nat. Cancer Inst.* **29**, 711, 1962
8. TANAKA, S. and SOUTHAM, C. M.: Joint action of Herpes simplex virus and 3-methylcholanthrene in production of papillomas in mice. *J. nat. Cancer Inst.* **34**, 441, 1965
9. OGAWA, K. *et al.*: Tumor induction by adenovirus type 12 and its target cells in the central nervous system. *Gann* **60**, 383, 1969
10. DRUCKREY, H. *et al.*: Organotrope Carcinogene Wirkungen bei 65 verschiedenen N-Nitroso-Verbindungen an BD-Ratten. *Krebsforsch.* **69**, 103, 1967
11. MURAO, T.: Induction of intracranial tumors in mice by human adenovirus type 12. I. Immunofluorescent studies on T antigen and the predilection sites for tumor development in the brain. Submitted for publication. 1971
12. CLAYSON, D. B.: Chemical Carcinogenesis, J. & A. Churchill, London, 1962
13. HIRONO, I. *et al.*: Induction of a cerebellar disorder with cycasin in newborn mice and hamsters. *Proc. Soc. exp. Biol. Med.* **131**, 593, 1969