

# *Acta Medica Okayama*

---

*Volume 52, Issue 2*

1998

*Article 4*

APRIL 1998

---

## Effects of endoluminal stent-grafts on acute aortic dissection in dogs.

Keiji Yunoki\*

Hatuzo Uchida†

Shunji Sano‡

Nobuyoshi Shimizu\*\*

\*Okayama University,

†Okayama University,

‡Okayama University,

\*\*Okayama University,

# Effects of endoluminal stent-grafts on acute aortic dissection in dogs.\*

Keiji Yunoki, Hatuzo Uchida, Shunji Sano, and Nobuyoshi Shimizu

## Abstract

Acute aortic dissection is a life-threatening condition, and may be treated with aggressive hypotensive drug therapy, but emergency surgery is often necessary. We evaluated the effectiveness of stent-grafts for the treatment of acute aortic dissection. Aortic dissection was surgically created in the descending thoracic aorta in 20 adult mongrel dogs. A stent-graft was inserted in the entry position. The tested animals were divided into 4 groups based on re-entry type and blood pressure alteration rate (AR) after acute aortic dissection. After insertion of the stent, the following results were observed: a) AR improved; b) proximal descending aorta and superior mesenteric arterial flows increased; c) cardiac function improved; and d) the dissecting aortic diameter decreased in the presence of pressure gradient group. From these results, insertion of a stent-graft to treat acute aortic dissection was judged to be effective.

**KEYWORDS:** stent-graft, endoluminal graft, acute aortic dissection, Blanton's method

## Effects of Endoluminal Stent-Grafts on Acute Aortic Dissection in Dogs

Keiji YUNOKI<sup>a</sup>, Hatuzo UCHIDA<sup>a</sup>, Shunji SANO<sup>a</sup> and Nobuyoshi SHIMIZU<sup>b</sup>

<sup>a</sup>Department of Cardiovascular Surgery and <sup>b</sup>Second Department of Surgery, Okayama University Medical School, Okayama 700-8558, Japan

Acute aortic dissection is a life-threatening condition, and may be treated with aggressive hypotensive drug therapy, but emergency surgery is often necessary. We evaluated the effectiveness of stent-grafts for the treatment of acute aortic dissection. Aortic dissection was surgically created in the descending thoracic aorta in 20 adult mongrel dogs. A stent-graft was inserted in the entry position. The tested animals were divided into 4 groups based on re-entry type and blood pressure alteration rate (AR) after acute aortic dissection. After insertion of the stent, the following results were observed: a) AR improved; b) proximal descending aorta and superior mesenteric arterial flows increased; c) cardiac function improved; and d) the dissecting aortic diameter decreased in the presence of pressure gradient group. From these results, insertion of a stent-graft to treat acute aortic dissection was judged to be effective.

**Key words:** stent-graft, endoluminal graft, acute aortic dissection, Blanton's method

Acute aortic dissection may be treated conservatively, but emergency surgery is often necessary when the risk of rupture is high and organ ischemia is marked. Surgery in the acute period is difficult and the results of this emergency surgery are not acceptable (1-5). Endoluminal grafting was developed as a treatment for aneurysms and is being clinically applied (6-10), but reports of its application to acute aortic dissection are still scarce. Moreover, since laboratory studies of this method are lacking, its indications and effectiveness have not been clarified (11-18). For these reasons, we decided to examine the efficacy of endoluminal grafts for acute aortic dissection.

The purpose of this study was to clarify the pathology at the onset of acute aortic dissection and to evaluate the

usefulness of stent insertion using a catheter by examining changes in the pathology after the treatment with regard to the following points: a) whether the treatment alleviates organ ischemia associated with acute aortic dissection and b) whether the treatment blocks blood flow to the dissection lumen.

### Materials and Methods

**Materials.** Twenty adult mongrel dogs weighing 6-11.5 kg (mean 8.6 kg) were used.

**Operating procedure.** The dogs were endotracheally intubated, the thoracic descending aorta was exposed by thoracotomy at the left fourth intercostal level under general anesthesia, and acute aortic dissection was created in the descending aorta by modified Blanton's method (19). Our modified version of Blanton's method involved exposing the thoracic descending aorta by left posterolateral thoracotomy under general anesthesia, cross-clamping the aorta, and making a transverse incision in the aortic wall over about half the circumference. Subsequently, an antegrade pocket approximately 1.5 cm in diameter was produced in the media on the distal side. After this, the incision was closed by suturing the full thickness of the aortic wall on the proximal side but only the adventitia on the distal side, and the aorta was declamped (Fig. 1). We maintained the systolic pressure in the aortic arch at nearly 100 mmHg during measurement by simply adjusting the concentration of inhaled anesthetic (halothane).

**Stent-graft.** In this model, a stent-graft was inserted retrogradely at the entry of the dissection. The stent-graft employed consisted of Gianturco Z stent (self-expandable type, 8-14 mm in diameter and 10 mm in length, double linked stents type from Medicos Hirata Co. Ltd., Osaka, Japan) covered with a Biobrane silicone sheet (0.125 mm thick, Japan Vilene Co. Ltd., Tokyo,

---

\* To whom correspondence should be addressed.

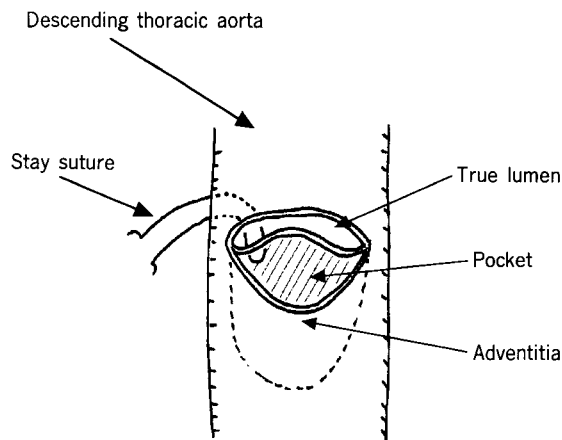


Fig. 1 Preparation of the model (modified Blanton's method).

Table 1 Grouping of tested dogs based on re-entry type and blood pressure alteration rate

	Number of dogs			Total
	RE (-) <sup>a</sup>	RE (small) <sup>b</sup>	RE (large) <sup>c</sup>	
PG (+) <sup>d</sup>	5	5	1	11
PG (-) <sup>e</sup>	4	3	2	9
Total	9	8	3	20

RE: Re-entry; PG: Pressure gradient.

<sup>a</sup>: Group of dogs without RE; <sup>b</sup>: Group of dogs with small RE;

<sup>c</sup>: Group of dogs with large RE;

<sup>d</sup>: Alteration rate (AR) of blood pressure (femoral artery/aortic arch) < 0.6;

<sup>e</sup>: AR ≥ 0.6.

Japan).

**Parameters.** The following parameters were measured before and after dissection preparation and after stent insertion: arterial blood pressure in the aortic arch and the right femoral artery; in the descending aorta (Ao), superior mesenteric artery (SMA), and left renal artery (RA) blood flow was measured with a Doppler flowmeter (T201 model, Transonic systems Inc., NY, USA); cardiac output (CO); central venous pressure (CVP), and pulmonary arterial pressure (PAP). Aortography was performed before and after stent insertion. Before and after stent insertion, maximal transverse diameter of the dissection site was measured by aortography, and changes after stent insertion were studied. Subsequently, the dogs were sacrificed, and the extent of dissection as

well as the presence or absence and the morphology of re-entry were examined.

**Groups.** At the time of dissection preparation, the blood pressure alteration rate (AR: femoral artery/aortic arch) was calculated. Animals in which the AR was 0.6 or greater were placed in the PG (-) group, and those in which the AR was less than 0.6, the PG (+) group. After determining the presence or absence of re-entry in resected specimens, animals without re-entry were designated as the RE (-) group, and those with re-entry the RE (+) group. Within the RE (+) group were the RE (small) group (those in which re-entry resulted from extension of dissection to the intercostal arteries), and the RE (large) group (those in which re-entry developed due to a large rupture of the intima and the media). The numbers of animals in each group are shown in Table 1.

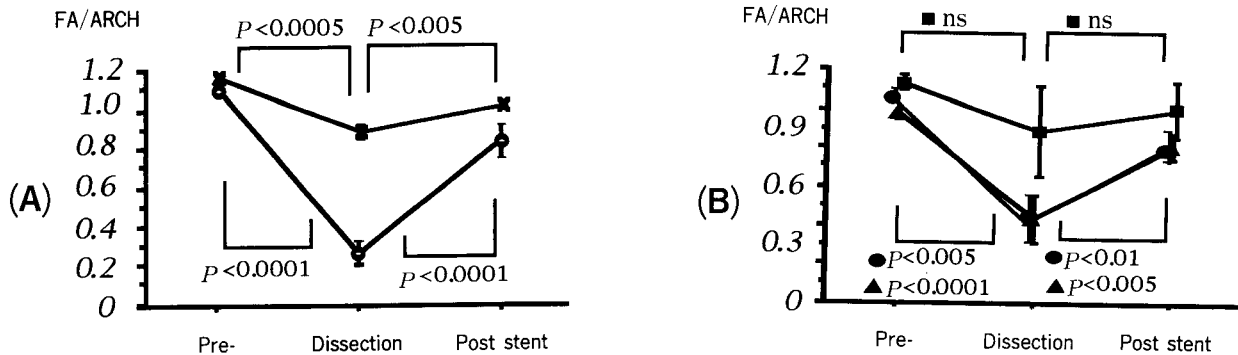
**Statistical analysis.** Statistical analysis was performed using repeated-measures ANOVA, and two groups were compared using Bonferroni's modified *t*-test (Statview J 4.11, Abacus Concepts Inc., Berkeley, CA, USA). The results are expressed as the mean ± standard deviation (SD). A *P* value of less than 0.05 was considered significant.

This experiment was carried out in accordance with the Principles of Laboratory Animal Care formulated by the National Society of Medical Research and the Guide for the Care and Use of Laboratory Animals prepared by the National Academy of Sciences and published by the National Insitute of Health (NIH Publication no. 80-23, revised in 1978).

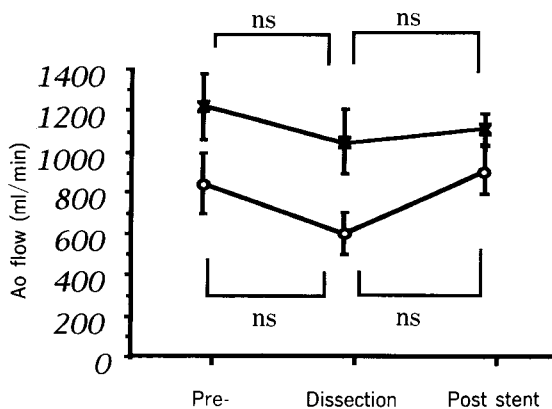
## Results

**Blood pressure.** The AR decreased significantly after dissection preparation in both the PG (+) group ( $n = 11$ ) ( $P < 0.0001$ : Bonferroni's modified *t*-test) and the PG (-) group ( $n = 9$ ) ( $P < 0.0005$ ), and the AR increased significantly after stent insertion in both the PG (+) group ( $P < 0.0001$ ) and the PG (-) group ( $P < 0.005$ ) ( $n = 20$  in Total). In re-entry morphological groups, the AR increased significantly in the RE (-) ( $P < 0.01$ ) and the RE (small) ( $P < 0.005$ ) groups. The changes were not significant in the RE (large) group (Fig. 2).

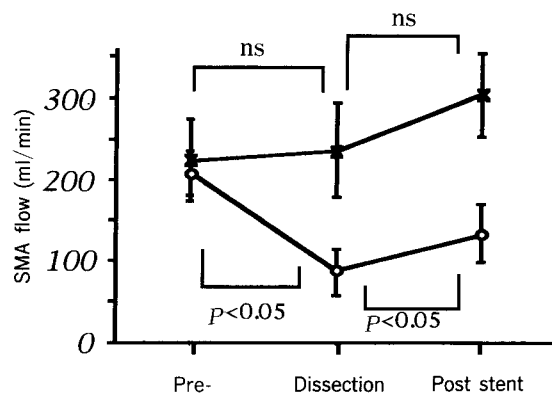
**Blood flow ( $n = 14$ ).** In the Ao, the blood flow change was not statistically significant (Fig. 3). In the SMA, the blood flow decreased significantly after



**Fig. 2** Alteration rates (AR) of blood pressure. (A): Pressure gradient (PG) of tested dogs. ○: Presence of PG (n = 11); ×: Absence of PG (n = 9). (B): Re-entry of stent-grafts. ●: No re-entry (n = 9); ▲: Small re-entry (n = 8); ■: Large re-entry (n = 3). AR were increased significantly after stent insertion in all groups except for the re-entry (large) group. Data are expressed as mean ± SD. FA/ARCH: Femoral artery/aortic arch; ns: Not significant.



**Fig. 3** Changes in descending aortic flow. ○: Presence of pressure gradient (PG) (n = 6); ×: Absence of PG (n = 8). Ao: Descending aorta; ns: Not significant. Data are expressed as mean ± SD.



**Fig. 4** Changes in superior mesenteric arterial flow. SMA: Superior mesenteric artery; ○: Presence of pressure gradient (PG) (n = 6); ×: Absence of PG (n = 8); ns: Not significant. Data are expressed as mean ± SD.

dissection and increased significantly after stent insertion only in the PG (+) group ( $P < 0.05$ ) (Fig. 4). In the RA, the blood flow change was not statistically significant (Fig. 5).

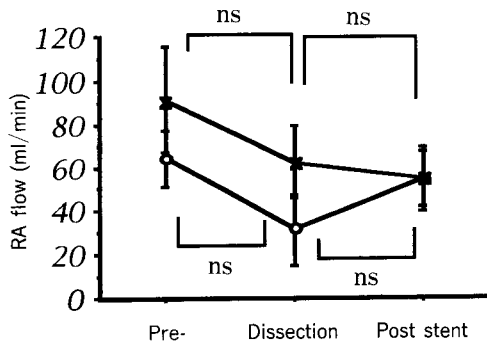
**Cardiac output (n = 14).** CO increased significantly after stent insertion only in the PG (+) group ( $P < 0.05$ ) (Fig. 6).

**CVP and PAP (n = 10).** CVP and PAP changes were not significant in both the PG (+) group and the PG (-) group.

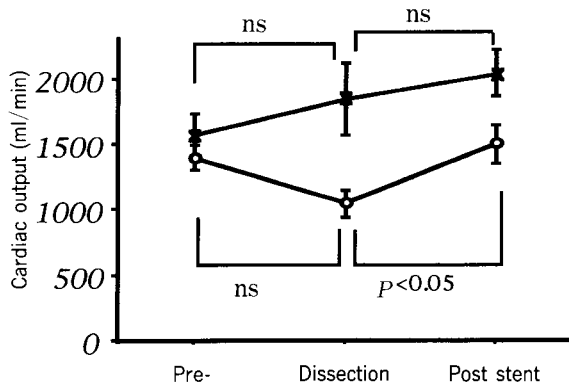
**Systemic vascular resistance (n = 10).** Systemic vascular resistance (SVR) significantly in-

creased after dissection preparation in both the PG (+) group ( $P < 0.005$ ) and the PG (-) group ( $P < 0.005$ ), and decreased after stent insertion in the both PG (+) group ( $P < 0.05$ ) and the PG (-) group ( $P < 0.005$ ).

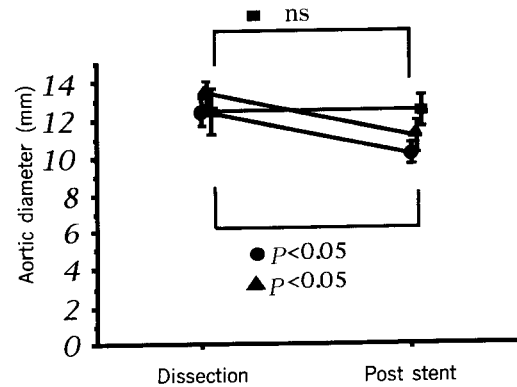
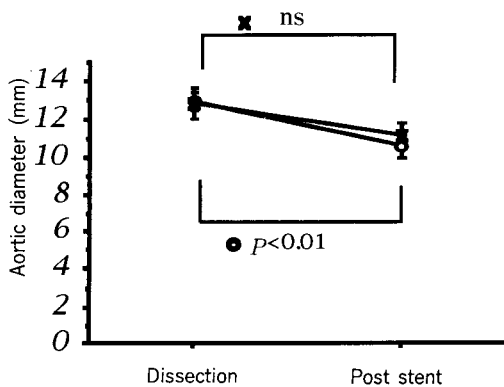
**Dissecting aortic diameter (n = 19).** Aortic diameter decreased significantly only in the PG (+) ( $P < 0.01$ ) group after stent insertion. Regarding re-entry morphology, aortic diameter decreased significantly in the RE (-) group ( $P < 0.05$ ) and the RE (small) group ( $P < 0.05$ ) after stent insertion. However the changes were not significant in the RE (large) group (Fig. 7).



**Fig. 5** Changes in left renal arterial (RA) flow.  
 ○: Presence of pressure gradient (PG) (n = 6); ×: Absence of PG (n = 8); ns: Not significant.  
 Data are expressed as mean ± SD.



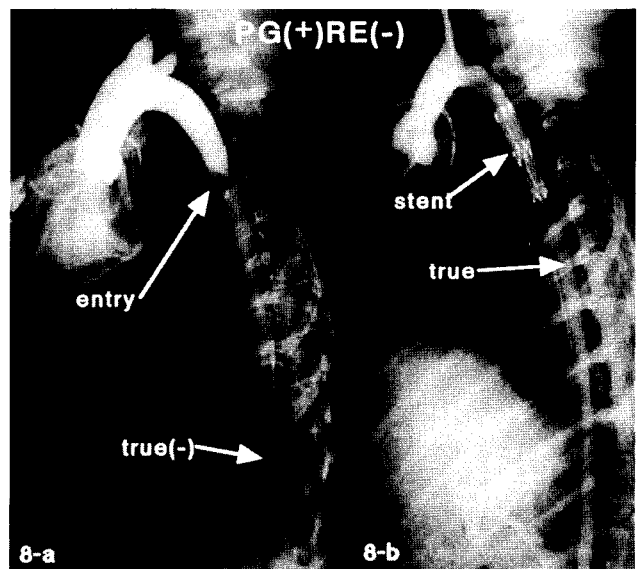
**Fig. 6** Changes in cardiac output.  
 ○: Presence of pressure gradient (PG) (n = 6); ×: Absence of PG (n = 8); ns: Not significant.  
 Data are expressed as mean ± SD.



**Fig. 7** Changes in transverse diameter of the aorta.  
 ○: Presence of pressure gradient (PG) (n = 11); ×: Absence of PG (n = 9); ●: No re-entry (n = 9); ▲: Small re-entry (n = 8); ■: Large re-entry (n = 3).  
 Data are expressed as mean ± SD. ns: Not significant.

**Angiographic findings.** The dissection lumen disappeared in 8 dogs, a small lumen remained in 9 dogs, and the lumen largely remained in 2 dogs (Figs. 8 and 9).

**Macroscopic appearance.** Dissection did not extend to major abdominal branches in any of the animals; re-entry was absent in 9 and present in 11 dogs. Of these 11 dogs, an intercostal artery involved in the dissection served as a re-entry in 8 and rupture of the intima over



**Fig. 8** PG (+) and RE (-) case angiography.  
 a) Before stent insertion: A large false lumen is visible in front of a compressed true lumen.  
 b) After stent insertion: The false lumen has disappeared and the true lumen is clearly visible.

nearly half the circumference was present in 3 dogs (Fig. 10).

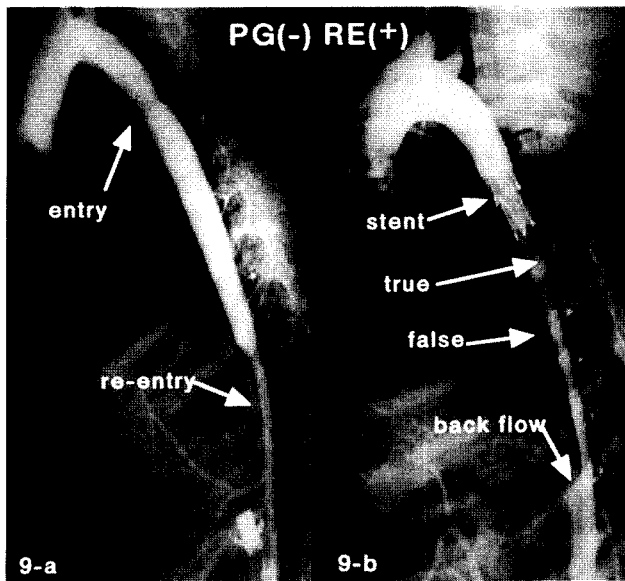


Fig. 9

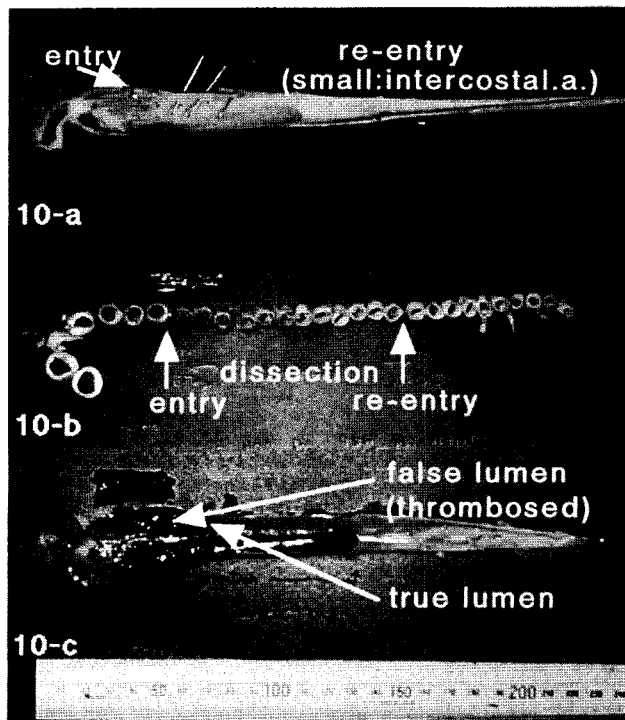


Fig. 10

## Discussion

According to the report of Hirst *et al.* (20), the prognosis of acute aortic dissection was extremely poor before the introduction of aggressive hypotensive drug therapy. Subsequently, the survival rate has reportedly improved with this therapy (21-23), and the survival rate after surgery in the acute period has also improved with advances in surgical therapy (1-5). Presently, surgical treatment is indicated for all Stanford type A dissection and Stanford type B dissections with complications, and hypotensive drug therapy is indicated for other conditions. In the chronic period, surgery may be indicated for the cases with the increased rupture possibility of dissecting aortic aneurysms or with complications associated with dissection. However, the risk of surgery itself is high in patients with a poor pre-operative condition or in elderly patients whether it is performed in the acute period or chronic period. Therefore, an alternative and safe method other than surgery or medication is called for.

Since Dotter *et al.* developed the stent (24), it has been used clinically not only in the biliary tract but also in the vascular system (coronary artery, peripheral arteries and veins). Presently, endoluminal grafts, in which a covered stent is placed in the aneurysm using a catheter, are being tested clinically (6-10).

The initial step in acute aortic dissection surgery is to close the entry or to replace the entry region with an artificial graft. Therefore, closing of the entry with a catheter has been attempted in laboratory experiments and clinical cases. However, the effectiveness of this surgery is not sufficiently supported by experimental data (12-16). Kato *et al.* (12) found that stent insertion was effective to treat acute aortic dissection in an experimental model. However, they did not consider the varieties of acute

Fig. 9 PG (-) and RE (+, small) case angiography.

a) Before stent insertion: A wide false lumen is visible and the distal side of dissection is clearly visible.

b) After stent insertion: The true and false lumen were present because of the backflow from the re-entry site.

Fig. 10 Macroscopic appearance of experimental dissection.

a, b) Extent of dissection. There were re-entries which resulted from extension of the dissection to the intercostal arteries.

c) Seven days after stent insertion. The false lumen was thrombosed and the true lumen was present.

aortic dissection. Kato *et al.* (14) found that stent insertion was useful in maintaining blood flow in the true lumen on the basis of angiographic findings alone.

In our study, the pressure gradient and re-entry morphology varied among the cases, even though they had similar entries (size, location). In this study, we found that the pressure gradient between the proximal and distal side of the dissection site and morphology of the re-entry were critical to the sequence of acute aortic dissection. Also in this study, we clarified the relationship between stent-graft insertion and pressure gradient and re-entry morphology. We characterized the cardiovascular hemodynamic parameters (blood pressure, blood flow, CO, CVP, PAP and SVR) and angiographic findings before and after stent insertion.

After dissection, blood pressure [in both PG (+) group and PG (-) group] and SMA blood flow [in the PG (+) group] decreased significantly on the distal side of the dissection (Figs. 2 and 5), and SVR increased significantly. Dissection changed blood pressure and blood flow on the distal side, and increased afterload.

We found that the pressure gradient produced by dissection was decreased by stent insertion in the PG (+) group ( $P < 0.0001$ ). The pressure gradient was also decreased in the PG (-) group ( $P < 0.05$ ) (Fig. 2). Regarding the re-entry morphology, the pressure gradient decreased after stent insertion in the RE (-) ( $P < 0.01$ ) and the RE (small) ( $P < 0.005$ ) groups. This suggests that the narrowed true lumen was enlarged sufficiently to the level of pre-dissection.

We consider stent insertion to be effective for the treatment of acute aortic dissections accompanied by a pressure gradient. A pressure gradient was observed in all groups except for the RE (large) group after dissection. This may have been a result of the creation of a pocket over about one-third to one-half of the aortic wall in this model. The SMA blood flow increased significantly after stent insertion, but the Ao and RA blood flow did not increase significantly. The changes in SMA blood flow may be due to the fact that SMA blood flow depends largely on blood pressure and so any increase in blood pressure after stent-graft insertion is reflected in increased SMA blood flow. In contrast, changes in RA blood flow may reflect the fact that RA blood flow is largely auto-regulated and that the RA went into a spasm when the flow probe was inserted and thus did not show an increase in blood flow after stent insertion. This situation is visible in clinical patients. However, improvement in

blood flow after stent insertion (Fig. 4) supports the effectiveness of this treatment for organ ischemia. Considering the fact that CO increased significantly in the PG (+) group after stent insertion (Fig. 6), and that SVR increased after dissection but decreased significantly in both the PG (+) group and the PG (-) group after stent insertion, the treatment appears to have increased the CO and reduced CVP and PAP by reducing afterload. We believe that stent insertion may be applicable to, and effective in the treatment of, patients with heart failure associated with dissection, since it is less invasive than other surgical procedures.

Aortic diameter was reduced after stent insertion in all groups other than the large re-entry group (Figs. 7, 8 and 9). Therefore, stent insertion is considered to be effective for reducing the blood flow into the dissection lumen and preventing aneurysm formation. In the large re-entry group, the stent blocked blood flow into the dissecting lumen, but aortic diameter was not reduced after stent insertion due to the blood backflow from the re-entry site. We observed that there were no changes in aortic diameter in the large re-entry group caused by backflow from the re-entry site. Thus, we believe that stent insertion is best performed as soon as possible after the onset of large re-entry formation, and that the stent is best placed at the large re-entry site. However, we did not evaluate the effectiveness of stent insertion to the large re-entry site after stent insertion to the entry site in this study.

The following pathological conditions associated with acute aortic dissection were suggested by the data from the pressure gradient and re-entry morphology groups: a) a pressure gradient is produced at the dissection site; b) blood flow is reduced on the distal side of the dissection; c) cardiac output decreases; and d) the afterload of the heart increases. After stent insertion, the above conditions were relieved, often significantly. Based on these observations, we conclude that stent insertion is useful for the treatment of acute aortic dissection.

**Acknowledgments.** The authors express their thanks to the technician Tetsuo Kawakami for his cooperation in the experiment.

## References

1. Doroghazi RM, Skater EE, DeSanctis RW, Buckley MJ, Austen WG and Rosenthal S: Long-term survival of patients with treated aortic Dissection. *J Am Coll Cardiol* (1984) **3**, 1026-1034.
2. Miller DC, Mitchell RS, Oyer PE, Stinson EB, Jamieson SW and Shumway NE: Independent determinants of operative mortality for



- patients with aortic dissections. *Circulation* (1984) **70** (3 pt 2), I153-I164.
3. Miller DC, Stinson EB, Oyer PE, Rossiter SJ, Reitz BA, Griep RB and Shumway NE: Operative treatment of aortic dissections. *J Thorac Cardiovasc Surg* (1979) **78**, 365-381.
  4. DeBakey ME, McCollum CH, Crawford ES, Morris GC Jr, Howell J, Noon GP and Lawrie G: Dissection and dissecting aneurysms of the aorta: Twenty-year follow-up of five hundred twenty-seven patients treated surgically. *Surgery* (1982) **92**, 1118-1133.
  5. Crawford ES, Svensson LG, Coselli JS, Safi HJ and Hess KR: Aortic dissection and dissecting aortic aneurysms. *Ann Surg* (1988) **208**, 254-273.
  6. Parodi JC, and Palmaz JC and Barone HD: Transfemoral intraluminal graft implantation for abdominal aortic aneurysms. *Ann Vasc Surg* (1991) **5**, 491-499.
  7. Dake MD, Miller DC, Semba CP, Mitchell RS, Walker PJ and Liddell RP: Transluminal placement of endovascular stent-grafts for the treatment of descending thoracic aortic aneurysms. *N Engl J Med* (1994) **331**, 1729-1734.
  8. Parodi JC: Endovascular repair of abdominal aortic aneurysms; in *Advances in Vascular Surgery*, Whittemore AD, Bandyk DF, Cronenwett JL, Hertzner NR and White RA eds, 1st Ed, Vol I, Mosby, Chicago (1993) pp85-106.
  9. Chuter TAM: Straight and bifurcated endovascular grafts for infrarenal aortic aneurysm repair; in *Endoluminal Vascular Prostheses*, Chuter TAM, Donayre CE and White RA eds, 1st Ed, Little Brown and Company, New York (1995) pp55-80.
  10. Semba CP and Dake MD: Endoluminal stent-grafting in the thoracic aorta; in *Endoluminal Vascular Prostheses*, Chuter TAM, Donayre CE and White RA eds, 1st Ed, Little Brown and Company, New York (1995) pp153-171.
  11. Kato M, Masuda T, Kotoh K, Kaneko M, Imagawa H, Ueda T, Kuratani T, Yoshioka Y and Ohnishi K: Development of a chronic endothelialized transcatheter implantable intra-aortic graft. *ASAIO J* (1993) **39**, M518-M521.
  12. Kato M, Ohnishi K, Kaneko M, Imagawa H, Ueda T, Kuratani T, Yoshioka Y and Matsuda T: Development of an expandable intra-aortic prosthesis for experimental aortic dissection. *ASAIO J* (1993) **39**, M758-M761.
  13. Karube N, Noishiki Y, Yamamoto K, Kondo J and Matsumoto A: Percutaneous insertion of a jacketed stent to close the entry of dissecting aortic aneurysms of DeBakey types I and II. *Artif Organs* (1993) **17**, 1004-1009.
  14. Kato N, Hirano T, Takeda K, Nakagawa T, Mizumoto T and Yuasa H: Treatment of acute aortic dissections with expandable metallic stents: Experimental study. *J Vasc Interv Radiol* (1994) **5**, 417-423.
  15. Wright KC, Wallace S, Charnsangavej C, Carrasco CH and Gianturco C: Percutaneous endovascular stents: An experimental evaluation. *Radiology* (1985) **156**, 69-72.
  16. Trent MS, Parsonnet V, Shoenfeld R, Brener BJ, Eisenbud DE, Novick AS, Campbell AY, Ferrara-Ryan M and Villanueva A: A balloon-expandable intravascular stent for obliterating experimental aortic dissection. *J Vasc Surg* (1990) **11**, 707-717.
  17. Lawrence DD Jr, Charnsangavej C, Wright KC, Gianturco C and Wallace S: Percutaneous endovascular graft: Experimental evaluation. *Radiology* (1987) **163**, 357-360.
  18. Chuter TAM, Green RM, Ouriel K, Fiore WM and DeWeese JA: Transfemoral endovascular aortic graft placement. *J Vasc Surg* (1993) **18**, 185-197.
  19. Blanton FS Jr, MüllerWH Jr and Warren WD: Experimental production of dissecting aneurysms of the aorta. *Surgery* (1959) **45**, 81-90.
  20. Hirst AE Jr, Johns VJ Jr and Wesley K Jr: Dissecting aneurysm of the aorta: A review of 505 cases. *Medicine* (1958) **37**, 217-277.
  21. Wheat MW Jr, Palmer RF, Bartley TD, Seelman RC and Gainesville: Treatment of dissecting aneurysms of the aorta without surgery. *J Thorac Cardiovasc Surg* (1965) **50**, 364-373.
  22. Anagnostopoulos CE, Prabhakar MJS and Kittle CF: Aortic dissection and dissecting aneurysms. *Am J Cardiol* (1972) **30**, 263-273.
  23. Pressler V and McNamara JJ: Thoracic aortic aneurysm natural history and treatment. *J Thorac Cardiovasc Surg* (1980) **79**, 489-498.
  24. Dotter CT: Transluminally placed coil-spring endarterial tube grafts: Long term patency in canine popliteal artery. *Invest Radiol* (1969) **4**, 329-332.

---

Received November 5, 1997; accepted December 16, 1997.