

Acta Medica Okayama

Volume 63, Issue 6

2009

Article 8

DECEMBER 2009

Breast Cancer with Cartilaginous and/or Osseous Metaplasia Diagnosed by Lymph Nodal Metastasis: A Case Report

Kazunori Tsukuda* Hisashi Tsuji† Tadayoshi Kunitomo‡
Keiju Aokage** Takayoshi Miyake††
Saki Nakahara‡‡ Hiroko Masuda§

*Department of Surgery, Okayama Red Cross General Hospital,

†Department of Surgery, Okayama Red Cross General Hospital,

‡Department of Pathology, Okayama Red Cross General Hospital,

**Department of Surgery, Okayama Red Cross General Hospital,

††Department of Pathology, Okayama Red Cross General Hospital,

‡‡Department of Surgery, Okayama Red Cross General Hospital,

§Department of Surgery, Okayama Red Cross General Hospital,

Breast Cancer with Cartilaginous and/or Osseous Metaplasia Diagnosed by Lymph Nodal Metastasis:A Case Report

Kazunori Tsukuda, Hisashi Tsuji, Tadayoshi Kunitomo, Keiju Aokage,
Takayoshi Miyake, Saki Nakahara, and Hiroko Masuda

Abstract

Breast cancer with cartilaginous and/or osseous metaplasia is a type of metaplastic carcinomas and is a rare disease. We report the case of a 49 year-old female who underwent right mastectomy for a large breast tumor. Histological examinations revealed a mixed tumor with both stromal and epithelial elements;the stroma showed poor differentiated spindle-shape and multiform cells with a massive osseous matrix, and atypical epithelial cells, which mainly existed on the surface of the cysts, showed nucleic atypia. The tumor was diagnosed as a malignant phyllodes tumor with osteosarcomatous differentiation;it was not identified as a metaplastic carcinoma because of the lack of proof of a cancerous component. Two years after a mastectomy, swelling of the axillary lymph nodes was found and a biopsy was performed. Histological findings for the lymph node indicated a metastasis of the invasive ductal carcinoma. The primary tumor was re-examined and was considered to be the origin of the lymph nodal metastasis. Lymph nodal metastasis of cancer proved that the primary tumor had cancerous potential, and the pathological diagnosis was altered to a breast cancer with cartilaginous and/or osseous metaplasia.

KEYWORDS: breast cancer, metaplastic cancer, phyllodes tumor

Case Report

**Breast Cancer with Cartilaginous and/or Osseous Metaplasia
Diagnosed by Lymph Nodal Metastasis: A Case Report**Kazunori Tsukuda^{a*}, Hisashi Tsuji^a, Tadayoshi Kunitomo^b, Keiju Aokage^a,
Takayoshi Miyake^b, Saki Nakahara^a, and Hiroko Masuda^a*Departments of ^aSurgery, and ^bPathology, Okayama Red Cross General Hospital, Okayama 700-8607, Japan*

Breast cancer with cartilaginous and/or osseous metaplasia is a type of metaplastic carcinomas and is a rare disease. We report the case of a 49 year-old female who underwent right mastectomy for a large breast tumor. Histological examinations revealed a mixed tumor with both stromal and epithelial elements; the stroma showed poor differentiated spindle-shape and multiform cells with a massive osseous matrix, and atypical epithelial cells, which mainly existed on the surface of the cysts, showed nucleic atypia. The tumor was diagnosed as a malignant phyllodes tumor with osteosarcomatous differentiation; it was not identified as a metaplastic carcinoma because of the lack of proof of a cancerous component. Two years after a mastectomy, swelling of the axillary lymph nodes was found and a biopsy was performed. Histological findings for the lymph node indicated a metastasis of the invasive ductal carcinoma. The primary tumor was re-examined and was considered to be the origin of the lymph nodal metastasis. Lymph nodal metastasis of cancer proved that the primary tumor had cancerous potential, and the pathological diagnosis was altered to a breast cancer with cartilaginous and/or osseous metaplasia.

Key words: breast cancer, metaplastic cancer, phyllodes tumor

Breast cancer with cartilaginous and/or osseous metaplasia is a special types of invasive breast cancer and has been reported to occur in only 0.003–0.12% of breast cancer cases [1, 2]. This breast cancer is characterized as a cartilaginous or osseous metaplasia, or both, in breast cancer tissue, and as a transitional zone between carcinoma and sarcoma-like metaplastic lesions. Based on these criteria of diagnosis, histological diagnosis is difficult in some cases. We report herein a case of metaplastic carcinoma that had been diagnosed as a malignant phyllodes tumor

because a sarcoma-like metaplastic lesion was dominant and epithelial malignancy could not confirmed in the primary tumor. The diagnosis of metaplastic carcinoma was finally made after identifying the presence of lymph nodal metastasis.

Case Report

A 49 year-old female patient had noticed a right breast tumor but did not consult a physician for 9 months. On a regular visit to our hospital for primary biliary cirrhosis and diabetes mellitus, which had been treated for the last 10 years, a physician noticed the breast tumor and consulted a general surgeon. The tumor occupied the entire right breast with skin

Received January 30, 2009; accepted July 1, 2009.

*Corresponding author. Phone:+81-86-222-8811; Fax:+81-86-222-8841
E-mail:jcb01512@nifty.com (K. Tsukuda)

involvement, redness, and ulceration and was fixed to the anterior chest wall. The tumor measured $20 \times 16 \times 13$ cm, but no right axillary or supra-clavicular lymph nodes were palpable. Mammography and magnetic resonance imaging revealed a huge heterogeneous mass with multiple cystic regions and septa (Fig. 1). A high intensity T2-weighted image indicated a pooling of blood or fluid inside of the cysts. Invasion to the skin and major pectoral muscle was shown, but no axillary lymph nodal swelling was observed. Other imaging modalities revealed no evidence of liver, lung, or bone metastases. Fine-needle aspiration biopsy did not confirm the diagnosis. After hospitalized treatment for primary biliary cirrhosis, surgical treatment was undertaken. Though ascites had diminished and the prothrombin time was normalized, the patient continued to suffer from jaundice and hypoalbuminemia; total bilirubin and albumin levels of 5.7 mg/dl and 2.6 g/dl, respectively, persisted at the time of the surgery. A simple mastectomy with a major pectoral muscle resection was performed but axillary lymphadenectomy was not undertaken, because of the patient's poor general condition.

The tumor showed a honeycomb structure, and cystic lesions contained hemorrhage and serous fluid (Fig. 2). Microscopic examination revealed as a mixed tumor with both stromal and epithelial elements. The stroma showed a high cellularity with poor differentiated spindle-shape and multiform cells and osteosarcoma like appearance, and osteoblast-like cells with a massive osseous matrix were also shown in some areas (Fig. 3A-D). Cuboid and polygonal

epithelial cells were found mainly on the surface of the cystic lesions (Fig. 3E) and showed hyperplasia and nucleic atypia. But cancer cell nests with invasion or infiltration to the stroma or massive vessel invasions were not found. The possibility of a metaplastic breast cancer versus malignant phyllodes tumor was suggested and a diagnosis of a malignant phyllodes tumor with osteosarcomatous differentiation was made at this time, because cancerous changes in the primary




Fig. 2 The macroscopic view of the primary tumor showed a honeycomb structure and cystic lesions.

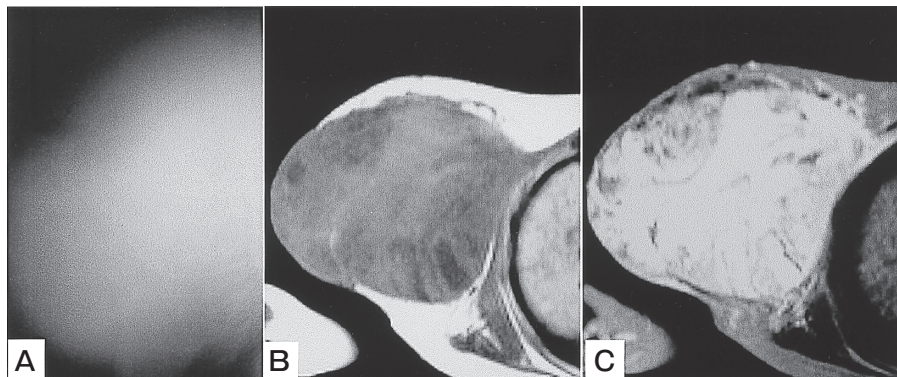


Fig. 1 A, Mammography demonstrated a huge tumor in the right breast. Coarse calcification was not observed; B, T1-weighted image of MRI demonstrated a low-intensity and heterogeneous tumor in the right breast; C, The high-intensity of the T2-weighted image implied a cystic lesion with pooling of blood or body fluid.

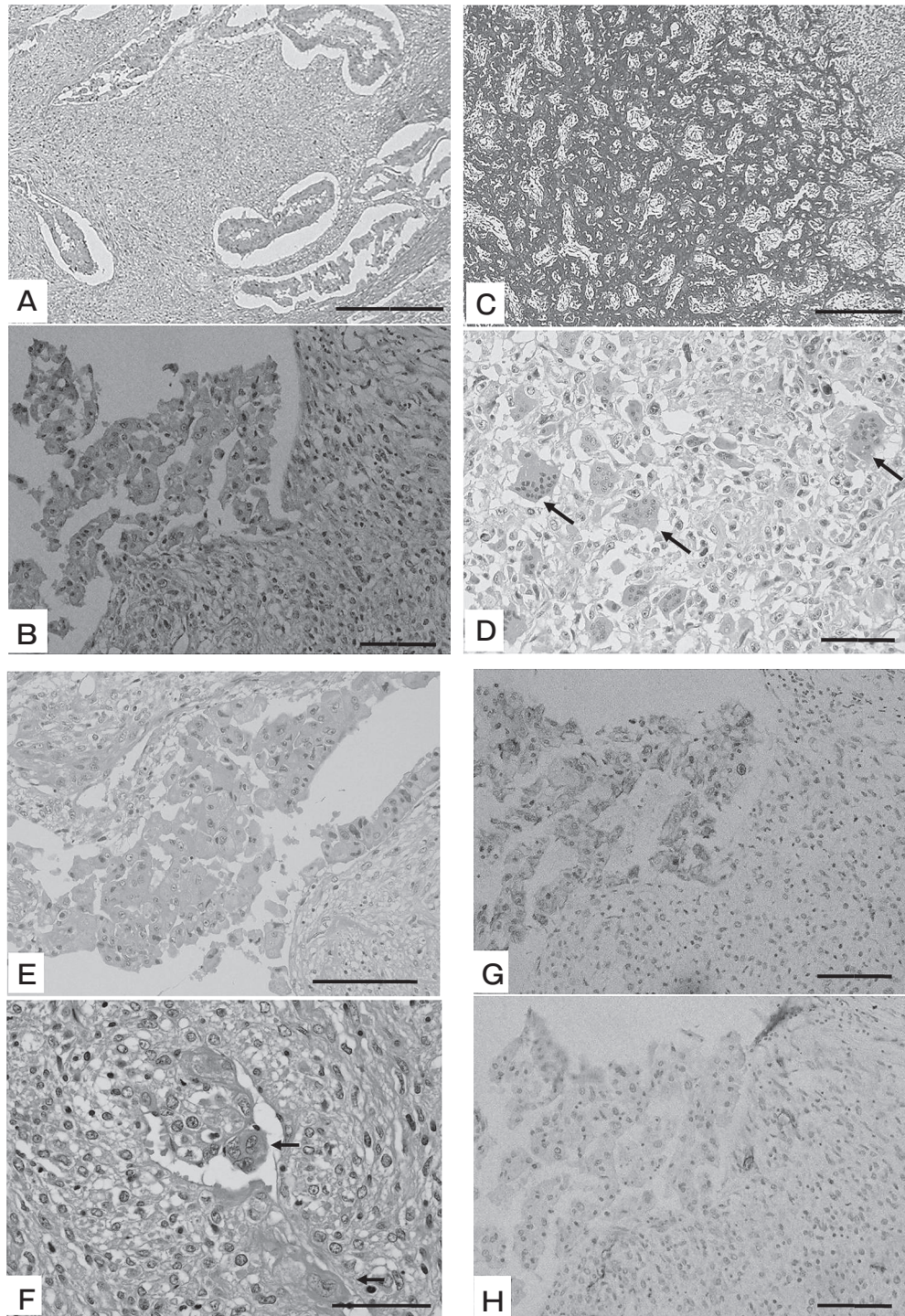


Fig. 3 Histological findings of the primary tumor. **A, B**: H&E staining showed a mixed tumor with both stromal and epithelial elements (bar: **A**, 100 μ m, **B**, 20 μ m); **C**: Azan staining showed a massive osseous matrix (bar: 40 μ m); **D**: Arrows indicate osteoclast-like giant cells (bar: 20 μ m); **E**: The epithelial cells on the surface of the cystic lesion showed nucleic atypia (bar: 30 μ m); **F**: Arrows indicate the cluster of epithelial cells in the lymphatic vessels (bar: 10 μ m); **G**: 34 β E12 was positive in epithelial cells, but not in the stromal area (bar: 20 μ m) (anti-34 β E12 was purchased from Dako, Glostrup, Denmark); **H**: CD34 was negative in both the epithelial and stromal areas (bar: 20 μ m) (anti-CD34 class II antibody was purchased from Dako).

tumor had not been clarified. This tumor was estrogen receptor-negative and progesterone receptor-negative.

During the 21st month following the surgery, computed tomography revealed right axillary lymph nodal swelling. The lymph nodes were gradually enlarged and biopsied for the pathological examination 28-months after the previous surgery. One out of 8 resected lymph nodes showed metastasis of ductal carcinoma (Fig. 4A). Immunohistochemistry revealed that these cancer cells had cytoplasmic positive expression of gross cystic disease fluid protein 15 (GCDFP15)/prolactin-inducible protein (PIP), characterized by apocrine cells (Fig. 4B). Epithelial cells of the primary breast tumor also expressed GCDFP15 in their cytoplasm, which is consistent with cancer cells of the axillary lymph node. GCDFP15 is a marker of apocrine epithelium and showed a positive test in malignancies such as a breast carcinoma with apocrine feature or Paget's disease. In the present case, the primary breast tumor was considered to be the origin of the lymph nodal metastasis, which proved

that the epithelial component of the primary tumor had malignant characteristics. Thus the pathological diagnosis of primary breast tumor was altered to cancer with cartilaginous and/or osseous metaplasia and lymph nodal metastasis. Re-examination of the primary tumor was carried out, and a cluster of epithelial cells in lymphatic vessels that suggested lymphatic invasion was found (Fig. 3F), but cancer cell nests with invasive proliferation were not confirmed. According to Dunne's report [3], immunohistochemical examination with 34 β E12 and CD34 was also performed. Though the epithelial component was positive for 34 β E12, either 34 β E12 or CD34 was negative in the stromal area (Fig. 3G, H). Positive staining of cytokeratins in the stromal area is considered to support a diagnosis of metaplastic carcinoma, but such positive staining did not occur in this case. Adjuvant chemotherapy was not undertaken because of liver dysfunction. No liver tumor or other malignancies were confirmed throughout the observation period. Though no recurrence was observed over a 12-month follow-up period, the patient died of liver failure.

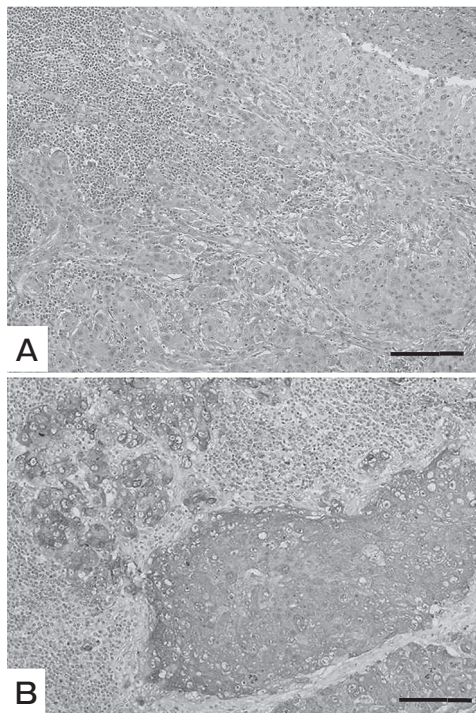


Fig. 4 Histological findings of the axillary lymph node. **A**, Histology of the lymph node showed metastasis of ductal carcinoma (bar: 30 μ m); **B**, Immunohistochemistry revealed that cancer cells had positive expression of GCDFP15/PIP (anti-GCDFP15 was purchased from Kyodo Byori, Kobe, Japan) (bar: 30 μ m).

Discussion

Breast cancer with cartilaginous and/or osseous metaplasia is a special type of invasive breast cancer. The clinicopathological features of this cancer have been reported to be a comparatively large tumor size with rapid enlargement, a lack of specific findings on radiographic examinations, an occasional cystic pattern, and the presence of necrotic or hemorrhagic tissues [4, 5]. In addition, metastasis to axillary lymph nodes is rarely observed and occurs at a rate comparable to common breast cancers. Cartilaginous or osseous metaplasia is observed in the breast cancer tissue derived from glandular epithelium, and a transitional zone exists between carcinoma and sarcoma-like metaplastic lesions. It has been reported that these cancers show cartilaginous metaplasia alone in 51% of cases, both cartilaginous and osseous metaplasia in 42% of cases, and osseous metaplasia alone in 7% of cases [6].

The differential diagnosis is important with this cancer because diseases of the mammary gland with cartilaginous and/or osseous metaplasia include phylloides tumor, primary sarcoma, and mixed fibroma-

toses [7]. In our case, the primary pathological diagnosis was malignant phyllodes tumor with osteosarcomatous differentiation because the presence of cancerous components such as invasive proliferation or metastasis at the time of the first surgery could not be confirmed. We finally made a diagnosis of metaplastic carcinoma, however, because lymph nodal metastasis was shown later; immunohistochemical examination of the epithelial components of the primary breast tumor was consistent with metastatic carcinomas of the lymph node. Though reexamination of the primary tumor has carried out after the recurrence, it was difficult to confirm the presence of cancerous components in the primary tumor histologically. Immunohistochemical markers may be helpful for differential diagnosis in such cases. Dunne *et al.* have reported that immunohistochemistry may be helpful in distinguishing metaplastic carcinoma from others because the expression of cytokeratins; 34 β E12, cytokeratin 5, and cytokeratin 14 in the sarcomatous area is unique for metaplastic carcinomas [3]. According to their report, 11 out of 18 cases (61%) were positive for 34 β E12 in metaplastic carcinomas, while none of the phyllodes tumors was positive. In contrast, CD34 and bcl-2 are more frequently expressed in phyllodes tumors than in metaplastic carcinomas; 18 out of 26 phyllodes tumors (69%) were positive for CD34, while none of the metaplastic cancers expressed CD34 in their stromal area. Because both 34 β E12 and CD34 were negative in our case, the immunohistochemical examination did not support or contradict the pathological diagnosis.

The coexistence of carcinomatous and heterogeneous sarcomatous components is a characteristic of metaplastic carcinomas. Genetic evidence for *p53* alterations, which is identical in both carcinomatous and sarcomatous components, supports a monoclonal histogenesis of various components of the metaplastic carcinomas [8, 9]. In contrast, allelic imbalance is not always identical in the stroma and epithelium in phyllodes tumors [10]. These molecular examinations may therefore help with the differential diagnosis of these diseases.

The overall survival rates of metaplastic breast cancer have been reported to be the same as those of ordinary invasive ductal breast cancers [11]. However, Rayson *et al.* have reported that disease-

free survival and overall survival is decreased compared to typical carcinoma and that systemic therapy appears to be less effective [12]. Some reports have recommended that surgical and adjuvant treatment should be followed according to the guidelines for other common breast cancers [13].

References

1. Huvos AG, Lucas JC and Foote FW: Metaplastic breast carcinoma-Rare form of mammary cancer. *NY State J Med* (1973) 73: 1078-1082.
2. The 17th Japanese Association for Breast Cancer Research: *J Jpn Soc Cancer Therapy* (1974) 9: 71-75 (in Japanese).
3. Dunne B, Lee AH, Pinder SE, Bell JA and Ellis IO: An immunohistochemical study of metaplastic spindle cell carcinoma, phyllodes tumor and fibromatosis of the breast. *Hum Pathol* (2003) 34: 1009-1015.
4. Gunhan-Bilgen I, Memis A, Ustun EE, Zekioglu O and Ozdemir N: Metaplastic carcinoma of the breast: clinical, mammographic, and sonographic findings with histopathologic correlation. *AJR Am J Roentgenol* (2002) 178: 1421-1425.
5. Ninomiya J, Oyama T, Horiguchi J, Koibuchi Y, Yoshida T, Iijima K, Yoshida M, Takata D, Iino Y and Morishita Y: Two case of breast cancer with cartilaginous and osseous metaplasia. *Breast Cancer* (2005) 12: 52-56.
6. Tazawa K, Takahashi H, Yamagishi F, Suzuki S, Shimizu T, Tsukada K, Takagawa K and Ishizawa S: A case of carcinoma of the left breast with cartilaginous metaplasia. *Rinshogeka* (2001) 56: 117-120 (in Japanese).
7. Gal-Gombos EC, Esserman LE, Poniecka AW, Odzer SL, Weisberg S, Godinez J and Poppiti RJ: Osseous metaplasia of the breast: diagnosis with stereotactic core biopsy. *Breast J* (2002) 8: 50-52.
8. Wang X, Mori I, Tang W, Yang Q, Nakamura M, Nakamura Y, Sato M, Sakurai T and Kenichi K: Metaplastic carcinoma of the breast: p53 analysis identified the same point mutation in the three histological components. *Mod Pathol* (2001) 14: 1183-1186.
9. Lien HC, Lin CW, Mao TL, Kuo SH, Hsiao CH and Huang CS: p53 overexpression and mutation in metaplastic carcinoma of the breast: genetic evidence for a monoclonal origin of both the carcinomatous and the heterogeneous sarcomatous components. *J Pathol* (2004) 204: 131-139.
10. Sawyer EJ, Hanby AW, Ellis P, Lakhani SR, Ellis IO, Boyle S and Tomlinson IP: Molecular analysis of phyllodes tumors reveals distinct changes in the epithelial and stromal components. *Am J Pathol* (2000) 156: 1093-1098.
11. Chhieng C, Cranor M, Lesser ME and Rosen PP: Metaplastic carcinoma of the breast with osteocartilaginous heterologous elements. *Am J Surg Pathol* (1998) 22: 188-194.
12. Rayson D, Adjei AA, Suman VJ, Wold LE and Ingle JN: Metaplastic breast cancer: prognosis and response to systemic therapy. *Ann Oncol* (1999) 10: 413-419.
13. Bellino R, Arisio R, D'Addato F, Attini R, Durando A, Danese S, Bertone E, Grio R and Massobrio M: Metaplastic breast carcinoma: pathology and clinical outcome. *Anticancer Res* (2003) 23: 669-673.