

# *Acta Medica Okayama*

---

*Volume 59, Issue 5*

2005

*Article 9*

OCTOBER 2005

---

Term delivery choriocarcinoma patient with  
brain and lung metastases successfully treated  
by etoposide, methotrexate, actomycin D,  
cyclophosphamide and vincristine (EMA-CO)  
chemotherapy.

Yuji Hiramatsu\*

Hisashi Masuyama<sup>†</sup>

Makoto Ishida<sup>‡</sup>

Kazuharu Murakami\*\*

Masaru Sakurai<sup>††</sup>

\*Okayama University,

<sup>†</sup>Okayama University,

<sup>‡</sup>Hiroshima Red Cro Hospital & Atomic-bomb Survivors Hospital,

\*\*Tamashima Central Hospital,

<sup>††</sup>Tamashima Central Hospital,

# Term delivery choriocarcinoma patient with brain and lung metastases successfully treated by etoposide, methotrexate, actomycin D, cyclophosphamide and vincristine (EMA-CO) chemotherapy.\*

Yuji Hiramatsu, Hisashi Masuyama, Makoto Ishida, Kazuharu Murakami, and Masaru Sakurai

## Abstract

It is well known that antecedent term delivery and metastasis to sites other than the lungs and vagina are high risk factors for patients with gestational trophoblastic neoplasia. Here we report on a patient with choriocarcinoma who presented with brain and lung metastases after term delivery and was treated by EMA-CO chemotherapy. A 31-year-old woman delivered a healthy infant at term. Frequent episodes of hemoptysis occurred beginning 3 weeks after the delivery. On admission to our hospital, she had lesions in the uterus, lungs and brain as well as motor aphasia and hemiplegia. The pretreatment beta-hCG level was 21,000 ng/ml and the WHO score was 16 (high-risk group). The EMA-CO regimen was administered as first-line chemotherapy and the patient achieved complete remission after 7 courses. Treatment was terminated after 11 courses and maintained with etoposide (25 mg/day) for 6 months. The patient has remained in complete remission for more than 16 years without other adjuvant therapies. We believe that EMA-CO can currently be considered the regimen of first choice for most high-risk patients with gestational trophoblastic neoplasia in view of its effectiveness and excellent tolerability.

**KEYWORDS:** choriocarcinoma, term delivery, EMA-CO chemotherapy, metastasis

---

\*PMID: 16286962 [PubMed - indexed for MEDLINE]

Copyright (C) OKAYAMA UNIVERSITY MEDICAL SCHOOL

Case Report

## Term Delivery Choriocarcinoma Patient with Brain and Lung Metastases Successfully Treated by Etoposide, Methotrexate, Actomycin D, Cyclophosphamide and Vincristine (EMA-CO) Chemotherapy

Yuji Hiramatsu<sup>a\*</sup>, Hisashi Masuyama<sup>a</sup>, Makoto Ishida<sup>b</sup>,  
Kazuharu Murakami<sup>c</sup>, and Masaru Sakurai<sup>c</sup>

<sup>a</sup>Department of Obstetrics & Gynecology, Okayama University Graduate School of Medicine, Dentistry and Pharmaceutical Sciences, Okayama 700-8558, Japan,

<sup>b</sup>Hiroshima Red Cross Hospital & Atomic-bomb Survivors Hospital, Hiroshima 730-0052, Japan, and

<sup>c</sup>Tamashima Central Hospital, Kurashiki, Okayama 713-8122, Japan

It is well known that antecedent term delivery and metastasis to sites other than the lungs and vagina are high risk factors for patients with gestational trophoblastic neoplasia. Here we report on a patient with choriocarcinoma who presented with brain and lung metastases after term delivery and was treated by EMA-CO chemotherapy. A 31-year-old woman delivered a healthy infant at term. Frequent episodes of hemoptysis occurred beginning 3 weeks after the delivery. On admission to our hospital, she had lesions in the uterus, lungs and brain as well as motor aphasia and hemiplegia. The pretreatment  $\beta$ -hCG level was 21,000 ng/ml and the WHO score was 16 (high-risk group). The EMA-CO regimen was administrated as first-line chemotherapy and the patient achieved complete remission after 7 courses. Treatment was terminated after 11 courses and maintained with etoposide (25 mg/day) for 6 months. The patient has remained in complete remission for more than 16 years without other adjuvant therapies. We believe that EMA-CO can currently be considered the regimen of first choice for most high-risk patients with gestational trophoblastic neoplasia in view of its effectiveness and excellent tolerability.

**Key words:** choriocarcinoma, term delivery, EMA-CO chemotherapy, metastasis

**R**ecently, gestational trophoblastic neoplasia has become the most curable of gynecological malignancies for several reasons. DiSaia and Cresman [1] summarized these reasons as follows: 1) a sensitive marker is produced by the tumor *i.e.*, human chorionic gonadotropin (hCG), and the amount of hormone

produced is directly related to the number of viable tumor cells; 2) this tumor is extremely sensitive to various chemotherapy agents; 3) risk factors for recurrence are known, allowing treatment to be individualized; and 4) the aggressive use of multiple treatment modalities, such as single- and multiple-agent chemotherapy regimens, radiation, and surgery.

Nevertheless, the failure rate among "high-risk" patients is still too high despite the use of aggressive multi-drug regimens [2-4]. These patients usually have

Received March 24, 2005; accepted May 11, 2005.

\*Corresponding author. Phone: +81-86-235-7317; Fax: +81-86-225-9570  
E-mail: kiki1063@cc.okayama-u.ac.jp (Y. Hiramatsu)

multiple metastases (including brain and liver), high hCG levels, and term delivery.

Here, we report a case of choriocarcinoma presenting after term delivery with more than 16 years of survival in complete remission. The patient initially had lung and brain metastases with motor aphasia and hemiplegia, and was treated by etoposide, methotrexate, actinomycin D, cyclophosphamide and vincristine (EMA-CO) regimen.

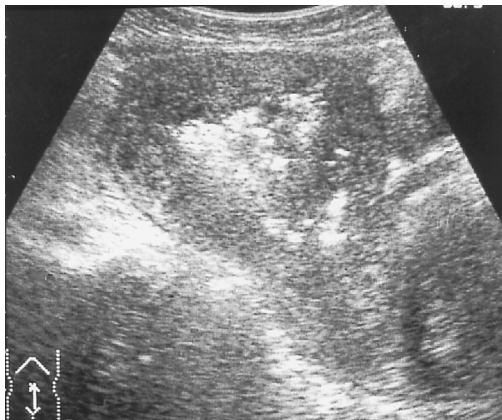### Case Report

A 31-year-old woman (gravida 3, para 2) who had no history of chorionic disease delivered a 3,265 g male infant on August 8, 1988. The placenta was macroscopically normal. The patient continued to have daily slight vaginal bleeding after delivery and frequently episodes of hemoptysis which began at the end of August. A physician detected coin lesions in both lungs by radiographic examination. She had generalized convulsions on September 30. A computed tomographic (CT) scan of the brain revealed a lesion in the left frontal lobe; motor aphasia subsequently developed. Further examination revealed that the urinary hCG level was over 300,000 IU/l and the serum hCG level was 497,000 IU/l. The patient was referred to the Okayama University Hospital for further examination and treatment.

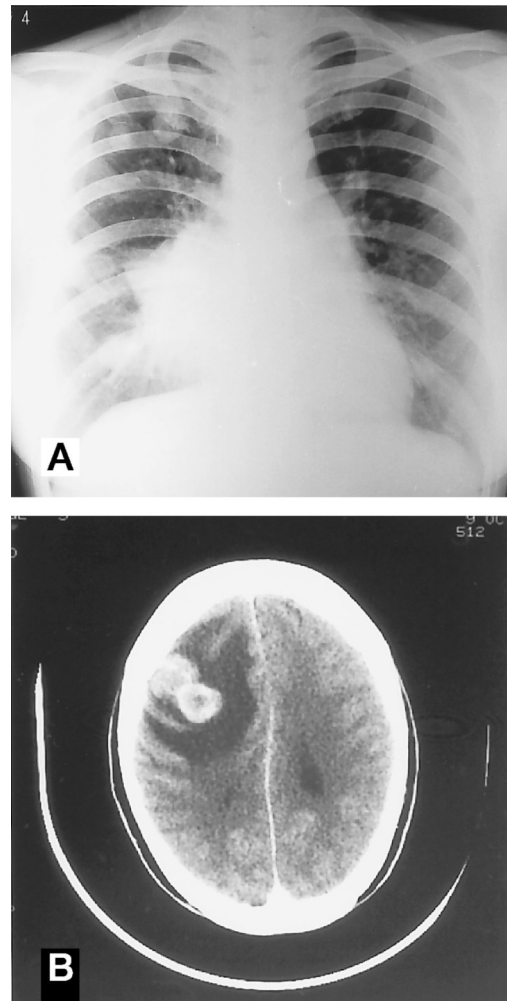
On admission, physical examination revealed right hemiplegia, motor aphasia, and genital bleeding, and the uterus was the size of a 10-week pregnancy. The pretreatment serum hCG level was 866,000 IU/l, the serum  $\beta$ -hCG level was 21,000 IU/l, and the urinary hCG level

was 512,000 IU/l. Ultrasonographic examination detected an intrauterine mass of 6 cm in diameter (Fig. 1). A chest X-ray (Fig. 2A) and thoracic CT scan detected scattered metastatic lesions in the bilateral lungs, and the brain CT examination revealed a large metastasis in the left frontal lobe (Fig. 2B). According to the modification of Bagshawe's scoring system by the World Health Organization (WHO) the patient scored 16, placing her in the high risk group ( $\geq 8$ ) and the FIGO stage was IVa. Therefore, the EMA-CO regimen of Bagshawe (Table 1) [5] was used as first-line chemotherapy for this patient.

With the first course of treatment, the patient suffered nausea, vomiting, and myelosuppression. However, few



**Fig. 1** Ultrasonography at admission. Longitudinal lower abdominal ultrasonographic examination showed an intrauterine mass about 6 cm in diameter with mixed echogenicity.



**Fig. 2** Chest X-ray film and brain CT scan at admission. There is a large mass around the right hilar region and multiple coin lesions in the lung fields (A). A large metastatic lesion is seen in the left frontal lobe (B).

**Table 1** EMA-CO Regimen

Course 1 (EMA)	
Day 1	Etoposide; 100 mg/m <sup>2</sup> , i.v. infusion in 200 ml of saline over 30 min Actinomycin D; 0.5 mg, i.v. push Methotrexate; 100 mg/m <sup>2</sup> , i.v. push followed by a 200 mg/m <sup>2</sup> , i.v. infusion over 12 h
Day 2	Etoposide; 100 mg/m <sup>2</sup> , i.v. infusion in 200 ml of saline over 30 min Actinomycin D; 0.5 mg, i.v. push Folic acid; 15 mg, i.m. or orally every 12 h for 4 days beginning 24 h after start
Course 2 (CO)	
Day 8	Vincristine; 1.0 mg/m <sup>2</sup> , i.v. push Cytosine; 600 mg/m <sup>2</sup> , i.v. in saline

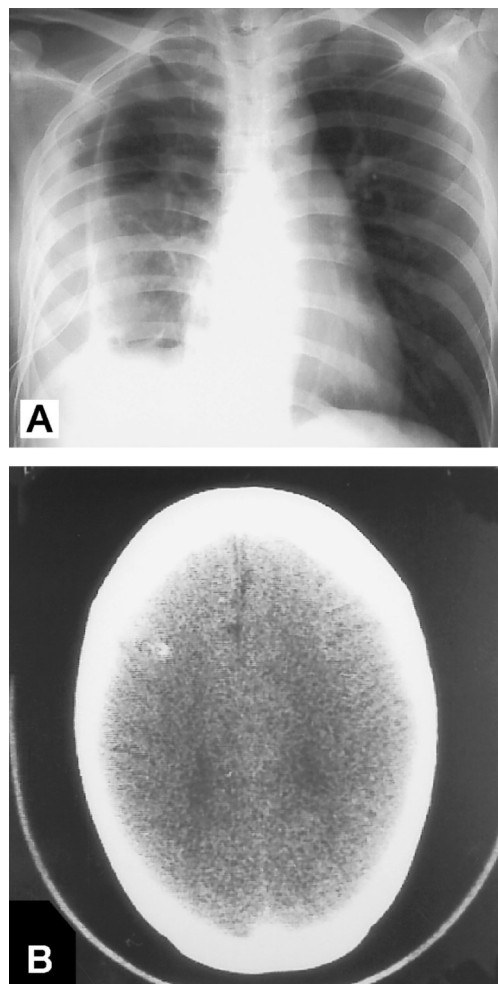
This regimen consists of 2 courses: 1) course 1 is given on days 1 and 2, 2) course 2 is given on day 8. These courses can usually be given on day 1 and 2, 8, 15 and 16, 22 *etc.*, and the intervals should not be extended without course.

side effects were noted after the first course and the tumors rapidly became smaller. Approximately 4 months after commencing chemotherapy, the patient achieved complete remission, as determined by 3 negative weekly  $\beta$ -hCG assays. At this time, she had received 7 courses of EMA-CO chemotherapy. Five consolidation courses were performed after complete remission and treatment was terminated after a total 11 courses (6 months after presentation). The chest X-ray and brain CT scan obtained after 10 courses are shown in Fig. 3. After 11 courses of EMA-CO chemotherapy, the patient was maintained with etoposide (25 mg/day) for 6 months. The patient has now been in complete remission for more than 16 years.

## Discussion

Choriocarcinoma is one of the most rapidly invasive and widely metastasizing malignancies, and its incidence is 1 per 150,000–160,000 normal pregnancies. The prognosis for patients with metastatic choriocarcinoma following term gestation is generally poor [3]. The more extensive spread of disease and the decreased responsiveness to chemotherapy following term gestation are postulated to be due to a change in the host immune response and/or a delayed diagnosis. Although vaginal bleeding is the most common presenting symptom of this carcinoma, it can occur at any time during pregnancy and the puerperium for a variety of reasons. Thus, the disease is generally widely disseminated at the time of diagnosis, and there is with a large tumor volume and a markedly elevated hCG titer.

There are several factors that adversely influence the response to treatment in patients with metastatic choriocarcinoma. Lurain *et al.* [3] proposed the following 6



**Fig. 3** The X-ray and brain CT scan after 10 courses of EMA-CO chemotherapy. The X-ray (A) shows only atelectasis of the right lung because of long-term drainage removing fluid due to tumor necrosis. No metastatic lesions were found at this time. The brain CT scan (B) shows a very small left frontal lesion and that appears to be calcified.

prognostic factors from a literature review: 1) a clinicopathological diagnosis of choriocarcinoma; 2) more than 4 months from the antecedent pregnancy to treatment; 3) a pretreatment hCG titer > 100,000 IU/L; 4) metastasis to sites other than the lungs and vagina; 5) antecedent term gestation; and 6) previous failed therapy. It has also been reported that patients with metastatic high-risk gestational trophoblastic disease following term pregnancy have a 50.0% remission rate (11/22) compared to a 75.0% remission rate (18/24) for women with metastatic choriocarcinoma following other types of pregnancy [3].

The number of high-risk factors present had a very significant effect on the response to treatment. If there were only 1 or 2 of the high-risk factors outlined above, the survival rate was 74%, in contrast to only 27% for patients with 3 or 4 factors [3]. The patient in this case had 3 high-risk factors and thus presented a very high-risk case, but she has survived for more than 16 years in complete remission.

Several multi-drug chemotherapy schedules have been reported, including MAC (methotrexate, actinomycin D, and cyclophosphamide), CHAMOCA, and EMA-CO [5]. The cure rate achieved with the MAC regimen was reported to be 51% for primary treatment and 30% for secondary treatment [3]. The CHAMOCA regimen was reported to produce complete clinical remission in patients who were resistant to MAC therapy, but it is a highly toxic protocol. Bolis *et al.* [6] reported that the overall response rate of EMA-CO was 86% with 81% of subjects surviving a median observation time of 32 months, while the survival rate of high-risk patients was 88% with 76% having no evidence of disease. In addition, they reported that the remission rate for second-line treatment by the EMA-CO regimen was 64%, which is higher than the rates achieved using other regimens such as MAC or CHAMOCA.

The toxicity of EMA-CO regimen is acceptable and less than that of the CHAMOCA or MAC regimens. Our patient was treated with only EMA-CO therapy and maintenance etoposide. Etoposide shows promise not only as first-line therapy, but also in treating patients who have become resistant to conventional therapy [1]. Recently, it was reported that taxanes have also been effective with relapsed high-risk trophoblastic disease [7, 8].

In gestational trophoblastic disease, it is necessary to

continue treatment even after a negative hCG titer is achieved. As is well known, a minimum of  $10^4$  viable tumor cells are necessary to produce a detectable  $\beta$ -hCG titer, so most authors advocate at least three consolidation courses. Moreover, relapse sometimes occurs after several years of complete remission. The likelihood of relapse depends on individual risk factors; however, the overall relapse rate for EMA-CO therapy was reported to be 11% by Newland *et al.* [4] and 19.0% by Bolis *et al.* [6].

Accordingly, adjuvant therapy is given to most high-risk patients. Cerebral metastasis may be treated simultaneously with whole-brain irradiation of 30 to 40 Gy, while hysterectomy and thoracotomy are used for the excision of resistant tumor foci [1, 3].

It is well known that secondary chemotherapy yields poor results in patients with gestational trophoblastic disease [3], so is very important to choose the most effective regimen for treating high risk metastatic choriocarcinoma from the start. We believe that currently the EMA-CO regimen should be considered the first-line for most high-risk patients with gestational trophoblastic disease in view of the good response rate it has achieved and its excellent tolerability.

## References

1. DiSaia PJ and Cresman WT: Gestational trophoblastic neoplasia; in Clinical Gynecologic Oncology, 4th Ed, Mosby Year Book, St. Louis (1993) pp 210-237.
2. Begent RH and Bagshawe KD: The management of high-risk choriocarcinoma. *Semin Oncol* (1982) 9: 198-207.
3. Lurain JR and Brewer JI: Treatment of high-risk gestational trophoblastic disease with methotrexate, actinomycin D, and cyclophosphamide chemotherapy. *Obstet Gynecol* (1985) 65: 830-836.
4. Newlands ES, Bagshawe KD, Begent RH, Rustin GJ, Holden L and Dent J: Developments in chemotherapy for medium- and high-risk patients with gestational trophoblastic tumors (1979-1984). *Br J Obstet Gynecol* (1986) 93: 63-69.
5. Bagshawe KD: Treatment of high-risk choriocarcinoma. *J Reprod Med* (1984) 29: 813-820.
6. Bolis G, Bonazzi C, Landoni F, Mangili G, Vergadoro F, Zanaboni F and Mangioni C: EMA/CO regimen in high-risk gestational trophoblastic tumor (GTT). *Gynecol Oncol* (1988) 31: 439-444.
7. Joshua AM, Carter JR and Beale P: The use of taxanes in choriocarcinoma; a case report and review of the literature. *Gynecol Oncol* (2004) 94: 581-583.
8. Osborne R, Covens A, Merchandani DE and Gerulath A: Successful salvage of relapsed high-risk gestational trophoblastic neoplasia patients using a novel paclitaxel-containing doublet. *J Reprod Med* (2004) 49: 655-661.