

Acta Medica Okayama

Volume 42, Issue 6

1988

Article 8

DECEMBER 1988

A case of complete atrioventricular block due to malignant lymphoma.

Masaharu Shigenobu*

Hiroshi Mukuzono†

Shigeru Teramoto‡

*Okayama University,

†Okayama University,

‡Okayama University,

A case of complete atrioventricular block due to malignant lymphoma.*

Masaharu Shigenobu, Hiroshi Mukuzono, and Shigeru Teramoto

Abstract

A case of malignant lymphoma associated with complete heart block in a 30-year-old woman is reported. The patient progressively deteriorated despite temporary pacing and died 24 days after being admitted. Microscopic examination of the heart revealed marked infiltration by lymphoma cells in the atrioventricular node and the bundle of His. A diffuse lymphoma (large cell type, B cell) was diagnosed. This case is considered to be rare, since complete heart block was the first and only manifestation of the malignant lymphoma.

KEYWORDS: malignant lymphoma, complete heart block, cardiac involvement

*PMID: 3239440 [PubMed - indexed for MEDLINE]

Copyright (C) OKAYAMA UNIVERSITY MEDICAL SCHOOL

A Case of Complete Atrioventricular Block Due to Malignant Lymphoma

Masaharu Shigenobu*, Hiroshi Mukuzono^a, and Shigeru Teramoto

Second Department of Surgery and ^aDepartment of Pathology, Okayama University Medical School, Okayama 700, Japan

A case of malignant lymphoma associated with complete heart block in a 30-year-old woman is reported. The patient progressively deteriorated despite temporary pacing and died 24 days after being admitted. Microscopic examination of the heart revealed marked infiltration by lymphoma cells in the atrioventricular node and the bundle of His. A diffuse lymphoma (large cell type, B cell) was diagnosed. This case is considered to be rare, since complete heart block was the first and only manifestation of the malignant lymphoma.

Key words : malignant lymphoma, complete heart block, cardiac involvement

Complete atrioventricular block directly attributable to a cardiac lymphoma is extremely rare. A case is presented in which chest pain and general fatigue due to complete heart block were the first manifestations of malignant lymphoma.

A 30-year-old woman was admitted on March 3, 1987, with chest pain and general fatigue on exertion, and slight fever. Physical examination revealed a well-developed but slightly dyspneic woman with moderate conjunctival pallor. The pulse rate was regular. The blood pressure in the right arm was 108/56 mmHg. Examination of the heart revealed no heart murmur. There were lymphadenopathies involving both the lateral neck and inguinal regions. These lymph nodes were up to 1.5 cm in size and reasonably discrete. Abdominal examination showed a firm, tender liver, extending 6 cm below the costal margin. The spleen was

also enlarged up to 2 cm below the left costal margin. Abdominal CT revealed hepatosplenomegaly associated with ascites.

The following laboratory data were obtained: red blood cell, $384 \times 10^3/\text{mm}^3$; hemoglobin, 11.8 g/dl; white blood cell, $7300/\text{mm}^3$; GOT, 131 IU/l; GPT, 83 IU/l; total bilirubin, 1.4 mg/dl; LDH, 1913 IU/l; ALP, 1501 LU/l; erythrocyte sedimentation rate, 75 mm/h, and CEA, 0.9 ng/ml. The electrolytes and bicarbonates were within normal limits. A chest x-ray showed slight enlargement of the heart.

The initial electrocardiogram recorded on the first day of admission displayed a pattern of complete atrioventricular block (Fig. 1).

Temporary pacing was applied through the right subclavian vein by the supraclavicular approach. Her condition improved temporarily, but high fever (38-40°C) occurred on the 4th day of admission and continued until she expired. A chest x-ray on the

* To whom correspondence should be addressed.

16th day of admission showed marked enlargement of the heart and pleural effusion. Five consecutive blood cultures were all negative.

Blood examinations revealed atypical lymphocytes, promyelocytes and myeloblasts. This finding suggested a leukemic type of malignant lymphoma in the present case. Bone marrow aspiration showed no leukemic cells.

The patient progressively deteriorated despite of administration of antibiotics and steroids. An echocardiogram showed normal cardiac function except for approximately 200 ml of pericardial effusion. Blood urea increased to 62.3 mg/dl, serum creatinine to 2.28 mg/dl, total bilirubin to 23.58 mg/dl, GOT to 500 IU/l, GPT to 346 IU/l, LDH to 3240 IU/l and ALP to 227 IU/l. She died 24 days after being admitted because of multiple organ failure.

Postmortem findings were as follows: An autopsy disclosed a malignant lymphoma in the advanced stage, infiltrating to the heart,

both lungs, liver, pancreas, digestive tract, both kidneys, urinary bladder, uterus, both ovaries, both adrenal glands, thyroid gland and spleen. There were lymphadenopathies involving the anterior mediastinal, paratracheal, paraaortic and mesenteric chains. A microscopic examination demonstrated that the malignant lymphoma was of the diffuse, large cell type according to the Working Formulation of malignant lymphoma. Immunohistochemically, large lymphoma cells were stained positively for leucocyte common antigen and MB-1, but not for MT-1, Ig kappa or Ig lambda chains, so the malignant lymphoma was considered to be a B cell lymphoma. The heart weighed 319 g and showed diffuse subepicardial petechiae. The conduction system was examined histologically. Malignant lymphoma cells diffusely infiltrated the inter-ventricular septum (Fig. 2A). The structure of the atrioventricular node was destroyed by marked infiltration, which also occurred in the cardiac muscle and the bundle of His. (Fig. 2B). It was

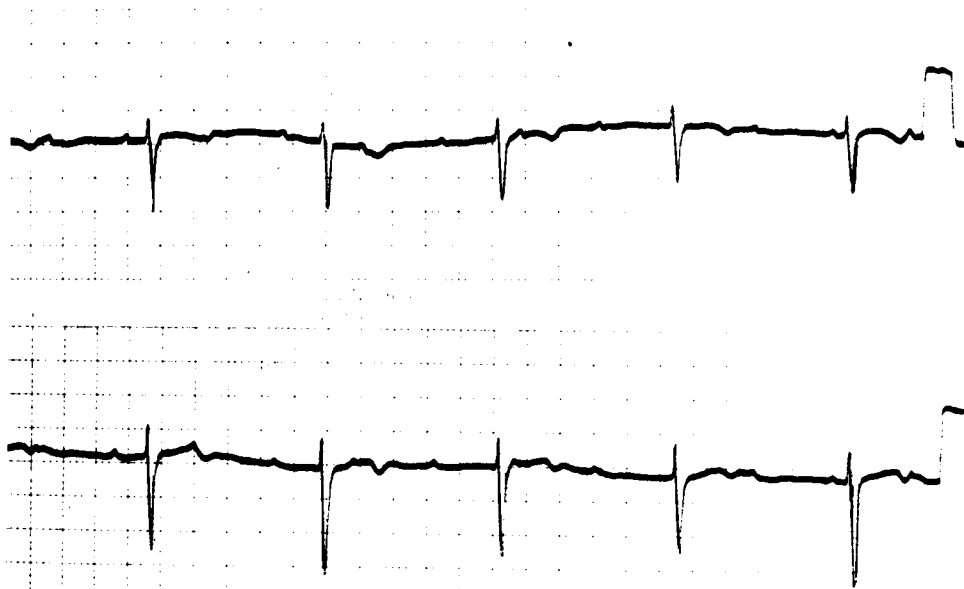


Fig. 1 Electrocardiogram (leads V₁, V₂ from top to bottom; paper speed 25 mm/sec) showing complete atrioventricular block.

clearly demonstrated that the disturbance of the heart conduction was caused by the infiltration of malignant lymphoma cells into the atrioventricular node and the upper part of

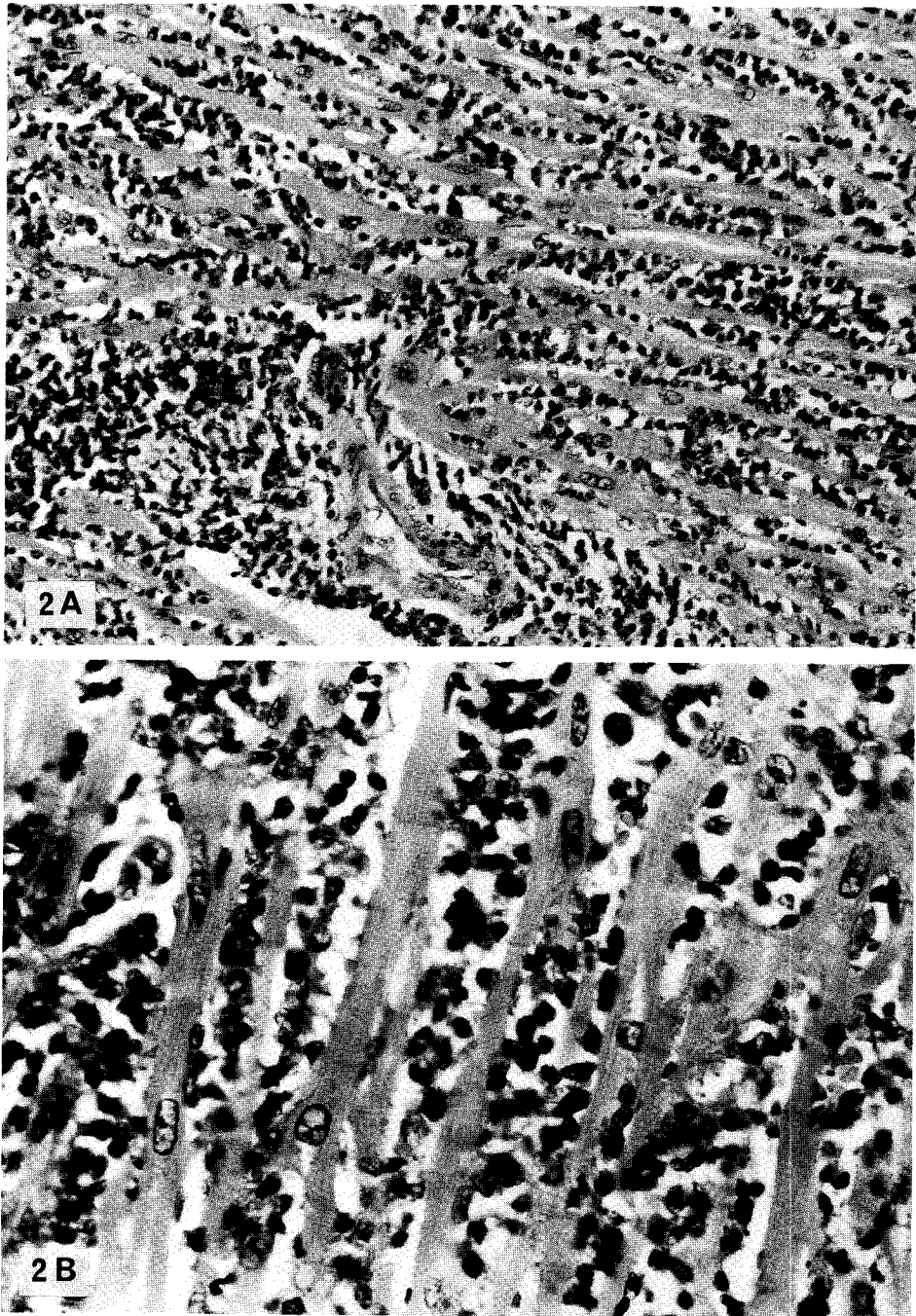


Fig. 2 Photomicrograph of a section of the interventricular septum (A) and the bundle of His (B) showing diffuse infiltration by malignant lymphoma cells. Hematoxylin-Eosin stain (original magnification A, $\times 200$ and B, $\times 400$).

the bundle of His.

Over 9% of all metastases to the heart are from lymphomas and up to 20% of patients dying of lymphoma are found to have cardiac metastasis. These statistics suggest a much higher incidence of cardiac involvement than has been reported (1,2). The antemortem diagnosis of cardiac involvement is often difficult, since the clinical signs and symptoms of cardiac dysfunction may not be specific, so that findings of cardiac metastasis by malignant lymphoma are largely derived from autopsy studies. In the present case, the antemortem diagnosis of cardiac involvement was not established because of the patient's critical condition.

Roberts *et al.* (3) reported a necropsy study of 196 patients with malignant lymphoma and found cardiac involvement in 48 patients. Cardiac infiltration was detected in 16% of the patients with Hodgkin's disease and 25% of the patients with non-Hodgkin's lymphoma. Of these 48 patients, lymphoma was identified grossly in the heart in 27 cases, but found only by microscopic studies in 21 cases (3). There was no tumor or mass in the heart or pericardium in the present case.

The most frequent electrocardiographic disturbance studied by Roberts (3) was sinus tachycardia, alterations in the ST segment or T wave, or both. These are not specific findings. McDonnel (4) also reported that electrocardiograms and thallium im-

aging were not effective screening tools for cardiac metastasis of malignant lymphoma.

The present case is considered to be rare and especially interesting, because complete heart block was the first and only manifestation of malignant lymphoma (5). In this patient, the electrocardiogram showed complete heart block with a normal QRS interval. This suggested infiltration of the atrioventricular node and the bundle of His by lymphoma cells, which caused the conduction disturbance.

Involvement of the heart by malignant lymphoma should be considered in patients with complete heart block and high fever refractory to antibiotics and steroids where no other cause can be detected.

References

1. Goudie RB: Secondary tumors of the heart and pericardium. *Br Heart J* (1955) 17, 183-188.
2. Young JM and Goldman IR: Tumor metastasis to the heart. *Circulation* (1954) 9, 220-229.
3. Roberts WC, Glancy DL and DeVita VT: Heart in malignant lymphoma (Hodgkin's disease, lymphosarcoma, reticulum cell sarcoma and mycosis fungoides): a study of 196 autopsy cases. *J Cardiol* (1968) 22, 85-107.
4. McDonnel PJ, Mann RB and Bulkley BH: Involvement of the heart by malignant lymphoma: a clinicopathologic study. *Cancer* (1982) 49, 944-951.
5. Goggio AF, Harkness JT and Palmer WS: Stokes-Adams syndrome in Hodgkin's granuloma. *J Am Med Assoc* (1961) 176, 687-689.

Received May 24, 1988; accepted September 6, 1988