

Acta Medica Okayama

Volume 25, Issue 6

1971

Article 3

OCTOBER 1971

Intracranial transplantation of the tumor induced by adenovirus type 12 in Syrian hamster—an experimental brain tumor model

Kazuo Tabuchi*

*Okayama University,

Copyright ©1999 OKAYAMA UNIVERSITY MEDICAL SCHOOL. All rights reserved.

Intracranial transplantation of the tumor induced by adenovirus type 12 in Syrian hamster—an experimental brain tumor model*

Kazuo Tabuchi

Abstract

A method of intracranial transplantation of the tumor induced by adenovirus type 12 in syrian hamster has been described. The incidence of intracranial tumor development was 86 (90.5 %) out of 95 animals and the average survival time and tumor size at death were 15.1 days and 4.1 mm in diameter respectively. The consistency of the days of death after intracranial transplantation of the tumor was remarkable. The transplanted tumors developed preferentially at the site of implantation and tumor cell seeding and tumor growing took place rarely along the ventricular system. Glial or lymphoid cell response to the tumor was not observed at any stage after transplantation in surrounding cerebral tissues of the animals. Histomorphologically, no elementary differences were observed between intracranially transplanted tumors and serially transplanted subcutaneous tumors. These facts permit the system to be applied to an experimental brain tumor model as large-scale testing.

Acta Med. Okayama 25, 605—613 (1971)

**INTRACRANIAL TRANSPLANTATION OF THE TUMOR
INDUCED BY ADENOVIRUS TYPE 12 IN SYRIAN HAMSTER
— AN EXPERIMENTAL BRAIN TUMOR MODEL —**

Kazuo TABUCHI

*Department of Neurological Surgery, Okayama University Medical School, Okayama, Japan
(Director: Prof. Akira Nishimoto)*

Received for publication, Oct. 1, 1971

Many agents, including oncogenic viruses, chemical carcinogens and irradiation are being used to induce an experimental brain tumor in laboratory animals (1-18) and also intracranial transplantation of various tumors induced by chemical carcinogens is attempted by many investigators (5, 19-22). There is, however, no attempt made on intracranial transplantation of tumors induced by oncogenic viruses. Since the report by TRENTIN *et al.* (23) on adenovirus type 12 which induces tumor in newborn hamsters, several opinions of its cellular origin have been advocated (23-28), and OGAWA *et al.* suggested (29-31) that the tumor is of undifferentiated neuroectodermal origin.

The present report deals with our method of making an experimental brain tumor model in syrian hamsters by intracranial transplantation of the tumor induced by adenovirus type 12.

MATERIALS AND METHODS

Animals: Syrian golden hamsters (*Mesocricetus auratus*) commercially available in Japan were used. The animals used for the virus inoculation were less than 24 hours old.

Virus: Adenovirus type 12, prototype strain Huie, was obtained by the courtesy of Dr Y. YABE from the Cancer Institute of Okayama University Medical School.

Tumor: Adenovirus type 12-induced tumors were obtained by subcutaneous inoculation of newborn hamsters with 0.1 ml of adenovirus type 12 of 10^2 50 TCID $_{50}$ /0.1 ml. Typical adenovirus type 12-induced tumors appeared 6 to 8 weeks after virus inoculation as reported by many investigators (25, 27, 30).

Transplantation: The necrotic material and connective tissue capsule were removed from the tumor, and the remainder of the tumor tissue was cut into 1 cu mm pieces in phosphate buffered saline (pH 7.2). Each piece was then placed in a trocar lumen with the tip of No. 21 by sucking the tumor fragment, then the trocar with a piece of tumor ready for implantation was inserted into the

hamster's cerebral cortex by removing a 2×2 mm piece of calvarium and dura over the left frontoparietal region of hamsters five to six-week old, weighing 60 to 70 g under Nembutal anesthesia, and intracranial implantation was accomplished aseptically by pushing the trocar content with the stylet.

In a similar manner, a tumor fragment was placed in the subcutaneous tissue of the flank of young adult hamsters for tumor maintenance, but in this instance, a No. 13 trocar containing tumor fragment was used for implantation.

The tumor so induced was transplanted successively over 30 generations and the samples of each tumor were fixed and stained with Hematoxylin and Eosin (H. E.) at regular intervals, and were examined for histological stability. In a series of the experiments, some animals were also sacrificed every other day after transplantation to observe the course of tumor growth and development in the intracerebral site.

Preparation of tissue sections: The hamster brains with tumor were fixed in 10% neutral formalin and embedded in paraffin, and with some of them, serial sections of the whole brain were prepared mostly on the frontal plane. The sections were stained with H. E. and some of sections with phosphotungstic acid-hematoxylin (PTAH).

RESULTS

Clinical course of the tumor bearing animals: After tumor implantation the animals recovered from the anesthesia and resumed their routine activity in the cage within 6 hours. No pathological signs following tumor implantation were seen until approximately 5 days prior to death. The animals which developed intracranial tumor at first showed general malaise and remarkable ventriflexion with gradual loss of weight, and finally they became languid and cachexic. All of these signs were not necessarily present prior to death.

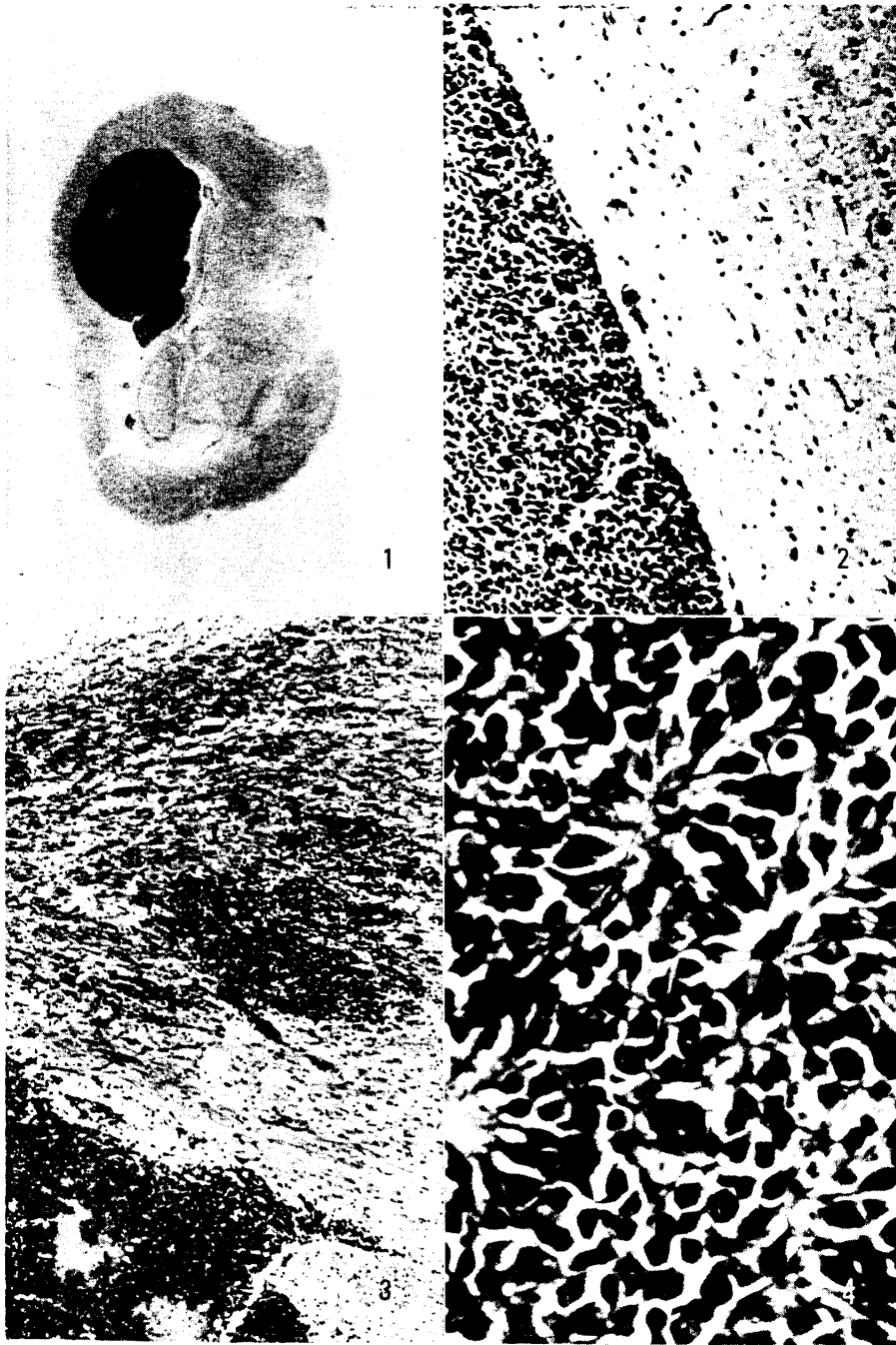
Distribution, growth and spread of tumor: The growth of intracranially transplanted tumor was followed serially. Early in the course of the transplantation, the tumor cells proliferated at the site of implantation and eventually occupied most of the left cerebral hemisphere of the animal brain (Fig. 1). The tumor mass occasionally grew out through the cranial defect as a narrow stalk of cells which then produced a dome-shaped subcutaneous tumor nodule. Tumor cell seeding and tumor growth take

Fig. 1. Whole section of hamster brain bearing growing transplant of adenovirus type 12-induced tumor H. E., × 5.5

Fig. 2. The tumor is clearly demarcated from the surrounding cerebral tissue in which the edematous change can be observed H. E., × 100

Fig. 3. Invasion of tumor cells into the cerebral tissue H. E., × 40

Fig. 4. Characteristic cell arrangement of the adenovirus type 12-induced tumor H. E., × 400



place rarely along the ventricular system in the brain. None of the tumors made extracranial metastasis as observed macroscopically by autopsies. No increase in the size of the skull was seen in animals in spite of the rapid growth of tumor. Usually, the growth of the tumor was expansive and the tumor was demarcated clearly from the surrounding cerebral tissues in which the edematous changes could be observed (Fig. 2), but partial invasion of tumor cells into the cerebral tissue was observed (Fig. 3). Neither glial nor lymphoid cell responses to the tumor were observed in the surrounding cerebral tissue at any stage after the tumor implantation.

Histomorphological observation: Histomorphologically, the serially transplanted subcutaneous tumors were almost the same, and also no difference was observed between intracranially transplanted tumors and serially transplanted subcutaneous tumors. The cell arrangement was mostly irregular, but some parts of the tumor showed the identical characteristic cell arrangement of the tumor induced by adenovirus type 12 as described precisely by OGAWA, *et al.* (31). As shown in Fig. 4, small spindle shaped cells were attached to the stroma with fine protoplasmic process and in some areas they showed palisade arrangement, pseudorosette or small rosette-like structure. Furthermore, anaplastic bizarre giant cells often appeared. Some mitotic figures were also observable in the tumor and occasionally the tumor tissue showed some tiny necrotic areas according to the stage of the tumor growth.

Incidence of tumor development: The incidence of tumor development in animals of intracranial implantation was 86 (90.5%) out of 95 animals.

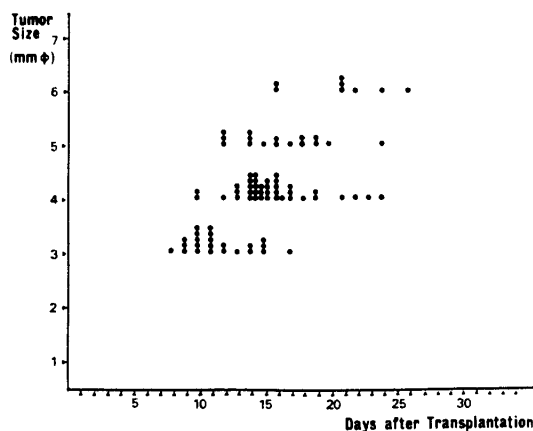


Fig. 5. The correlation between the size of tumor and the survival time of each animal at death

Only 9 (9.5%) out of the 95 animals survived longer than 60 days after the transplantation, which were considered to be of failure of tumor development and no tumor was found in the brain of 4 animals of those sacrificed on the 65th day after implantation.

Correlation between the size of the tumor and the survival time of the animals: The growth of the intracranially transplanted tumor was rapid, and the tumor bearing animals rarely survived more than 3 weeks after transplantation. The average survival time was 15.1 days after transplantation. In these animals, the size of tumors at death ranged from 3-6 mm (average 4.1 mm in diameter). Fig. 5 shows the correlation between the size of tumor and the survival time of each animal at death.

DISCUSSION

For making experimental brain tumors, many chemical carcinogens and viruses are applied to the laboratory animals (3), and also the successful transplantation of chemically induced tumors to the brain of laboratory animals has been reported (5, 19-22). Transplantation of human brain tumors to the brain of laboratory animals was also attempted by many investigators (32-34).

However, there has been no experimental report about the intracranial transplantation of virus-induced tumors to the brain of laboratory animals except for one report by BERMAN which was not a histomorphological but an immunological study (35). In the present investigation for intracranial transplantation of the adenovirus type 12-induced tumor, it was of interest to know that the tumor mass developed preferentially at the site of implantation in the brain of animals, and the growth was expansive.

On the other hand, it was reported by OGAWA *et al.* (29) that the tumors induced by adenovirus type 12 in the central nervous system of newborn hamsters (incidence being 37.2%) were observed to develop in various places of the brain, such as in the subependymal region of ventricles of the brain and central canal of the spinal cord, and in the meninges. These facts show that the site of tumor development is more localized and consistent with the site of implantation in the transplanted tumors. The use of the intracranially transplanted tumor induced by adenovirus type 12 as an experimental brain tumor model is subject to some criticism. First, the tumor genesis is controversial among many investigators (24-27), but many endeavors were done by OGAWA *et al.* (29-31) to search the origin of the tumor cells induced by adenovirus type

12, and they suggested that histologically, the tumor possessed the characteristics of undifferentiated neuroectodermal tumors. Histomorphologically, there are no essential differences between intracranially and subcutaneously induced tumors. The multifarious appearance of histological pattern which seems to be a marked characteristic of this tumor, may be due to not only immature tumor, but also mixed composition of several groups of different cell types and, furthermore, of many bizarre giant cells. Purification of tumor cells was not observed by intracranial transplantations or by serial subcutaneous passages. Secondly, the implantation procedure may be not precise enough and non-quantitative. To be exact, the angles of needle placement of tumor implantation may not be constant from animal to animal. The site of development of transplanted tumor in the animal brain is, however, localized and consistent with the site of implantation and more than 90 % of the inoculated animals died within a consistent time range. From these facts, the system of transplantation can be applied to an experimental brain tumor model as large-scale testing.

As pointed out by GREENE (36), one of the major disadvantages of employing the brain as a site for tumor implantation is the inability of the investigator to see or to palpate the growing transplanted tumor. Neurological signs suggestive of intracranial growth do not become apparent until shortly before death, and there is nothing in the animal behavior to indicate the presence or absence of tumor growth. It was described by SMITH *et al.* (37) that tumor isografts to mouse brain elicited a small cell infiltration which dissipated by 16 days, leaving a flourishing tumor, and migration of large mononuclear cells from the blood stream into cerebral tissue surrounding the tumor was observed. Some of these cells were monocytes, many of them were apparently medium-large lymphocytes. From a more particular point of view, it was interesting in the author's study that neither glial nor lymphoid cell response to the transplants was observed in surrounding cerebral tissue, and this fact may be explained by immunological properties of the tumor or the brain (35, 38). There was no evidence of inflammatory reaction in adjacent cerebral tissues, and the tumor was abundantly supplied with thin-walled blood vessels. Approximately, the incidence of tumor take in the cerebral tissue was the same as that obtained in the subcutaneous transplantation of the tumor (39). As the tumors grow to larger size, they are always medullary with minimum of connective tissue stroma, representing similar findings to those in almost pure culture, and offer an unique material for model of experimental brain tumor.

There are two possibilities concerned with failure of tumor takes, one may be due to tumor-host relationship of individual animals, and the other, due to lack of enough tumor cells to grow in the transplanted site.

Although the tumors were histologically the same, they may differ in their growth characteristics. In the individual animals, the range of days of death may be explained by the variability in the transplantation technique, by the quantity of tumor implanted, by the precise location of the tumor, and by the external decompression through the trephine hole. Also, the neurological deficits produced and the coincident alteration in the functional state of the animals, such as feeding, drinking, and ambulating activities, may influence the time of death. In spite of these variables, the consistency of the days of death after transplantation was remarkable.

CONCLUSION

A method of intracranial transplantation of the tumor induced by adenovirus type 12 in syrian hamster has been described. The incidence of intracranial tumor development was 86 (90.5%) out of 95 animals and the average survival time and tumor size at death were 15.1 days and 4.1 mm in diameter respectively. The consistency of the days of death after intracranial transplantation of the tumor was remarkable. The transplanted tumors developed preferentially at the site of implantation and tumor cell seeding and tumor growing took place rarely along the ventricular system. Glial or lymphoid cell response to the tumor was not observed at any stage after transplantation in surrounding cerebral tissues of the animals.

Histomorphologically, no elementary differences were observed between intracranially transplanted tumors and serially transplanted subcutaneous tumors.

These facts permit the system to be applied to an experimental brain tumor model as large-scale testing.

ACKNOWLEDGEMENT

I wish to express my thanks to Prof. AKIRA NISHIMOTO for his valuable suggestions and guidance. Thanks are also due to Prof. KATSUO OJAWA for helpful advice, to Prof. YOSHIRO YABE for the supply of the virus for this study and to the staff of the Department of Neurological Surgery for much assistance.

REFERENCES

1. BIGNER, D. D., ODOM, G. L., MAHALEY, M. S. Jr. and DAY, E. D.: Brain tumors induced in dogs by the Schmidt-Ruppin strain of Rous sarcoma virus. *J. Neuropath. Exp. Neurol.* **28**, 648, 1969
2. DUFFELL, D., HINZ, R. and NELSON, E.: Neoplasms in hamsters induced by simian virus 40. *Am. J. Path.* **45**, 59, 1964
3. GROVE, A. S. Jr., DI CHIRO, G. and RABOTTI, G. F.: Experimental brain tumors, with a report of those induced in dogs by Rous sarcoma virus. *J. Neurosurg.* **26**, 465, 1967
4. HOPEWELL, J. W. and WRIGHT, E. A.: The importance of implantation site in cerebral carcinogenesis in rats. *Cancer Res.* **29**, 1927, 1969
5. KAWAI, S.: Experimental studies of brain tumor. *Tr. Soc. Path. Jap.* **52**, 59, 1963
6. KENT, S. P. and PICKERING, J. E.: Neoplasms in monkeys spontaneous and irradiation induced. *Cancer* **11**, 138, 1956
7. KIRSCHTEIN, R. L.: Ependymomas produced after intracerebral inoculation of SV 40 into new-born hamsters. *Nature* **195**, 299, 1962
8. PEERS, J. H.: The response of the central nervous system to the application of carcinogenic hydrocarbons. I. Dibenzanthracene. *Am. J. Path.* **15**, 261, 1939
9. PEERS, J. H.: The response of the central nervous system to the application of carcinogenic hydrocarbons, II. Methylcholanthrene. *Am. J. Path.* **16**, 799, 1940
10. PERESE, D. M. and MOORE, G. E.: Method of induction and histogenesis of experimental brain tumors. *J. Neurosurg.* **17**, 677, 1960
11. RABOTTI, G. F., GROVE, A. S., SELLERS, R. L. and ANDERSON, W. R.: Induction of multiple brain tumors (gliomata and leptomeningeal sarcomata) in dogs by Rous sarcoma virus. *Nature* **209**, 884, 1966
12. RAPP, F., PAULUZZI, S., WALTZ, T. A., BURDINE, J. A. Jr., MATSEN, F. A. III. and LEVY, B.: Induction of brain tumors in new born hamsters by simian adenovirus SA7. *Cancer Res.* **29**, 1173, 1969
13. SELIGMAN, A. M. and SHEAR, M. J.: Studies in Carcinogenesis, VIII. Experimental production of brain tumors in mice with methylcholanthrene. *Am. J. Cancer* **37**, 364, 1939
14. WECHSLER, W., KLEIHUES, P., MATSUMOTO, S., ZÜLCH, K. J., IVANKOVIC, S., PREUSSMANN, R. and DRUCKREY, H.: Pathology of experimental neurogenic tumors chemically induced during prenatal and postnatal life. *Ann. N. Y. Acad. Sci.* **360**, 1969
15. ZIMMERMAN, H. M. and ARNOLD, H.: Experimental brain tumors, I. Tumors produced with methylcholanthrene. *Cancer Res.* **1**, 919, 1941
16. ZIMMERMAN, H. M. and ARNOLD, H.: Experimental brain tumors, II. Tumors produced with benzpyrene. *Am. J. Path.* **19**, 939, 1943
17. ZIMMERMAN, H. M. and ARNOLD, H.: Experimental brain tumors, IV. The incidence in different strains of mice. *Cancer Res.* **4**, 98, 1944
18. ZIMMERMAN, H. M.: Experimental brain tumors. *Brain and Nerve* **14**, 637, 1962
19. AUSMAN, J. I., SHAPIRO, W. R. and RALL, D. P.: Studies on the chemotherapy of experimental brain tumors: Development of an experimental model. *Cancer Res.* **30**, 2394, 1970
20. NETSKY, M. G.: Experimental induction and transplantation of brain tumors in animals. *Acta Neurochir.* **10** (Suppl.), 46, 1964
21. ROSSO, R., PALMA, V. and GARATTINI, S.: A model of a cerebral tumor for studies in cancer chemotherapy. *Experientia* **22**, **1**, 62, 1966
22. ZIMMERMAN, H. M. and MAIER, N.: The transplantation of experimentally induced brain tumors. *Am. J. Path.* **25**, 801, 1949

23. TRENTIN, J. J., YABE, Y. and TAYLOR, G.: The quest for human cancer viruses. *Science* **137**, 835, 1962
24. CHINO, F., TSURUHARA, T. and EGASHIRA, Y.: Pathological studies on the oncogenesis of adenovirus type 12 in hamsters. *Japan J. Med. Sci. Biol.* **20**, 483, 1967
25. HUEBNER, R. J., ROWE, W. P. and LANE, W. T.: Oncogenic effects in hamsters of human adenovirus type 12 and 18. *Proc. Nat. Acad. Sci.* **40**, 2051, 1962
26. NEIDERS, M. E., WEISS, L. and YOHAN, D. S.: A morphologic comparison of tumors produced by type 12 adenovirus and by the HA-12-IT line of adeno-12 tumor cells. *Cancer Res.* **28**, 577, 1968
27. PEREIRA, M. S. and MACCALLUM, F. O.: Infection with adenovirus type 12. *Lancet* **7326**, 198, 1964
28. RABSON, A. S., KRISCHSTEIN, R. L. and PAUL, F. J.: Tumors produced by adenovirus 12 in mastomys and mice. *J. Nat. Can. Inst.* **32**, 77, 1964
29. OGAWA, K., HAMAYA, K., FUJII, Y., MATSUURA, K. and ENDO, T.: Tumor induction by adenovirus 12 and its target cells in the central nervous system. *Gann* **60**, 383, 1969
30. OGAWA, K., TSUTSUMI, A., IWATA, K., FUJII, Y., OHMORI, M., HAYAMA, K. and YABE, Y.: Pathohistological study on the tumor development induced by adenovirus type 12, especially on the mother cell of the tumor. *Igaku-no-Ayumi* **53**, 120, 1965
31. OGAWA, K., TSUTSUMI, A., IWATA, K., FUJII, Y., OHMORI, M., TAGUCHI, K. and YABE, Y.: Histogenesis of malignant neoplasm induced by adenovirus type 12. *Gann* **57**, 43, 1966
32. GREENE, H. S. N.: The transplantation of human brain tumors to the brains of laboratory animals. *Cancer Res.* **13**, 422, 1953
33. MIYAWAKI, H. and ISHII, S.: The heterologous intracerebral transplantation of human brain tumors. *Arch. Path.* **70**, 508, 1960
34. SCHMIDT, H.: Wachstum und Ausbreitung intracerebral transplantiertes Geschwülste. *Vern. Deutsch Ges. Path.* **51**, 356, 1967
35. BERMAN, L. D.: On the nature of transplantation immunity in the adenovirus tumor system. *J. Exp. Med.* **125**, 983, 1967
36. GREENE, H. S. N.: The transplantation of tumors to the brains of heterologous species. *Cancer Res.* **11**, 529, 1951
37. SMITH, C. W. and WALKER, B. E.: Glial and lymphoid cell response to tumor implantation in mouse brain. *Texas Reports on Biology and Medicine* **254**, 585, 1967
38. SCHEINBERG, L. C., EDELMAN, F. L. and LEVY, W. A.: Is the brain "an immunologically privileged site?" *Arch. Neurol.* **11**, 248, 1964
39. FUJITA, H.: Successive transplantation of adenovirus type 12 induced tumor. *J. Karyopath.* **12**, 3, 9, 1969