

Acta Medica Okayama

Volume 47, Issue 4

1993

Article 11

AUGUST 1993

Disappearance of pulmonary metastases by OK-432 treatment in a case of hepatocellular carcinoma.

Naoki Hino, *Okayama University*
Toshihiro Higashi, *Okayama University*
Tooru Ueki, *Okayama University*
Harushige Nakatsukasa, *Okayama University*
Souhei Ooguchi, *Okayama University*
Kouzou Ashida, *Okayama University*
Kouzou Fujio, *Okayama University*
Akinobu Takaki, *Okayama University*
Taiji Yonei, *Okayama University*
Toshimi Hasui, *Okayama University*
Hideyuki Tsuji, *Okayama University*
Takao Tsuji, *Okayama University*

Disappearance of pulmonary metastases by OK-432 treatment in a case of hepatocellular carcinoma.*

Naoki Hino, Toshihiro Higashi, Tooru Ueki, Harushige Nakatsukasa, Souhei Ooguchi, Kouzou Ashida, Kouzou Fujio, Akinobu Takaki, Taiji Yonei, Toshimi Hasui, Hideyuki Tsuji, and Takao Tsuji

Abstract

We report here a case of hepatocellular carcinoma (HCC) with multiple lung metastases, which were disappeared by treatment of OK-432. The patient was a 65-year-old man and was diagnosed in 1986 with a small (17 x 11 mm) HCC in the anterior-superior segment of the liver. A part of the right hepatic lobe including the tumor was surgically removed, and transarterial injections of adriamycin (10 mg/week) and subcutaneous injections of OK-432 (10 KE/week) were given. Two and a half years later, recurrence of HCC in the liver and its invasion to vena cava inferior (IVC) were found. OK-432 administration was then stopped and percutaneous ethanol injection therapy (PEIT) was performed 10 times. Six months later, the PEIT was effective and the liver tumor with IVC invasion diminished. However, multiple lung metastases were visible on roentgenograms of the chest, and serum alphafetoprotein (AFP) concentration increased to 50,000 ng/ml. The OK-432 treatment resumed. After 6 months of OK-432 treatment, the multiple lung metastases were disappeared and the serum AFP level decreased to 100 ng/ml. At present, the patient is surviving without any sign of recurrence in either the liver or the lung. The clinical course of this case suggests that OK-432 might have effectively treated lung metastases of HCC, although the exact mechanisms are at present unclear.

KEYWORDS: hepatocellular carcinoma, OK-432, pulmonary metastasis

*PMID: 7692705 [PubMed - indexed for MEDLINE]

Copyright (C) OKAYAMA UNIVERSITY MEDICAL SCHOOL

Disappearance of Pulmonary Metastases by OK-432 Treatment in a Case of Hepatocellular Carcinoma

Naoki Hino, Toshihiro Higashi, Tooru Ueki, Harushige Nakatsukasa, Souhei Ooguchi, Kouzou Ashida, Kouzou Fujio, Akinobu Takaki, Taiji Yonei, Toshimi Hasui, Hideyuki Tsuji and Takao Tsuji

First Department of Internal Medicine, Okayama University Medical School, Okayama 700, Japan

We report here a case of hepatocellular carcinoma (HCC) with multiple lung metastases, which were disappeared by treatment of OK-432. The patient was a 65-year-old man and was diagnosed in 1986 with a small (17 × 11mm) HCC in the anterior-superior segment of the liver. A part of the right hepatic lobe including the tumor was surgically removed, and transarterial injections of adriamycin (10mg/week) and subcutaneous injections of OK-432 (10KE/week) were given. Two and a half years later, recurrence of HCC in the liver and its invasion to vena cava inferior (IVC) were found. OK-432 administration was then stopped and percutaneous ethanol injection therapy (PEIT) was performed 10 times. Six months later, the PEIT was effective and the liver tumor with IVC invasion diminished. However, multiple lung metastases were visible on roentgenograms of the chest, and serum alphafetoprotein (AFP) concentration increased to 50,000ng/ml. The OK-432 treatment resumed. After 6 months of OK-432 treatment, the multiple lung metastases were disappeared and the serum AFP level decreased to 100ng/ml. At present, the patient is surviving without any sign of recurrence in either the liver or the lung. The clinical course of this case suggests that OK-432 might have effectively treated lung metastases of HCC, although the exact mechanisms are at present unclear.

Key words : hepatocellular carcinoma, OK-432, pulmonary metastasis

Hepatocellular carcinoma (HCC) is one of the most prevalent malignant tumors in Japan and most cases are resistant to chemotherapy. OK-432 is used clinically as an immunological stimulant, and is reported to activate natural killer (NK) cells, macrophages, lymphocytes and neutrophils which induce various cytokines. It has also been reported that OK-432 increases natural killer (NK) activity and lymphokine-activated killer (LAK) activity (1-5). However, very few cases of HCC have been reported to be effectively treated by OK-432 *per se* (6). Here we report a very interesting case of HCC whose multiple lung metastases disappeared after long-term administration of OK-432.

Case Presentation

The patient, a 65-year-old man, had a history of acute hepatitis in 1971, and rupture of esophageal varices accompanied with liver cirrhosis in October 1982. At that time, he received a blood transfusion, and underwent esophageal transection and splenectomy. In 1986, a small space occupying lesion (SOL) in the anterior-superior segment (S8) of the right hepatic lobe was found by ultrasonic tomography (UST). The patient was then admitted to the First Department of Internal Medicine in the Okayama University Medical School Hospital for further examination and treatment of the liver tumor.

On admission, the patient's height was 162cm, weight was 59.8kg, blood pressure was 100/70mmHg

* To whom correspondence should be addressed.

and pulse rate was 72/min and regular. His consciousness level was clear. Specific signs of chronic liver diseases, palmar erythema, vascular spiders, jaundice, ascites and anemia were not found. Enlargement of the right hepatic lobe was the only abnormal finding on

physical examination.

Laboratory data on admission is shown in Table 1. Serum levels of GOT and GPT were elevated to 87 IU/l and 121 IU/l, respectively. Platelet count of the peripheral blood was 93,000/ μ l. Prothrombin time was prolonged to 14.6 sec. The hepaplastin test was 63 % of the normal control, and the K_{ICG} value was 0.077. Serum alphafetoprotein (AFP) concentration was slightly elevated to 44.0 ng/ml, and antibodies for hepatitis C virus were positive. Clinical diagnosis was liver cirrhosis with a hepatocellular carcinoma 18 × 17 mm in S8 of the liver by abdominal UST, computed tomography (CT) and angiography of the liver. Subsequently, part of the right hepatic lobe that contained the tumor was removed. Histology of the tumor revealed moderately differentiated hepatocellular carcinoma, equivalent to Edmondson-Steiner's grade 2 hepatocellular carcinoma. The clinical course of the case is shown in Fig 1.

Because carcinoma cells were at the surgical margin of the resected liver, transarterial injections of adriamycin (ADM 10 mg/week) to the liver and subcutaneous injections of OK-432 (10 KE/week, 152 weeks) were administered. Two and a half years later, despite these treatments, a recurrence of HCC (38 × 24 mm) was found in the posterior-superior segment (S7) of the liver with

Table 1 Laboratory data on admission in 1986

Hematology		Urinalysis	n.p.
WBC	4500/mm ³	Stool occult blood	(-)
RBC	434 × 10 ⁴ /mm ³	Blood chemistry	
Hb	15.2 g/dl	TP	7.82 g/dl
Ht	45.9 %	Alb	4.09 g/dl
Coagulation		TIT	4.6 MU
PT	14.6 sec	ZTT	12.1 KU
APTT	33.5 sec	T.Bil	0.94 mg/dl
Hpt	63 %	D.Bil	0.43 mg/dl
Fibrinogen	186 mg/dl	GOT	87 IU/l
Bleeding time	3.5 min	GPT	121 IU/l
Clotting time	8.5 min	ALP	31 IU/l
Serology		LAP	59 IU/l
HBsAg	(-)	γ -GTP	19 IU/l
anti-HBs	(-)	CHE	300 IU/l
anti-HCV	n.e.	LDH	355 IU/l
AFP	44.0 ng/ml	T.Cho	199 mg/dl
CEA	2.15 ng/ml	FBS	92 mg/dl
Fe	171 μ g/dl	K _{ICG}	0.007

AFP: α -fetoprotein; n.p.: not particular; n.e.: not examined.

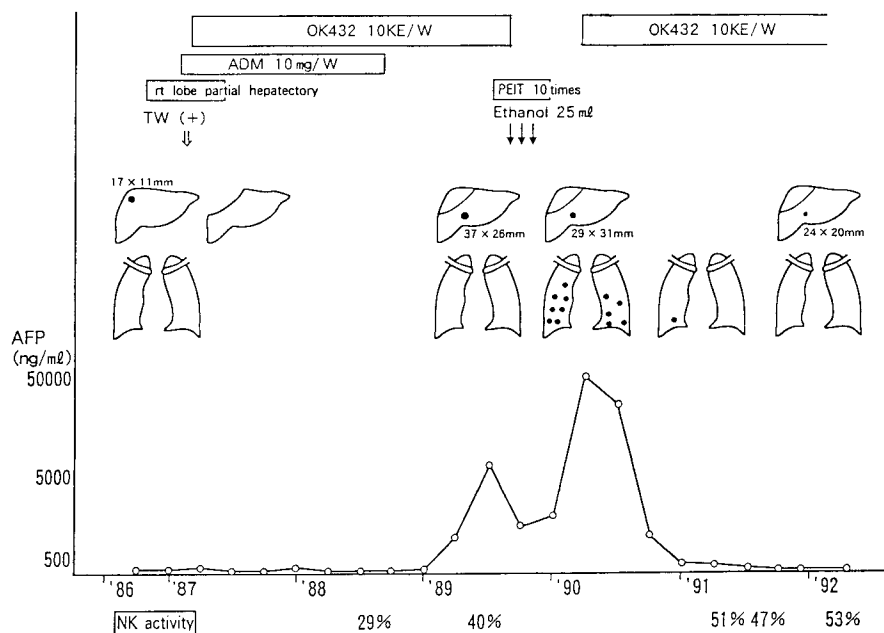


Fig. 1 Clinical course

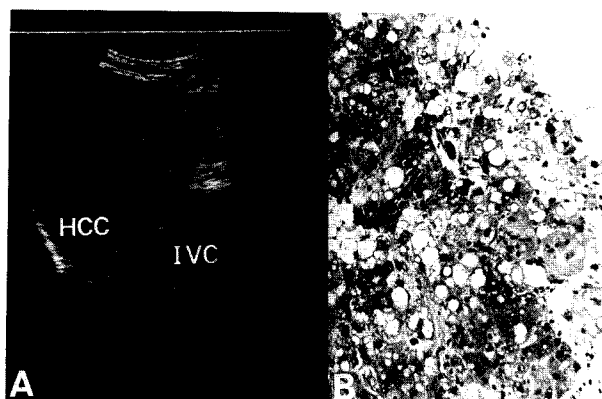


Fig. 2 Abdominal UST showed recurrence of HCC in the posterior-superior segment of the liver with invasion to vena cava inferior (A). US guided biopsy specimen revealed Edmondson-Steiner's grade 3 (B).

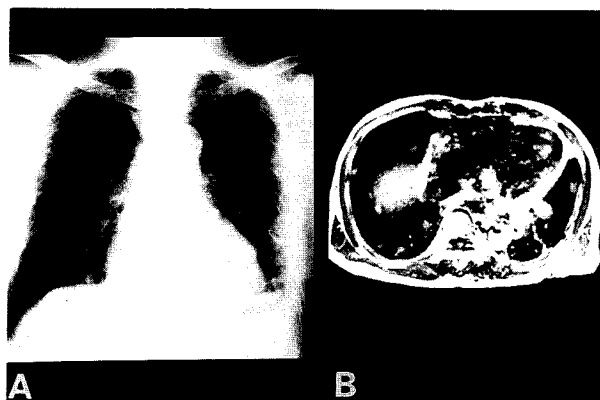


Fig. 3 Chest roentgenogram (A) and MRI (B) examination showed multiple nodular lesions in bilateral lower lung fields.

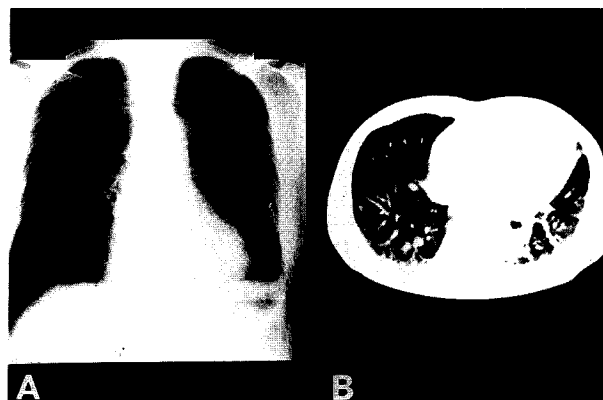


Fig. 4 Absence of multiple lung metastases on chest roentgenogram (A) and CT (B) examination after OK-432 treatment.

invasion to vena cava inferior (Fig. 2a) by abdominal UST examination. Histology of a ultrasonography-guided biopsy specimen revealed Edmondson-Steiner's grade 3 tumor (Fig 2b) that was less differentiated than the original tumor. At that time, natural killer activity was activated to 40 %, but serum AFP concentration elevated to a level of 6,800 ng/ml. The administration of OK-432 was stopped and percutaneous pure (100 %) ethanol injection therapy (PEIT) was applied directly to the tumor 10 times by using a fine needle under a guide of US. This therapy had been recently developed as a special and effective treatment modality for HCC to create coagulation necrosis. The PEIT was effective and the serum AFP concentration decreased to a level of 1,000 ng/ml.

Ten months later, serum AFP level again rose to 50,000 ng/ml and multiple lung metastases of the HCC, particularly in bilateral lower lung fields, were found by roentgenographic and magnetic resonance imaging (MRI) examinations (Fig 3 a, b). Then OK-432 (10 KE/week) without any other anti-cancer drugs was subcutaneously administered again in an attempt to activate immunocompetent cells. After 6 months, a dramatic disappearance of the multiple lesions of pulmonary metastases was seen on roentgenogram and CT images (Fig, 4 a and b), and the serum AFP level had decreased to 100 ng/ml. To date, one year after disappearance of the tumors, no findings of recurrence in either the liver or the lung have been found.

Discussion

Accumulated evidence suggests that OK-432 exerts antitumor effects by inducing various kinds of cytokines (*e.g.*, interferons (2, 3), interleukin-1 and -2 (2, 5)) as well as by activating immunocompetent cells (*e.g.*, NK cells, cytotoxic T lymphocyte (CTL) (2, 4), macrophages and neutrophils (2)) both *in vivo* and *in vitro*. There is a report of reduced cellular immunity (*e.g.*, NK activity) in patients with malignant tumors (7). Interestingly, it has been suggested that OK-432 suppresses both metastasis and recurrence of cancers via activation of NK and LAK cells (2, 8), although the exact mechanisms are still obscure. However, it seems to be difficult to maintain blood concentration of OK-432 *in vivo* to activate effector cells (*e.g.*, NK and LAK cells) by subcutaneous administration of OK-432 (9). It is apparently rare for malignant tumors or their metastatic lesions to decrease in size or

disappear by OK-432 treatment. It has also been reported that in experimental tumors occurrence of metastases and frequency of metastatic nodule formation are diminished by OK-432 treatment, but once metastases are formed OK-432 is no longer effective (10, 11).

In the present case, transarterial injection of adriamycin was added and intermittent subcutaneous administration of OK-432 was continued after the removal of the primary liver cancer. Although NK activity was activated to 40%, HCC with invasion to vena cava inferior recurred. Six months after OK-432 treatment ceased, multiple lung metastases were found. It is possible that both the PEIT to HCC with invasion to vena cava inferior and the end of OK-432 treatment might have increased the chance of lung metastases.

It is unclear why multiple lung metastases disappeared 6 months after the resumption of OK-432 therapy, but HCC recurred during the initial OK-432 treatment. It is possible that an increased immunological response might serve the complete regression of lung metastases, because NK activity was increased to 51% by the readministration of OK-432. It may also be possible that antigenicity of lung metastases might have been changed by means of PEIT and anticancerous drugs and might be different from that of recurrent tumor in the liver. Thereby tumors might respond well to immune cells (*e.g.*, NK and LAK cells). It is desirable to accumulate data on these kinds of cases and to pursue immunological studies to clarify the mechanisms of antitumor effects of OK-432 or other biological response modifiers.

Acknowledgment. This work was supported by grant from the Ministry of Health and Welfare (Ten years strategy for cancer treatment).

References

1. Tanaka T, Shirai R, Watanabe S, Kagawa H, Terada S and Nishioka M: Clinical pathological study of intratumoral injection of drug in patients with hepatocellular carcinoma. *Jpn J Clin Expl Med* (1989) **66**, 136-141 (in Japanese).
2. Hoshino T: Recent progress in biological response modifiers OK-432 (Picibanil): Clinical effect and action mechanism. *Semin Gastroenterol* (1990) **40**, 49-72 (in Japanese).
3. Saito M, Ebina T, Koi M, Yamaguchi T, Kawada Y and Ishida N: Induction of interferon in mouse spleen cells by OK-432, a preparation of streptococcus pyrogens. *Cell Immunol* (1982) **68**, 189-192.
4. Uchida A, Michshe M: *In vitro* augmentation of natural killing activity by OK-432. *Int J Immunol Pharmacol* (1981) **3**, 366-375.
5. Ichimura O, Suzuki S, Saito M, Sugawara Y and Ishida N: Augmentation of interleukin 1 and 2 production by OK-432. *Int J Immunol Pharmacol* (1985) **7**, 263-270.
6. Syubo T, Nakanishi A and Yoshida Y: A case of hepatocellular carcinoma effected by OK432 therapy. *Cancer Clin* (1982) **28**, 1163-1167.
7. Pross HF and Baines MB: Spontaneous human lymphocyte mediated cytotoxicity against tumor target cell: The effect of malignant disease. *Int J Cancer* (1976) **18**, 593-604.
8. Ono J, Sakihama K, Kondo T, and Kozuki T: Clinical immunological studies of OK432 therapy in patients with hepatoma accompanied by liver cirrhosis. *Jpn J Gastroenrerol Surg* (1985) **18**, 2106-2110 (in Japanese)
9. Hosokawa T.: Clinical study on the effect of intertumoral administration of OK432 on breast cancer: Anti-tumor immune response at the site of local injection. *J Jpn Surg Soc* (1991) **92**, 577-586 (in Japanese).
10. Masuyama K, Tazawa K, Kasagi T, Yamasita I, Ishizawa N and Fujimaki M: Inhibition of pulmonary metastasis in mice by OK432-MCT emulsion administrated enterally. *J Jpn Soc Cancer Ther* (1988) **23**, 1300-1306 (in Japanese).
11. Ito H, Nishiguchi I, Shigematsu N, Kuribayashi T and Hashimoto S: Experimental studies on the incidence of metastasis after failure of radiotherapy and the effect of salvage surgery with OK432. *J Jpn Soc Cancer Ther* (1991) **26**, 2420-2426 (in Japanese).

Received January 28, 1993; accepted March 15, 1993.