

Acta Medica Okayama

Volume 63, Issue 4

2009

Article 7

AUGUST 2009

Successful voriconazole treatment of invasive pulmonary aspergillosis in a patient with acute biphenotypic leukemia

Koichiro Kobayashi, *Department of Hematology, Oncology and Respiratory Medicine, Okayama University Graduate School of Medicine, Dentistry and Pharmaceutical Sciences*

Masahiro Ogasawara, *Department of Hematology, Sapporo Hokuyu Hospital*

Yoshio Kiyama, *Department of Hematology, Sapporo Hokuyu Hospital*

Takayoshi Miyazono, *Department of Hematology, Sapporo Hokuyu Hospital*

Kumiko Kagawa, *Department of Hematology, Sapporo Hokuyu Hospital*

Kiyotoshi Imai, *Department of Hematology, Sapporo Hokuyu Hospital*

Teiichi Hirano, *Department of Hematology, Sapporo Hokuyu Hospital*

Naoki Kobayashi, *Department of Hematology, Sapporo Hokuyu Hospital*

Mitsune Tanimoto, *Department of Hematology, Oncology and Respiratory Medicine, Okayama University Graduate School of Medicine, Dentistry and Pharmaceutical Sciences*

Masaharu Kasai, *Department of Hematology, Sapporo Hokuyu Hospital*

Successful voriconazole treatment of invasive pulmonary aspergillosis in a patient with acute biphenotypic leukemia

Koichiro Kobayashi, Masahiro Ogasawara, Yoshio Kiyama, Takayoshi Miyazono, Kumiko Kagawa, Kiyotoshi Imai, Teiichi Hirano, Naoki Kobayashi, Mitsune Tanimoto, and Masaharu Kasai

Abstract

A 23-year old woman with acute biphenotypic leukemia (ABL) complained of chest pain with cough, high fever and hemoptysis during induction chemotherapy, although she had been treated with anti-biotics and micafungin. We made a clinical diagnosis of invasive pulmonary aspergillosis (IPA) based on a consolidation in the right upper lung field on a chest radiograph as well as a high level of serum beta-D-glucan (with no evidence of tuberculosis and candidiasis). We changed her treatment from micafungin to voriconazole. Later, we discovered an air-crescent sign by CT scan that supported the diagnosis of IPA. Following voriconazole treatment, clinical symptoms ceased and abnormal chest shadows improved gradually and concurrently with a recovery of neutrophils. IPA must be considered in immunocompromised patients with pulmonary infiltrates who do not respond to broad-spectrum antibiotics. Serological tests and CT findings can aid in early diagnosis of IPA, which, along with treatment for IPA, will improve clinical outcomes.

KEYWORDS: invasive pulmonary aspergillosis, voriconazole, acute biphenotypic leukemia, febrile neutropenia, β -D-glucan

Case Report

Successful Voriconazole Treatment of Invasive Pulmonary Aspergillosis in a Patient with Acute Biphenotypic Leukemia

Koichiro Kobayashi^{a,b*}, Masahiro Ogasawara^a, Yoshio Kiyama^a, Takayoshi Miyazono^a,
Kumiko Kagawa^a, Kiyotoshi Imai^a, Teiichi Hirano^a, Naoki Kobayashi^a,
Mitsune Tanimoto^b, and Masaharu Kasai^a

^aDepartment of Hematology, Sapporo Hokuyu Hospital, Sapporo 003-0006, Japan, and

^bDepartment of Hematology, Oncology and Respiratory Medicine, Okayama University Graduate School of Medicine,
Dentistry and Pharmaceutical Sciences, Okayama 700-8558, Japan

A 23-year old woman with acute biphenotypic leukemia (ABL) complained of chest pain with cough, high fever and hemoptysis during induction chemotherapy, although she had been treated with antibiotics and micafungin. We made a clinical diagnosis of invasive pulmonary aspergillosis (IPA) based on a consolidation in the right upper lung field on a chest radiograph as well as a high level of serum β -D-glucan (with no evidence of tuberculosis and candidiasis). We changed her treatment from micafungin to voriconazole. Later, we discovered an air-crescent sign by CT scan that supported the diagnosis of IPA. Following voriconazole treatment, clinical symptoms ceased and abnormal chest shadows improved gradually and concurrently with a recovery of neutrophils. IPA must be considered in immunocompromised patients with pulmonary infiltrates who do not respond to broad-spectrum antibiotics. Serological tests and CT findings can aid in early diagnosis of IPA, which, along with treatment for IPA, will improve clinical outcomes.

Key words: invasive pulmonary aspergillosis, voriconazole, acute biphenotypic leukemia, febrile neutropenia, β -D-glucan

Invasive pulmonary aspergillosis (IPA) is a severe complication occurring in patients with neutropenia induced by intensive chemotherapy for hematologic malignancies. The diagnosis of IPA is often delayed, and effective therapeutic agents are limited, resulting in a poor prognosis with a mortality rate of 55% to 80% [1]. Cases of IPA complicating hematologic malignancies have recently increased in number [2]. It has been reported that the incidence of IPA with acute leukemia is 25% to 55% and that

the incidence of IPA after allogenic bone marrow transplantations is 4% to 10%, with a mortality rate of 80% to 90% [3]. Recently, new antifungal agents such as voriconazole (VRCZ) and echinocandins, including caspofungin and micafungin (MCFG), have been clinically evaluated [4, 5]. VRCZ is one of the azoles, a powerful antifungal agent, especially against *Aspergillus* spp. [6]. In western countries, VRCZ is widely used in the second prophylaxis, empirical, or target therapy among patients with hematologic malignancies complicated with febrile neutropenia associated with intensive chemotherapy [6]. However, the efficacy of VRCZ as initial therapy for IPA with neutropenia has not been investigated in Japan. We

Received January 20, 2009; accepted March 27, 2009.

*Corresponding author. Phone:+81-86-235-7226; Fax:+81-86-232-8226
E-mail:kouichiro.kobayashi@mb3.seikyoku.ne.jp (K. Kobayashi)

report, herein, a successful treatment of IPA using VRCZ in a patient with acute biphenotypic leukemia (ABL).

Case Report

In August, 2005 a 23-year-old woman was admitted to our hospital with fever, general fatigue, and anemia. Hematological tests revealed a white blood cell count of $6.8 \times 10^9/L$, with 8% neutrophils and 26% blast cells, and a hemoglobin level of 8.0g/dL. Bone marrow aspiration yielded a nuclear cell count of $395 \times 10^9/L$ with 95.0% blast cells. The blast cells were negative for myeloperoxidase but positive for cytoplasmic CD3 (cyCD3), CD5, CD7, CD13, CD33, CD34, CD117 and HLA-DR. Cytogenetic analysis of a bone marrow specimen revealed an abnormal karyotype in 24 of 24 cells of 46, XX, t(12; 19)(p13; p11), add(1)(p34), del(5)(q22q35), del(7)(q32q34), add(11)(p15), add(16)(p13). Thus, this patient was given a diagnosis of acute biphenotypic leukemia (ABL). Remission-induction chemotherapy, consisting of idarubicin and cytosine arabinoside, was initiated (Fig. 1). For antifungal prophylaxis, fluconazole was administered. On the 16th day of chemotherapy she experienced febrile neutropenia, so ceftazidime and amikacin were administered. Because the high fever continued, micafungin (150mg once a day, drip infusion) was added. Several tests, such as blood

and sputum culture and polymerase chain reaction (PCR) for tuberculosis, were all negative. On the 22nd day of chemotherapy, the patient complained of right chest pain with a cough and hemoptysis. Although the neutrophil count had recovered to $2.0 \times 10^9/L$, she experienced dyspnea and hypoxia (pulse oximeter oxygen saturation: SpO₂ 90% on room air). A chest radiograph revealed patchy opacities and a CT scan revealed a mass-like lesion in the right upper lung field. The level of β -D-glucan (Fungitec G test MK) was elevated (34.9pg/ml), and a serum *Candida*-antigen test was negative. Five days later, a chest x-ray revealed a consolidation (Fig. 2A). We could not perform a transbronchial lung biopsy (TBLB) or a bronchoalveolar lavage (BAL) because the patient was in poor systemic condition and had severe hypoxia. We made a clinical diagnosis of IPA based on our findings thus far. We adjusted her treatment from micafungin to VRCZ, which resulted in an elimination of the clinical symptoms. One week after the initiation of VRCZ treatment, the neutrophil count had fully recovered but CT scan revealed a mass with a cavity surrounded by ground-glass opacity that indicated typical halo and air-crescent signs (Fig. 2B). Three weeks after the start of VRCZ treatment, the patient was switched from drip infusion to oral administration because abnormal chest shadows improved gradually. In September, 2005 bone marrow aspiration findings revealed complete remission. In October, 2005 the

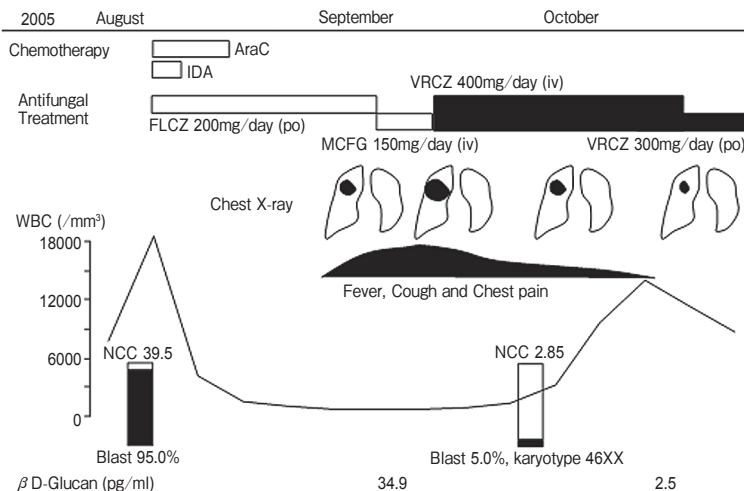


Fig. 1 Clinical course of the patient. AraC indicates cytosine arabinoside; IDA, idarubicin; FLCZ, fluconazole; MCFG, micafungin; VRCZ, voriconazole; NCC, nuclear cell count.

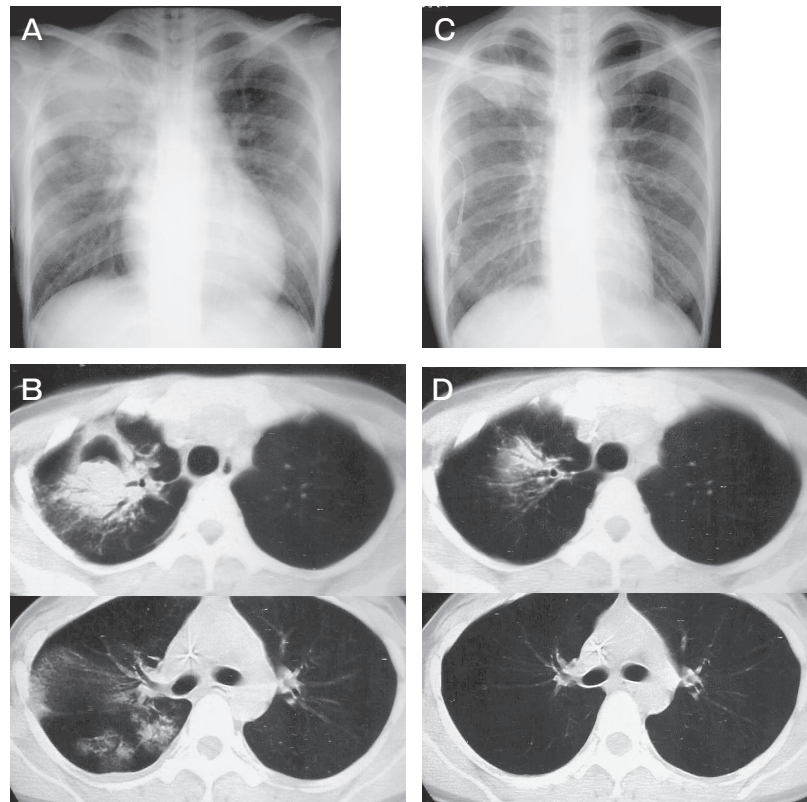


Fig. 2 Chest X-ray and CT evaluation of the patient. **A**, Chest X-ray on September 20, showing pneumonia in the right upper lung; **B**, CT scan of chest demonstrates typical air-crescent signs and many consolidations in the right pulmonary lobe at one week after the start of VRCZ treatment; **C**, Chest X-ray on October 5, showing improvement of pneumonia; **D**, CT scan of chest demonstrates improvement at 3 weeks after the start of VRCZ treatment.

mass with halo and air crescent signs remarkably improved on a chest radiograph and a CT scan (Fig. 2C and 2D). Since then, no recurrence of IPA has been observed during 3 courses of consolidation chemotherapies because oral VRCZ was continued for antifungal prophylaxis.

Discussion

Our case highlights a successful treatment of IPA in an immunocompromised patient with ABL. In many cases, a delayed diagnosis of IPA leads to more severe disease or even death. Despite recent advances in antifungal treatment, clinical outcomes are still generally considered to be inadequate [7] with the best reported response rates in the range of 50–60% [6]. Response to treatment and survival can potentially be improved if specific antifungal treatment for IPA is initiated at an early stage of infection.

However, an early diagnosis of IPA based on histopathological or mycological evidence can be difficult to establish [8]. Sputum cultures are neither sensitive nor specific; positive sputum cultures do not always correlate with invasive disease, and negative sputum cultures are common in patients with proven IPA [9]. Indeed, in another report, a culture of BAL remained negative in 70% of IPA cases with neutropenia [10]. Moreover, in a large number of patients with hematological malignancy who are in poor systemic condition, it is difficult to perform invasive examinations such as TBLB and BAL. Therefore, to make an accurate diagnosis of deep fungal infection, investigative efforts have focused on molecular and serological diagnostic techniques that determine the presence of fungal cell-wall constituents such as galactomannan and β -D-glucan antigens. For diagnosis of invasive aspergillosis in immunocompromised patients, the rates of sensitivity and specificity of serological tests were

70% to 90% and 84% to 86%, respectively [11]. Although β -D-glucan is present in other pathogenic fungi such as *Candida species*, measurement of this antigen in blood may be a useful preliminary screening tool for invasive aspergillosis. Extensive efforts have been made to detect the DNA of the *Aspergillus species*, but a lack of technical standardization and a relatively poor understanding of DNA release and kinetics continue to hamper the broad applicability of this technique [12].

CT scans may be able to detect lung involvement at an early stage of IPA [13]. The halo sign, a macro nodule (>1 cm in diameter) surrounded by a perimeter of ground-glass opacity, is regarded to be an early indicator of IPA [14] and has been incorporated into the inclusion criteria of clinical studies [6]. Systematic CT screening for the halo sign in high-risk patients has been recommended because the initiation of antifungal treatment on the basis of this finding may lead to better outcomes [15]. The present patient was diagnosed with IPA as a clinically documented fungal infection based on a mass in chest CT scans, in addition to high levels of serum β -D-glucan. For early detection of IPA in immunocompromised patients, the use of a combination of blood samples and CT scan appears to be the most promising approach.

For the patient in this study, chest x-rays, CT findings, and high levels of serum β -D-glucan led to a clinical diagnosis of IPA, and VRCZ treatment was effective as an early-presumptive therapy. The key to obtaining a favorable outcome was early diagnosis, a full recovery of neutrophils, and aggressive antifungal treatment with VRCZ or lipid-based amphotericin-B for IPA. Administration of these antifungal agents should be started as a presumptive therapy for IPA if clinical signs, serological results, chest x-rays or CT findings are suggestive of IPA.

In conclusion, IPA should be considered in immunocompromised patients with pulmonary infiltrates who do not respond to broad-spectrum antibiotics. Serological tests and CT findings aid in an early diagnosis of IPA which, along with intensive treatment, will improve clinical outcomes.

References

- Denning DW: Invasive aspergillosis. Clin Infect Dis (1998) 26: 781-803.
- Marr KA, Carter RA, Boeckh M, Martin P and Corey L: Invasive aspergillosis in allogeneic stem cell transplantation recipients: changes in epidemiology and risk factors. Blood (2002) 100: 4358-4366.
- Jantunen E, Anttila VJ and Ruutu T: *Aspergillus* infections in allogeneic stem cell transplant recipients: have we made any progress? Bone Marrow Transplant (2002) 30: 925-929.
- Denning DW: Echinocandin antifungal drugs. Lancet (2003) 362: 1142-1151.
- Ota S, Tanaka J, Kahata K, Toubai T, Kondo K, Mori A, Toyoshima N, Musashi M, Asaka M and Imamura M: Successful micafungin (FK463) treatment of invasive pulmonary aspergillosis in a patient with acute lymphoblastic leukemia in a phase II study. Int J Hematol (2004) 79: 390-393.
- Herbrecht R, Denning DW, Patterson TF, Bennett JE, Greene RE, Oestmann JW, Kern WV, Marr KA, Ribaud P, Lortholary O, Sylvester R, Rubin RH, Wingard JR, Stark P, Durand C, Caillot D, Thiel E, Chandrasekar PH, Hodges MR, Schlamm HT, Troke PF and de Pauw B; Invasive Fungal Infections Group of the European Organisation for Research and Treatment of Cancer and the Global Aspergillus Study Group: Voriconazole versus amphotericin B for primary therapy of invasive aspergillosis. N Engl J Med (2002) 347: 408-415.
- Perfect JR, Cox GM, Lee JY, Kauffman CA, de Repentigny L, Chapman SW, Morrison VA, Pappas P, Hiemenz JW and Stevens DA; Mycoses Study Group: The impact of culture isolation of *Aspergillus species*: a hospital-based survey of aspergillosis. Clin Infect Dis (2001) 33: 1824-1833.
- Reichenberger F, Habicht JM, Gratwohl A and Tamm M: Diagnosis and treatment of invasive pulmonary aspergillosis in neutropenic patients. Eur Respir J (2002) 19: 743-755.
- Horvath JA and Dummer S: The use of respiratory-tract cultures in the diagnosis of invasive pulmonary aspergillosis: Am J Med (1996) 100: 171-178.
- Caillot D, Couaillier JF, Bernard A, Casasnovas O, Denning DW, Mannone L, Lopez J, Couillault G, Piard F, Vagner O and Guy H: Increasing volume and changing characteristics of invasive pulmonary aspergillosis on sequential thoracic computed tomography scans in patients with neutropenia. J Clin Oncol (2001) 19: 253-259.
- Verweij PE, Stynen D, Rijs AJ, de Pauw BE, Hoogkamp-Korstanje JA and Meis JF: Sandwich enzyme-linked immunosorbent assay compared with Pastorex latex agglutination test for diagnosing invasive aspergillosis in immunocompromised patients. J Clin Microbiol (1995) 33: 1912-1914.
- Hope WW, Walsh TJ and Denning DW: Laboratory diagnosis of invasive aspergillosis. Lancet Infect Dis (2005) 5: 609-622.
- Hauggaard A, Ellis M and Ekelund L: Early chest radiography and CT in the diagnosis, management and outcome of invasive pulmonary aspergillosis. Acta Radiol (2002) 43: 292-298.
- Caillot D, Mannone L, Cuisenier B and Couaillier JF: Role of early diagnosis and aggressive surgery in the management of invasive aspergillosis in neutropenic patients. Clin Microbiol Infect (2001) 7: 54-61.
- Greene RE, Schlamm HT, Oestmann JW, Stark P, Durand C, Lortholary O, Wingard JR, Herbrecht R, Ribaud P, Patterson TF, Troke PF, Denning DW, Bennett JE, de Pauw BE and Rubin RH: Imaging findings in acute invasive pulmonary aspergillosis: clinical significance of the halo sign. Clin Infect Dis (2007) 44: 373-379.