

Acta Medica Okayama

Volume 41, Issue 3

1987

Article 3

JUNE 1987

Extra-anatomical bypass formation and exclusion of thoracic aortic aneurysms by “paired clamp method”: the development of hind leg paralysis, the thrombus formation and the pressure ratio between the excluded cavity and the aorta.

Setsuro Imawaki*

*Okayama University,

Copyright ©1999 OKAYAMA UNIVERSITY MEDICAL SCHOOL. All rights reserved.

Extra-anatomical bypass formation and exclusion of thoracic aortic aneurysms by “paired clamp method”: the development of hind leg paralysis, the thrombus formation and the pressure ratio between the excluded cavity and the aorta.*

Setsuro Imawaki

Abstract

The extra-anatomical bypass formation and the exclusion of thoracic aortic aneurysms by the “paired clamp method” applied to the thoracic aorta of mongrel dogs, and the development of hind leg paralysis was studied experimentally in relation to the ratio between the mean excluded cavity pressure and the mean aortic pressure ratio (EA-ratio). The relationship between thrombus formation in the excluded cavity and the EA-ratio was also studied. Animals were divided into 4 groups: Group 1 underwent the cross-clamping of the descending thoracic aorta for 8 min; Group 2 underwent exclusion of the entire thoracic aorta under permanent bypass; Group 3 underwent ligation of 2/3 of the proximal intercostal arteries which branched from the excluded thoracic aorta; and Group 4 underwent division of the excluded thoracic aorta into 3 parts by ligation. No animals in group 1 developed paralysis. When EA-ratios were higher than 0.48, animals in groups 2 and 3 were not paralyzed, whereas all but 1 animals with EA-ratios lower than or equal to 0.48 were paralyzed. There was statistically significant difference between the EA-ratio of the non-paralyzed animals and that of the paralyzed animals in groups 2 and 3. Four out of 5 animals in group 4 were paralyzed. However, there was no statistically significant difference between the EA-ratio in these 4 paralyzed animals and that in the non-paralyzed animals in groups 2 and 3. When the EA-ratio was lower than or equal to 0.59, all but 1 excluded cavities of groups 2 and 3 animals were fully thrombosed 7 or 8 days after the operation. None of these animals showed the aggravation of the paralysis during the observation period and, conversely, the paralysis of almost all animals was ameliorated. These results suggested that the EA-ratio is useful in predicting the development of paralysis and thrombus formation in the excluded cavity after the operation of

*PMID: 3630760 [PubMed - indexed for MEDLINE]

thoracic aortic aneurysms by the "paired clamp method".

KEYWORDS: extra-anatomical bypass, thoracic aortic aneurysm, paired clamp method, paralysis, thrombus formation

Extra-Anatomical Bypass Formation and Exclusion of Thoracic Aortic Aneurysms by "Paired Clamp Method": The Development of Hind Leg Paralysis, the Thrombus Formation and the Pressure Ratio between the Excluded Cavity and the Aorta

Setsuro Imawaki

Second Department of Surgery, Okayama University Medical School, Okayama 700, Japan

The extra-anatomical bypass formation and the exclusion of thoracic aortic aneurysms by the "paired clamp method" applied to the thoracic aorta of mongrel dogs, and the development of hind leg paralysis was studied experimentally in relation to the ratio between the mean excluded cavity pressure and the mean aortic pressure ratio (EA-ratio). The relationship between thrombus formation in the excluded cavity and the EA-ratio was also studied. Animals were divided into 4 groups: Group 1 underwent the cross-clamping of the descending thoracic aorta for 8 min; Group 2 underwent exclusion of the entire thoracic aorta under permanent bypass; Group 3 underwent ligation of 2/3 of the proximal intercostal arteries which branched from the excluded thoracic aorta; and Group 4 underwent division of the excluded thoracic aorta into 3 parts by ligation. No animals in group 1 developed paralysis. When EA-ratios were higher than 0.48, animals in groups 2 and 3 were not paralyzed, whereas all but 1 animals with EA-ratios lower than or equal to 0.48 were paralyzed. There was statistically significant difference between the EA-ratio of the non-paralyzed animals and that of the paralyzed animals in groups 2 and 3. Four out of 5 animals in group 4 were paralyzed. However, there was no statistically significant difference between the EA-ratio in these 4 paralyzed animals and that in the non-paralyzed animals in groups 2 and 3. When the EA-ratio was lower than or equal to 0.59, all but 1 excluded cavities of groups 2 and 3 animals were fully thrombosed 7 or 8 days after the operation. None of these animals showed the aggravation of the paralysis during the observation period and, conversely, the paralysis of almost all animals was ameliorated. These results suggested that the EA-ratio is useful in predicting the development of paralysis and thrombus formation in the excluded cavity after the operation of thoracic aortic aneurysms by the "paired clamp method".

Key words : extra-anatomical bypass, thoracic aortic aneurysm, paired clamp method, paralysis, thrombus formation.

The recent operative treatment for thoracic aortic aneurysms is indwelling of a tubular prosthesis in the aneurysmal lesion (1), but the operation is very invasive and complicated. Carpentier *et al.* (2) developed a new surgical approach, the "flow reversal and thromboexclusion", to DeBakey type III_b aor-

tic dissection. However, the enlargement of excluded aortic aneurysms after the operation by this method has been reported (3). Shimazu *et al.* (4) devised another operative technique, the "paired clamp method", in which the thoracic aortic aneurysm was excluded with paired clamps at the point just

proximal and distal to the aneurysmal lesion. It has been pointed out, however, that there remains the danger of paralysis of the legs after the operation by this method (5). Marked reduction of the blood supply to the lower spinal cord via the excluded cavity, caused by the exclusion of the thoracic aorta, may lead to the development of paralysis. The blood flow volume to the spinal cord via the excluded cavity has been evaluated by measuring the excluded cavity pressure. However, it appears to be more accurate to evaluate the blood flow volume to the spinal cord by the ratio between the mean excluded cavity pressure and the mean aortic pressure (EA-ratio), because the excluded cavity pressure probably changes parallel to the aortic pressure. Besides, the influence of the thrombus formation in the excluded cavity on the development of paralysis has not been clearly resolved. In order to investigate these problems, the development of the paralysis and the thrombus formation in the

excluded cavity were studied in relation to the EA-ratio in mongrel dogs.

Materials and Methods

Twenty-two adult mongrel dogs weighing 6.0 to 12.6 kg (average 9.9 kg) were immobilized with ketamin hydrochloride and anesthetized with pentobarbital sodium. An endotracheal tube was inserted and the animal was ventilated with a respirator using room air.

Animals were divided into 4 groups. All groups underwent left thoracotomies through the 5th and 11th intercostal spaces. Group 1 (5 animals) underwent ligation of the left subclavian artery, 2 proximal pairs of intercostal arteries, Th₁₃ intercostal arteries and L_{1,2} lumbar arteries. The thoracic aorta was cross-clamped for 8 min at the site just distal to the left subclavian artery and at the Th₁₃ site. Group 2 (6 animals) underwent ligation of branches of the thoracic aorta in the same manner as group 1. The thoracic aorta was excluded using paired ligations under permanent bypass from just distal to the left subclavian artery to Th₁₃ site. Group 3 (6 animals) under-

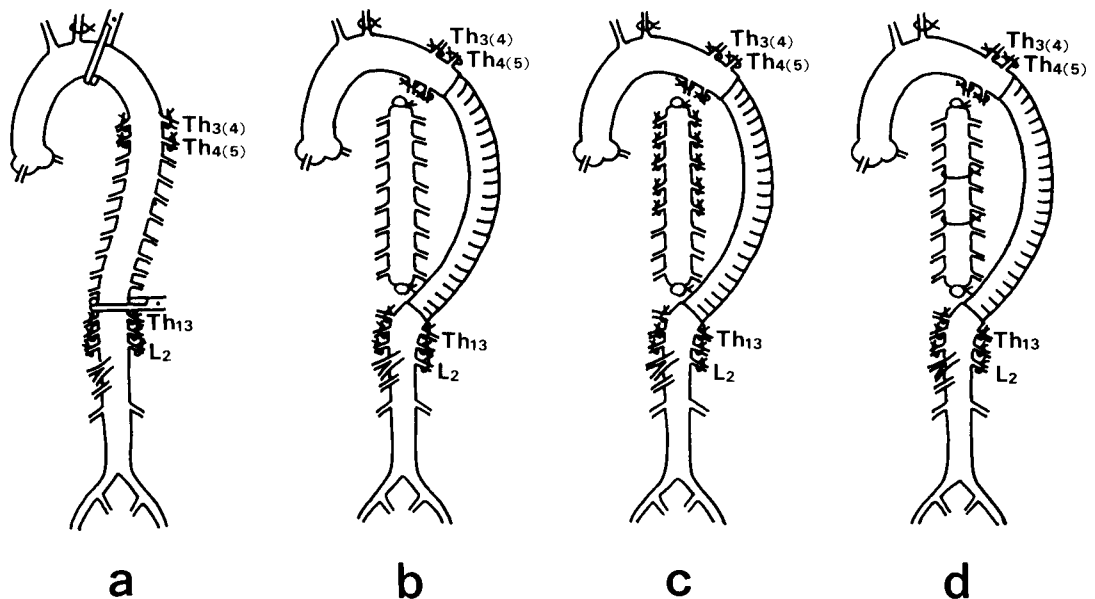


Fig. 1 Schematic illustration of the operative methods. a, (group 1) The descending thoracic aorta was cross-clamped for 8 min. b, (group 2) The thoracic aorta was simply excluded. c, (group 3) The thoracic aorta was excluded and 2/3 of the proximal intercostal arteries were ligatured. d, (group 4) The thoracic aorta was excluded and it was divided into 3 parts by ligation.

went the same procedure as group 2, and ligation of 2/3 of the proximal intercostal arteries from the excluded thoracic aorta. Group 4 (5 animals) underwent the same procedure as group 2, and the excluded thoracic aorta was divided into 3 parts by ligation (Fig. 1).

A ringed composite graft of 8 mm inner diameter at the proximal end and 6 mm at the distal end, was used to bypass the thoracic aorta. While the graft was inserted into the descending thoracic aorta, the aorta was cross-clamped without the use of any shunts. Animals were excluded from the study when the cross-clamping time was longer than 8 minutes, because prolonged cross-clamping of the thoracic aorta directly induce the paralysis as reported by Coles *et al.* and Katz *et al.* (6,7).

Animals were given heparin sodium just before the thoracic aorta was cross-clamped.

In groups 2, 3 and 4, the mean aortic pressure in the graft and the mean pressure in the excluded cavity were measured by the needle puncture method, and then the EA-ratio was calculated.

The motor function of the hind legs was observed daily, and classified into 5 grades, modifying Fride's grading (8): grade 0, normal motor function; grade 1, minimal motor disability in which the hind legs can still be used in walking; grade 2, moderate paraparesis in which standing is accomplished with support of the fore legs but animal can not walk; grade 3, marked paraparesis in which the hind legs can move against gravity but can not be used for standing; grade 4, paraplegia in which there is minimal or no voluntary

movement in hind legs.

Animals were sacrificed around 7 days after the operation. The thrombus formation in the excluded cavity was examined, and the spinal cord (Th₄-Th₁₃, L₁) was carefully removed. The cross sections of some of the removed spinal cords were stained with hematoxylin-eosin and Klüer-Barrera stain, and examined microscopically.

Results were expressed as means \pm standard deviation. Statistical significance was determined by Student's *t* test.

Results

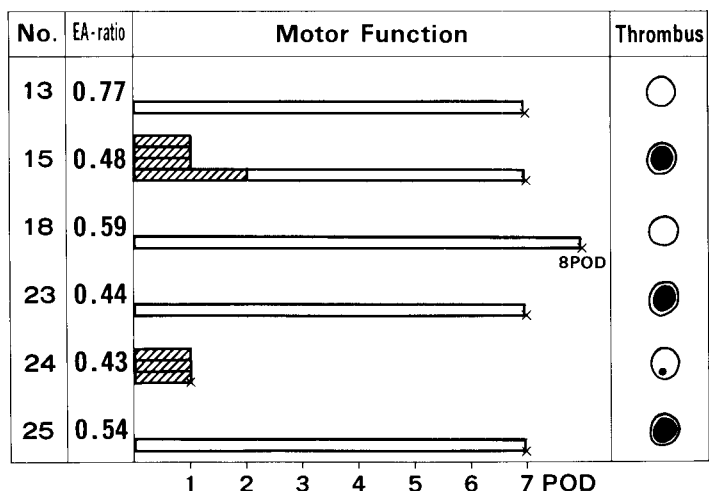
Paralysis, Thrombus Formation and EA-Ratio

Group 1. No animals developed paralysis during the observation period.

Group 2. The aortic cross-clamping time was 5.8 ± 1.7 min. The mean aortic pressure and the mean excluded cavity pressure were 131 ± 19 mmHg and 70 ± 14 mmHg respectively, making EA-ratio 0.54 ± 0.12 . The postoperative course of the animals of this group is summarized in Fig. 2.

Two (Nos. 15 and 24) out of 6 animals developed paralysis with motor disability of grades 4 and 3, respectively. The paraplegia of No. 15 disappeared 3 days after the operation. No. 24 died 2 days after the operation, and no change in the paralysis was

Fig. 2 Postoperative course of group 2. Two out of 6 animals were paralyzed. Obliquely lined bars represent grades of motor disability. Open bars show normal motor function. Nos. 13 and 18 had no thrombus in the excluded cavity. Schematic illustrations of thrombus formation in the excluded cavities are given. EA-ratio: The ratio between the mean excluded cavity pressure and mean aortic pressure. Crosses: operative death or protocol death. POD: postoperative days.



observed. The other animals did not develop paralysis.

Nos. 13 and 18, with EA-ratios of 0.77 and 0.59 respectively, had no thrombi in the excluded cavity. Nos. 15, 23 and 25, with EA-ratios lower than or equal to 0.54, had fully thrombosed excluded cavities. The EA-ratio of No. 24 was the lowest (0.43) in group 2. This animal had a small entire length thrombus in the excluded cavity when it was posthumously examined.

Group 3. The aortic cross-clamping time was 5.2 ± 1.0 min. The mean aortic pressure and the mean excluded cavity pressure were 130 ± 21 mmHg and 64 ± 9 mmHg respectively, making EA-ratio 0.50 ± 0.06 . The postoperative course of the animals of this group is summarized in Fig. 3.

Four (Nos. 14, 26, 27 and 29) out of 6 animals developed paralysis with motor disability of grades 3, 4, 1 and 4, respectively. Nos. 20 and 30 were not paralyzed. The paralysis of No. 14 and 27 disappeared 2 days after the operation. No. 26 died 2 days after the operation, and no change in motor function was observed. No. 29 was still paraplegic when it was sacrificed. The excluded cavity of No. 26 was not thrombosed. The other 5 animals had fully thrombosed

excluded cavities.

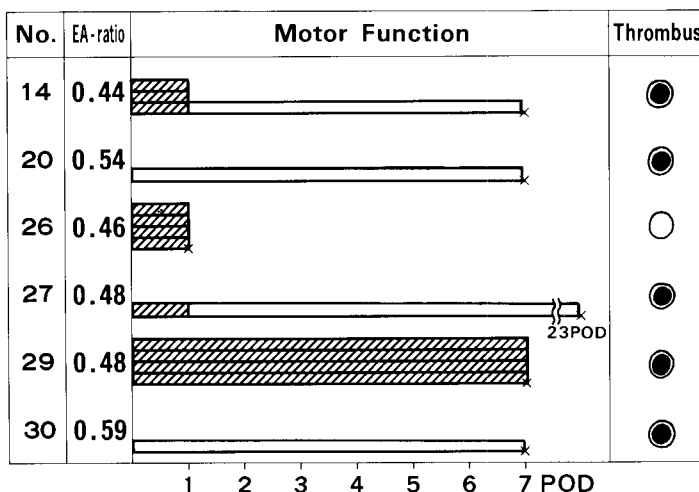
Group 4. The aortic cross-clamping time was 6.8 ± 1.3 min. The mean aortic pressure and the mean excluded cavity pressure measured before the division of the excluded cavity into 3 parts were 135 ± 19 mmHg and 75 ± 12 mmHg respectively, making EA-ratio 0.57 ± 0.06 . The pressure and the EA-ratio of each divided part of the excluded cavity was different. Some divided parts showed very low pressure and very low EA-ratio. The postoperative course of the animals of this group is summarized in Fig. 4.

Four (Nos. 17, 32, 35 and 37) out of 5 animals developed paralysis with motor disability of grades 1, 2, 1 and 4, respectively. No. 39 was not paralyzed. The paralysis of Nos. 17, 32 and 35 disappeared 2 or 4 days after the operation. No. 37 was found to be paraplegic the day after the operation, then improved gradually, but still had grade 2 paralysis when it was sacrificed.

Of 15 divided parts of the excluded cavity, only 1 was not thrombosed (No. 39). The EA-ratio of this non-thrombosed part was relatively high, 0.66.

The differences in the cross-clamping time among groups 2, 3 and 4 were not statistically significant. Fig. 5 shows the cor-

Fig. 3 Postoperative course of group 3. Four out of 6 animals were paralyzed. Obliquely lined bars represent grades of motor disability. Open bars show normal motor function. Five out of 6 excluded cavities were fully thrombosed. Schematic illustrations of thrombus formation in the excluded cavities are given. EA-ratio: The ratio between the mean excluded cavity pressure and mean aortic pressure. Crosses: operative death or protocol death. POD: postoperative days.



relation among the mean aortic pressure, the mean excluded cavity pressure and the EA-ratio of all animals in groups 2, 3 and 4. There was no statistically significant

difference among the parameters of these 3 groups.

Six out of 12 animals in groups 2 and 3, showed paralysis the day after the operation.

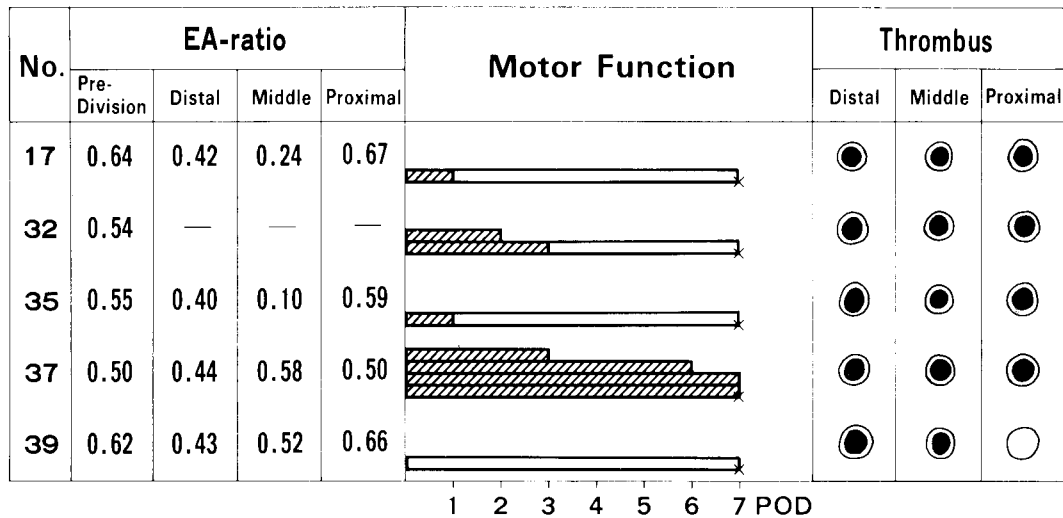


Fig. 4 Postoperative course of group 4. Four out of 5 animals were paralyzed. Obliquely lined bars represent grades of motor disability. Open bars show normal motor function. All but 1 of the excluded parts were fully thrombosed. Schematic illustrations of thrombus formation in the excluded cavities are given. EA-ratio: The ratio between the mean excluded cavity pressure and mean aortic pressure. Crosses: operative death or protocol death. POD: postoperative days.

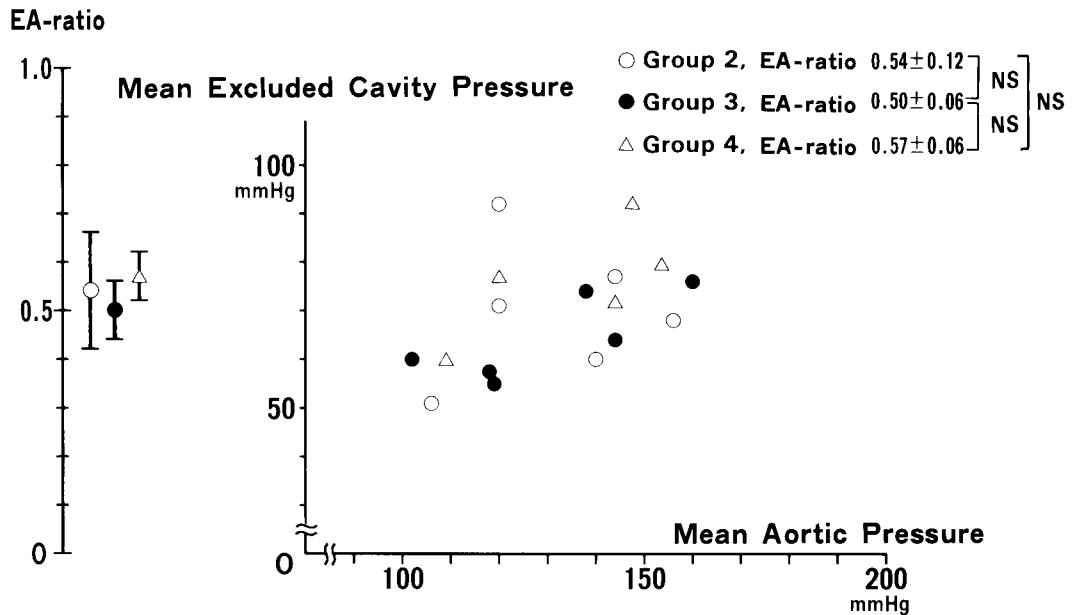


Fig. 5 Correlation among mean aortic pressure, excluded cavity pressure and EA-ratio of groups 2, 3 and 4. These parameters were not statistically different among the 3 groups.

The mean excluded cavity pressure and the EA-ratio of the paralyzed animals were 61 ± 9 mmHg and 0.46 ± 0.02 , respectively. The respective values of the non-paralysed animals were 74 ± 11 mmHg and 0.58 ± 0.10 . The differences between these values were statistically significant ($p < 0.05$) (Fig. 6).

Four out of 5 animals in group 4 were paralyzed after the operation. The mean excluded cavity pressure and EA-ratio of the 4 paralyzed animals (measured before the division of the excluded cavity into 3 parts) were 71 ± 9 mmHg and 0.56 ± 0.05 , respectively. These values were not statistically different from those of the non-paralyzed animals in groups 2 and 3.

Among 9 animals in groups 2 and 3 that were sacrificed 7 or 8 days after the operation, 2 animals showed no thrombus formation in the excluded cavities, and the other animals showed fully thrombosed cavities. The EA-ratio of the 2 non-thrombosed cavities was 0.59 and 0.77, respectively. Among the EA-ratios of the thrombosed cavities,

one was 0.59 and the others were lower than 0.59. Statistical difference between the EA-ratio of the thrombosed cavities and the non-thrombosed cavities was not examined because the number of cases studied was too small (Fig. 7).

Fig. 8 shows the representative, macroscopic findings of the thoracic aorta and grafts. The excluded thoracic aorta is opened longitudinally showing thrombus formation.

Ischemic change of the spinal cord. All of the spinal cords removed from the animals appeared normal externally. Each segment of the spinal cords of 7 animals was studied microscopically.

No sections showed thrombus formation in the anterior or posterior spinal arteries. Five animals, that were not paralyzed or paralyzed with motor disability of grades 1-3, showed no ischemic change microscopically. The other 2 animals, that were paraplegic the day after the operation, showed ischemic change of the spinal cord. No. 15 showed necrosis of the spinal cord from Th₆

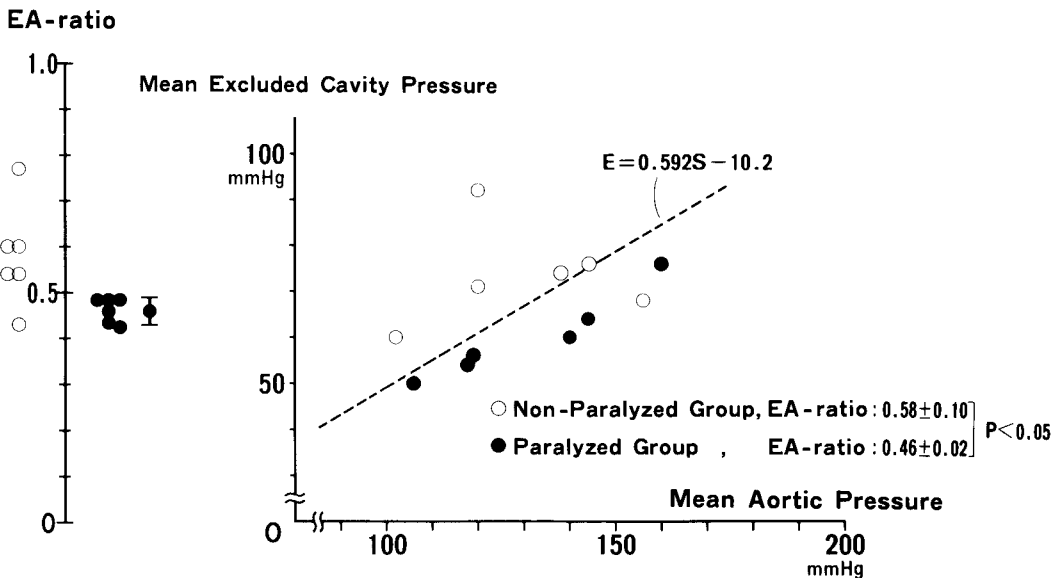


Fig. 6 Correlation among mean aortic pressure, excluded cavity pressure, EA-ratio and motor function in groups 2 and 3. Mean EA-ratio and excluded cavity pressure of the non-paralyzed animals were statistically higher than those of paralyzed animals.

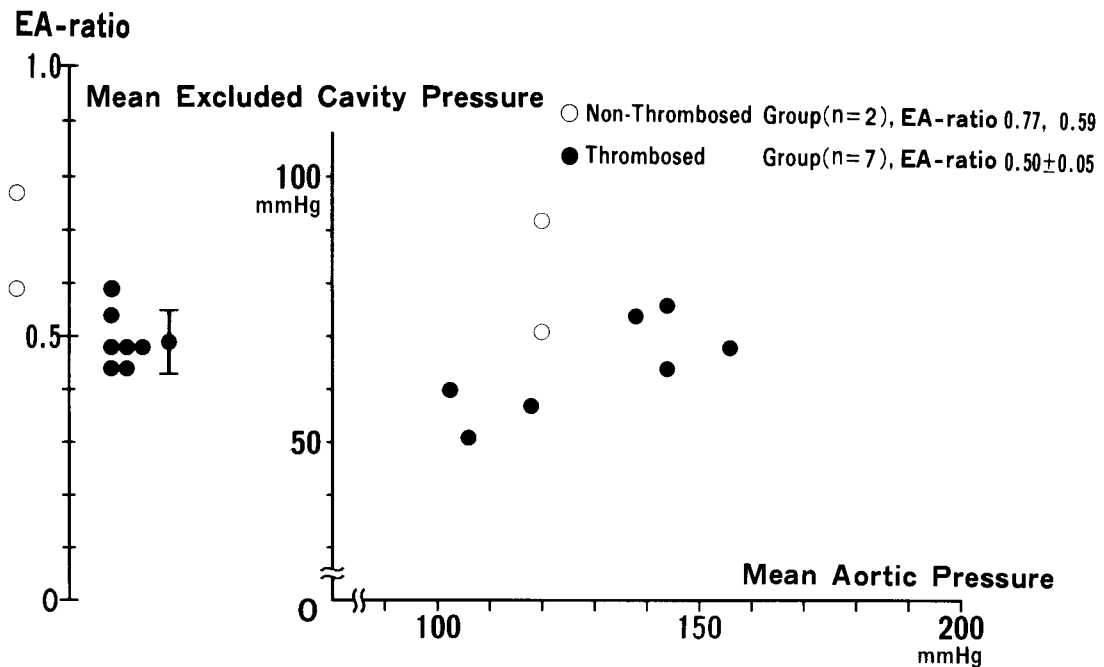


Fig. 7 Thrombus formation in groups 2 and 3. Among 9 animals in groups 2 and 3, that were sacrificed 7 or 8 days after the operation, 2 animals showed no thrombus formation in the excluded cavities.

to Th₁₁. The widest ischemic lesion was observed at the section of Th₇. This lesion showed necrosis involving the left side of the gray matter and the anterior and posterior gray column of the right side. The white matter was intact. No. 37 showed necrosis of the spinal cord from Th₇ to Th₁₂. The widest ischemic lesion was observed at the section of Th₁₁. The lesion showed necrosis involving most of the right gray matter and a part of the right white matter. The left anterior gray column was also affected. This lesion showed total loss of neurons and neuroglia with replacement by foamy macrophages (Fig. 9).

Discussion

When the thoracic aorta is completely excluded by the "paired clamp method", the blood supply to the thoracic spinal cord is mainly maintained by the collaterals, from the subclavian arteries through the internal

thoracic arteries, the excluded thoracic aorta, the intercostal arteries, the anterior and posterior radicular arteries (5). However, the blood flow to the spinal cord via these collaterals is reduced, and this is probably responsible for the spinal cord ischemia or paralysis. Besides, the thrombus formation in the excluded cavity may also have some influence on the development of the paralysis.

Shimazu *et al.* (4) experimentally studied and reported that no dogs were paralyzed after the exclusion of the entire thoracic aorta under permanent bypass without ligation of the branches of the thoracic aorta. In the present studies, some branches of the thoracic aorta were ligatured in order to imitate the state of the patient suffering from thoracic aortic aneurysm with severe atherosclerosis and arteriosclerosis, and 2 out of 6 animals in group 2 developed paralysis. There is no possibility that the ligation of some branches of the thoracic aorta directly induce the paralysis even if the artery of

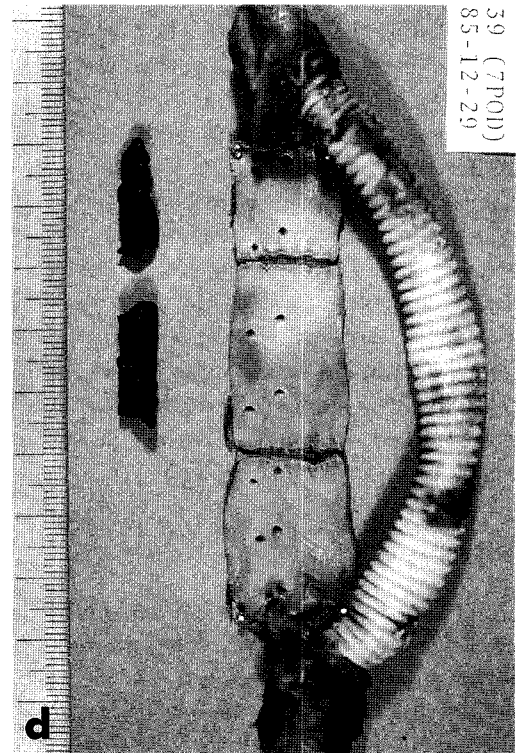
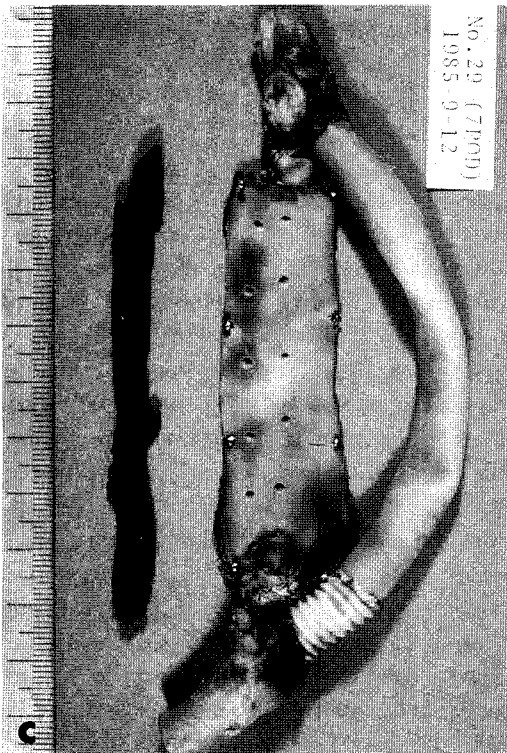
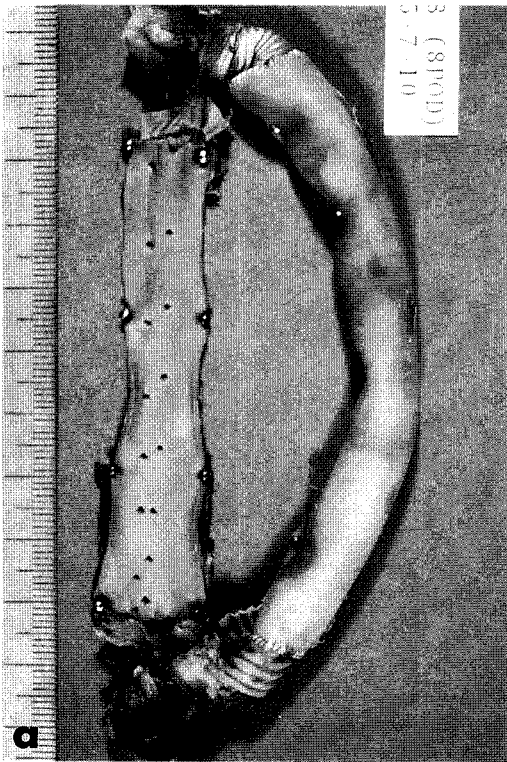


Fig. 8 Macroscopic findings of thoracic aorta and graft removed. The aorta is opened longitudinally. a, There is no thrombus formation in the excluded cavity (No. 18). b, There is a thin entire length thrombus in the excluded cavity (No. 24). c, The excluded cavity is fully thrombosed (No. 29). d, Among 3 divided parts, the proximal part is not thrombosed (No. 39).

Adamkiewicz is included in these ligatured intercostal and lumbar arteries, because no animals in group 1 developed paralysis. The difference between these 2 studies was ligation of some branches of the thoracic aorta. The "paired clamp method" should be carefully applied to the patient suffering from the thoracic aortic aneurysm with severe atherosclerosis and arteriosclerosis. The EA-ratio should be a reasonable value to predict the development of paralysis, because it evaluate the total blood flow to the thoracic spinal cord via excluded cavity.

Oka *et al.* (9) reported that all the dogs they studied were paralyzed after the simultaneous ligation of the left subclavian artery, all intercostal arteries and L_{1,2} lumbar arteries. In the present studies, half of the animals of groups 2 and 3 were not paralyzed. The difference between these 2 studies was the collateral circulation via the excluded cavity to the spinal cord. The excluded cavity pressure of the paralyzed animals and the non-paralyzed animals in groups 2 and 3 was 61 ± 7 mmHg and 74 ± 11 mmHg ($p < 0.05$), respectively. The EA-ratio of these 2 groups was 0.46 ± 0.02 and 0.58 ± 0.10 ($p < 0.05$), respectively. When the EA-ratio was higher than 0.48, no animals in groups 2 and 3 were paralyzed, and when it was lower than or equal to 0.48, all but 1 animals were paralyzed. It thus can be concluded that the EA-ratio is useful in predicting the development of paralysis after the operation by the "paired clamp method", and the EA-ratio should be kept higher than 0.48 in order to avoid the development of the paralysis. Laschinger *et al.* (10) and Kringeret *et al.* (11) reported almost similar

results in preserving the blood supply to the spinal cord.

Four out of 5 animals in group 4 were paralyzed. However, the mean excluded cavity pressure and the EA-ratio (measured before the division of the excluded cavity into 3 parts) of these 4 paralyzed animals were not statistically different from those of the non-paralyzed animals in groups 2 and 3. Group 4 animals had their excluded thoracic aortae divided by ligation, and some of the divided parts had a very low excluded part pressure and very low EA-ratio. The blood flow direction in the excluded cavity is possibly from the intercostal artery with highest back flow pressure to other intercostal arteries. The blockage of the blood flow caused by the division of the excluded cavity may be harmful to the spinal cord. In other words, collateral circulation to the spinal cord via the excluded cavity plays an important role in the blood supply to the spinal cord after the operation by the "paired clamp method".

Of 2 animals (Nos. 24 and 26) which died 2 days after the operation, one animal had no thrombus and the other had only a thin entire-length thrombus in the excluded cavity and the EA-ratio of each animal was 0.43 and 0.46, respectively. These 2 animals were paralyzed the day after the operation. These facts indicate that the thrombus formation in the excluded cavity was not responsible for the development of paralysis. Therefore, it appears that the most important factor that contributes to the development of paralysis after the operation by the "paired clamp method" may be the sudden reduction of the blood supply to the spinal cord via the excluded cavity.

The excluded cavity was fully thrombosed 7 or 8 days after the operation when the EA-ratio was lower than 0.59. It is worthy of notice that none of these animals showed aggravation of the paralysis during the obser-

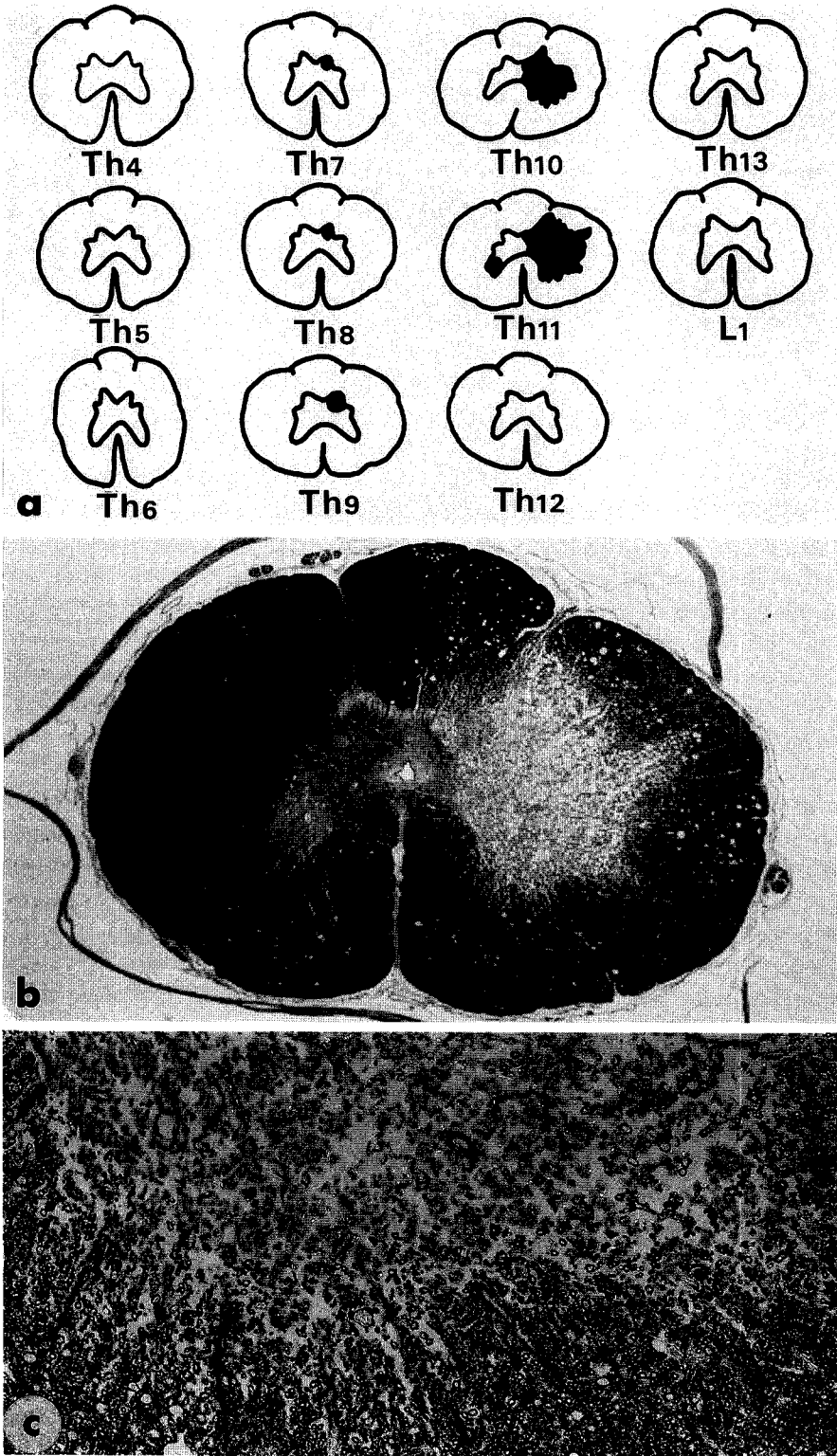


Fig. 9 Microscopic findings of the spinal cord. a, Schematic illustration of sections of spinal cord (No. 37). Black shows necrosis. The widest ischemic lesion is observed at Th₁₁. b, The section of spinal cord (No. 37) at Th₁₁ shows necrosis involving most of the right gray matter and a part of the white matter. The left anterior column is also affected. The anterior and posterior spinal arteries are not thrombosed (Klüver-Barrera stain, $\times 5$). c, Upper portion showed total loss of neurons and neuroglia with replacement by foamy macrophages. Right anterior gray column (Th₁₁, No. 37, Klüver-Barrera stain, $\times 250$).

vation period. Conversely, the paralysis of almost all of these animals was ameliorated. It is concluded that the thrombus formation in the excluded cavity is possibly slow enough so as not to be harmful to the spinal cord.

All but 1 of the divided parts of the excluded cavity of animals in group 4 were thrombosed. The EA-ratio of the non-thrombosed part was relatively high, 0.66. The division of the excluded cavity probably makes the formation of thrombi easier. The thrombus formation in the 3 divided parts of each animal did not progress uniformly, and this may be due to the different pressures or different blood flow volumes in each of the excluded parts.

The intraoperative measurement of the EA-ratio would be a useful method for predicting thrombus formation in the excluded cavity. When EA-ratio was higher than 0.59, thrombus formation in the excluded cavity was delayed. Therefore, the patients with higher EA-ratio than 0.59 should be strictly checked on their arterial pressure postoperatively, because they have the possibility of the enlargement or rupture of the excluded cavity.

Six out of 7 animals, whose spinal cords were examined microscopically, had fully thrombosed excluded cavities. No animals, however, showed thrombus formation in the anterior and posterior radicular arteries. This fact indicates that thrombus formation in the excluded cavity does not induce the occlusion of anterior or posterior spinal

arteries, and the thrombus formation is not responsible to the development of paralysis, as reported by Herrick *et al.* (12).

Somatosensory evoked potentials or spinal cord evoked potentials have been applied to predict the development of paralysis after the operation for thoracic aortic aneurysms (13). However, it is not a completely reliable method, and some clinical cases present false negative data.

Gaines *et al.* (14) reported that to alter the peroneal evoked potential in dogs, at least three quadrants of the spinal cord must be damaged. Among 7 spinal cords studied microscopically, two spinal cords showed necrosis of the gray matter and a part of the white matter. However, the extent of the necrosis did not cover three quadrants of the spinal cord. A small degree of necrosis of the spinal cord may sometimes not be detected by somatosensory evoked potentials or spinal cord evoked potentials, because there are many pathways for these electrophysiological stimuli and they have not been clearly identified. To predict the development of paralysis after the operation for the thoracic aortic aneurysm by the "paired clamp method", not only these electrophysiological tests but also the EA-ratio should be used simultaneously during the operation.

Acknowledgement. I wish to thank Prof. Shigeru Teramoto M. D., Hatsuzo Uchida M. D. and Makoto Motoi M. D. for continuously guiding me and giving me many suggestions during this investigation.

References

1. Webb WR and Brunswick R: Aneurysm of the Thoracic Aorta; in Textbook of Surgery, Sabiston ed, 12th Ed, Saunders Company, Philadelphia (1981) pp 1986-1990.
2. Carpentier A, Deloche A, Fabiani JN, Chauvaud S, Relland J, Nottin R, Vouhe P, Massoud H and Dubost Ch: New surgical approach to aortic dissection: Flow reversal and thromboexclusion. J Thorac Cardiovasc Surg (1981) 81, 659-668.

3. Shimizu Y, Iioka S, Ohashi H, Oka Y, Maeda S, Ogawa N, Yoshida T and Miyamoto T: Acute expansion of the false lumen after Carpentier's operation for extensive thoracic aortic aneurysm complicated with DeBakey type III_a dissecting aneurysm and infra-renal abdominal aortic aneurysm. *Jpn J Thorac Surg* (1983) **31**, 2075-2084 (in Japanese).
4. Shimazu K and Hashimoto A: Experimental study of "thromboexclusion technique" on dissecting aneurysm. *Igaku no Ayumi* (1982) **120**, 670-672 (in Japanese).
5. Oka Y, Miyamoto T, Murata H, Ohashi H, Yamashita K and Kohara M: A case of total exclusion of thoracoabdominal aortic aneurysm for the type of DeBakey III_b dissecting aneurysm — with special reference to the problem of the spinal cord injury—. *Jpn J Thorac Surg* (1985) **33**, 1340-1345 (in Japanese).
6. Coles JG, Wilson GJ, Sima AF, Klement P, Tait GA, Williams WG and Baird RJ: Intraoperative management of thoracic aortic aneurysm. *J Thorac Cardiovasc Surg* (1983) **85**, 292-299.
7. Katz NM, Blackstone EH, Kirklin JW and Krap RB: Incremental risk factors for spinal cord injury following operation for acute traumatic aortic transection. *J Thorac Cardiovasc Surg* (1981) **81**, 669-674.
8. Fried LC, Chiro GD and Doppman JL: Ligation of major thoraco-lumbar spinal cord arteries in monkeys. *J Neurosurg* (1969) **31**, 608-614.
9. Oka Y, Miyamoto T, Kitai K and Murata H: An experimental study of prevention of spinal cord injury during operation for thoracoabdominal aortic aneurysms by somatosensory evoked potential. *Jpn J Thorac Surg* (1984) **32**, 278 (in Japanese).
10. Laschinger JC, Cunningham JN Jr, Nathan IM, Knopp EA, Cooper MM and Spencer FC: Experimental and clinical assessment of the adequacy of partial bypass in maintenance of spinal cord blood flow during operations on the thoracic aorta. *Ann Thorac Surg* (1983) **36**, 417-426.
11. Krieger KH and Spencer FC: Is paraplegia after repair of coarctation of the aorta due principally to distal hypotension during aortic cross-clamping? *Surgery* (1985) **97**, 2-7.
12. Herrick MK and Mills PE: Infarction of spinal cord. *Arch Neurol* (1971) **24**, 228-241.
13. Laschinger JC, Cunningham JN, Catinella FP, Nathan IM, Knopp EA and Spencer FC: Detection and prevention of intraoperative spinal cord ischemia after cross-clamping of the thoracic aorta: Use of somatosensory evoked potentials. *Surgery* (1982) **92**, 1109-1117.
14. Gaines R, York DH and Watts C: Identification of spinal cord pathways responsible for the peroneal-evoked response in dog. *Spine* (1984) **9**, 810-814.

Received: November 15, 1986

Accepted: March 25, 1987

Correspondence to:

Setsuro Imawaki

First Department of Surgery

Kagawa Medical School

1750-1 Ikenobe, Miki-cho, Kida-gun

Kagawa 761-07, Japan