

Acta Medica Okayama

Volume 35, Issue 6

1981

Article 7

DECEMBER 1981

A case of supernumerary cuspid.

Seishi Kobayashi*

Katsumi Nishijima†

Hisatake Yao‡

Hideki Sugi**

Yasuo Takaya††

Tsuyoshi Ikeda‡‡

*Okayama University Dental School,

†Okayama University Dental School,

‡Okayama University Dental School,

**Okayama University Dental School,

††Okayama University Dental School,

‡‡Ikeda Dental Office,

— BRIEF NOTE —

A CASE OF SUPERNUMERARY CUSPID

Seishi KOBAYASHI, Katsumi NISHIJIMA, Hisatake YAO,
Hideki SUGI, Yasuo TAKAYA and Tsuyoshi IKEDA*

Department of Oral Surgery, Okayama University Dental School, Okayama 700, Japan
and * Ikeda Dental Office, Fukuyama 720, Japan

(Director: Prof. K. Nishijima)

Received July 13, 1981

Abstract. A supernumerary cuspid located distal to the maxillary right cuspid and buccal to the maxillary right first bicuspid in a 13-year-old girl was described.

Key words : oral anatomy, supernumerary cuspid

There have been many articles about supernumerary teeth (1-6) but reports of supernumerary cuspids are few (3-6). This report presents a case of supernumerary cuspid located distal to the maxillary right cuspid ($\underline{3}$), and buccal to the maxillary first bicuspid ($\underline{4}$).

Case report. The patient was a 13-year-old Japanese girl examined by one of our staff on March 27 th, 1979. On admission, the patient was in good health condition and her medical and family history contained nothing remarkable.

At the intraoral examination, a supernumerary tooth was observed at distal of $\underline{3}$ and buccal of $\underline{4}$. Enamel hypoplasia was seen at the tip of $\frac{63+36}{3+3}$ and the crowns of $\overline{6|6}$ were restored. $\underline{42|2}$ were dislocated palatally and $\underline{4}$ was rotated mesially about 45° (Figs. 1, 2).

$\underline{3}$ was in normal position and the supernumerary tooth was located between $\underline{3}$ and $\underline{5}$. $\underline{3}$ and the supernumerary tooth were at the same level of eruption. The crown morphology of the supernumerary tooth was very similar to that of $\underline{3}$ (Figs. 3, 4).

On the periapical radiograph, the crowns and the roots of $\underline{3}$ and the supernumerary tooth were about the same size and shape. No root resorption was observed (Fig. 5). The size of the supernumerary tooth measured from a dental model was almost the same as $\underline{3}$, but was slightly smaller than $\underline{3}$. The measurements of $\underline{3}$ were slightly less than Fujita's (6) average (Table 1).

TABLE 1. MEASUREMENTS (mm)

	Crown length	Mesiodistal diameter	Labiolingual diameter	Remarks
Sup. num. tooth ^a	7.8	7.5	7.6	Measured from plaster model
3	8.1	7.6	7.5	
3	8.8	7.7	8.1	
Average val. of maxil. cuspid val. ^b	10.9	7.9	8.3	from Fujita

^a Supernumerary tooth ; ^b Average value of maxillary cuspid value.

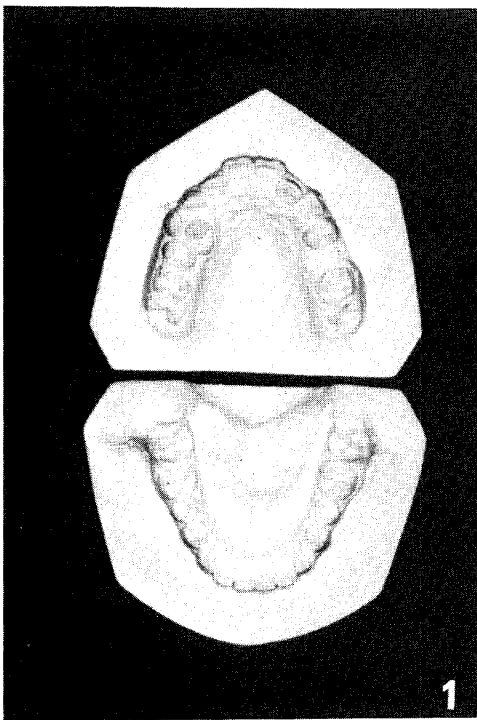


Fig. 1. Dental Models.

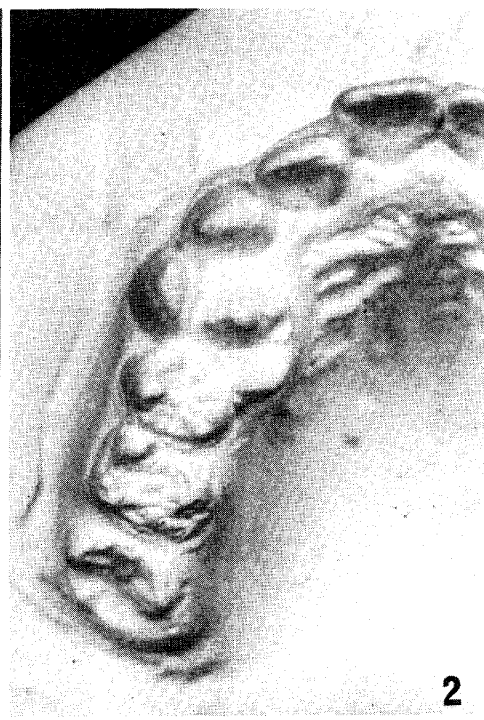

Fig. 2 Dental Model (Part).

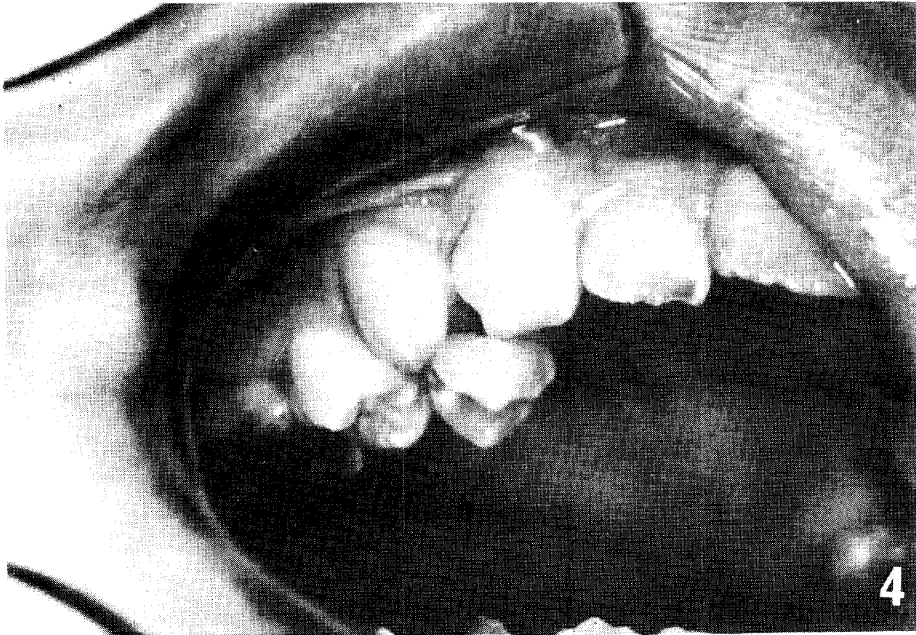
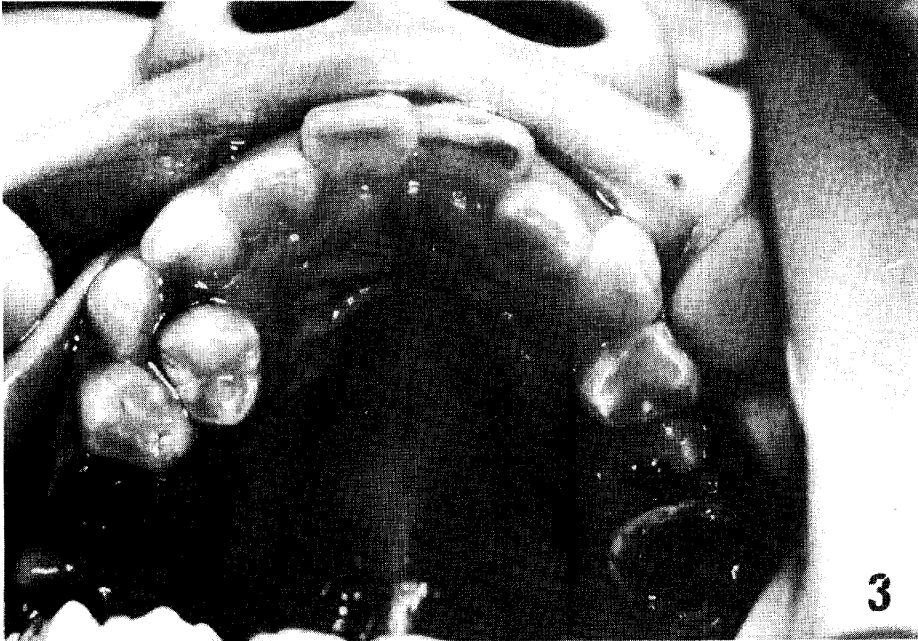


Fig. 3. Photograph of Maxilla.

Fig. 4. Photograph of Cuspid and Supernumerary Cuspid.

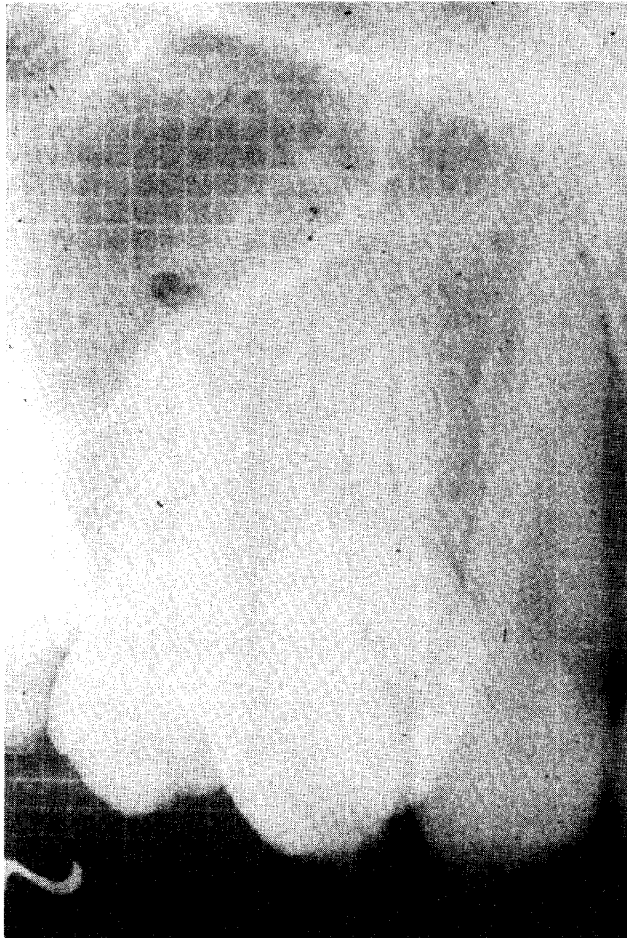


Fig. 5. Periapical Radiograph of Cuspid and Supernumerary Cuspid.

Discussion. According to studies of Stafne (1, 2), there were only two cases (0.4%) of maxillary supernumerary cuspid and one case (0.2%) of mandibular supernumerary cuspid in 500 cases which had supernumerary teeth and he stated that the incidence of supernumerary teeth in the maxillary and mandibular cuspid regions was the least.

In our case, the morphology and developmental stage of $\underline{3}$ and of the supernumerary tooth were similar. Nezu-Uchida (3) reported a case of maxillary supernumerary cuspid similar to as ours, the only difference being the site of the supernumerary tooth.

Fujita (4, 6) stated that the identification of supernumerary teeth which erupt at the cuspid region was difficult and a supernumerary tooth should be

identified by its morphological characteristics and location.

Based on morphological characteristics and location, this supernumerary tooth was considered to be a supernumerary cuspid. From the aspects of enamel hypoplasia accompanying this case, the appearance of tooth bud and the growth of this supernumerary cuspid seemed to have occurred simultaneously with maxillary cuspids. We suspect that the origin of this supernumerary cuspid was ontogenetic.

REFERENCES

1. Stafne, E.C.: Denticles, supernumerary cuspids & compound composite odontomes. *Dent. Cosmos* **73**, 796-798, 1931.
2. Stafne, E.C.: Supernumerary teeth. *Dent. Cosmos* **74**, 653-659, 1932.
3. Nezu, F. and Uchida, H.: A case of extremely rare supernumerary cuspid. *Shikageppo* **31**, 20-23, 1957 (in Japanese).
4. Fujita, K.: Abnormal number of teeth in man, *Kokubyo Z.* **25**, 97-106, 1958 (in Japanese).
5. Iwazawa, T., Nomura, S., Shoji, K. and Kita, K.: A case of rare supernumerary mandibular cuspids, Nihon Univ. *J. Oral Sci.* **38**, 246-248, 1964.
6. Fujita, K.: *The Anatomy of Teeth*, Kaneharashuppan Co., Tokyo. pp.44-137, 1974 (in Japanese).