

Case Report

A *c-KIT* Codon 816 Mutation, D816H, in the Testicular Germ Cell Tumor: Case Report of a Japanese Patient with Bilateral Testicular Seminomas

Genshu Tate*, Takao Suzuki, Koji Kishimoto, and Toshiyuki Mitsuya

Department of Surgical Pathology, Showa University Fujigaoka Hospital, Yokohama 227–8501, Japan

Mutations of the *c-KIT* gene have been reported not only in gastrointestinal stromal tumors and mast cell tumors, but also in testicular germ cell tumors (TGCTs). In the present study we employed polymerase chain reaction and DNA sequencing analysis to characterize the *c-KIT* gene in a 29-year-old Japanese patient with bilateral testicular seminomas. Direct sequence analyses revealed a single base substitution in exon 17 in one *c-KIT* allele, resulting in an amino acid substitution of D816H in this mutated allele. This mutation was found in the left, but not in the right, testicular seminoma. This is the first description of a *c-KIT* gene mutation in a Japanese patient with bilateral TGCT. The mutational analysis of the *c-KIT* gene seems to provide crucial information for managing TGCT patients not only in Europe but also in Japan.

Key words: testicular germ-cell tumor, seminoma, *c-KIT*, CD117

Recently, expression of KIT and mutations of the *c-KIT* gene have been identified in several kinds of tumors, including gastrointestinal stromal tumors (GISTs) [1], mast cell tumors [2], and germ cell tumors [3–7]. Mutational hot spots of the *c-KIT* gene in sporadic and familial GISTs have been found in exons 9, 11, 13 and 17 [1, 8]. In mast cell tumors, mutational hot spots exist in exons 11 and 17 [2]. An accurate mutational analysis of the *c-KIT* gene is indispensable not only to elucidation of the molecular basis of oncogenesis for the *c-KIT* gene, but also to evaluating the efficacy of STI571 (imatinib mesylate, Gleevec; Novartis Pharmaceuticals, East Hanover, NJ, USA) [9].

More than 90% of the primary testicular neoplasms in Japanese adolescent and adult males are testicular germ-cell tumors (TGCTs), and approximately 2–5% of

TGCT patients will develop contralateral disease. In TGCTs, KIT expression is characteristic of most seminomas, but not of nonseminomas.

We here report a missense mutation of the *c-KIT* gene that resulted in a codon 816 mutation of D816H in the left testicular seminoma of a Japanese patient with bilateral testicular seminomas.

Case Report

The patient was a 29-year-old Japanese man. He was admitted to our hospital due to left testicular swelling. Ultrasonography revealed a solid and uneven echo not only in the softball-sized left testis but also in the hen's egg-sized right testis. Laboratory data were AFP 2.0 ng/ml, LDH 1482 U/l, and beta-HCG 3.2 ng/ml on admission. High orchiectomy of the bilateral testes was performed based on a pathological diagnosis of seminoma for the biopsy specimen obtained from the right testis. The final diagnosis was bilateral testicular seminoma,

clinical stage I (pT2, N0, M0), according to the TNM classification. Chemotherapy was not performed after surgery. Androgen supplemental therapy has been carried out biweekly since the surgery, however, and the patient has been disease-free in his 6 years of follow-up. The cut surface of the resected testes showed a lobulated and grayish-white mass (Fig. 1A). Microscopically, both testes showed the same features, and the pathological diagnosis for both testes was typical seminoma (Fig. 1B, 1C). Immunohistochemical analysis showed that seminoma cells of both testes were positive for CD117 (*c-KIT*, No. 18101, Immuno-Biological Laboratories Co., Ltd., Fujioka, Japan) (Fig. 1D, 1E).

Genomic DNA was prepared from formalin-fixed and paraffin-embedded tissue by standard methods using phenol/chloroform extraction and ethanol precipitation. The exons and the intron/exon boundaries in the *c-KIT* gene were analyzed by polymerase-chain-reaction (PCR) and direct sequencing of the PCR products [10]. The primers used for amplification of the genomic DNA were as follows: *c-KIT*, ex17F, 5'- TTA GTT TTC ACT CTT TAC AAG TTA-3', *c-KIT*, ex17R, 5'- GTT GAA ACT AAA AAT CCT TTG CAG-3'.

PCR amplification was performed on a Smart Cycler (Cepheid, CA, USA) under the following conditions: 95 °C for 10 sec of initial heat denaturation and 40 cycles of 94 °C for 15 sec, 55 °C for 30 sec, and 72 °C for 30 sec. Amplified DNA fragments were recovered from a low melting temperature agarose gel and used for the sequencing analysis. We sequenced the PCR products by using a DNA sequencing system (model 377; Applied Biosystems). Direct sequencing was performed in both directions, and the mutation analysis was repeated independently. As shown in Fig. 1G, mutational analysis of the *c-KIT* gene using a pair of primers, ex17F and ex17R, revealed a heterozygous single nucleotide transversion from G to C in exon 17 that resulted in the mutation codon at 816 from aspartic acid (D) to histidine (H) in the left testicular seminoma, whereas the right testicular seminoma showed no mutations (Fig. 1F). Not only exon 17 but also exons 9, 11, and 13 of the *c-KIT* gene in the right testicular seminoma were examined, but no mutations were found (data not shown).

Discussion

The cases of bilateral TGCTs raise the question as to whether the molecular basis of TGCT is same or indepen-

dent between left and right testes and whether the histogenesis differs between unilateral and bilateral TGCTs. Our results imply that the molecular basis of bilateral seminomas is different between left and right testes and that the hypothesis set forward by Looijenga *et al.* [6] is true in this case. Their interesting retrospective study of 224 unilateral and 61 proven bilateral TGCTs reported in 2003 [6] led to identification of a *c-KIT* codon 816 mutation in 3 unilateral TGCTs (1.3%) and in 57 bilateral TGCTs (93%). Based on these data, they insisted that the presence of an activating codon 816 *c-KIT* mutation in a TGCT is associated with development of a contralateral TGCT. The patients examined in their study were from three independently collected series in Europe. In Japan, Sakuma *et al.* have reported that amongst 34 Japanese patients with TGCTs, *c-KIT* mutations were found in 4 cases (8.8%), with the mutant codons being D816V (2 cases), D816H, and W557R [5].

The frequency of bilateral testicular neoplasms in Japanese is 3.5% (8 of 229 cases)[11]. Bilateral testicular tumors have been found to be seminoma in 4 of 8 cases. In 2 cases (0.9%), bilateral tumors have been found simultaneously, and in 4 cases (2.6%) a contralateral tumor has been found asynchronously. The mean age of patients at the time of clinical diagnosis of the first tumor has been 30.5 years, with the mean difference in age between clinical presentation of the first and second tumors being 66.6 months [11]. These clinical findings in Japanese patients are almost in accordance with the published data outside Japan [12]. We successively found the *c-KIT* mutation and have reported here the first case of a Japanese patient with bilateral TGCTs. Little is known, however, regarding the *c-KIT* mutation of the bilateral TGCTs in Japan. Therefore, at present, it is uncertain whether the hypothesis that the *c-KIT* codon 816 mutations predict development of bilateral TGCTs [6] is applicable to the majority of Japanese patients of bilateral TGCTs. Large-scale examinations are necessary to confirm this. If, however, this hypothesis of Looijenga *et al.* does hold true in Japanese patients, mutational analyses to determine whether or not the codon 816 is affected will be crucial to counseling TGCT patients and to answering questions regarding why mutations affecting codon 816 of *c-KIT* are involved in the pathogenesis of bilateral TGCTs.

Hot spots of gain-of-function mutations of the *c-KIT* gene as reported in GISTs affect exons 9 or 11, but not exon 17. These mutations result in ligand-independent

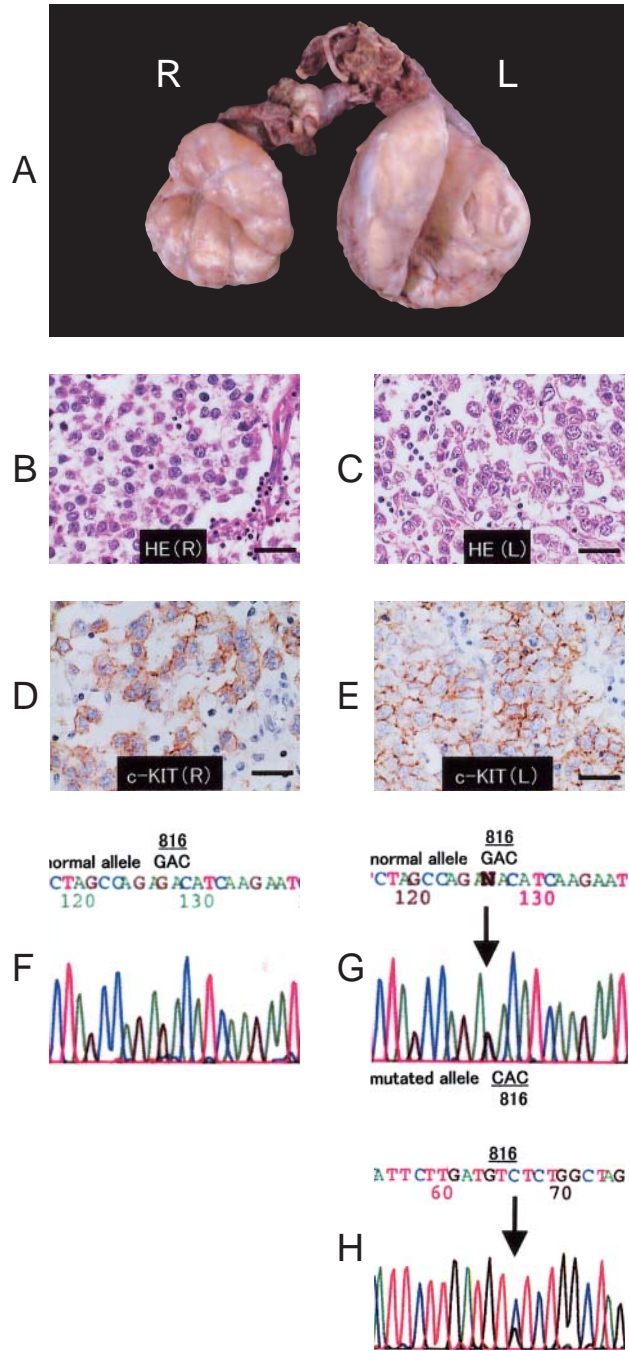


Fig. 1 A, Gross appearances of the bilateral TGCTs. On cross section, the tumor appears grayish-white and lobulated. B and C, Histological features of the bilateral TGCTs. Seminomas in the right (B) and left (C) testes are composed of polyhedral large cells, and the connective tissue septa are infiltrated with lymphocytes (Hematoxylin-Eosin; HE stain). A bar indicates 60 μm . D and E, Immunohistochemistry of the bilateral TGCTs. Seminomas are reactive with antibodies to c-KIT (CD117) in the right (D) and left (E) testes. A bar indicates 100 μm . F and G, Mutational analysis of the bilateral TGCTs. A single base substitution from G to C, resulting in D816H, is found in exon 17 in the left testis (G), whereas no mutations in exon 17 can be observed in the right testis (F). The nucleotide sequence shown at the top of Fig. 1G indicates the normal allele, while the mutated allele is shown at the bottom of Fig. 1G. The heterozygous transversion in the mutated allele is indicated by an arrow (G), and this mutation is confirmed by the sequencing in the reverse direction (H). An arrow in Fig. 1H indicates the missense mutation.

receptor dimerization and lead to the kinase activation of c-KIT. In contrast to GISTs, the codon 816 mutations found in our case of bilateral TGCTs resulted in constitutional intrinsic kinase activation, indicating that the molecular basis of carcinogenesis for the *c-KIT* gene is different between GISTs and TGCTs [13]. The tyrosine kinase inhibitor STI571 has been developed to be effective in treating GISTs, but this drug does not inhibit c-KIT-containing codon 816 mutations [14], as found in TGCTs. Mutational analysis of the *c-KIT* gene in TGCTs might be of great value in developing a new drug to treat TGCTs, and an accumulation of data is important to provide evidence-based therapy for TGCT patients.

Acknowledgments. We would like to thank Prof. M. Omine for providing us with the OmniMix HS beads and the Smart Cycler. This work was supported in part by the High-Technology Center Project from the Ministry of Education, Culture, Sports, Science, and Technology of Japan (GT).

References

- Hirota S, Isozaki K, Moriyama Y, Hashimoto K, Nishida T, Ishiguro S, Kawano K, Hanada M, Kurata A, Takeda M, Muhammad Tunio G, Matsuzawa Y, Kanakura Y, Shinomura Y and Kitamura Y: Gain-of-function mutations of c-kit in human gastrointestinal stromal tumors. *Science* (1998) 279: 577–580.
- Furitsu T, Tsujimura T, Tono T, Ikeda H, Kitayama H, Koshimizu U, Sugahara H, Butterfield JH, Ashman LK, Kanayama Y, Matsuzawa Y, Kitamura Y and Kanakura Y: Identification of mutations in the coding sequence of the proto-oncogene c-kit in a human mast cell leukemia cell line causing ligand-independent activation of c-kit product. *J Clin Invest* (1993) 92: 1736–1744.
- Tian Q, Frierson HF Jr, Krystal GW and Moskaluk CA: Activating c-kit gene mutations in human germ cell tumors. *Am J Pathol* (1999) 154: 1643–1647.
- Strohmeier T, Reese D, Press M, Ackermann R, Hartmann M and Slamon D: Expression of the c-kit proto-oncogene and its ligand stem cell factor (SCF) in normal and malignant human testicular tissue. *J Urol* (1995) 153: 511–515.
- Sakuma Y, Sakurai S, Oguni S, Hironaka M and Saito K: Alterations of the c-kit gene in testicular germ cell tumors. *Cancer Sci* (2003) 94: 486–491.
- Looijenga LH, de Leeuw H, van Oorschot M, van Gurp RJ, Stoop H, Gillis AJ, de Gouveia Brazao CA, Weber RF, Kirkels WJ, van Dijk T, von Lindern M, Valk P, Lajos G, Olah E, Nesland JM, Fossa SD and Oosterhuis JW: Stem cell factor receptor (c-KIT) codon 816 mutations predict development of bilateral testicular germ-cell tumors. *Cancer Res* (2003) 63: 7674–7678.
- Kemmer K, Corless CL, Fletcher JA, McGreevey L, Haley A, Griffith D, Cummings OW, Wait C, Town A and Heinrich MC: KIT mutations are common in testicular seminomas. *Am J Pathol* (2004) 164: 305–313.
- Sakurai S, Oguni S, Hironaka M, Fukayama M, Morinaga S and Saito K: Mutations in c-kit gene exons 9 and 13 in gastrointestinal stromal tumors among Japanese. *Jpn J Cancer Res* (2001) 92: 494–498.
- Frost MJ, Ferrao PT, Hughes TP and Ashman LK: Juxtamembrane mutant V560GKit is more sensitive to Imatinib (STI571) compared with wild-type c-kit whereas the kinase domain mutant D816VKit is resistant. *Mol Cancer Ther* (2002) 1: 1115–1124.
- Tate G, Suzuki T and Mitsuya T: A new mutation of *LKB1* gene in a Japanese patient with Peutz-Jeghers syndrome. *Acta Med Okayama* (2003) 57: 305–308.
- Tashiro K, Yanada S, Furuta A, Takizawa A, Iwamuro S, Suzuki M, Hatano T, Kondo N and Ohishi Y: Bilateral germ cell testicular cancer. *Rinsho Hinyokika (Jpn J Clin Urol, Tokyo)* (2001) 55: 549–552 (in Japanese).
- Holzbeierlein JM, Sogani PC and Sheinfeld J: Histology and clinical outcomes in patients with bilateral testicular germ cell tumors: the Memorial Sloan Kettering Cancer Center experience 1950 to 2001. *J Urol* (2003) 169: 2122–2125.
- Tian Q, Frierson HF Jr, Krystal GW and Moskaluk CA: Activating c-kit gene mutations in human germ cell tumors. *Am J Pathol* (1999) 154: 1643–1647.
- Heinrich MC, Blanke CD, Druker BJ and Corless CL: Inhibition of KIT tyrosine kinase activity: a novel molecular approach to the treatment of KIT-positive malignancies. *J Clin Oncol* (2002) 20: 1692–1703.