

Acta Medica Okayama

Volume 59, Issue 6

2005

Article 7

DECEMBER 2005

Abdominal wall and thigh abscess resulting from the penetration of ascending colon cancer.

Kazuhiro Tsukuda, *Okayama Red Cro General Hospital*
Eiji Ikeda, *Okayama Red Cro General Hospital*
Takayoshi Miyake, *Okayama Red Cro General Hospital*
Yoko Ishihama, *Okayama Red Cro General Hospital*
Hiroyuki Watatani, *Okayama Red Cro General Hospital*
Tomohiro Nogami, *Okayama Red Cro General Hospital*
Hiroko Masuda, *Okayama Red Cro General Hospital*
Shouji Takagi, *Okayama Red Cro General Hospital*
Ryuji Hirai, *Okayama Red Cro Hospital*
Shigeharu Moriyama, *Okayama Red Cro General Hospital*
Hisashi Tsuji, *Okayama Red Cro General Hospital*
Shiro Furutani, *Okayama Red Cro General Hospital*
Tadayoshi Kunitomo, *Okayama Red Cro General Hospital*
Sugato Nawa, *Okayama Red Cro General Hospital*

Abdominal wall and thigh abscess resulting from the penetration of ascending colon cancer.*

Kazuhiro Tsukuda, Eiji Ikeda, Takayoshi Miyake, Yoko Ishihama, Hiroyuki Watatani, Tomohiro Nogami, Hiroko Masuda, Shouji Takagi, Ryuji Hirai, Shigeharu Moriyama, Hisashi Tsuji, Shiro Furutani, Tadayoshi Kunitomo, and Sugato Nawa

Abstract

An unusual case is described in which an abdominal wall and thigh abscess was an initial symptom of ascending colon cancer. A 76-year-old woman was referred to our hospital for investigation of fever and abdominal and thigh swelling. Computed tomography revealed a right abdominal wall, retroperitoneal, psoas and thigh abscess formation suspected to be caused by colon perforation. Due to the patient's poor general condition, local drainage of the abscess was performed on the following day of hospitalization. Histological examination of necrotic tissues removed from the retroperitoneal cavity demonstrated adenocarcinoma of the colon. The patient subsequently underwent right hemicolectomy with lymph nodal dissection after 19 days of the drainage procedure and was transferred to another hospital on the 49th day following the second surgery.

KEYWORDS: colorectal cancer, abdominal wall abscess, thigh abscess

*PMID: 16418772 [PubMed - indexed for MEDLINE]

Copyright (C) OKAYAMA UNIVERSITY MEDICAL SCHOOL

Case Report

Abdominal Wall and Thigh Abscess Resulting from the Penetration of Ascending Colon Cancer

Kazunori Tsukuda^{a*}, Eiji Ikeda^a, Takayoshi Miyake^b, Yoko Ishihama^a,
Hiroyuki Watatani^a, Tomohiro Nogami^a, Hiroko Masuda^a, Shoji Takagi^a,
Ryuji Hirai^a, Shigeharu Moriyama^a, Hisashi Tsuji^a, Shiro Furutani^a,
Tadayoshi Kunitomo^b, and Sugato Nawa^a

*Departments of ^aSurgery, and ^bPathology, Okayama Red Cross General Hospital,
Okayama 700–9607, Japan*

An unusual case is described in which an abdominal wall and thigh abscess was an initial symptom of ascending colon cancer. A 76-year-old woman was referred to our hospital for investigation of fever and abdominal and thigh swelling. Computed tomography revealed a right abdominal wall, retroperitoneal, psoas and thigh abscess formation suspected to be caused by colon perforation. Due to the patient's poor general condition, local drainage of the abscess was performed on the following day of hospitalization. Histological examination of necrotic tissues removed from the retroperitoneal cavity demonstrated adenocarcinoma of the colon. The patient subsequently underwent right hemicolectomy with lymph nodal dissection after 19 days of the drainage procedure and was transferred to another hospital on the 49th day following the second surgery.

Key words: colorectal cancer, abdominal wall abscess, thigh abscess

Colorectal cancer ranks second in terms of both incident and mortality in developed countries [1]. Bleeding is a common symptom of advanced cancer, and constipation or occlusion suggests a left-sided tumor. The faecal occult bleeding test is effective for mass screening in asymptomatic persons [2]. Fever or pain caused by abscess formation has been less frequently reported as the initial symptom of colorectal cancers [3–5]. Invasion toward adjacent organs is often found in advanced colorectal cancers, but concomitant invasion as an abdominal wall abscess is relatively rare. We report a case of ascending colon cancer found by abdominal wall and thigh abscess formation.

Case Report

A 76-year-old female patient felt general fatigue but had not consulted physicians. A month later, a family member found swelling and redness on the right abdomen. The patient consulted a physician and was referred to our institution. The patient presented a high fever of 39.0 °C and remarkable swelling and redness on her right abdominal wall and right thigh. Spontaneous pain and severe tenderness of the right abdomen and thigh were also presented. A leukocytosis level of 34,200 cells/mm³ and a remarkable increased C-reactive protein of 28.4 mg/dl were noted. Computed tomography showed retroperitoneal and psoas abscess as well as subcutaneous and thigh abscess (Fig. 1). The route of extension of infection into the thigh seemed to be through the femoral canal. The wall of the ascending colon was swollen and existed adjacent to the retroperitoneal abscess. We speculated

Received March 22, 2005; accepted May 18, 2005.

*Corresponding author. Phone: +81-86-222-8811; Fax: +81-86-222-8841
E-mail: kazu.tsukuda@nifty.com (K. Tsukuda)

that perforation of ascending colon due to the colon cancer or diverticulitis was the cause of the abscess.

Local drainage of the abscess was performed before proceeding with further examinations, due to the poor general condition of the patient. The subcutaneous and retroperitoneal abscess was drained by a retroperitoneal approach through an oblique incision on the right lower abdomen. Abundant purulent fluid and necrotic tissues were removed from the abscess cavity, but no stool was collected. Thigh drainage was also performed, and the extension of abscess through the femoral canal was confirmed. Cultures obtained from the abscess grew *Escherichia coli* and *Proteus penneri*. The patient was treated with imipenem, and abscess reduction and improvement of physical findings were shown. The pathological findings of necrotic tissues removed from the retroperitoneal cavity demonstrated adenocarcinoma of the colon, and the cause of the abscess was considered to be the penetration of colon cancer.

Nineteen days after the drainage, a right

hemicolectomy was undertaken. The ascending colon was easily removed from the retroperitoneal tissues, and there was no sign of peritoneal dissemination. Though the anterior abdominal fascia was partially resected, retroperitoneal tissues which made up the abscess wall were too huge to be dissected completely. The tumor was 5.0 cm in diameter and existed in the ascending colon, extending to the cecum and terminal ileum (Fig. 2A), with lymph node metastasis (stage II in UICC criteria). The pathological finding was moderately differentiated adenocarcinoma, se, ly3, v3, n1 (Fig. 2C). A peritoneal inclusion cyst existed in the muscle layer of the ascending colon but did not seem to be associated with the penetration of colon cancer (Fig. 2B).

The patient had an uneventful postoperative course and was referred to another hospital on the 49th day following the second surgery. No adjuvant treatment was performed because of the poor performance status of the patient but at 3 months there had been no evidence of recurrence.

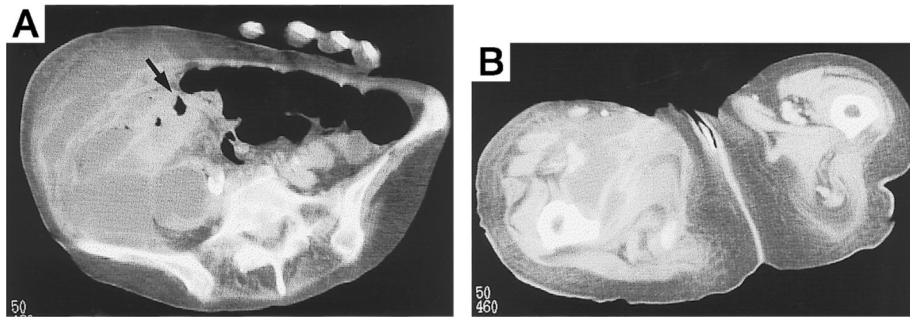


Fig. 1 A, The computed tomography shows a large retroperitoneal, psoas and subcutaneous abscess and swelling of the ascending colon wall (arrow); B, Abscess was extended to the right thigh.




Fig. 2 A, Macroscopic findings of a tissue specimen revealed an ulcerative tumor that occupied the ascending colon. The fistula tract was not evident at the time of operation; B, A peritoneal inclusion cyst (arrow) existed at the ascending colon adjacent to the tumor; C, Microscopic findings showed a well differentiated adenocarcinoma. (H&E, $\times 100$)

Discussion

The colorectal cancers have the tendency to spread locally, and advanced cancers frequently show direct invasion to adjoining organs and peritoneal dissemination. Abscess formation has been reported to occur in 0.3 to 0.4% of colonic carcinomas, but the frequency may be lower because of the recent advance of diagnostic techniques [6, 7]. Most of the perforation of colorectal cancers occurs in the intraabdominal cavity, with abdominal wall abscess occurring rarely [8]. A higher incidence of mucinous carcinomas was reported among colon cancers presenting an abdominal wall abscess. It has been suggested that mucinous carcinoma is slow-growing and usually spreads by direct extension. Psoas abscess associated with colon carcinoma is less common; only 3 cases have been reported [9]. This case was an adenocarcinoma, a common histological type of colorectal cancer, and the patient was not under depressed immune condition. Nonspecific symptom of a retroperitoneal abscess and poor performance status of the patient may indicate a huge abscess extended to the abdominal wall and thigh [9].

In our case, the route of extension of infection into the thigh appears to have been through the femoral canal. The route by which thigh abscesses spread from abdominal sources is reported to occur in 2 groups [10-13]. One is the direct soft tissue extension of infection from the extraperitoneal portion of the rectum. The other is the extension of infection into the thigh via naturally occurring defects in the abdominal wall, as follows: (1) along the psoas muscle deep to the inguinal ligament and iliofemoral vessels; (2) through the femoral canal; (3) by way of the obturator foramen; or (4) through the sacrosclatic notch into the buttock and thigh posteriorly. Though the extension of intraabdominal infection to extraabdominal sites through these potential opening is limited by the peritoneum, several cases of colorectal origins have been reported in the literature.

The drainage procedures of the abscess caused by the perforation of colon cancer could cause regional spreading of cancer cells. An en bloc excision of the cancer, fistula

wall, and abscess wall may be preferable in such cases, but such a procedure could not be undertaken in some cases because of the high invasiveness [6, 8].

In conclusion, we have described a patient with ascending colon cancer who presented with an abdominal wall and thigh abscess. With recent advances in imaging techniques, diagnosis of abscess has become easily, but clinicians must keep in mind that the colorectal cancers could be a cause of abdominal wall or thigh abscess, and early diagnosis and appropriate drainage definitely reduce patient mortality rates.

References

1. Colorectal cancer; in World Cancer Report. 2003, Stewart BW and Kleihues P eds, IAPC Press, Lyon (2003) pp 198-202.
2. Mandel JS, Church TR, Bond JH, Ederer F, Geisser MS, Mongin SJ, Snover DC, Schuman LM: The effect of fecal occult-blood screening on the incidence of colorectal cancer. *N Engl J Med* (2000) 343: 1603-1607.
3. Magliante DD and Pollack HM: Retroperitoneal abscess: a presentation of colon carcinoma. *Gastrointest Radiol* (1983) 8: 177-181.
4. Llauger J, Perez C, Andreu J and Palmer J: Psoas abscess demonstrated by CT as the first evidence of carcinoma of the colon. *Comput Radiol* (1987) 11: 259-261.
5. Welch JP: Unusual abscess in perforating colorectal cancer. *Am J Surg* (1976) 131: 270-274.
6. Grunewald B and Bissett I: Abscess of the abdominal wall--an unusual presenting sign of colonic carcinoma. *N Z Med J* (1999) 112: 262.
7. Mandava N, Kumar S, Pizzi WF and Aprile IJ: Perforated colorectal carcinomas. *Am J Surg*. (1996) 172: 236-238.
8. Matsumoto G, Asano H, Kato E and Matsuno S: Transverse colonic cancer presenting as an anterior abdominal wall abscess: report of a case. *Surg Today* (2001) 31: 166-169.
9. Kobayashi H, Sakurai Y, Shoji M, Nakamura Y, Suganuma M, Imazu H, Hasegawa S, Matsubara T, Ochiai M and Funabiki T: Psoas abscess and cellulitis of the right gluteal region resulting from carcinoma of the cecum. *J Gastroenterol* (2001) 36: 623-638.
10. Mann GN, Scoggins CR and Adkins B: Perforated cecal adenocarcinoma presenting as a thigh abscess. *South Med J* (1997) 90: 949-951.
11. Rotstein OD, Pruett TL and Simmons RL: Thigh abscess. An uncommon presentation of intraabdominal sepsis. *Am J Surg* (1986) 151: 414-418.
12. Shimizu J, Kinoshita T, Tatsuzawa Y, Takehara A, Kawaura Y and Takahashi S: Gluteal abscess caused by perforating rectal cancer: a case report and review of the literature. *Tumori* (2001) 87: 330-331.
13. Peterson CM, Allison JG and Lu CC: Psoas abscess resulting from perforating carcinoma of the sigmoid colon. Report of a case. *Dis Colon Rectum* (1983) 26: 390-392.