

Acta Medica Okayama

Volume 57, Issue 2

2003

Article 5

APRIL 2003

The relationship between Doppler indices from inferior vena cava and hepatic veins in normal human fetuses.

Isoji Okura*

Yasunari Miyagi†

Katsuhiko Tada‡

Hiroshi Masaoka**

Nobuo Akamatsu††

Takafumi Kudo‡‡

*Okayama University,

†Okayama Red Cross General Hospital,

‡Okayama University Graduate School,

**Okayama University,

††Okayama University Graduate School,

‡‡Okayama University,

The relationship between Doppler indices from inferior vena cava and hepatic veins in normal human fetuses.*

Isoji Okura, Yasunari Miyagi, Katsuhiko Tada, Hiroshi Masaoka, Nobuo Akamatsu, and Takafumi Kudo

Abstract

This study was conducted to determine the gestational age-related reference range of the preload index [peak velocity during atrial contraction (A)/peak velocity during ventricular systole (S)] for the inferior vena cava (IVC), the right hepatic vein, the middle hepatic vein and the left hepatic vein. The slope and the intercept of the regression line for each preload index were compared among the 4 veins using analysis of covariance. Doppler measurements were obtained for the 4 veins of 316 normal fetuses at 22-40 weeks of gestation. A and S values were measured from the recorded flow velocity waveform of each vein and the A/S ratio was calculated as the preload index. The regression lines for the preload index of the 4 veins decreased gradually throughout gestation. Analysis of covariance revealed no significant differences in the slopes of the regression lines for the 4 veins. However, the intercepts of the regression lines for all hepatic veins were significantly higher than that of the regression line for the IVC ($P < 0.0001$), with the difference ranging from 0.024 to 0.033. There were no significant differences among the intercepts of the regression lines for different hepatic veins. We concluded that the relationship between the preload index and the duration of gestation was statistically similar for all hepatic veins, and strongly resembled that for the IVC.

KEYWORDS: fetus, Doppler ultrasonography, preload index, inferior vena cava, hepatic vein

*PMID: 12866747 [PubMed - indexed for MEDLINE]

Copyright (C) OKAYAMA UNIVERSITY MEDICAL SCHOOL

Original Article

The Relationship between Doppler Indices from Inferior Vena Cava and Hepatic Veins in Normal Human Fetuses

Isoji Okura^{a*}, Yasunari Miyagi^b, Katsuhiko Tada^a, Hiroshi Masaoka^a,
Nobuo Akamatsu^a, and Takafumi Kudo^a

^aDepartment of Obstetrics and Gynecology, Okayama University Graduate School of Medicine and Dentistry, Okayama 700-8558, Japan, and

^bDepartment of Obstetrics and Gynecology, Okayama Red Cross General Hospital, Okayama 700-8667, Japan

This study was conducted to determine the gestational age-related reference range of the preload index [peak velocity during atrial contraction (A)/peak velocity during ventricular systole (S)] for the inferior vena cava (IVC), the right hepatic vein, the middle hepatic vein and the left hepatic vein. The slope and the intercept of the regression line for each preload index were compared among the 4 veins using analysis of covariance. Doppler measurements were obtained for the 4 veins of 316 normal fetuses at 22-40 weeks of gestation. A and S values were measured from the recorded flow velocity waveform of each vein and the A/S ratio was calculated as the preload index. The regression lines for the preload index of the 4 veins decreased gradually throughout gestation. Analysis of covariance revealed no significant differences in the slopes of the regression lines for the 4 veins. However, the intercepts of the regression lines for all hepatic veins were significantly higher than that of the regression line for the IVC ($P < 0.0001$), with the difference ranging from 0.024 to 0.033. There were no significant differences among the intercepts of the regression lines for different hepatic veins. We concluded that the relationship between the preload index and the duration of gestation was statistically similar for all hepatic veins, and strongly resembled that for the IVC.

Key words: fetus, Doppler ultrasonography, preload index, inferior vena cava, hepatic vein

Abnormal flow velocity waveforms of the inferior vena cava (IVC), showing increased reverse flow during atrial contraction, have been reported in various fetal pathologic states, including arrhythmia [1], hydrops fetalis [2, 3], and growth restriction [4-8]. Thus, evaluation of IVC flow has recently been recognized as important in the assessment of fetal diseases.

The hepatic veins drain directly into the IVC just under the diaphragm [9-11]. In normal adults [12, 13] and normal children [14], hepatic vein flow velocity waveforms have been reported to be similar to the flow patterns in the IVC and the superior vena cava (SVC). In normal human fetuses, the flow patterns in the IVC and the right hepatic vein (RHV) have also been reported to be similar [15, 16]. However, in the hepatic veins of compromised fetuses such as those with growth restriction, the atrial contraction wave velocity increases, as in the IVC flow pattern [17].

Received September 24, 2002; accepted December 5, 2002.

*Corresponding author. Phone: +81-86-235-7320; Fax: +81-86-225-9570

Accordingly, the analysis of flow velocity patterns in hepatic veins is gaining recognition as a significant indicator for compromised fetuses, as is already the case for the IVC. Since the IVC runs parallel to the long axis of the fetal trunk, it is not so easy, in many cases, to set the incidence angle of the ultrasound beam at an appropriate angle of 60° or smaller. The hepatic veins, comprising the RHV, the middle hepatic vein (MHV) and the left hepatic vein (LHV), traverse the liver and drain into the IVC just beneath the diaphragm, making it easier to set the ultrasound beam at a proper angle to them. If analysis of flow velocity waveforms in the hepatic veins could be substituted for the analysis of IVC waveforms, easier and more accurate evaluation of fetal cardiac function would become possible. However, the association between the flow velocity pattern of the IVC and that of the hepatic veins has never been investigated. In the present study, we measured the flow velocity of the IVC, the RHV, the MHV and the LHV in normal human fetuses and calculated the preload index [2] as the ratio of the peak velocity during atrial contraction to the peak velocity during ventricular systole. Gestational age-related normal ranges of the preload index for the IVC, the RHV, the MHV and the LHV were determined, and differences in the preload index were compared among the 4 veins.

Materials and Methods

The subjects were 325 normally developing singleton fetuses at 22–40 weeks of gestation, in whom the IVC, the RHV, the MHV and the LHV could all be measured. The flow velocity waveforms of the IVC, the RHV, the MHV and the LHV were simultaneously recorded by pulsed Doppler ultrasonography with color flow mapping. Flow velocity waveforms from the IVC were recorded on a longitudinal scan through the trunk; the sample volume was established as close as possible to the right atrium. The RHV, the MHV and the LHV were visualized on an oblique transverse scan through the upper abdomen, and the sample volume was established in the main trunk of each vessel as close as possible to the IVC. Flow velocity waveforms were recorded in the absence of fetal breathing movements and fetal movements [18]. To minimize measurement errors, the probe was kept at an incident angle of less than 60° relative to the target vessel.

The flow velocity waveforms of the RHV, the MHV and the LHV showed a three-phase pulsatile pattern similar to that of the IVC (Fig. 1). Peak velocity during

atrial contraction (A) and peak velocity during ventricular systole (S) were measured from the recorded flow velocity waveform of each vein, and the A/S ratio was calculated to obtain the preload index [2] (Fig. 2). There were 9 fetuses who did not show an A wave in the IVC. These fetuses were excluded from analysis, since the typical flow velocity waveform of the IVC in normal fetuses was reported to be a three-phase pulsatile pattern [1]. Using data from 316 fetuses (excluding those who did not show an A wave), regression lines for the preload index of the IVC, the RHV, the MHV and the LHV from 22 to 40 weeks of gestation were obtained to prepare a normogram of each preload index. Then, the slope and the intercept of the regression line for each preload index were compared using analysis of covariance.

Recordings were obtained with color and pulsed Doppler ultrasound equipment (SSD 4000; Aloka Co., Tokyo, Japan, RT-8000; GE Yokogawa Medical Systems Co., Tokyo, Japan) using a 3.5 MHz convex probe. The Doppler carrier frequency ranged from 2.5 to 2.6 MHz. The low cut filter was set at 50 Hz and the pulsed Doppler sample volume was set at 2 mm.

All the mothers of the fetuses gave informed consent to the study.

Results

Fig. 3 shows the distribution of the preload index for the IVC, the RHV, the MHV and the LHV and the regression lines with 95% confidence intervals in the 316 normally developing singleton fetuses at 22–40 weeks of gestation. The regression equations for the veins were as follows.

$$\text{IVC : } y = -0.00416x + 0.393, \\ r = -0.369, P < 0.0001$$

$$\text{RHV : } y = -0.00429x + 0.421, \\ r = -0.344, P < 0.0001$$

$$\text{MHV : } y = -0.00448x + 0.436, \\ r = -0.373, P < 0.0001$$

$$\text{LHV : } y = -0.00366x + 0.405, \\ r = -0.332, P < 0.0001$$

(x, gestational week; y, preload index).

In the 4 veins, the preload index decreased gradually with the course of pregnancy.

Table 1 shows the results of comparison of the 4 regression lines by analysis of covariance. There were no significant differences in the slopes of the regression lines for the 4 veins. The intercepts of the regression lines for

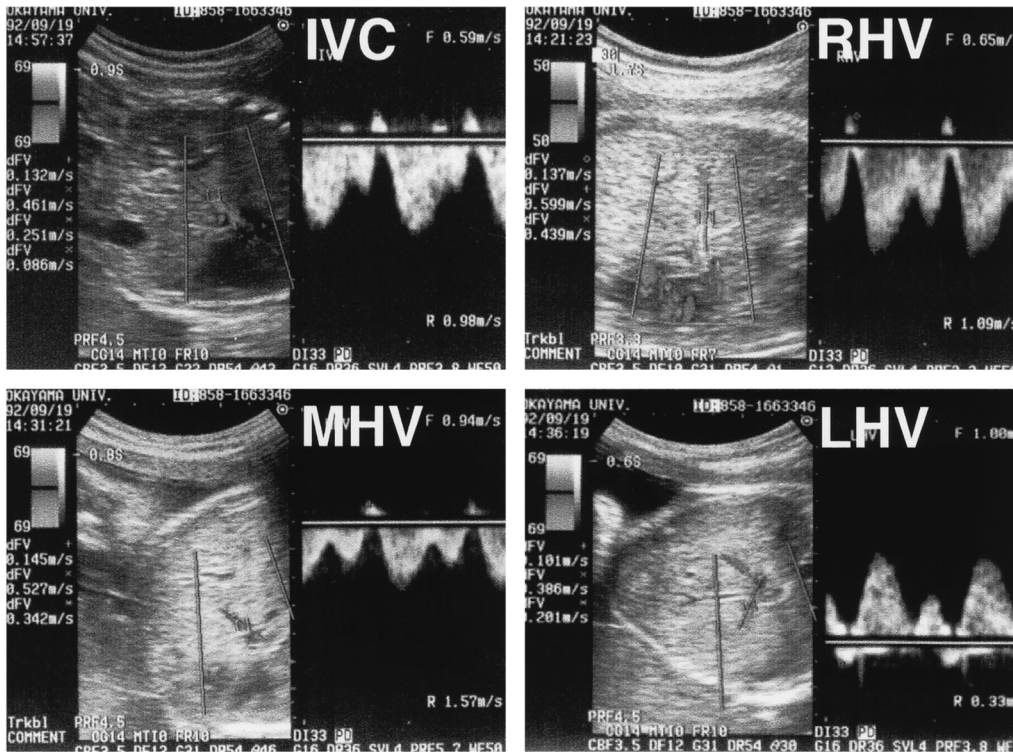


Fig. 1 Flow velocity waveforms from the IVC, the RHV, the MHV and the LHV in a normally developing fetus at 32 weeks of gestation. The flow velocity waveforms of the four veins (IVC, RHV, MHV, LHV) exhibited the same pattern. IVC, inferior vena cava; RHV, right hepatic vein; MHV, middle hepatic vein; LHV, left hepatic vein.

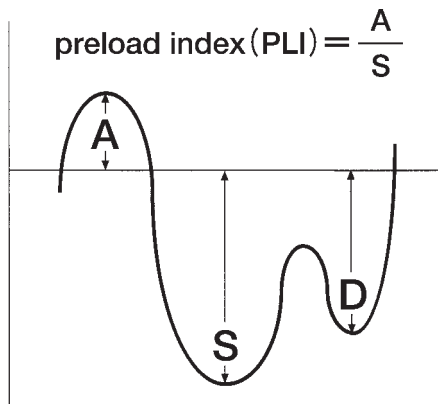


Fig. 2 Schematic representation of velocity waveform from inferior vena cava and hepatic vein and the definition of the preload index. A, peak velocity during atrial contraction; D, peak velocity during ventricular diastole; S, peak velocity during ventricular systole.

all hepatic veins were significantly higher than that of the regression line for the IVC ($P < 0.0001$), with the differences ranging from 0.024 to 0.033, while there were no significant differences among the hepatic veins. Because there were no statistical differences between any 2 hepatic veins, regression analysis was performed on pairs of hepatic veins, as shown in the lower panel of Table 1.

The preload index of the 4 veins changed similarly over the course of gestation. However, the preload index of each hepatic vein was significantly higher than that of the IVC at any gestational age.

Discussion

In the present study, the preload index of the IVC,

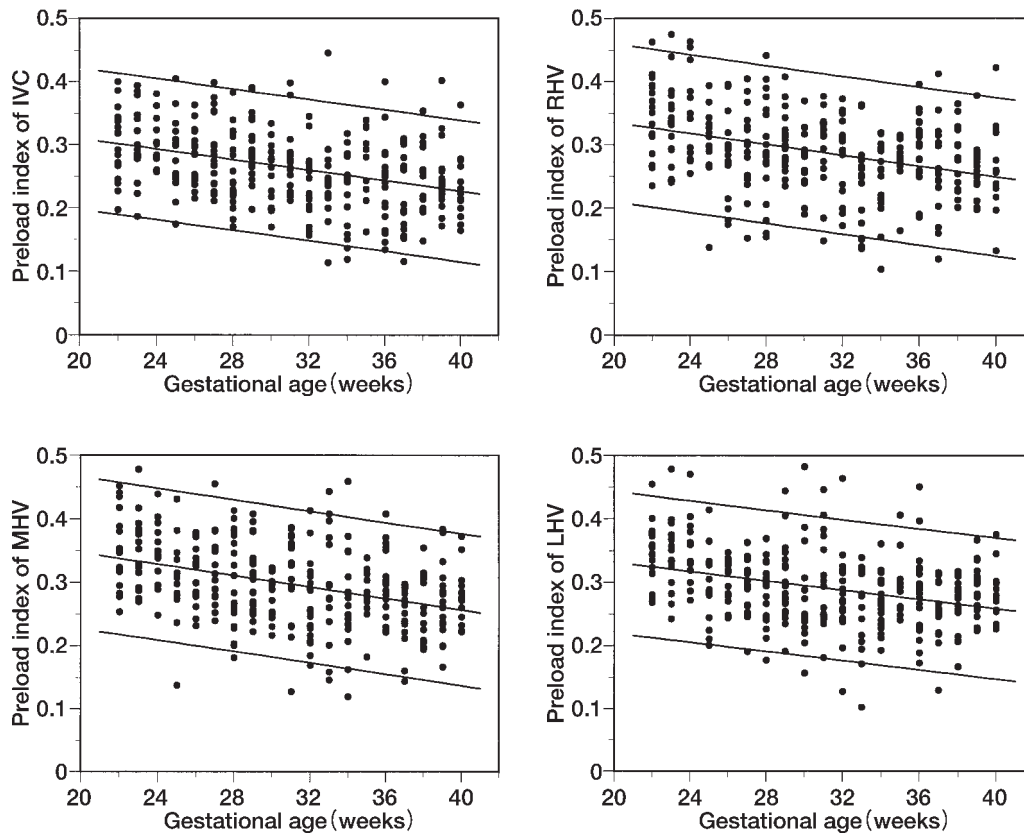


Fig. 3 Individual values obtained in 316 normally grown fetuses and the regression lines with the 95% confidence intervals of the preload index calculated from the IVC, the RHV, the MHV and the LHV.

IVC: $y = -0.00416x + 0.393$, $r = -0.369$, $P < 0.0001$; RHV: $y = -0.00429x + 0.421$, $r = -0.344$, $P < 0.0001$;

MHV: $y = -0.00448x + 0.436$, $r = -0.373$, $P < 0.0001$; LHV: $y = -0.00366x + 0.405$, $r = -0.332$, $P < 0.0001$;

(x, gestational week; y, preload index).

IVC, inferior vena cava; RHV, right hepatic vein; MHV, middle hepatic vein; LHV, left hepatic vein.

Table 1 The slopes and the intercepts of the regression lines for gestational age and the preload index of the IVC, the RHV, the MHV and the LHV by ANCOVA

	Slope	Intercept	Δ Intercept
IVC vs. RHV	-0.00422*	IVC, 0.395; RHV, 0.419‡	0.024
IVC vs. MHV	-0.00432*	IVC, 0.398; MHV, 0.431‡	0.033
IVC vs. LHV	-0.00391*	IVC, 0.385; LHV, 0.412‡	0.027
RHV and MHV	-0.00439*	0.428†	
RHV and LHV	-0.00398*	0.413†	
MHV and LHV	-0.00407*	0.420†	

IVC, inferior vena cava; RHV, right hepatic vein; MHV, middle hepatic vein; LHV, left hepatic vein; ANCOVA, analysis of covariance.

*common slope. † common intercept. ‡ $P < 0.0001$.

the RHV, the MHV and the LHV all decreased gradually with advancing gestational age. These results agreed with the report of Rizzo *et al.* [6] on gestational age-related changes in the preload index of the IVC.

Analysis of covariance showed that the regression lines for the preload index of the RHV, the MHV and the LHV were similar with respect to the slope and intercept. This is probably because the compliance of these veins is the same since they all run inside the liver. Hence, it may be said that the preload index of each hepatic vein will be similar at any gestational age.

The relationship between the preload index of each hepatic vein and that of the IVC was also assessed. With

regard to the slope of the regression line for each preload index, no statistical difference was detected between those of the hepatic veins and that of the IVC. On the other hand, the intercept of the regression line for each hepatic vein was significantly higher than that of the line for the IVC. Accordingly, the preload index of each hepatic vein is somewhat higher than that of the IVC at any gestational age. This is probably due to differences in compliance between the liver and the extrahepatic tissues. However, the difference ranged by analysis of covariance from 0.024 to 0.033, and such differences may be clinically insignificant, since they are too small when compared with the reported values for an abnormal preload index of the IVC, which are > 0.5 [2] and > 0.45 [19]. Therefore, we think that it is reasonable that criteria for the preload index of each hepatic vein should be the same as that of the IVC.

In human fetuses [1], the IVC blood flow waveform has a three-phase pulsatile pattern similar to that described in fetal sheep [20] and adult humans [13], comprising reverse flow during atrial contraction, early forward flow coinciding with atrial diastole and ventricular systole, and late forward flow coinciding with ventricular diastole. In fetal sheep, there is an association between changes in circulation and changes in the IVC flow pattern; increased reverse flow in the IVC during atrial contraction has been reported to suggest cardiac dysfunction [20, 21]. In adult humans, the flow patterns of the IVC and the SVC have also been reported to reflect the right atrial pressure [22-24]. In sum, changes in central venous blood velocity patterns have been considered to reflect abnormal cardiac hemodynamics in animal models and adult humans. Furthermore, increased reverse flow during atrial contraction has been reported in the IVC waveforms of compromised fetuses such as those with intrauterine growth restriction [1-8]. Hence, analysis of the flow velocity waveform in the IVC is thought to be significant for the evaluation of fetal hemodynamics.

Since the hepatic veins drain directly into the IVC just beneath the diaphragm [9-11], an association between the hemodynamics in the IVC and those in the hepatic veins seems likely. In normal adult humans [12, 13] and normal children [14], the hepatic vein blood flow pattern has been reported to show three phases similar to that of the SVC and the IVC. Also, the reverse flow of the hepatic vein flow velocity waveform has been shown to reflect right atrial pressure in adult humans, as is the case for the IVC [24]. Hecher *et al.* have reported that the

flow velocity waveforms of the RHV and the IVC are similar in normal human fetuses [15, 16]. In compromised fetuses such as those that are small for gestational age, increased reverse flow during atrial systole has been observed in the RHV as well as in the IVC [17]. Therefore, flow velocity waveforms of the hepatic vein seem to be as meaningful for hemodynamic assessment in fetuses as those of the IVC. However, there have been no previous investigations in which the flow velocity waveforms of the IVC, the RHV, the MHV and the LHV were assessed simultaneously and the relationship among these flow velocity waveforms evaluated. Accordingly, we examined gestational age-related changes of the preload index for these 4 veins, using the preload index proposed by Kanzaki *et al.* [2] as an indicator of increased reverse flow during atrial systole. Our findings suggested that the relationship between the preload index and the duration of gestation was statistically similar for all hepatic veins, and strongly resembled that for the IVC.

In fetal circulation, pulmonary blood flow is insubstantial; most of the flow to the left ventricle is supplied from the right atrium through the foramen ovale. Therefore, cardiac dysfunction in the fetus causes pressure overload or volume overload of the right atrium, which will make the blood pressure higher in the IVC and the hepatic veins. The present study suggests that analysis of flow velocity waveforms of the hepatic veins as well as of the IVC will provide a method of estimating fetal cardiac function. The normograms for the preload index of the hepatic veins that we have prepared may be utilized as an index for the estimation of fetal cardiac function.

References

1. Reed KL, Appleton CP, Anderson CF, Shenker L and Sahn DJ: Doppler studies of vena cava flows in human fetuses. Insights into normal and abnormal cardiac physiology. *Circulation* (1990) 81: 498-505.
2. Kanzaki T and Chiba Y: Evaluation of the preload condition of the fetus by inferior vena caval blood flow pattern. *Fetal Diagn Ther* (1990) 5: 168-174.
3. Gudmundsson S, Huhta JC, Wood DC, Tulzer G, Cohen AW and Weiner S: Venous Doppler ultrasonography in the fetus with nonimmune hydrops. *Am J Obstet Gynecol* (1991) 164: 33-37.
4. Rizzo G, Arduini D and Romanini C: Inferior vena cava flow velocity waveforms in appropriate- and small-for-gestational-age fetuses. *Am J Obstet Gynecol* (1992) 166: 1271-1280.
5. Rizzo G, Capponi A, Arduini D and Romanini C: The value of fetal arterial, cardiac and venous flows in predicting pH and blood gases measured in umbilical blood at cordocentesis in growth retarded fetuses. *Br J Obstet Gynaecol* (1995) 102: 963-969.
6. Rizzo G, Capponi A, Talone PE, Arduini D and Romanini C: Doppler

- indices from inferior vena cava and ductus venosus in predicting pH and oxygen tension in umbilical blood at cordocentesis in growth-retarded fetuses. *Ultrasound Obstet Gynecol* (1996) 7: 401-410.
7. Van Splunder P, Stijnen T and Wladimiroff JW: Fetal atrioventricular, venous, and arterial flow velocity waveforms in the small for gestational age fetus. *Pediatr Res* (1997) 42: 765-775.
 8. Areias JC, Matias A and Montenegro N: Venous return and right ventricular diastolic function in ARED flow fetuses. *J Perinat Med* (1998) 26: 157-167.
 9. Champetier J, Yver R and Tomasella T: Functional anatomy of the liver of the human fetus: Applications to ultrasonography. *Surg Radiol Anat* (1989) 11: 53-62.
 10. Kiserud T, Eik-Nes SH, Blaas HG and Hellevik LR: Foramen ovale: an ultrasonographic study of its relation to the inferior vena cava, ductus venosus and hepatic veins. *Ultrasound Obstet Gynecol* (1992) 2: 389-396.
 11. Huisman TWA, Gittenberger-de Groot AC and Wladimiroff JW: Recognition of a fetal subdiaphragmatic venous vestibulum essential for fetal venous Doppler assessment. *Pediatr Res* (1992) 32: 338-341.
 12. Appleton CP, Hatle LK and Popp RL: Superior vena cava and hepatic vein Doppler echocardiography in healthy adults. *J Am Coll Cardiol* (1987) 10: 1032-1039.
 13. Reynolds T and Appleton CP: Doppler flow velocity patterns of the superior vena cava, inferior vena cava, hepatic vein, coronary sinus, and atrial septal defect: A guide for the echocardiographer. *J Am Soc Echocardiogr* (1991) 4: 503-512.
 14. Meyer RJ, Goldberg SJ and Donnerstein RL: Superior vena cava and hepatic vein velocity patterns in normal children. *Am J Cardiol* (1993) 72: 238-240.
 15. Hecher K, Campbell S, Snijders R and Nicolaidis K: Reference ranges for fetal venous and atrioventricular blood flow parameters. *Ultrasound Obstet Gynecol* (1994) 4: 381-390.
 16. Hecher K and Campbell S: Characteristics of fetal venous blood flow under normal circumstances and during fetal disease. *Ultrasound Obstet Gynecol* (1996) 7: 68-83.
 17. Hecher K, Campbell S, Doyle P, Harrington K and Nicolaidis K: Assessment of fetal compromise by Doppler ultrasound investigation of the fetal circulation. Arterial, intracardiac, and venous blood flow velocity studies. *Circulation* (1995) 91: 129-138.
 18. Huisman TWA, van den Eijnde SM, Stewart PA and Wladimiroff JW: Changes in inferior vena cava blood flow velocity and diameter during breathing movements in the human fetus. *Ultrasound Obstet Gynecol* (1993) 3: 26-30.
 19. Okamura K, Murotsuki J, Kobayashi M, Yano M, Tanigawara S, Uehara S and Yajima A: Umbilical venous pressure and doppler flow pattern of inferior vena cava in the fetus. *Am J Perinatol* (1994) 11: 255-259.
 20. Reuss ML, Rudolph AM and Dae MW: Phasic blood flow patterns in the superior and inferior venae cavae and umbilical vein of fetal sheep. *Am J Obstet Gynecol* (1983) 145: 70-78.
 21. Gest AL, Martin CG, Moise AA and Hansen TN: Reversal of venous blood flow with atrial tachycardia and hydrops in fetal sheep. *Pediatr Res* (1990) 28: 223-226.
 22. Wexler L, Bergel DH, Gabe IT, Makin GS and Mills CJ: Velocity of blood flow in normal human venae cavae. *Circ Res* (1968) 23: 349-359.
 23. Appleton CP, Hatle LK and Popp RL: Demonstration of restrictive ventricular physiology by Doppler echocardiography. *J Am Coll Cardiol* (1988) 11: 757-768.
 24. Ommen SR, Nishimura RA, Hurrell DG and Klarich KW: Assessment of right atrial pressure with 2-dimensional and Doppler echocardiography: A simultaneous catheterization and echocardiographic study. *Mayo Clin Proc* (2000) 75: 24-29.