

Acta Medica Okayama

Volume 55, Issue 6

2001

Article 3

DECEMBER 2001

Expression of caspase-3 and -9 relevant to cartilage destruction and chondrocyte apoptosis in human osteoarthritic cartilage.

Masatsugu Matsuo*

Keiichiro Nishida†

Aki Yoshida‡

Takuro Murakami**

Hajime Inoue††

*Okayama University,

†Okayama University,

‡Okayama University,

**Okayama University,

††Okayama University,

Expression of caspase-3 and -9 relevant to cartilage destruction and chondrocyte apoptosis in human osteoarthritic cartilage.*

Masatsugu Matsuo, Keiichiro Nishida, Aki Yoshida, Takuro Murakami, and Hajime Inoue

Abstract

To clarify the involvement of the caspase family in the pathway of NO-induced chondrocyte apoptosis, osteoarthritis (OA) cartilage obtained from 8 patients undergoing total hip arthroplasty were used for histopathological study. Cartilage samples taken from non-fibrillated areas of femoral head resected during surgery for femoral neck fracture were used for comparison. DNA fragmentation of chondrocytes was detected by the nick end-labeling (TUNEL) method. Apoptosis was further confirmed by transmission electron microscopy. The distributions of nitrotyrosine (NT), caspase-3, and -9 were examined immunohistochemically. The populations of apoptotic as well as NT-, caspase-3-, and -9-positive cells were quantified by counting the number of cells in the superficial, middle, and deep layers, respectively. The TUNEL-positive cells were observed primarily in superficial proliferating chondrocytes, clustering chondrocytes, and deep-layer chondrocytes of OA cartilage. Few positive cells were seen in the proliferating chondrocytes in the middle layer. Positive reactions for caspase-3 and -9 were observed in chondrocytes in similar areas. Histological OA grade showed significant correlations with the mean populations of apoptotic chondrocytes (% apoptosis) over the 3 areas. The populations of NT-positive cells (% NT) over the same areas also showed significant correlation with OA grade. Positivity for caspase-3 closely correlated with the OA grade, % apoptosis and %NT. It was concluded that caspase-3 and -9 could play a role in NO-induced chondrocyte apoptosis in OA cartilage.

KEYWORDS: apoptosis, caspase, nitric oxide, osteoarthritis, chondrocyte

*PMID: 11779095 [PubMed - indexed for MEDLINE]

Copyright (C) OKAYAMA UNIVERSITY MEDICAL SCHOOL

Original Article

Expression of Caspase-3 and -9 Relevant to Cartilage Destruction and Chondrocyte Apoptosis in Human Osteoarthritic Cartilage

Masatsugu Matsuo, Keiichiro Nishida*, Aki Yoshida, Takuro Murakami^a, and Hajime Inoue

Department of Orthopaedic Surgery, and ^aDepartment of Anatomy II, Okayama University Medical School, Okayama 700-8558, Japan

To clarify the involvement of the caspase family in the pathway of NO-induced chondrocyte apoptosis, osteoarthritis (OA) cartilage obtained from 8 patients undergoing total hip arthroplasty were used for histopathological study. Cartilage samples taken from non-fibrillated areas of femoral head resected during surgery for femoral neck fracture were used for comparison. DNA fragmentation of chondrocytes was detected by the nick end-labeling (TUNEL) method. Apoptosis was further confirmed by transmission electron microscopy. The distributions of nitrotyrosine (NT), caspase-3, and -9 were examined immunohistochemically. The populations of apoptotic as well as NT-, caspase-3-, and -9-positive cells were quantified by counting the number of cells in the superficial, middle, and deep layers, respectively. The TUNEL-positive cells were observed primarily in superficial proliferating chondrocytes, clustering chondrocytes, and deep-layer chondrocytes of OA cartilage. Few positive cells were seen in the proliferating chondrocytes in the middle layer. Positive reactions for caspase-3 and -9 were observed in chondrocytes in similar areas. Histological OA grade showed significant correlations with the mean populations of apoptotic chondrocytes (% apoptosis) over the 3 areas. The populations of NT-positive cells (%NT) over the same areas also showed significant correlation with OA grade. Positivity for caspase-3 closely correlated with the OA grade, % apoptosis and %NT. It was concluded that caspase-3 and -9 could play a role in NO-induced chondrocyte apoptosis in OA cartilage.

Key words: apoptosis, caspase, nitric oxide, osteoarthritis, chondrocyte

Osteoarthritis (OA) is characterized by the destruction of articular cartilage, accompanied by the development of osteochondrocytes [1]. Recent studies have found that apoptotic chondrocyte death occurs more frequently in OA lesional than in non lesional cartilage [2-4]. Because chondrocytes are the only specific cell

type in cartilage responsible for the production and maintenance of the extracellular matrix, chondrocyte cell death seems to be a crucial event in the pathogenesis of OA.

In OA joints, nitric oxide (NO) has been implicated as an important mediator of inflammation. Proinflammatory cytokines such as IL-1 or TNF- α or increased mechanical stress stimulate chondrocytes to produce NO by activation of the inducible form of NO synthase (iNOS) [5]. Blanco *et al.* [6] first demonstrated that NO is the

Received March 26, 2001; accepted June 7, 2001.

*Corresponding author. Phone: +81-86-235-7273; Fax: +81-86-223-9727
E-mail: knishida@po.harenet.ne.jp (K. Nishida)

primary inducer of apoptosis of human chondrocytes. According to the report by Hashimoto *et al.* [7], the prevalence of apoptotic chondrocytes correlates significantly with nitrite levels in the tissue and the histological OA grade in the rabbit OA model. Excess NO can cause DNA strand-breaks in chondrocytes, lipid and protein modification, and induction of apoptosis. However, there are few studies demonstrating the signaling pathway of chondrocyte apoptosis after NO exposure. Pelletier *et al.* [8] have reported a reduction in chondrocyte apoptosis and caspase-3 levels after treatment by L-NIL, a selective inhibitor of iNOS in the experimental canine model of OA. In the current study, the authors first demonstrated the correlation of nitrotyrosine and caspase-3 and -9 levels with histological OA grade, and then the stainability of chondrocytes for the transferase-mediated biotinylation (TUNEL) method using human OA cartilage. The data suggests an involvement of the caspase family in NO-induced chondrocyte apoptosis, resulting in the breakdown of human OA cartilage.

Materials and Methods

Tissue preparation. Human OA cartilage was obtained at the time of total joint-replacement surgery from 8 patients with OA. Comparison samples were obtained from the femoral head of 4 patients with femoral neck fracture. Subsequently, 18 cartilage samples from the femoral head were obtained from 12 patients. The age of the patients ranged from 58–88 (mean 75.4) years.

Cartilage samples with subchondral bone were fixed with 4% paraformaldehyde (PFA) containing 0.1% glutaraldehyde (GA) in 0.1% phosphate-buffered saline (PBS) immediately after surgery, decalcified in 0.3 M EDTA (pH 7.5) for 2–3 weeks, and embedded in paraffin. Serial sections (4.5 μ m) were cut and stored at 37 °C until use for histologic evaluation. Smaller additional blocks (1 \times 1 \times 1 mm) from 5 of the 8 patients with OA were embedded in hydrophilic resin (LR-White) for electron microscopic examination.

Histological evaluation of OA severity. All sections were stained with safranin O and observed by light microscopy. Histopathological classification of the severity of osteoarthritic lesions was graded on a scale of 0–13, using the modified Mankin score reported by van der Sluijs *et al.* [9]. The modified Mankin score is a combined score assessing structure (0–6 points), cellular

abnormalities (0–3 points), and matrix-staining (0–4 points). As a result, 0 points represent normal and 13 represent the most severe cartilage lesions. The Mankin score point-range of 14 points was divided into 3 sub-ranges in the current study, OA (0–2), OA (3–8) and OA (9–13).

Detection of apoptosis. Deparaffinized sections were pretreated with bovine testicular hyaluronidase (1 mg/ml, 60 min at 37 °C) in 0.1% PBS, and the endogenous peroxidase was blocked with 0.3% H₂O₂ in PBS at room temperature for 30 min. DNA fragmentation in chondrocytes was detected by terminal deoxynucleotidyl transferase (TdT)-mediated deoxyuridine triphosphate (dUTP) biotinylation (TUNEL) methods. Briefly, DNA was end-labeled with digoxigenin-labeled dUTP using terminal transferase, and detected with peroxidase-conjugated antidigoxigenin antibody at 37 °C for 1 h. Sections were counterstained with methyl green. Incubation without TdT served as the negative control.

Immunohistochemistry. Deparaffinized sections were pretreated with bovine testicular hyaluronidase (1 mg/ml, 60 min at 37 °C) in 0.1% PBS. The endogenous peroxidase was blocked with 0.3% H₂O₂ in PBS at room temperature for 30 min, and incubated in normal goat serum at room temperature for 30 min. The sections were then treated with proteinase K (20 μ g/ml, Boehringer Mannheim, Germany) for 10 min at room temperature.

The presence and distribution of nitrotyrosine (NT), caspase-3 and caspase-9 were determined by immunohistochemistry using the avidin-biotin-peroxidase complex (ABC) method. Rabbit polyclonal anti-NT antibody (1:50 dilution, Upstate, Lake Placid, NY, USA), rabbit polyclonal anti-caspase-3 active antibody (1:500 dilution, R&D Systems, Minneapolis, MN, USA) and rabbit polyclonal anti-caspase-9 antibody (1:250 dilution, R&D Systems, Minneapolis, MN, USA) were used as primary antibody at 4 °C overnight. A biotinylated goat anti-rabbit antibody was used as the secondary antibody. The reaction was visualized by diaminobenzidine (DAB), resulting in a brown color. Methyl green was used for the counterstaining. Stained sections incubated with normal rabbit nonimmune serum or without primary antibodies were used as negative controls.

Quantification of TUNEL, and nitrotyrosine-, caspase-3-, and caspase-9-positive cells. In TUNEL staining, the chon-

drocytes with strongly stained nuclei were regarded as positive cells. In NT, caspase-3 and -9 immunostaining, chondrocytes with definite, diffusely stained cytoplasm or nuclei were regarded as positively stained. Each cartilage section was divided into 3 fields; superficial, middle and deep layers. The populations of apoptotic as well as NT-, caspase-3-, and -9-positive cells were quantified by counting the number of cells within the superficial, middle, and deep layers respectively, at $\times 200$ magnification. The number of positive chondrocytes was divided by the total number of chondrocytes within all 3 layers to calculate the positive chondrocyte ratio.

Statistical Analysis. The statistical significances of the relationships among histological-histochemical OA grade, TUNEL-positive cells, and NT-, caspase-3-, and -9-positive cells were analyzed using simple regression and Spearman's rank correlation test. Statistical analyses were performed using Macintosh StatView-J 5.0 (SAS Institute Inc., Cary, NC, USA).

Electron microscopy. Semi-thin sections were stained first with toluidine blue, and areas containing chondrocytes with morphologically apoptotic features with nuclear condensation were chosen for transmission electron microscopic (TEM) examination. The ultra-thin sections were cut, post-fixed in 1% glutaraldehyde, stained for 30 min with aqueous uranyl acetate and lead citrate, and examined via TEM (Hitachi type 7100, Tokyo, Japan).

Immunoelectron microscopy for caspase-9. To determine the expression of caspase-9 in morphologically apoptotic chondrocytes, immunoelectron microscopy was carried out. The ultra-thin sections were incubated in normal goat serum at room temperature for 30 min. The sections were secondarily incubated with polyclonal antibodies against caspase-9 (1:50 dilution; 10 $\mu\text{g}/\text{ml}$) at 4°C for overnight, and then with gold-conjugated anti-rabbit IgG (1:30 dilution, British BioCell International, Cardiff, UK) at room temperature for 60 min. The ultra-thin sections were post-fixed, stained, and observed via TEM as described above. For the negative controls, primary antibodies were omitted from the protocol.

Results

OA grade and TUNEL-positive chondrocytes. All cartilage from comparison samples showing a mild, irregular surface or slightly reduced

staining for safranin O in the radial layer had a score of 0–2. The means of the modified Mankin scores for the OA cartilage and for the comparison were 6.8 ± 2.3 and 1.2 ± 0.8 , respectively. Small clusters of chondrocytes were found in the superficial layer of OA (3–8) cartilage. Larger and more numerous clusters were found in the middle layer of OA (9–13) cartilage. While the comparison cartilage rarely showed apoptotic cells (TUNEL-positive ratio, $3.5 \pm 3.0\%$), the OA cartilage frequently contained apoptotic chondrocytes (TUNEL-positive ratio, $32.4 \pm 18.7\%$). The TUNEL-positive chondrocytes observed in the 3 layers of OA cartilage were primarily proliferating chondrocytes in the superficial layer, and there were few proliferating chondrocytes in the middle layer. Proliferating chondrocytes showed a minimal positive reaction, primarily in the superficial layer. The number of TUNEL-positive chondrocytes increased with cartilage degradation (Fig. 1-a, e, i).

Electron microscopy of apoptotic chondrocytes confirmed nuclear changes that included chromatin condensation and a shrunken and convoluted nucleus. The cytoplasmic membrane was irregular, with multiple blebs, and the cell remnants were surrounded by membrane-enclosed units, probably representing apoptotic bodies (Fig. 2-a, b).

Immunohistochemistry. NO reacts with the superoxide radical to form peroxynitrite. In tissues, peroxynitrite leads to the nitration of aromatic amino acid residues, and the presence of these may be a cause of peroxynitrite-mediated, NO-dependent damage *in vivo*. Nitrotyrosine (NT)-positive chondrocytes were detected in superficial proliferating chondrocytes and clustering chondrocytes, as well as chondrocytes in the deep layer (NT-positive ratio, $32.9 \pm 13.1\%$) (Fig. 1-b, f, j). The distribution of NT in all OA samples was similar to that of apoptotic chondrocytes and areas with PG depletion. The expression of active caspase-3 was observed in only a small percentage of chondrocytes in the superficial layer of comparison cartilage (caspase-3-positive ratio, $6.8 \pm 2.0\%$) (Table. 1). However, in OA cartilage, a significantly higher level of caspase-3-positive chondrocytes were observed in superficial proliferating chondrocytes, and clustering chondrocytes and chondrocytes in the deep layer (caspase-3-positive ratio, $33.7 \pm 12.7\%$) (Fig. 1-c, g, k).

The distribution of caspase-9-positive chondrocytes was similar to that of caspase-3-positive chondrocytes in OA cartilage (caspase-9-positive ratio, $20.2 \pm 9.8\%$).

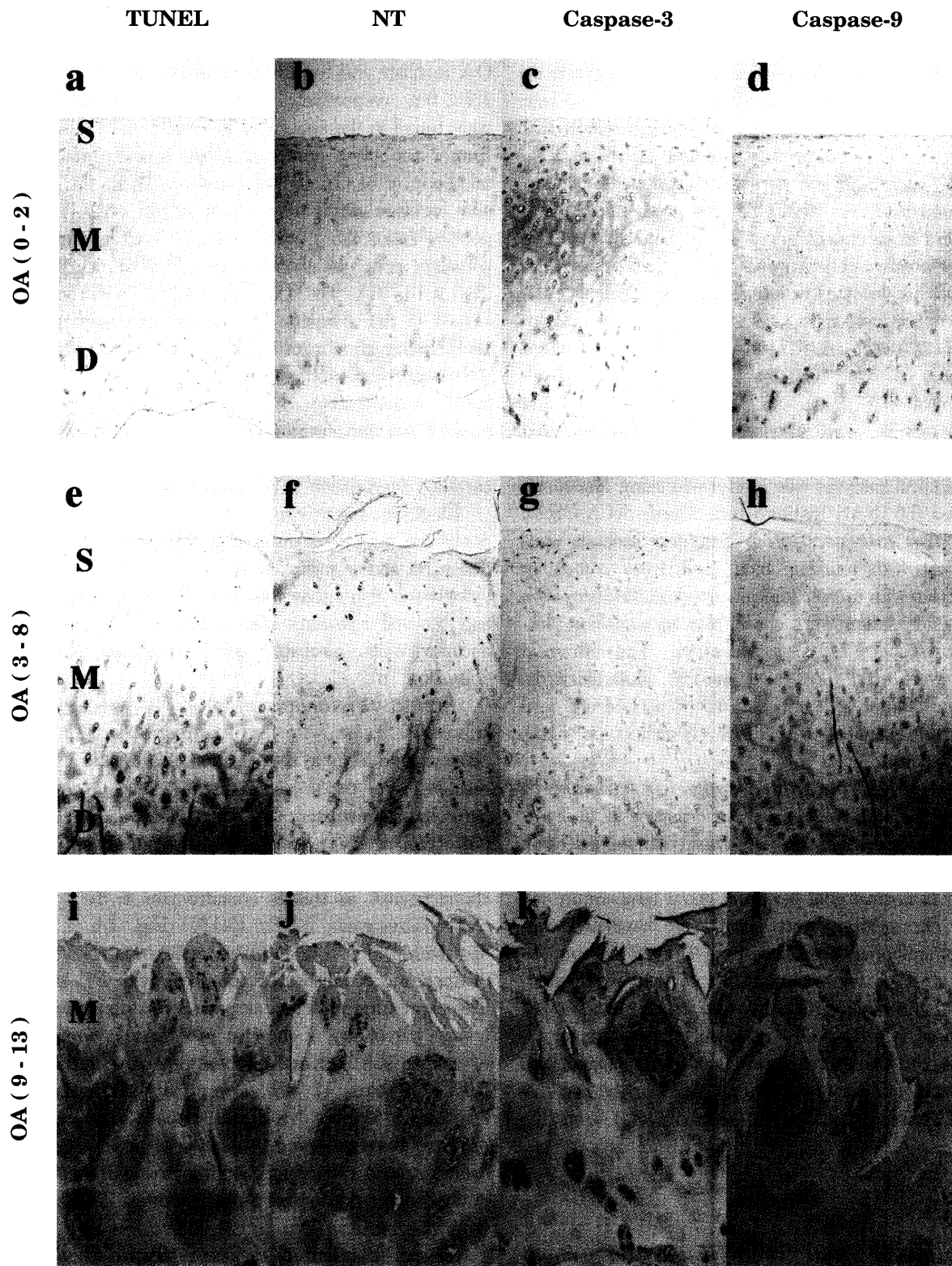


Fig. 1

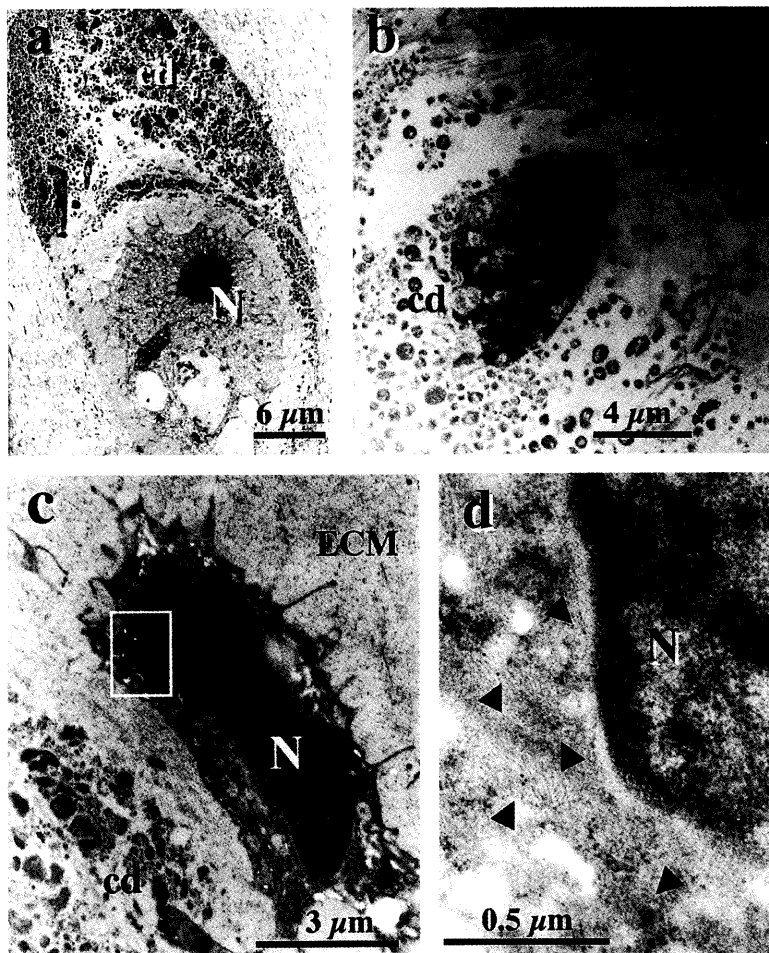


Fig. 2 Transmission electron microscopy (TEM) of apoptotic chondrocytes in OA cartilage. An apoptotic chondrocyte with chromatin condensation and a shrunken and convoluted nucleus (a). Post apoptotic changes of chondrocytes with cell fragmentation and apoptotic bodies. In later stage apoptotic chondrocytes, the pericellular matrix was absent, and the cell remnants appeared to be embedded in the extracellular matrix (b). Immunoelectron microscopic localization of caspase-9. The gold particles (allow head) can be seen in the convoluted nucleus as well as the cytoplasm (d) of morphologically apoptotic chondrocytes (c). N, nucleus; ECM, extra cellular matrix; cd, cell debris.

Fig. 1 The distribution of chondrocytes positive for TUNEL staining, and immunohistochemistry for nitrotyrosine (NT), active caspase-3, and caspase-9 in the 3 subranges of OA cartilage. Rare apoptotic chondrocytes, TUNEL-positive staining (a), expression of NT, active caspase-3, and caspase-9 were observed in only a small percentage of chondrocytes in the superficial layer of OA (0-2) (b-d). In OA (3-8) cartilage, positive reactions for TUNEL staining were observed, especially in the superficial proliferating chondrocytes and small clusters of chondrocytes, but not in the middle layer (e). NT-positive chondrocytes were detected in superficial proliferating chondrocytes, clustering chondrocytes, and chondrocytes in the deep layer of OA (3-8) cartilage (f). In OA (3-8) cartilage, a higher level of caspase-3-positive chondrocytes was observed in superficial proliferating chondrocytes, clustering chondrocytes, and chondrocytes in the deep layer (g). In OA (3-8) cartilage, caspase-9-positive chondrocytes were observed, especially in the superficial layer. Few caspase-9-positive chondrocytes were observed in the middle and deep layers (h). In OA (9-13) cartilage, the superficial layer was lost, and chondrocytes forming larger and more numerous clusters were found to be TUNEL-positive (i). The distribution of NT was similar to that of TUNEL-positive chondrocytes (j). A significantly higher level of caspase-3-positive chondrocytes was observed in the clustering chondrocytes and chondrocytes in the deep layer in OA (9-13) cartilage than in OA (3-8) cartilage (k). More numerous caspase-9-positive chondrocytes were observed in OA (9-13) cartilage than in OA (3-8) cartilage. The distribution of caspase-9 was similar to that of caspase-3-positive chondrocytes in OA (9-13) cartilage (l). (Original magnification; a-h: $\times 40$, i-l: $\times 100$). S, superficial layer; M, middle layer; D, deep layer.

Table 1 Population of positive chondrocytes for TUNEL staining and immunohistochemistry for NT, active caspase-3, and caspase-9-positive chondrocytes in OA cartilage

	OA (0-2)			OA (3-8)			OA (9-13)		
	S	M	D	S	M	D	S	M	D
TUNEL	—	—	±	++	+	+	n.c	+++	+
NT	±	±	±	++	+	++	n.c	++	++
Caspase-3	±	—	±	++	+	++	n.c	++	+++
Caspase-9	—	—	—	++	±	±	n.c	++	+

D, deep layer. (—) 0-5% positive chondrocytes, (±) 6-15% positive chondrocytes, (+) 16-30% positive chondrocytes, (++) 31-50% positive chondrocytes, (+++) > 50% positive chondrocytes. n.c, not counted because the superficial layer was destroyed by OA; M, middle layer; S, superficial layer.

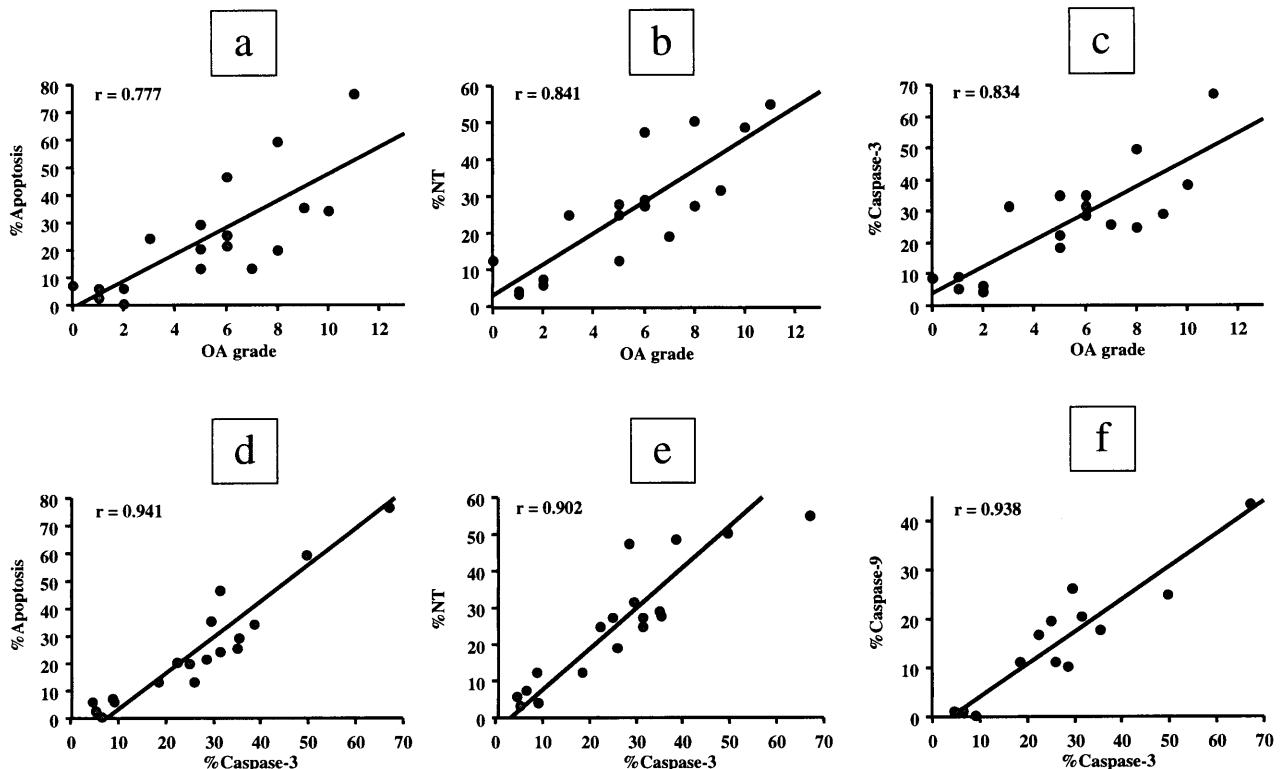


Fig. 3 Correlations between histological OA grade and the population of apoptotic as well as NT-, active caspase-3-, and caspase-9-positive chondrocytes (18 samples). OA grade (Mankin score) had significant correlations ($P < 0.01$) with the percentage of apoptotic chondrocytes (% apoptosis) ($r = 0.777$), NT-positive cells (% NT) ($r = 0.841$) and active caspase-3-positive cells (% caspase-3) ($r = 0.834$) (a-c). % caspase-3 also had significant correlations ($P < 0.01$) with % apoptosis ($r = 0.941$), % NT ($r = 0.902$) and % caspase-9 ($r = 0.938$) (d-f).

However, comparison cartilage showed a minimal percentage of caspase-9-positive chondrocytes (caspase-9-positive ratio, $0.7 \pm 0.6\%$) (Fig. 1-d, h, l) (Table 1). In the immunoelectron microscopic study, gold-labeled caspase-9 was shown to have both cytoplasmic and nuclear localization in morphologically apoptotic chon-

drocytes (Fig. 2-c, d). In chondrocytes with a morphologically normal appearance, gold deposits could not be detected (data not shown).

Relationship between OA grade, TUNEL, and nitrotyrosine-, caspase-3-, and caspase-9-positive chondrocytes. The mean population of

apoptotic chondrocytes in the following analyses included those in all layers of each sample. Histological OA grade (0-11) showed significant correlations with the mean population of apoptotic chondrocytes (% apoptosis) of comparison and OA cartilage ($r = 0.777$, $P = 0.0002$) (Fig. 3-a) (Table 1). The population of NT-positive cells (% NT) showed significant correlation with OA grade ($r = 0.841$, $P < 0.0001$) (Fig. 3-b). The positiveness for caspase-3 closely correlated with OA grade ($r = 0.834$, $P < 0.0001$) (Fig. 3-c), % apoptosis ($r = 0.941$, $P < 0.0001$) (Fig. 3-d) and %NT ($r = 0.902$, $P < 0.0001$) (Fig. 3-e). The positiveness for caspase-9 showed significant correlation with % caspase-3 ($r = 0.938$, $P < 0.0001$) (Fig. 3-f) (Table 1).

Discussion

Increasing amounts of evidence indicate that chondrocyte apoptosis plays an important role in cartilage development, aging and disease [6]. In addition, elevated production of NO has been linked with chondrocyte apoptosis in OA cartilage both *in vivo* and *in vitro* [6, 7, 10, 11]. Thus, proper regulation of the NO pathway or chondrocyte apoptosis is likely to lead to novel therapeutic approaches for OA. However, the signaling pathway of chondrocyte apoptosis after NO exposure has not been completely elucidated. Several possibilities lie in 1) direct or indirect DNA damage, 2) inactivation of antioxidant enzymes and 3) mitochondria damage resulting in cytochrome c release and activation of members of the caspase family.

The caspase family of enzymes plays an essential role in cell apoptosis [12]. Caspase-9 is activated in response to agents or insults inducing the release of cytochrome c from the inner mitochondrial membrane. Caspase-3, one of the effector caspases, is activated by initiator caspases such as caspase-8 and -9, and cleaves vital intracellular proteins. Caspase-activated deoxyribonuclease (CAD) is activated by cleavage of the CAD inhibitor (ICAD) by caspase-3, and mediates oligonucleosome fragmentation [13]. In the present study, the authors first demonstrated immunohistochemically that the active form of caspase-3 can be detected primarily in superficial and deep-zone chondrocytes. Caspase-3-positive chondrocytes are distributed where cartilage degradation is progressive. The correlation between the caspase-3- and TUNEL-positive cell ratio with OA grade supports the hypothesis that caspase-3 plays a role in chondrocyte apoptosis in OA

cartilage. The significant correlation between the caspase-3- and -9-positive chondrocyte ratio suggests the role of caspase-9 in the activation of caspase-3. Moreover, the correlation between caspase-3 and nitrotyrosine levels in the tissue strongly suggests that increased production of NO can activate the caspase-mediated apoptosis cascade. Kim *et al.* have reported an upregulation of Bax protein in the OA chondrocyte, whereas the levels of Bcl-2 protein apparently do not change in the course of OA [2]. These findings lead us to hypothesize that NO might cause mitochondrial damage in chondrocytes and induce Bax overexpression. An imbalance of Bax and Bcl-2 can cause a release of cytochrome c to activate caspase-9, followed by an activation of caspase-3, an effector molecule of apoptosis.

Pelletier *et al.* have demonstrated in the experimental OA canine model that treatment with N-iminoethyl-L-Lysine (L-NIL), a selective inhibitor of iNOS, reduces the progression of macroscopic cartilage lesions in a dose-dependent manner, both on femoral condyles and on tibial plateaus [14, 15]. The report that L-NIL reduces chondrocyte apoptosis and caspase-3 levels but does not affect Bcl-2, supports the results of the current study. However, L-NIL failed to completely inhibit either chondrocyte apoptosis or progression of OA in the experimental model. Van de Loo *et al.* have reported that cartilage loss progressively increases over time in zymosan-induced gonarthrosis of iNOS-deficient mice. It should be noted that continuous or complete inhibition of iNOS would lead to serious infectious complications [16]. More recently, Lee *et al.* have demonstrated that a caspase -3/-7-selective inhibitor successfully inhibits chondrocyte apoptosis *in vitro* [17]. The current results support their opinion that the inhibition of caspases might be a novel therapeutic approach to prevent the progression of OA. Further, extensive *in vivo* study of possible treatments of OA in various models by caspase inhibitors is required before such an approach could be considered for clinical application.

Acknowledgments. The authors wish to thank Mr. N. Kishimoto in the Central Research Laboratory of Okayama University Medical School for his technical assistance. We would also like to thank Mrs. Cherie McCown for editing drafts of the manuscript. This work was supported in part by a grant-in aid to KN from the Ministry of Education, Science, Sports, Culture and Technology, Japan (11770803).

References

1. Gardner DL: Osteoarthritis and allied diseases; in Pathological Basis of the Connective Tissue Diseases, Edward Arnold, London (1992) pp 842-923.
2. Kim HA, Lee YJ, Seong SC, Choe KW and Song YW: Apoptotic chondrocyte death in human osteoarthritis. *J Rheumatol* (2000) **27**, 455-462.
3. Heraud F, Heraud A and Harmand MF: Apoptosis in normal and osteoarthritic human articular cartilage. *Ann Rheum Dis* (2000) **59**, 959-965.
4. Kouri JB, Aguilera JM, Reyes J, Lozoya KA and Gonzalez S: Apoptotic chondrocytes from osteoarthrotic human articular cartilage and abnormal calcification of subchondral bone. *J Rheumatol* (2000) **27**, 1005-1019.
5. Clancy RM, Amin AR and Abramson SB: The role of nitric oxide in inflammation and immunity. *Arthritis Rheum* (1998) **41**, 1141-1151.
6. Blanco FJ, Ochs RL, Schwarz H and Lotz M: Chondrocyte apoptosis induced by nitric oxide. *Am J Pathol* (1995) **146**, 75-85.
7. Hashimoto S, Takahashi K, Amiel D, Coutts RD and Lotz M: Chondrocyte apoptosis and nitric oxide production during experimentally induced osteoarthritis. *Arthritis Rheum* (1998) **41**, 1266-1274.
8. Pelletier JP, Jovanovic DV, Lascau-Coman V, Fernandes JC, Manning PT, Connor JR, Currie MG and Martel-Pelletier J: Selective inhibition of inducible nitric oxide synthase reduces progression of experimental osteoarthritis *in vivo*: Possible link with the reduction in chondrocyte apoptosis and caspase 3 level. *Arthritis Rheum* (2000) **43**, 1290-1299.
9. van der Sluijs JA, Geesink RG, van der Linden AJ, Bulstra SK, Kuyper R and Drukker J: The reliability of the Mankin score for osteoarthritis. *J Orthop Res* (1992) **10**, 58-61.
10. Amin AR and Abramson SB: The role of nitric oxide in articular cartilage breakdown in osteoarthritis. *Curr Opin Rheumatol* (1998) **10**, 263-268.
11. Lotz M: The role of nitric oxide in articular cartilage damage. *Rheum Dis Clin North Am* (1999) **25**, 269-282.
12. Martin SJ and Green DR: Protease activation during apoptosis: Death by a thousand cuts? *Cell* (1995) **82**, 349-52.
13. Enari M, Sakahira H, Yokoyama H, Okawa K, Iwamatsu A and Nagata S: A caspase-activated DNase that degrades DNA during apoptosis, and its inhibitor ICAD. *Nature* (1998) **391**, 43-50.
14. Pelletier JP, Lascau-Coman V, Jovanovic D, Fernandes JC, Manning P, Connor JR, Currie MG and Martel-Pelletier J: Selective inhibition of inducible nitric oxide synthase in experimental osteoarthritis is associated with reduction in tissue levels of catabolic factors. *J Rheumatol* (1999) **26**, 2002-2014.
15. Pelletier J, Jovanovic D, Fernandes JC, Manning P, Connor JR, Currie MG and Martel-Pelletier J: Reduction in the structural changes of experimental osteoarthritis by a nitric oxide inhibitor. *Osteoarthritis Cartilage* (1999) **4**, 416-418.
16. van de Loo FA, Arntz OJ, van Enckevort FH, van Lent PL and van den Berg WB: Reduced cartilage proteoglycan loss during zymosan-induced gonarthrosis in NOS2-deficient mice and in anti-interleukin-1-treated wild-type mice with unabated joint inflammation. *Arthritis Rheum* (1998) **41**, 634-646.
17. Lee D, Long SA, Adams JL, Chan G, Vaidya KS, Francis TA, Kikly K, Winkler JD, Sung CM, Debouck C, Richardson S, Levy MA, DeWolf WE Jr, Keller PM, Tomaszek T, Head MS, Ryan MD, Haltiwanger RC, Liang PH, Janson CA, McDevitt PJ, Johanson K, Concha NO, Chan W, Abdel-Meguid SS, Badger AM, Lark MW, Nadeau DP, Suva LJ, Gowen M and Nuttall ME: Potent and selective nonpeptide inhibitors of caspases 3 and 7 inhibit apoptosis and maintain cell functionality. *J Biol Chem* (2000) **275**, 16007-16014.