

Acta Medica Okayama

Volume 58, Issue 3

2004

Article 2

JUNE 2004

Rapid response of hepatocyte growth factor in pulmonary ischemia in a rat model.

Kazunobu Nagai*

Motoi Aoe[†]

Nobuyoshi Shimizu[‡]

*Okayama University,

[†]Okayama University,

[‡]Okayama University,

Rapid response of hepatocyte growth factor in pulmonary ischemia in a rat model.*

Kazunobu Nagai, Motoi Aoe, and Nobuyoshi Shimizu

Abstract

Hepatocyte growth factor (HGF) is a multifunctional factor implicated in tissue regeneration, wound healing, and angiogenesis. HGF was initially thought to be liver-specific, but it has become clear that HGF acts on alveolar type II cells and bronchial epithelial cells. This study was conducted to determine the role of HGF in pulmonary ischemia in a rat model. The first increase of the plasma HGF level was noted 30 min after pulmonary ischemia, and reached a peak at 12 h. Real-time reverse transcription polymerase chain reaction (Real-time RT-PCR) revealed that the HGF messenger RNA (mRNA) expression in the injured left lung was markedly increased at 1, 6, and 12 h after pulmonary ischemia ($P < 0.05$). The interleukin-1beta (IL-1beta) mRNA expression, one of the inflammatory cytokines which induces HGF expression, was markedly increased at 1 h in the injured left lung ($P = 0.0007$). Therefore, we considered that HGF might be mainly induced by paracrine mechanisms in pulmonary ischemia. In conclusion, we have shown that the expression of HGF was induced in pulmonary ischemia, and may be a useful biological marker for the early diagnosis.

KEYWORDS: hepatocyte growth factor (HGF), interleukin-1 β (IL-1 β), pulmonary ischemia, enzyme-linked immunosorbent assay (ELISA), real-time reverse transcription polymerase chain reaction (real-time RT-PCR)

*PMID: 15471433 [PubMed - indexed for MEDLINE]

Original Article

Rapid Response of Hepatocyte Growth Factor in Pulmonary Ischemia in a Rat Model

Kazunobu Nagai*, Motoi Aoe, and Nobuyoshi Shimizu

*Department of Cancer and Thoracic Surgery, Okayama University Graduate School of
Medicine and Dentistry, Okayama 700-8558, Japan*

Hepatocyte growth factor (HGF) is a multifunctional factor implicated in tissue regeneration, wound healing, and angiogenesis. HGF was initially thought to be liver-specific, but it has become clear that HGF acts on alveolar type II cells and bronchial epithelial cells. This study was conducted to determine the role of HGF in pulmonary ischemia in a rat model. The first increase of the plasma HGF level was noted 30 min after pulmonary ischemia, and reached a peak at 12 h. Real-time reverse transcription polymerase chain reaction (Real-time RT-PCR) revealed that the HGF messenger RNA (mRNA) expression in the injured left lung was markedly increased at 1, 6, and 12 h after pulmonary ischemia ($P < 0.05$). The interleukin-1 β (IL-1 β) mRNA expression, one of the inflammatory cytokines which induces HGF expression, was markedly increased at 1 h in the injured left lung ($P = 0.0007$). Therefore, we considered that HGF might be mainly induced by paracrine mechanisms in pulmonary ischemia. In conclusion, we have shown that the expression of HGF was induced in pulmonary ischemia, and may be a useful biological marker for the early diagnosis.

Key words: hepatocyte growth factor (HGF), interleukin-1 β (IL-1 β), pulmonary ischemia, enzyme-linked immunosorbent assay (ELISA), real-time reverse transcription polymerase chain reaction (real-time RT-PCR)

Pulmonary embolism is a common and often fatal postoperative complication. Late diagnosis and delayed management of this condition is associated with pulmonary infarction, but an early diagnosis is very difficult to make. The common clinical manifestation in pulmonary embolisms are frequently inconsistent and often vague. Routine laboratory examinations are also nonspecific. A chest film, arterial saturation, and electrocardiogram may be helpful in excluding other cardiorespiratory diseases, but are frequently unreliable in establishing an objective diagnosis of pulmonary embolism.

Although pulmonary arteriography is the gold standard for the diagnosis of pulmonary embolism, it requires expensive equipment and trained radiologists, and the patient could be show sensitivity to the contrast agents used. Therefore, it is necessary to use a more convenient and reliable method of diagnosing pulmonary embolism.

Hepatocyte growth factor (HGF) has been purified from the serum of partially hepatectomized rats [1], rats platelets [2], and human plasma [3, 4]. Mature heterodimer HGF derives from a single chain precursor of 728 amino acids by proteolytic processing, and has 4 kringle domains in the α -chain and the serine protease-like domain in the β chain [3]. Notwithstanding the original concept of HGF as potent mitogen for hepatocytes [1-4], HGF was widely distributed, and the HGF messen-

Received July 14, 2003; accepted December 19, 2003.

*Corresponding author. Phone: +81-86-472-8111; Fax: +81-86-472-8116
E-mail: nagaidr@ybb.ne.jp (K. Nagai)

ger RNA (mRNA) is found in a relatively high concentration in the rat lung as well as in the rat liver [5, 6]. *In vitro*, HGF stimulates the DNA synthesis of the alveolar type II cells [5, 7]. *In vivo*, the HGF mRNA expression is rapidly induced, and the DNA synthesis of alveolar type II cells and bronchial epithelial cells are increased in the lung after acute lung injury caused by the intratracheal administration of hydrochloride solution [7]. Furthermore, the intravenous and intratracheal administration of recombinant HGF stimulates DNA synthesis of alveolar type II cells in the rat lung after acute lung injury [8, 9]. In humans, the HGF levels are elevated in the serum and bronchoalveolar lavage fluid of patients with lung disease [6, 10-12]. These findings suggest that HGF acts as a pulmotrophic factor for pulmonary injury.

Despite the recent increase in information on HGF, no study has yet been conducted to examine the relationship between pulmonary ischemia and HGF expression. To evaluate the HGF response following pulmonary ischemia, we measured the plasma HGF level, the tissue HGF mRNA expression, and the tissue interleukin-1 β mRNA (IL-1 β mRNA) expression, using the rat model of pulmonary ischemia.

Materials and Methods

Animals. Adult male Wistar rats weighing 280 to 320 g were purchased from JAPAN SLC, Inc., (Shizuoka, Japan) and maintained at a constant temperature (22 °C), humidity (40%), and light cycle (6:00 A.M. to 6:00 P.M.) with standard laboratory food and tap water. All of the experimental procedures were reviewed and approved by the Guidelines for Animal Experimentation of the Okayama University Medical School.

Pulmonary ischemia model and sham-operated model. To induce pulmonary ischemia, we anesthetized the animals with pentobarbital (50 mg/kg IP), and intubated the rats by translaryngeal illumination with a 14-gauge angiocatheter. Ventilation was accomplished with a volume-controlled ventilator (Rodent Ventilator model 683; Harvard Apparatus Co., South Natick, MA, USA) at a rate of 60 strokes/min and a tidal volume of 10 ml/kg. The left thorax was opened at the third intercostal space, and the left pulmonary artery was exposed and ligated at the middle with 3-0 silk braid. The thoracotomy incision was closed in 3 layers with 3-0 silk braid, when the animals were alert and breathing spontaneously. The endotracheal tube was then removed, and

the rats were returned to their cages. The sham-operated rats underwent the same surgical procedures, except that the suture that was passed under the left pulmonary artery was not tied. At each specified time after surgery, the rats were killed by excision of the heart under anesthesia.

Histological change. The tissues were embedded in paraffin, and 4 μ m-thick sections were deparaffinized and stained with hematoxylin and eosin.

The plasma HGF Level. Four milliliter blood samples were rapidly collected from the inferior vena cava of 5 rats in each group at 9 timed intervals (after 0, 0.5, 1, 3, 6, 12, 24, 48, and 72 h). The blood samples were transferred to tubes containing Na₂EDTA (1 mg/ml), and immediately centrifuged at 18000 rpm for 15 min. The resultant plasma sample was stored at -80 °C until HGF assay. The plasma concentration of HGF was measured with 50 μ l of plasma, using enzyme-linked immunosorbent assay (ELISA) kits (Institute of Immunology, Tokyo, Japan) according to the protocol supplied by the manufacturer. The minimum detectable level of HGF found with these ELISA kits was 0.2 ng/ml. All the samples were assayed at least twice.

Real-Time Reverse Transcription Polymerase Chain Reaction (Real Time RT-PCR) assay. Bilateral lung and liver were obtained and immediately frozen in each group at 7 timed intervals (after 0, 1, 6, 12, 24, 48, and 72 h). The total RNA was extracted using a commercial kit (RNAzol-B isolation kit; Phone-TEST Inc., Friendswood, TX, USA). AN RT reaction was performed 4 times for each RNA sample in MicroAmp reaction tubes using TaqMan reverse transcription reagents (Applied Biosystems, Foster City, CA, USA). Each reaction tube contained 20 ng of total RNA in a volume of 20 μ l containing 10 \times TaqMan RT Buffer, 25 mM MgCl₂, 500 μ M of each dNTP, 2.5 μ M of Random Hexamer primers, 0.4 U/ μ l of RNase Inhibitor, and 1.25 U/ μ l of MultiScribe Reverse Transcriptase (Applied Biosystems). The RT reaction was performed at 25 °C for 10 min, 48 °C for 30 min, and 90 °C for 5 min. The DNA was stored at -20 °C until use. Primers for HGF and IL-1 β were designed using the computer program Primer Express (Applied Biosystems). The primers were chosen from sequences of different exons. The primers used were GAPDH (sense, 5'-AACGACCCCTTCATTGACCTC-3'; and antisense, 5'-ATTCTCAGCCTTGACTGTGCC-3'), HGF (sense, 5'-TGCAACGGTGAAAGCTACAGAG-3'; and antisense, 5'-ATTTGTGCCGGTGTGGTGT-3'), and

IL-1 β (sense, 5'-CACAGCAGCATCTCGACAAGA-3'; and antisense, 5'-AAGACATAGGTAGCTGCCACAGC-3').

PCR was performed in a MicroAmp Optical 96-Well Reaction Plate (Applied Biosystems) with a Gene Amp 5700 Sequence Detection System (Applied Biosystems), according to the manufacturer's instructions. By using the SYBER Green PCR Master Mix (Applied Biosystems), fluorescence signals were generated during each PCR cycle via the 5'- to 3'-endonuclease activity of AmpliTaq Gold DNA polymerase to provide Real-time RT-PCR information. The standards, no template controls, and unknown samples were added in a total volume of 50 μ l. The PCR retaining conditions were 2 min at 50 °C, 10 min at 95 °C, 40 cycles of 15 sec at 95 °C, and 60 sec at 60 °C for each amplification. All PCR experiments were performed with a hot start. Standard curves for the HGF and IL-1 β mRNA expression were generated using a serially diluted solution of the injured left lung at 6 h and 1 h after pulmonary ischemia, which showed the highest value by the preliminary study. The parameter threshold cycle (Ct) was designed as the fractional cycle number at which the fluorescence signals were generated during each PCR cycle. The HGF and IL-1 β mRNA expressions were calculated from the standard curve, and quantitative normalization in each sample was performed using the expression of the glyceraldehyde-3-phosphate dehydrogenase (GAPDH) gene as an internal control.

Statistical Analysis. All data are presented as the mean \pm standard deviation (SD), and significance was established by one-way analysis of variance (ANOVA) with multiple comparisons and Fisher's protected least significant difference test. A *P* value of less than 0.05 was considered statistically significant.

Results

All rat characteristics, operation times, and anesthesia times were comparable, and there were no significant differences between the study groups.

Histological changes after pulmonary embolism. The histological changes are summarized in Fig. 1. In the normal lung, the intima of the thin alveolar septa consisted of simple squamous epithelia (Fig. 1A). In the ischemic left lung at 6 h, mild hyperemia of the alveolar septa and effusion in the alveolar sac were observed (Fig. 1B). In the ischemic left lung at 24 h, moderate hyperemia and hypertrophy of the alveolar septa

were observed (Fig. 1C). In the ischemic left lung at 48 h, severe infiltration of leukocytes and neutrophils in the alveolar septa were observed. Effusion in the alveolar sac and hyperemia of the alveolar septa were also observed along with severe hypertrophy. However, no hemorrhagic necrosis of the alveolar walls was seen. Pulmonary infarction was not recognized (Fig. 1D).

Assay for the plasma HGF Level. In all rats, the plasma HGF level was 0.48 ± 0.9 ng/mL before surgery. The plasma HGF level in the rats who were sham-operated was below 0.5 ng/mL at 0, 3, 6, 12, 24, 48, and 72 h after the simple thoracotomy, but it was slightly increased compared with before the operation at 0.5 and 1 h after the simple thoracotomy. However, the plasma HGF level in the rats with pulmonary ischemia was markedly increased at 1, 3, 12, 24, and 48 h after the pulmonary ischemia (3.1 ± 1.5 ng/mL, 1.9 ± 0.36 ng/mL, 3.9 ± 1.7 ng/mL, 2.2 ± 0.06 ng/mL, and 3.1 ± 0.93 ng/mL respectively; *P* < 0.05 versus sham-operated rats); the maximum level was 12.6-fold higher than in the sham-operated rats (*P* < 0.0001) (Fig. 2).

HGF mRNA Expression in the left lung. The HGF mRNA expression in the injured left lung was markedly increased at 1, 6, and 12 h after the pulmonary ischemia (1.9 ± 0.38 , 2.9 ± 0.41 , and 2.0 ± 0.36 , respectively; *P* < 0.05 versus right lung and liver); the maximum level was 7.5-fold higher than in the liver (*P* < 0.0001) (Fig. 3).

IL-1 β mRNA Expression in the left lung. The IL-1 β mRNA expression in the injured left lung was markedly increased at 1 h after pulmonary ischemia than in the liver (*P* = 0.0007) (Fig. 4).

Discussion

Pulmonary embolism is a common and often fatal postoperative complication. By heightening awareness of this diagnosis, the appropriate management of pulmonary infarction could be improved. Thus, we created acute obstruction of the pulmonary artery in a rat model, in order to examine pulmonary ischemia and its importance in clinical medicine.

It is generally thought that infarction is caused by the relative or absolute deficiency of the oxygen supply, due to obstruction of the arteries, and that the cause of pulmonary infarction is acute obstruction of the pulmonary artery. However, it has been reported that the incidence of pulmonary infarction is as low as 10 to 30%

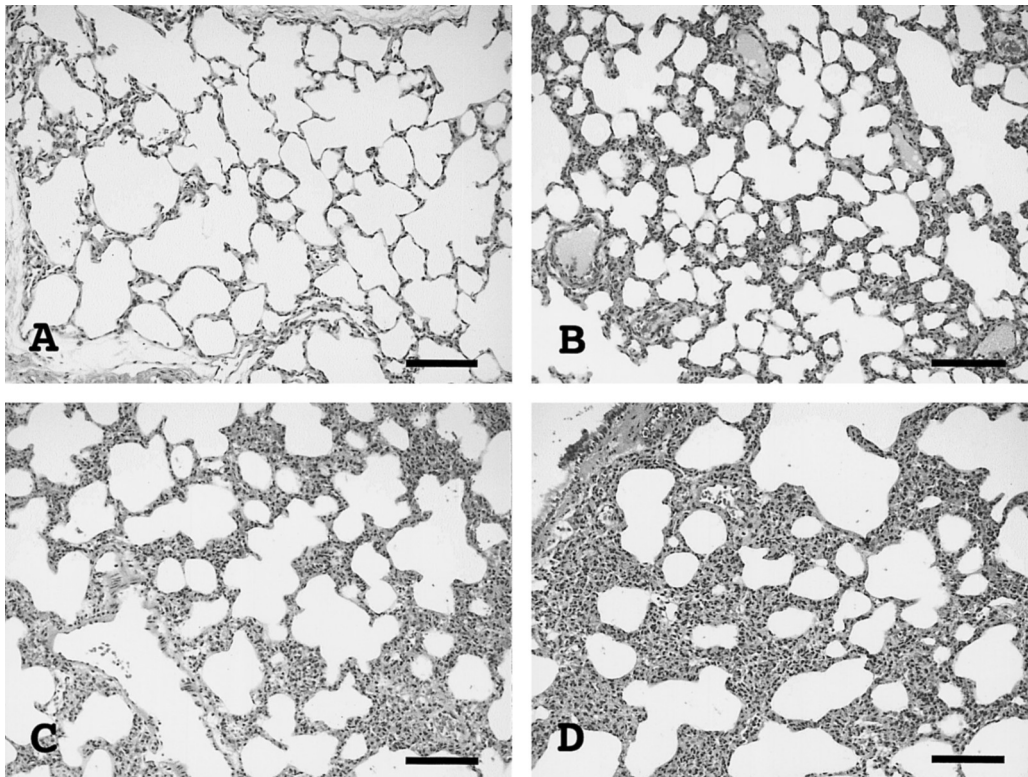


Fig. 1 Histological changes of lung tissues after pulmonary embolism. (A) Normal lung, in which the intima of thin alveolar septa consists of simple squamous epithelia. (B) In the injured left lung of rats with pulmonary embolism at 6 h, mild hyperemia of the alveolar septa and effusion in the alveolar sac were observed. (C) In the injured left lung of rats with pulmonary embolism at 24 h, hyperemia and hypertrophy of the alveolar septa was observed. (D) In the injured left lung of rats with pulmonary embolism at 48 h, infiltration of lymphocytes and severe hyperemia of the alveolar septa was observed along with severe hypertrophy. Hemorrhagic necrosis was not seen. (Haematoxylin-eosin stain, bars indicate 100 μm .)

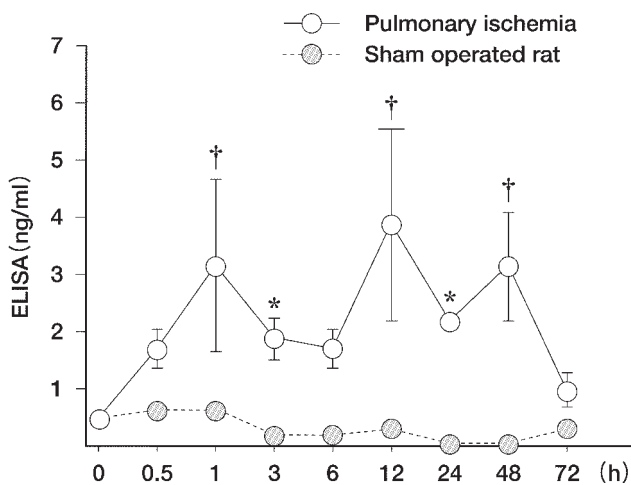


Fig. 2 Time course of plasma HGF levels in pulmonary ischemia in both rat groups. The plasma HGF level began to increase at 30 min after pulmonary ischemia, reached a maximum at 12 h, and decreased at 72 h. Values are mean \pm SD for 5 rats. * $P < 0.05$ vs. sham-operated rats at the same time after the pulmonary ischemia. † $P < 0.01$ vs. sham-operated rats at the same time after the pulmonary ischemia (Fisher's PLSD test).

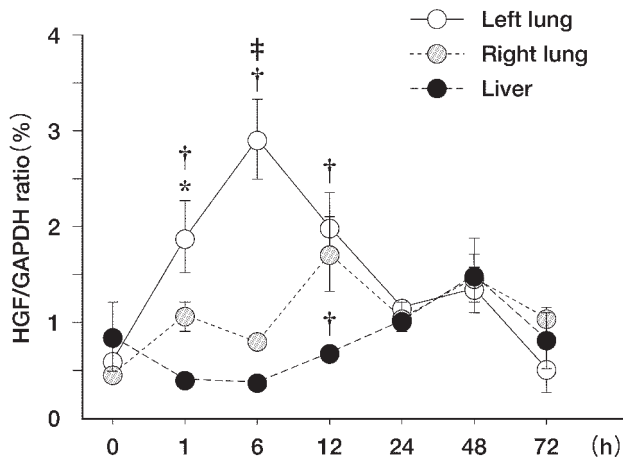


Fig. 3 We used the dilution real-time RT-PCR method to quantitate the HGF mRNA expression in the injured left lung, right lung, and liver. The HGF mRNA expression in the injured left lung was markedly increased at 1, 6, and 12 h after the pulmonary ischemia ($*P < 0.05$ vs. right lung, $\dagger P < 0.01$ vs. liver, $\ddagger P < 0.01$ vs. right lung at the same time after the pulmonary ischemia); the maximum level was 7.5-fold higher than in the liver ($P < 0.0001$). (Fisher's PLSD test).

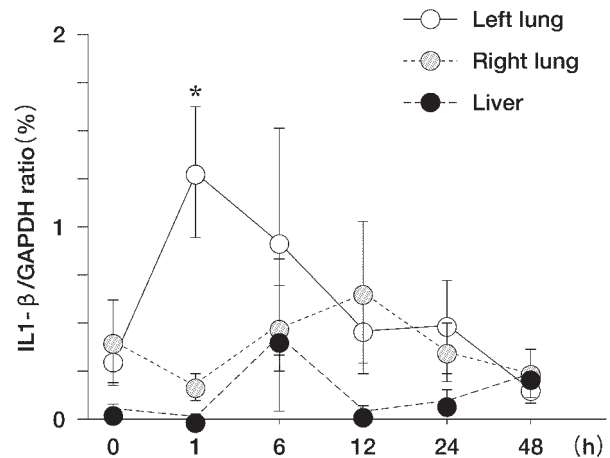


Fig. 4 We used the dilution Real-time RT-PCR method to quantitate the IL1- β mRNA in the injured left lung, right lung, and liver. The IL1- β mRNA expression in the injured left lung was markedly increased at 1 h after the pulmonary ischemia than in the liver ($*P = 0.0007$).

in all cases of thromboembolism of the pulmonary artery [12]. Moreover, interruption of the pulmonary arterial flow by ligation or embolization of the pulmonary artery failed to induce pulmonary infarction in animal experiments [13]. The present study demonstrates that ligation of the pulmonary artery leads to severe infiltration of neutrophils, hyperemia of the alveolar septa, and effusion in the alveolar sac. However, no hemorrhagic necrosis of the pulmonary structure was seen. Therefore, our results suggest that ligation of the pulmonary artery leads to severe ischemic change of the pulmonary structure, but does not induce pulmonary infarction.

Compensatory proliferation and subsequent differentiation of alveolar type II epithelial cells and bronchial epithelial cells are essential for lung regeneration. In case of alveolar injury, alveolar type I epithelial cells are predominantly damaged, and alveolar type II cells proliferate and differentiate into alveolar type I epithelial cells. In case of bronchial injury, the remaining bronchial epithelial cells, Clara cells, and basal cells are thought to proliferate and differentiate into multipotent progenitor cells, and bronchial epithelial cells are regenerated by the differentiation of those cells [14–16]. In lung regeneration, several polypeptide growth factors, such as EGF, KGF, IGF-I, aFGF, and HGF were reported to

elicit mitogenic activity for alveolar type II epithelial cells and bronchial epithelial cells [8]. HGF was initially thought to be liver-specific, but it has become clear that HGF acts on a variety of epithelial cells and organs [17], such as mitogen [1, 3], motogen [17], and morphogen. HGF may also be involved in vascular proliferation and regeneration, as it is a principal mediator of mesenchymal, epithelial, and endothelial interactions that contribute to wound healing and angiogenesis [18]. It is likely that HGF plays an important role in ischemic lung injury.

To investigate the relationship between HGF and pulmonary ischemia, we measured the plasma HGF concentration. The first increase in the plasma HGF level was noted at 0.5 h, reached a peak at 12 h, and remained at 48 h after pulmonary ischemia in rats, and it was hardly increased compared with those of the sham-operated rats. Therefore, we expect that HGF may elicit mitogenic activity for the alveolar structure and angiogenic activity for the vessels in pulmonary ischemia.

The lung, liver, kidney, and spleen produce and supply HGF to injured tissues or organs for the purposes of regeneration following organ insults such as hepatectomy [19], hepatic ischemia [20], unilateral nephrectomy [21], and myocardial ischemia [22]. In the lung, HGF is known to be synthesized and secreted by mesenchymal cells, such as macrophages, endothelial cells, and fibroblasts, and controls the proliferation and

morphogenesis of a broad spectrum of epithelial cells [5, 11, 23]. We did Real-time RT-PCR with the injured left lung, right lung, and liver to identify the origin of serum HGF.

Real-time RT-PCR revealed that HGF mRNA was up-regulated in the ischemic left lung, which was much earlier than the peak plasma HGF level, and increased rapidly not only in the ischemic left lung, but also in the intact right lung and the liver. However, the level was significantly higher in the injured left lung compared with the other organs. Therefore, we considered that HGF might be mainly induced by paracrine mechanisms in pulmonary ischemia.

Two sequence elements, an interleukin-6 (IL-6) response element and a potential binding site for nuclear factor IL-6, are located near the transcription initiation site of the human HGF gene, and might be involved in the regulation of HGF gene expression [24]. It has also been reported that inflammatory cytokines such as IL-1 β stimulate HGF production [25]. IL-1 is a multifunctional factor produced by macrophages, monocytes, neutrophils, vascular endothelial cells, fibroblasts, keratinocytes, and Kupffer cells. Among various biological activities, IL-1 plays an important role as an inflammatory cytokine to mediate acute phase reactions, such as the induction of acute protein synthesis. IL-1 β also stimulates nitric oxide (NO) synthesis in vascular cells [26]. NO, an important regulator of vessel tone and vascular homeostasis through its effect on platelets and smooth muscle cell function, inhibits platelet adhesion and aggregation in pulmonary thrombosis in the rat model [27, 28]. In addition, inhaled NO is a selective pulmonary vasodilator and effectively reduces pulmonary hypertension [29, 30].

Therefore, we hypothesized that IL-1 β is thought to be released into the circulation and to act in turn on pulmonary ischemia, inducing HGF expression. IL-1 β mRNA was rapidly up-regulated in the ischemic left lung, and precedes HGF mRNA, which began at 6 hour after the pulmonary ischemia. Therefore, these studies suggested that IL-1 β might be released in pulmonary ischemia, which acts by regulating HGF gene expression, and is an important regulator of the vessel.

We have shown that the expression of HGF was induced in the early stages of pulmonary ischemia, and was rapidly up-regulated compared with in other cardiorespiratory diseases [6, 22, 31]. Though further study is needed to ascertain the HGF levels, in order to

compare them with other cardiorespiratory diseases, the plasma HGF level may be a useful biological marker of pulmonary ischemia, and thus be a tool for making an early diagnosis. Clarification of the mechanisms, characteristics, and biological significance of HGF elevation is important for clinical use in diagnosing and treating pulmonary ischemia.

References

1. Nakamura T, Nawa K and Ichihara A: Partial purification and characterization of hepatocyte growth factor from serum of hepatectomized rats. *Biochem Biophys Res Commun* (1984) 122: 1450-1459.
2. Nakamura T, Teramoto H and Ichihara A: Purification and characterization of a growth factor from rat platelets for mature parenchymal hepatocytes in primary cultures. *Proc Natl Acad Sci USA* (1986) 83: 6489-6493.
3. Nakamura T, Nishizawa T, Hagiya M, Seki T, Shimonishi M, Sugimura A, Tashiro K and Shimizu S: Molecular cloning and expression of human hepatocyte growth factor. *Nature* (1989) 342: 440-443.
4. Gohda E, Tsubouchi H, Nakayama H, Hirono S, Sakiyama O, Takahashi K, Miyazaki H, Hashimoto S and Daikuhara Y: Purification and partial characterization of hepatocyte growth factor from plasma of a patient with fulminant hepatic failure. *J Clin Invest* (1988) 81: 414-419.
5. Mason RJ, Leslie CC, McCormick-Shannon K, Deterding RR, Nakamura T, Rubin JS and Shannon JM: Hepatocyte growth factor is a growth factor for rat alveolar type II cells. *Am J Respir Cell Mol Biol* (1994) 11: 561-567.
6. Yanagita K, Matsumoto K, Sekiguchi K, Ishibashi H, Niho Y and Nakamura T: Hepatocyte growth factor may act as a pulmotrophic factor on lung regeneration after acute lung injury. *J Biol Chem* (1993) 268: 21212-21217.
7. Shiratori M, Michalopoulos G, Shinozuka H, Singh G and Ogasawara H, Katyal SL: Hepatocyte growth factor stimulates DNA synthesis in alveolar epithelial type II cells *in vitro*. *Am J Respir Cell Mol Biol* (1995) 12: 171-180.
8. Ohmichi H, Matsumoto K and Nakamura T: *In vivo* mitogenic action of HGF on lung epithelial cells: Pulmotrophic role in lung regeneration. *Am J Physiol* (1996) 270: L1031-1039.
9. Panos RJ, Patel R and Bak PM: Intratracheal administration of hepatocyte growth factor/scatter factor stimulates rat alveolar type II cell proliferation *in vivo*. *Am J Respir Cell Mol Biol* (1996) 15: 574-581.
10. Maeda J, Ueki N, Hada T and Higashino K: Elevated serum hepatocyte growth factor/scatter factor levels in inflammatory lung disease. *Am J Respir Crit Care Med* (1995) 152: 1587-1591.
11. Sakai T, Satoh K, Matsushima K, Shindo S, Abe S, Abe T, Motomiya M, Kawamoto T, Kawabata Y, Nakamura T and Nukiwa T: Hepatocyte growth factor in bronchoalveolar lavage fluids and cells in patients with inflammatory chest diseases of the lower respiratory tract: Detection by RIA and *in situ* hybridization. *Am J Respir Cell Mol Biol* (1997) 16: 388-397.
12. Schraufnagel DE, Tsao MS, Yao YT and Wang NS: Factors associated with pulmonary infarction. A discriminant analysis study. *Am J Clin Pathol* (1985) 84: 15-18.
13. Urano T, Shibayama Y, Fukunishi K, Nariyama K and Ohsawa N: Interruption of pulmonary arterial flow with inadequate ventilation

- leads to pulmonary infection. *Virchows Arch* (1996) 427: 607–612.
14. Ford JR and Terzaghi-Howe M: Basal cells are the progenitors of primary tracheal epithelial cell cultures. *Exp Cell Res* (1992) 198: 69–77.
 15. Johnson NF and Hubbs AF: Epithelial progenitor cells in the rat trachea. *Am J Respir Cell Mol Biol* (1990) 3: 579–585.
 16. Liu JY, Nettesheim P and Randell SH: Growth and differentiation of tracheal epithelial progenitor cells. *Am J Physiol* (1994) 266: L296–307.
 17. Matsumoto K, Hashimoto K, Yoshikawa K and Nakamura T: Marked stimulation of growth and motility of human keratinocytes by hepatocyte growth factor. *Exp Cell Res* (1991) 196: 114–120.
 18. Grant DS, Kleinman HK, Goldberg ID, Bhargava MM, Nickloff BJ, Kinsella JL, Polverini P and Rosen EM: Scatter factor induces blood vessel formation *in vivo*. *Proc Natl Acad Sci USA* (1993) 90: 1937–1941.
 19. Higuchi O and Nakamura T: Identification and change in the receptor for hepatocyte growth factor in rat liver after partial hepatectomy or induced hepatitis. *Biochem Biophys Res Commun* (1991) 176: 599–607.
 20. Uemura T, Miyazaki M, Hirai R, Matsumoto H, Ota T, Ohashi R, Shimizu N, Tsuji T, Inoue Y and Namba M: Different expression of positive and negative regulators of hepatocyte growth in growing and shrinking hepatic lobes after portal vein branch ligation in rats. *Int J Mol Med* (2000) 5: 173–179.
 21. Nagaïke M, Hirao S, Tajima H, Noji S, Taniguchi S, Matsumoto K and Nakamura T: Renotropic functions of hepatocyte growth factor in renal regeneration after unilateral nephrectomy. *J Biol Chem* (1991) 266: 22781–22784.
 22. Ono K, Matsumori A, Shioi T, Furukawa Y and Sasayama S: Enhanced expression of hepatocyte growth factor/c-Met by myocardial ischemia and reperfusion in a rat model. *Circulation* (1997) 95: 2552–2558.
 23. Yanagita K, Nagaïke M, Ishibashi H, Niho Y, Matsumoto K and Nakamura T: Lung may have an endocrine function producing hepatocyte growth factor in response to injury of distal organs. *Biochem Biophys Res Commun* (1992) 182: 802–809.
 24. Miyazawa K, Kitamura A and Kitamura N: Structural organization and the transcription initiation site of the human hepatocyte growth factor gene. *Biochemistry* (1991) 30: 9170–9176.
 25. Matsumoto K, Okazaki H and Nakamura T: Up-regulation of hepatocyte growth factor gene expression by interleukin-1 in human skin fibroblasts. *Biochem Biophys Res Commun* (1992) 188: 235–243.
 26. Marczin N, Papapetropoulos A and Catravas JD: Tyrosine kinase inhibitors suppress endotoxin- and IL-1 beta-induced NO synthesis in aortic smooth muscle cells. *Am J Physiol* (1993) 265: H1014–1018.
 27. Moncada S, Palmer RM and Higgs EA: Nitric oxide: physiology, pathophysiology, and pharmacology. *Pharmacol Rev* (1991) 43: 109–142.
 28. Radomski MW and Moncada S: The biological and pharmacological role of nitric oxide in platelet function. *Adv Exp Med Biol* (1993) 344: 251–264.
 29. Frostell C, Fratacci MD, Wain JC, Jones R and Zapol WM: Inhaled nitric oxide. A selective pulmonary vasodilator reversing hypoxic pulmonary vasoconstriction. *Circulation* (1991) 83: 2038–2047.
 30. Pepke-Zaba J, Higenbottam TW, Dinh-Xuan AT, Stone D and Wallwork J: Inhaled nitric oxide as a cause of selective pulmonary vasodilatation in pulmonary hypertension. *Lancet* (1991) 338: 1173–1174.
 31. Sugahara K, Matsumoto M, Baba T, Nakamura T and Kawamoto T: Elevation of serum human hepatocyte growth factor (HGF) level in patients with pneumonectomy during a perioperative period. *Intensive Care Med* (1998) 24: 434–437.