

Acta Medica Okayama

Volume 64, Issue 2

2010

Article 10

APRIL 2010

Operative treatment for pincer type femoroacetabular impingement: a case report

Hirosuke Endo* Tomoyuki Noda† Shigeru Mitani‡
Ryuichi Nakahara** Tomonori Tetsunaga††
Toshiyuki Kunisada‡‡ Toshifumi Ozaki§

*Department of Medical Materials for Musculoskeletal Reconstruction, Okayama University Graduate School of Medicine, Dentistry and Pharmaceutical Sciences, hirosuke@md.okayama-u.ac.jp

†Orthopaedic Surgery, Okayama University Hospital,

‡Department of Bone and Joint Surgery, Kawasaki Medical School,

**Orthopaedic Surgery, Okayama University Hospital,

††Orthopaedic Surgery, Okayama University Hospital,

‡‡Department of Medical Materials for Musculoskeletal Reconstruction, Okayama University Graduate School of Medicine, Dentistry and Pharmaceutical Sciences,

§Orthopaedic Surgery, Okayama University Hospital,

Operative treatment for pincer type femoroacetabular impingement: a case report

Hirosuke Endo, Tomoyuki Noda, Shigeru Mitani, Ryuichi Nakahara, Tomonori Tetsunaga, Toshiyuki Kunisada, and Toshifumi Ozaki

Abstract

Femoroacetabular impingement (FAI) is a condition characterized by the impingement of the femur and acetabulum. In Japan, this disorder has become recognized gradually. Here we report a rare case of surgically treated FAI, associated with an osseous protrusion on the acetabulum of a 30-year-old female. Plain computed tomography (CT) and reconstructive 3D-CT images clearly demonstrated an anterolateral bony protrusion. Hip arthroscopy showed no degeneration of the cartilage on either the femoral or acetabular side, but degeneration at the edge of labrum was observed in the region of the bony protrusion. The complete removal of the bony protrusion under hip arthroscopy was thus considered impracticable, and a small skin incision was therefore made anteriorly to approach the acetabulum. The Short-Form 36-Item Health Survey (SF-36) revealed improvement in all scores.

KEYWORDS: femoroacetabular impingement, bony protrusion, Pincer type, hip arthroscopy, SF36

Case Report

Operative Treatment for Pincer Type Femoroacetabular Impingement: A Case Report

Hirosuke Endo^{a*}, Tomoyuki Noda^b, Shigeru Mitani^c, Ryuichi Nakahara^b,
Tomonori Tetsunaga^b, Toshiyuki Kunisada^a, and Toshifumi Ozaki^b

Department of ^aMedical Materials for Musculoskeletal Reconstruction, Okayama University Graduate School of Medicine, Dentistry and Pharmaceutical Sciences, and ^bOrthopaedic Surgery, Okayama University Hospital, Okayama 700-8558, Japan, and ^cDepartment of Bone and Joint Surgery, Kawasaki Medical School, Kurashiki, Okayama 701-0192, Japan

Femoroacetabular impingement (FAI) is a condition characterized by the impingement of the femur and acetabulum. In Japan, this disorder has become recognized gradually. Here we report a rare case of surgically treated FAI, associated with an osseous protrusion on the acetabulum of a 30-year-old female. Plain computed tomography (CT) and reconstructive 3D-CT images clearly demonstrated an anterolateral bony protrusion. Hip arthroscopy showed no degeneration of the cartilage on either the femoral or acetabular side, but degeneration at the edge of labrum was observed in the region of the bony protrusion. The complete removal of the bony protrusion under hip arthroscopy was thus considered impracticable, and a small skin incision was therefore made anteriorly to approach the acetabulum. The Short-Form 36-Item Health Survey (SF-36) revealed improvement in all scores.

Key words: femoroacetabular impingement, bony protrusion, Pincer type, hip arthroscopy, SF36

Femoroacetabular impingement (FAI) is a condition characterized by the impingement of the femur and acetabulum due to a morphological abnormality and to hypermobility of the hip joint, with consequent coxalgia, and which thereafter progresses to osteoarthritis of the hip [1-3]. This disorder is classified as either a Pincer type due to an abnormality on the acetabular side, or a Cam type, due to an abnormality on the femoral side [4, 5]. In Europe and the United States, cases of FAI have increasingly been reported as well as treatment strategies and results [6-10]. In Japan, on the other hand, secondary osteoarthritis of the hip due to acetabular dysplasia is a more common problem [11], and there are not

so many reports on FAI. The present report describes a case of surgically treated Pincer type FAI.

Case Report

The patient was a 30-year-old female. Her height was 160 cm, weight was 56 kg, and BMI was 21.8 (kg/m²). She was a grocery store clerk and had suffered from indeterminate coxalgia for nearly 10 years which had remained untreated. However, the coxalgia worsened and eventually led to occasional gait disturbance in the 6 months prior to presentation. The patient visited our hospital with the chief complaint of right hip-joint pain and gait disturbance. The patient's history of sporting activities and her family history were unremarkable, and no history of either developmental dysplasia of the hip (DDH) or of any specific

Received July 30, 2009; accepted November 4, 2009.

*Corresponding author. Phone:+81-86-235-7273; Fax:+81-86-223-9727
E-mail:hirosuke@md.okayama-u.ac.jp (H. Endo)

trauma was found. A physical examination revealed a slight limping gait and limited range of motion (flexion and internal rotation) in the right hip joint. The mobility of her joints was within the normal ranges. Severe pain occurred above 100 degrees flexion combined with 10 degrees internal rotation. The patient was hardly able to walk long distances. Her Japanese Orthopaedic Association (JOA) hip score was 80 points. The initial radiographic examination of the hip joint from the anteroposterior view revealed that the joint space on the affected side had not narrowed. The central edge angle and the Sharp angle were 33 and 42 degrees, respectively, and thus acetabular dysplasia was excluded (Fig. 1A). The femoral head was spherical, not deformed, and the α -angle and head-neck offset were within the normal limits [5]; however, there existed an osseous protrusion on the anterolateral side from the acetabular rim (Fig. 1B, C). Plain magnetic resonance imaging (MRI) showed no adverse findings such as necrosis of the femoral head, hydroa-

rthrosis, or remarkable labral tearing (Fig. 2). Plain computed tomography (CT) (Fig. 3) and reconstructive 3D-CT images (Fig. 4) clearly demonstrated the anterolateral bony protrusion. Hip arthrography was performed and no particular abnormalities were found (Fig. 5). Arthroscopy of the hip joint was then performed using a traction apparatus in the supine position. No degeneration of the cartilage was observed on either the femoral or acetabular side, but degeneration at the edge of the labrum was observed in the region where the bony protrusion was situated (Fig. 6A, B). The complete removal of the bony protrusion under arthroscopy was thus considered impracticable, and a small skin incision was therefore made anteriorly to approach the acetabulum (Fig. 7A). After the capsule was opened partially using a direct anterior approach, the bony protrusion was resected using a chisel while the labrum was carefully protected (Fig. 7B). The labrum subjacent to the bony protrusion had been slightly torn at its insertion, but it was left

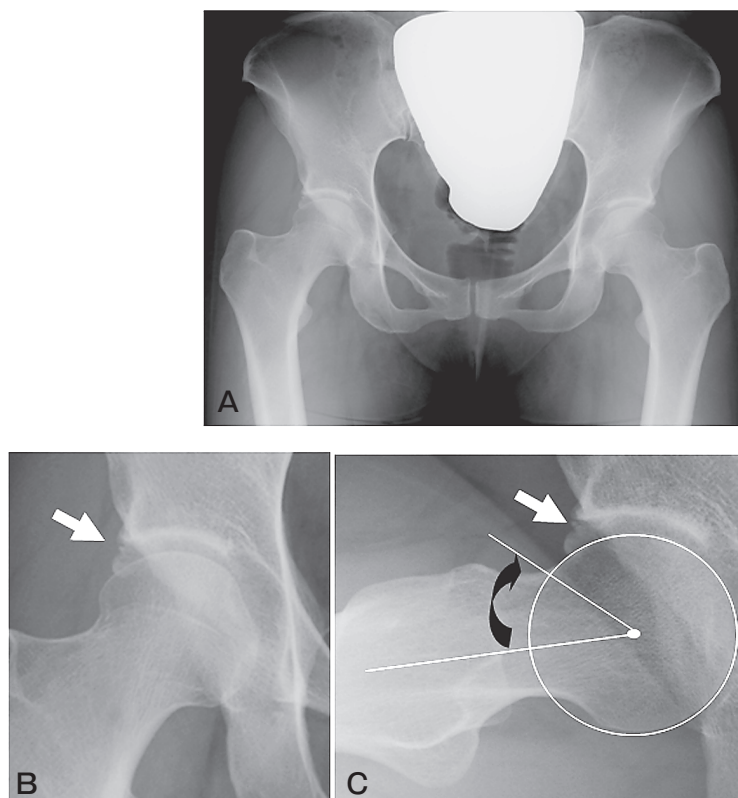


Fig. 1 The initial radiograph. **A**, A-P view; **B**, Osseous protrusion (arrow) in right hip joint seen by the expansion of A-P view; **C**, Osseous protrusion (white arrow) in anterior-superior site seen by expansion of the lateral view. The α angle (black arrow) was 40 degrees and head-neck offset was 12 mm.

unrepaired because the tear lesion was within 5 millimeters. Histopathologically, the resected protrusion was noted to be normal bone tissue, and the possibility of exostosis and other lesions was ruled out (Fig. 7C). Postoperative X-ray films (Fig. 8A) and CT images (Fig. 8B) demonstrated a complete removal of the bony bump. Training for range of motion (ROM) and

walking on crutches with weight-bearing were permitted depending on the severity of pain, beginning on the third postoperative day. Two weeks after the operation the patient was discharged with improved hip joint ROM and subjective symptoms. The patient thereafter became capable of walking without assistance with a virtually complete resolution of the pain experienced when walking within 2 months after operation. At 6 months after operation, the hip joint ROM of the affected side showed no limitation, the same as the

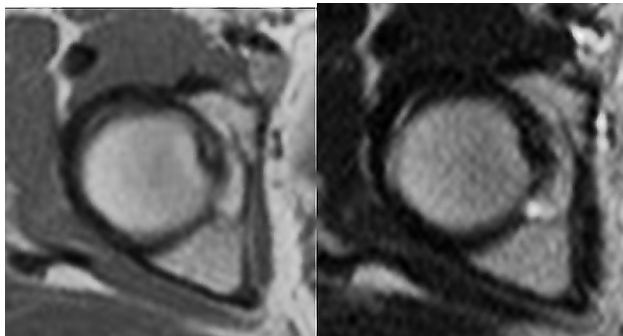


Fig. 2 Magnetic resonance imaging, T1 and T2 weighting.

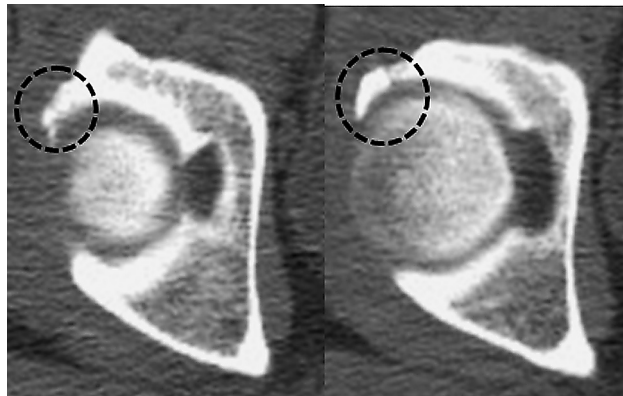


Fig. 3 Axial CT showed abnormal bony coverage of acetabulum.

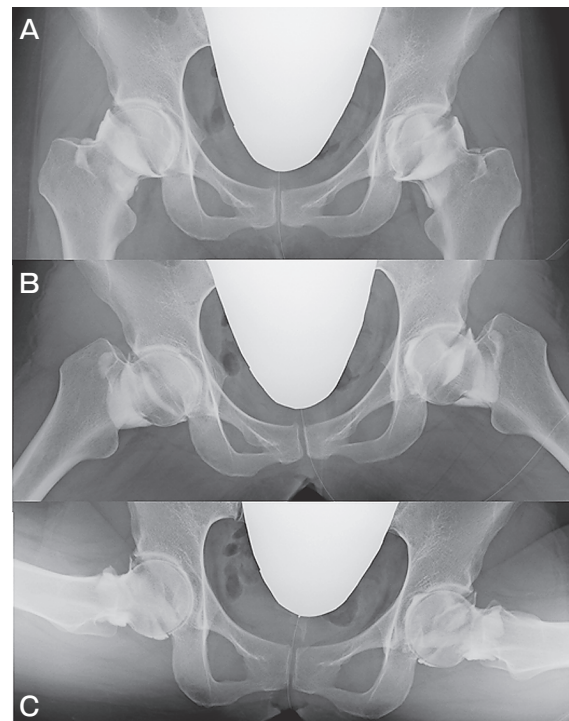


Fig. 5 Arthrography of both hip joints. A, neutral position; B, abduction position; C, frog position.

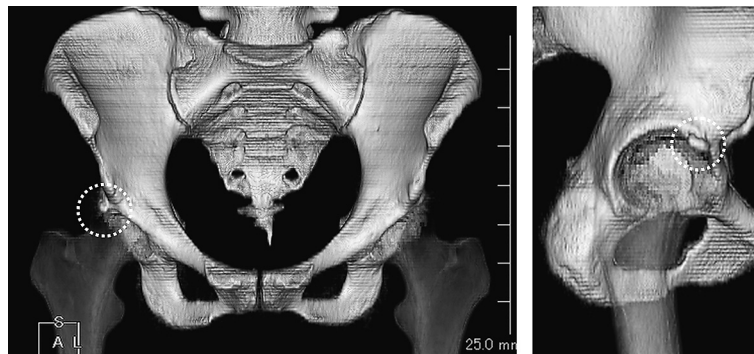


Fig. 4 Three dimensional reconstruction computed tomography of the pelvis.

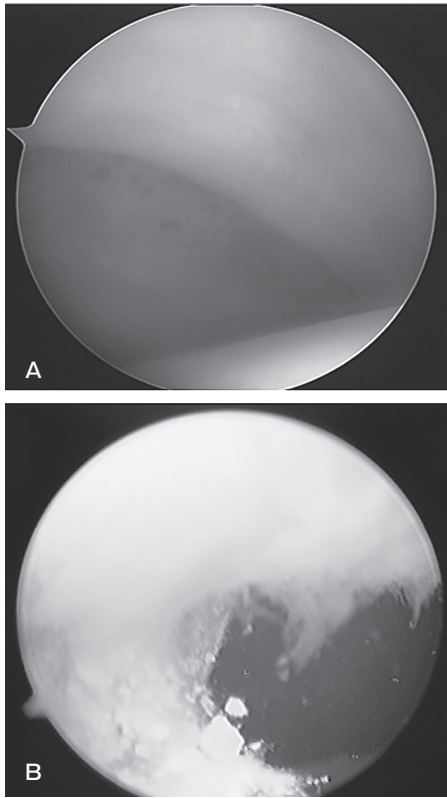


Fig. 6 Intraoperative view of arthroscopy. **A**, femoral head and acetabulum; **B**, anterior-lateral site of labrum.

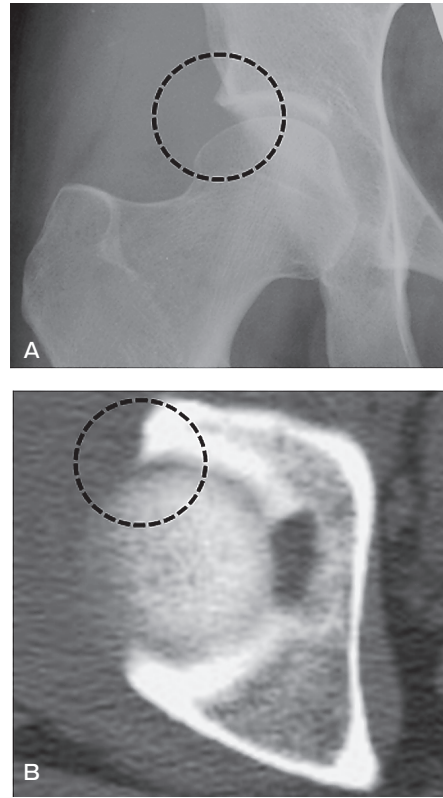


Fig. 8 After the operation. The osseous protrusion is completely gone.

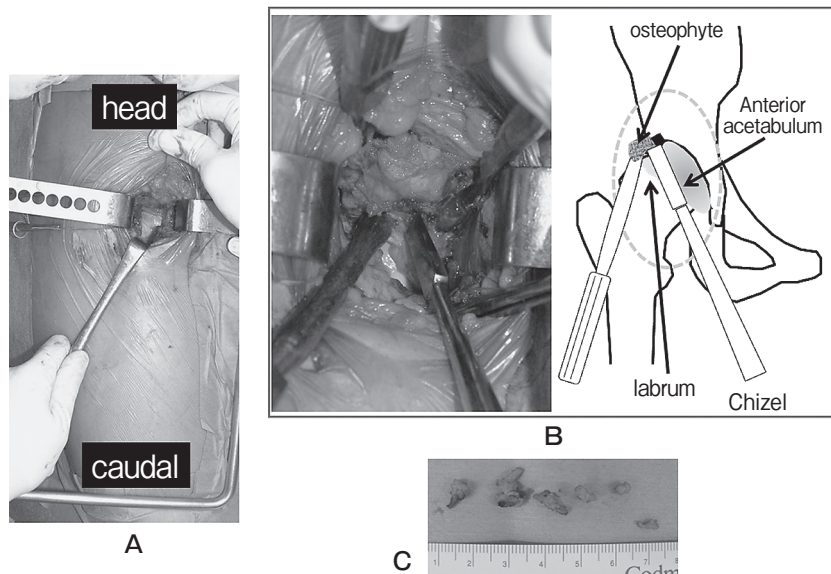


Fig. 7 Operation. **A**, A small (8cm) incision in anterior approach; **B**, Photograph of resection for osseous protrusion by using Chisel. Diagram showing the operative technique to protect the labrum for inspection and to resect the osseous protrusion precisely; **C**, The resected bone of the anterior-lateral bump.

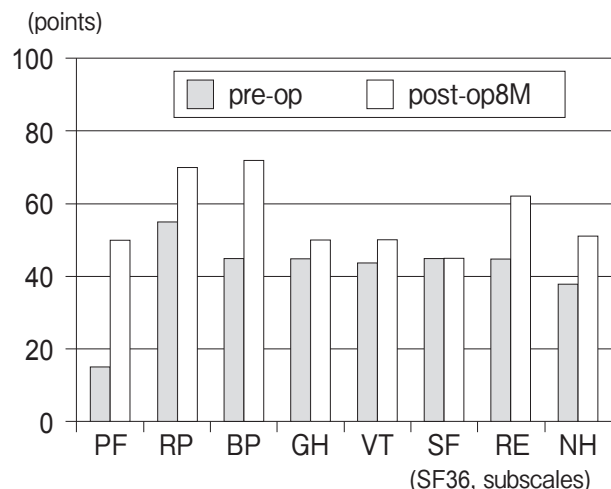


Fig. 9 Short-form 36-Item Health Survey (SF-36) on pre-operation and 8 months postoperatively. SF-36 consist of 8 subscales: PF, physical functioning; MH, mental health; RP, role-physical; RE, role-emotional; BP, bodily pain; GH, general health perception; VT, vitality; SF, social functioning.

unaffected side, and the JOA hip score was improved to a full score. A subjective assessment based on the Medical Outcomes Study (MOS) Short-Form 36-Item Health Survey (SF-36) [12] revealed improvement in all scores, especially regarding the physical functioning (PF) at 8 months post operation, in comparison to the preoperative status (Fig. 9).

Discussion

FAI has been reported in recent years as a cause of osteoarthritis of the hip which tends to develop among relatively young people [1-3], and the concept of this disease has also become increasingly recognized in Japan. Such impingement is attributable to an ill-balanced hip joint resulting from an anatomical abnormality, and is generally classified into 2 types; Cam impingement due to an abnormality on the femoral side and Pincer impingement due to an abnormality on the acetabular side. The Cam type includes slipped femoral capital epiphysis and has been overwhelmingly more frequently reported among male patients, whereas Pincer type is relatively more common among female patients who are prone to have hypermobility of the joint [5]. The clinical diagnosis includes anterior impingement, in which pain is reproduced on flexion and internal rotation of the joint, and posterior

impingement, where pain is reproduced on extension and external rotation; a diagnosis of either the Cam or Pincer types is base mainly on X-ray and MRI results [4, 5].

In Japan, asymptomatic cases of Cam impingement have been reported in patients with slipped femoral capital epiphysis [13]; however, there have been few reports on cases of Pincer impingement. In the present case, a 30-year-old female presented with pain reproduced on flexion and internal rotation as well as ROM limitation. No anatomical abnormality was found on the femoral side while an abnormal bony eminence was noted only on the acetabulum, thus leading to a diagnosis of Pincer impingement. Nevertheless, the central edge angle and Sharp angle were within the normal ranges; there was no over-coverage and no retroversion such as the so-called cross-over sign. Any possibility of acetabular dysplasia or acetabular rim syndrome due to acetabular retroversion [14, 15] was ruled out. In the present case, hypermobility of the hip joint was not found, but the formation of an abnormal osteophyte may have been caused by friction repeatedly occurring on the articular labrum, thus resulting in a microfracture, which was previously reported as an 'acetabular rim fracture' [16]. The patient had no history of any trauma, and her history of sporting activities was unremarkable. We thus hypothesized that the anterolateral rim fracture occurred due to some unknown factors and that this pathological condition had been formed with repeated daily working activities, especially those involving deep squatting.

There are 2 major treatment strategies for FAI: arthroscopy and more-invasive open surgery with surgical dislocation. The former treatment is associated with less postoperative burden on the patient, such as less pain, less limitation of motion, and shorter hospital stay. However, the accessible area of the hip joint is limited, in particular for lesions on the acetabular side, and this method is mainly indicated for Cam impingement. On the other hand, surgical dislocation allows full access to the hip joint [7, 17], so the acetabuloplasty, such as rim resection and reattachment of the labrum, is possible. However, the burden on the patient is also significant because of the greater surgical invasiveness, complications, and limitations during the early postoperative days. Disease recurrence due to intra-articular adhesions

has also been reported [18]. To overcome these drawbacks, another surgical method combined with arthroscopy and a small anterior incision of skin for Cam impingement has also been reported [9]. The same minimally invasive procedure was performed for the present case with excellent short-term results. However, this method is only indicated for Pincer impingement with a lesion situated at the anterolateral acetabulum. It is therefore important to determine cases for which such treatment is clearly indicated, and to perform long-term postoperative follow-up.

References

- Ganz R, Parvizi J, Beck M, Leunig M, Nötzli H and Siebenrock KA: Femoroacetabular impingement. A cause for osteoarthritis of the hip. *Clin Orthop Relate Res* (2003) 417: 112–120.
- Wagner S, Hofstetter W, Chiquet M, Mainil-Varlet P, Stauffer E, Ganz R and Siebenrock KA: Early osteoarthritic changes of human femoral head cartilage subsequent to femoroacetabular impingement. *Osteoarthritis Cartilage* (2003) 11: 508–518.
- Beck M, Kalhor M, Leunig M and Ganz R: Hip morphology influences the pattern of damage to the acetabular cartilage. *J Bone Joint Surg* (2005): 1012–1018.
- Ito K, Minka-II MA, Leunig M, Werlen S and Ganz R: Femoroacetabular impingement and the cam-effect. *J Bone Joint Surg* (2001) B-83: 171–176.
- Tannast M, Siebenrock KA and Anderson SE: Femoroacetabular impingement radiographic diagnosis; what the radiologist should know. *AJR* (2007) 188: 1540–1552.
- Siebenrock KA, Schoeniger R and Ganz R: Anterior Femoroacetabular impingement due to acetabular retroversion. *J Bone Joint Surg Am* (2003): 278–286.
- Lavigne M, Parvizi J, Beck M, Siebenrock KA, Ganz R and Leunig M: Anterior femoroacetabular impingement; Part 1. techniques of joint preserving surgery. *Clin Orthop Relat Res* (2004) 418: 61–66.
- Jäger M, Wild A, Westhoff B and Krauspe R: Femoroacetabular impingement caused by a femoral osseous head-neck bump deformity: clinical, radiological, and experimental results. *J Orthop Sci* (2004) 9: 256–263.
- Clohisey JC and McClure JT: Treatment of anterior femoroacetabular impingement with combined hip arthroscopy and limited anterior decompression. *IOWA Orthop J* (2005) 25: 164–171.
- Sampson TG: Arthroscopic treatment of femoroacetabular impingement: A proposed technique with clinical experience. *Instr Course Lect* (2006) 55: 337–346.
- Nakamura S, Ninomiya S and Nakamura T: Primary osteoarthritis of the hip in Japan. *Clin Orthop Relat Res* (1989) 241: 190–196.
- Fukuhara S, Bito S, Green J, Amy H and Kurokawa K: Translation, adaptation and validation of the SF-36 Health Survey for use in Japan. *J Clin Epidemiol* (1998) 51: 1037–1044.
- Mitani S, Endo H, Kadota Y, Ozaki T and Aoki K: Location of the femoral head after pinning in situ for slipped capital femoral epiphysis; realignment could not occur. *Seikeisaigaikeka* (2008) 51: 83–89 (in Japanese).
- Klaue K, Durnin CW and Ganz R: The acetabulum rim syndrome: a clinical presentation of hip dysplasia of the hip. *J Bone Joint Surg Br* (1991) 73: 423–429.
- Reynolds D, Lucas J and Klaue K: Retroversion of the acetabulum. A cause of the hip pain. *J Bone Joint Surg Br* (1999) 81: 281–288.
- Mast JW, Mayo KA, Chosa E, Berlemann U and Ganz R: The acetabular rim fracture: A variant of the acetabular rim syndrome. *Semin Arthro* (1997) 8: 97–101.
- Ganz R, Gill TJ, Gautier E, Ganz K, Krügel N and Berlemann U: Surgical dislocation of the adult hip. *J Bone Joint Surg Br* (2001) 83: 1119–1124.
- Krueger A, Leunig M, Siebenrock KA and Beck M: Hip arthroscopy after previous surgical hip dislocation for femoroacetabular impingement. *Arthroscopy* (2007) 23: 1285–1289.