

# *Acta Medica Okayama*

---

*Volume 37, Issue 5*

1983

*Article 4*

OCTOBER 1983

---

## Anomalies of the bile ducts: a case report of direct drain of the cystic duct into the papilla of Vater.

Akiharu Watanabe\*

Yoshito Ohashi<sup>†</sup>

Hideo Nagashima<sup>‡</sup>

\*Okayama University,

<sup>†</sup>Okayama University,

<sup>‡</sup>Okayama University,

# Anomalies of the bile ducts: a case report of direct drain of the cystic duct into the papilla of Vater.\*

Akiharu Watanabe, Yoshito Ohashi, and Hideo Nagashima

## Abstract

Direct drain of the cystic duct and drain of the biliary tract through an internal fistula into the duodenum in a 81-year-old man were endoscopically diagnosed without an operation.

**KEYWORDS:** bile duct anomaly, cystic duct, pancreatic duct, internal fistula

Acta Med. Okayama 37, (5), 409-415 (1983)

## **ANOMALIES OF THE BILE DUCTS: A CASE REPORT OF DIRECT DRAIN OF THE CYSTIC DUCT INTO THE PAPILLA OF VATER**

Akiharu WATANABE, Yoshito OHASHI and Hideo NAGASHIMA

*First Department of Internal Medicine, Okayama University Medical School, Okayama 700, Japan  
(Director : Prof. H. Nagashima)*

*Received March 2, 1983*

*Abstract.* Direct drain of the cystic duct and drain of the biliary tract through an internal fistula into the duodenum in a 81-year-old man were endoscopically diagnosed without an operation.

*Key words :* bile duct anomaly, cystic duct, pancreatic duct, internal fistula.

Anomalies of the extrahepatic biliary tract are surgically problematic because of their prevalence and anatomic variation. Indeed, Kehr (1) reported finding a variation of one type or another with each of 3000 operations on the biliary system. The cystic duct normally empties into the common bile duct, and the latter drains directly into the papilla of Vater. We recently experienced a patient who had a long cystic duct draining into the duodenal papilla in addition to an internal fistula between the duodenum and biliary tract. This condition, diagnosed by gastroenterological endoscopy, is very uncommon.

### CASE REPORT

An 81-year-old man was admitted to Kasaoka Daiichi Hospital on October 10, 1979, complaining of an undefined dull abdominal pain and vomiting for 3 days. He had neither fever, jaundice nor weight loss. In his previous history, he had recurrent episodes of upper abdominal pain 3 to 4 times yearly from the age of 8 to 15. The pain was relieved on occasion with antacids. However, the symptoms completely disappeared as he grew up. He has been well for more than 65 years until the recent admission. The patient's body temperature, pulse and blood pressure were normal. There was slight epigastric tenderness, but the liver and gallbladder were not palpable. Hematological studies showed a peripheral leukocyte count of 4600 ; 46 % neutrophils (1 % band form), 49 % lymphocytes, 2 % monocytes, 1 % eosinophil and 2 % basophils. The blood sedimentation rate was 9 mm in the first h, and C-reactive protein was negative. Blood glucose, urea, uric acid, electrolytes and protein concentrations were all within the normal range. Liver function tests were also normal : serum bilirubin, 0.82 mg/dl ; GOT, 10 IU ; GPT, 6 IU ; alkaline phosphatase, 5.4 K.A.U., and r-glutamyl

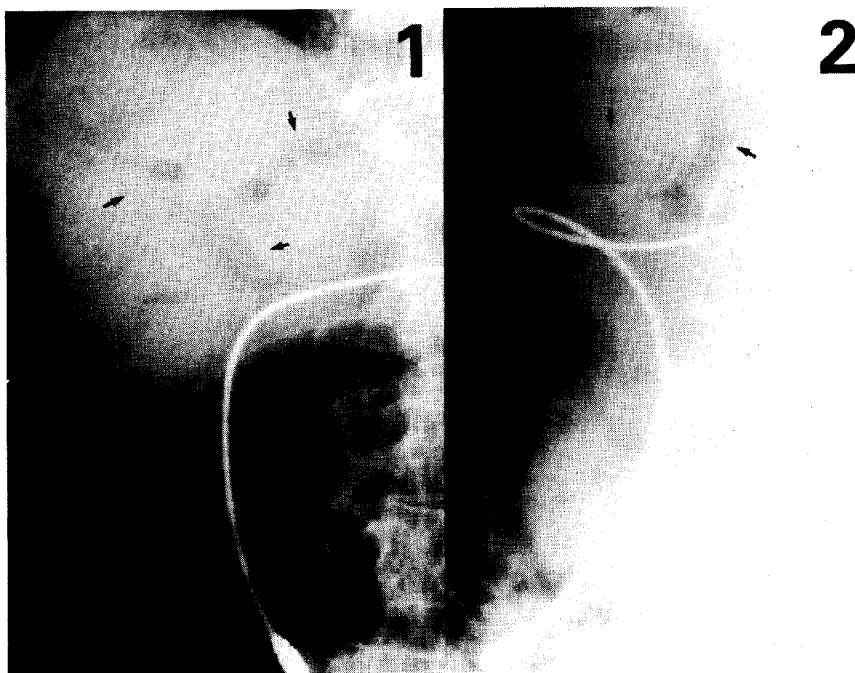


Fig. 1. Roentgenogram of the abdomen. Air-filled, branching structures (arrows) in the area corresponding to the liver under the right diaphragm. 1. Postero-anterior view in the standing position. 2. The 1st oblique position. Duodenal tubing for feeding barium into the duodenum can be seen.

transpeptidase, 48 U. Serum amylase activity was 176 Somogyi units, and amylase creatinine clearance was within the normal limit.

An air-filled branching structure, possibly in the intrahepatic biliary tract, was seen in the abdominal roentgenogram (Fig. 1). Cholecystograms by means of intravenous drip infusion showed no filling of the gallbladder. A barium meal examination showed that barium flowed backward naturally without pressure into the dilated extra-and intrahepatic bile ducts and also into the gallbladder. The gallbladder could not be extended enough and its shape was abnormal. The dilated cystic duct, which seemed to drain directly into the duodenum, was clearly demonstrated with the patient on his back, but on his abdomen only the dilated intra-and extrahepatic bile ducts could be observed. The barium remained in the intra-and extrahepatic bile ducts and gallbladder 4 h after the barium meal, but the next morning was mostly replaced by air. The time course of biliary opacification was examined in detail from the back by feeding barium directly into the second portion of the duodenum using a duodenal tube (Fig. 2). The extrahepatic biliary tract from the duodenum to the gallbladder was selectively

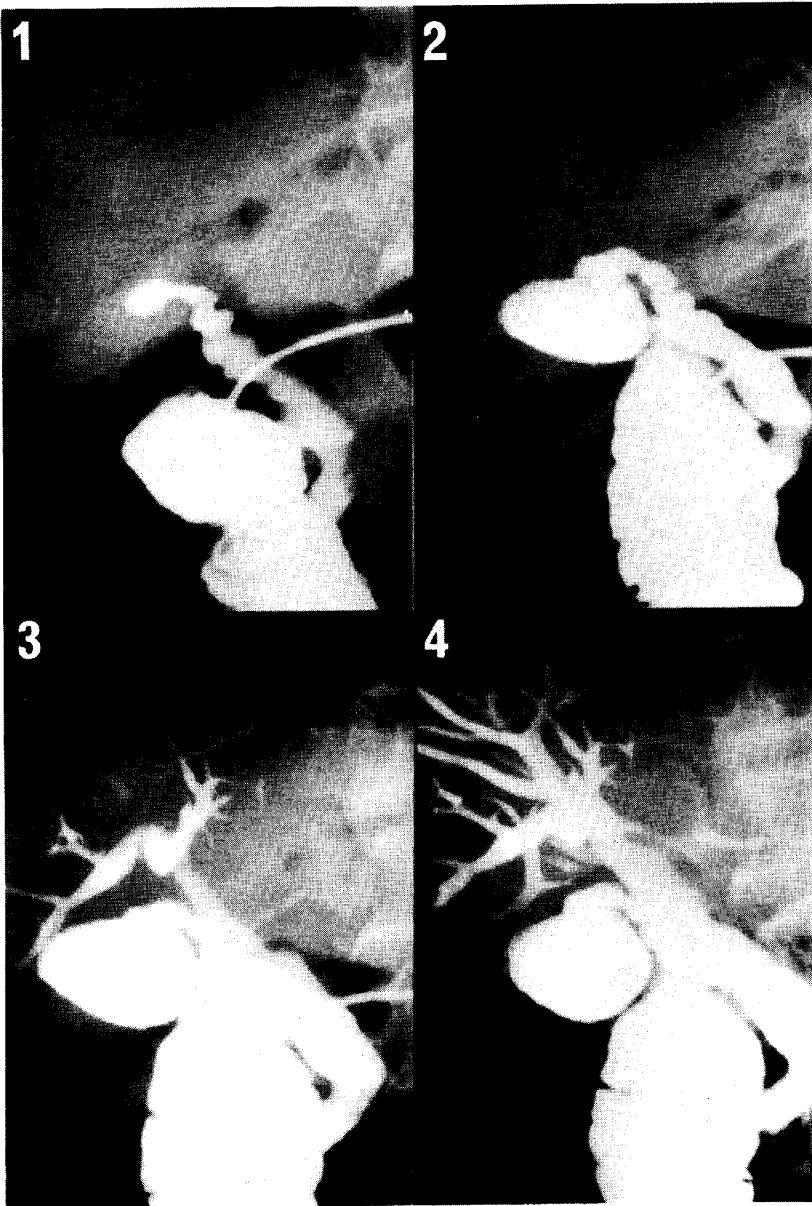


Fig. 2. Time course of opacification in the intra- and extrahepatic bile ducts by intermittent feeding barium into the duodenum. The cystic duct was first observed (1 and 2). The intra- and extrahepatic ducts could be seen only after the cystic duct and gallbladder were filled by the contrast medium (3 and 4). Photographs were taken in the supine position.

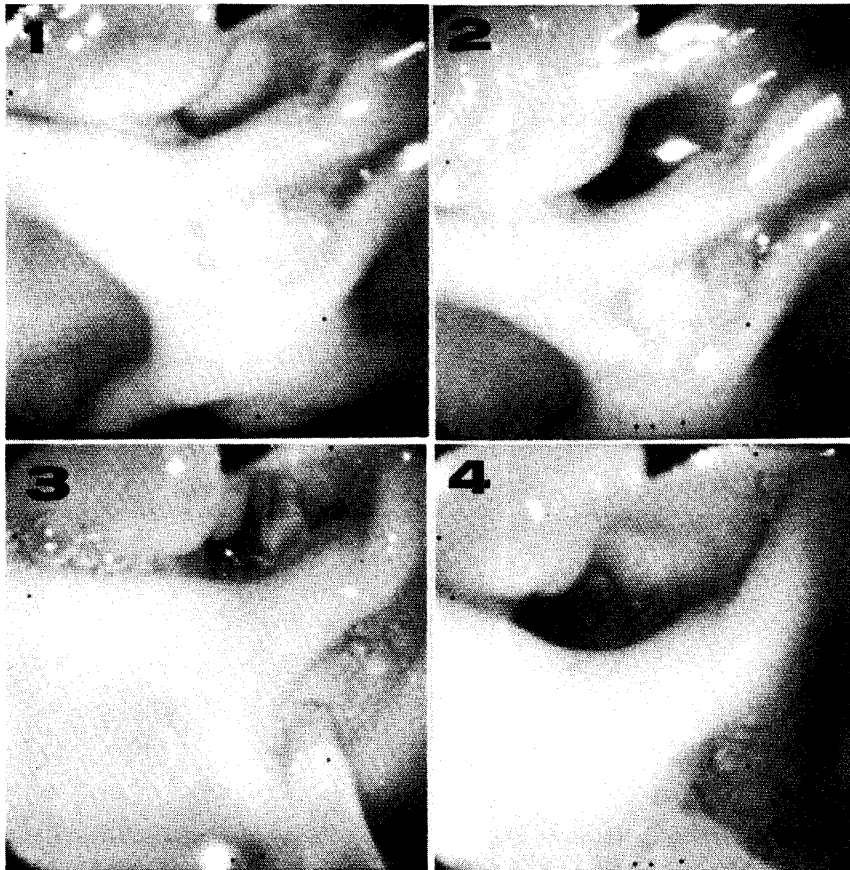


Fig. 3. Endoscopic close up views of a hole in the proximal portion of the protrusion (1, 2 and 4).  
3. Cannulation of the minor papilla.

opacified first and then the deformed gallbladder appeared. No flowing of barium into the hepatic biliary tract could be observed until this time. The biliary tract between the gallbladder and duodenum seemed to be coil-shaped even near the duodenum and to be a directly draining cystic duct. The intra- and extrahepatic biliary trees could be revealed only by further feeding of the contrast medium.

In order to evaluate the anatomical relation between the biliary tract and duodenum in more detail, endoscopic retrograde cholangiopancreatography using a duodenofiberscope was carried out. Duodenofiberscopic examination disclosed a protruded portion which was covered by normal duodenal mucosa. The major and minor papillas could be seen in the distal edge of the protrusion and in the flat central portion of the protrusion, respectively. The minor papilla was slightly edematous and reddish. A diverticulum-like opening was observed in the proximal

portion of the protrusion (Fig. 3), from which bile flow in large quantities was noted. Only the pancreatic duct, which was remarkably enlarged (12 mm in diameter) in the head and body and partially stenotic in the tail, could be visualized by cannulating the major papilla, but no leakage of the contrast medium could be seen from either the orifice of the minor papilla or the diverticulum-like hole (Fig. 4). By cannulating the minor papilla, the tip of another cannula was seen in the diverticulum-like hole (Fig. 3), and the cystic duct and common hepatic ducts could be separately opacified depending upon the length of the canula inserted, which observations suggest that there was separate drainage of the cystic duct and common hepatic duct. These endoscopic observations also indicated the existence of an internal fistula between the duodenum and biliary tract.

A pancreozymin-secretin test revealed normal pancreatic exocrine function : volume output, 4.24 ml/kg body weight ; maximum bicarbonate concentration, 104.7 mEq/l, and amylase output, 4933 Somogyi units/kg body weight. A serum amylase provocation test was also negative. Abdominal computed-tomography demonstrated branching low density areas in the liver which possibly corresponded

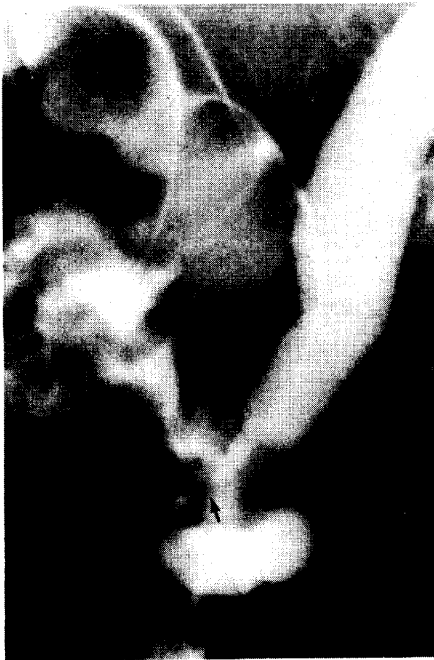

Fig. 4. Endoscopic retrograde cholangiopancreatographic findings. The arrow indicates an opening of the biliary tract other than that of the main pancreatic duct.

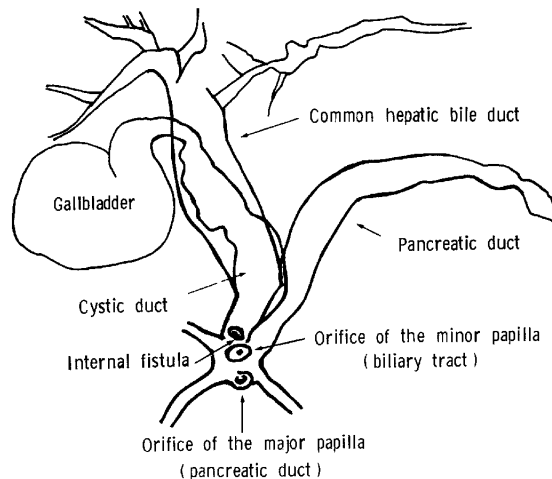


Fig. 5. Schematic illustration of the biliary and pancreatic ducts drawn from the endoscopic findings shown in Figs. 3 and 4.

to the air in the dilated intrahepatic bile ducts. The gallbladder could not be found and the pancreas seemed to be normal. Duodenal drainage was checked by a duodenal tubing: clear bile was drawn, but the peak volume and bilirubin concentrations did not correspond to B-bile. *E. coli*, *Pseudomonas* and *Klebsiella* were found in the bile. In abdominal ultrasonograms, neither the gallbladder nor a gallstone was detected. Peritoneoscopy showed an uneven surface of the liver and the white portion of liver capsules in places. Histological study of the liver biopsy specimen revealed proliferation of the bile ductules, demarcated fibrosis of the portal area and chronic interstitial inflammation without cholestasis. Fig. 5 is a schematic representation of the biliary and pancreatic duct and papilla of Vateri.

The patient's complaints at the time of admission disappeared 2 days following admission, and thereafter he had no complaint. He has had neither fever, abdominal pain nor jaundice during the past 2 years. He refused any operation.

#### DISCUSSION

From gastrointestinal endoscopic observations, this patient was thought to have direct drainage of the cystic duct into the duodenum and an internal fistula between the biliary tract and duodenum. However, a definite diagnosis can not be confirmed until anatomical evidence is obtained by operation or autopsy. Similar cases have been discovered incidentally at the time of autopsy or exploration of the abdomen for an unrelated condition (2, 3). Unusual in this case was that anomalies of the bile ducts could be observed endoscopically without an operation.

Junction of the cystic duct and common hepatic duct may occur in a high or very low position (4). The cystic and hepatic ducts may run parallel to each other (parallel type, 23 %) and the cystic duct may drain into the medial side of the common hepatic duct, crossing it either anteriorly or posteriorly (spiral type, 13 %) (5). A low junction in which the length of the parallel portion is more than 4 cm is very rare. Separate drainage of the biliary tract and pancreatic duct, as seen in this patient, has a frequency of 6 or 9 % (6, 7). However, there is little detailed statistical data on the biliary tract and Santorini canaliculi (ductus pancreaticus minor) simultaneously draining into the papilla duodeni minor. The pancreatic ductural system in this patient could not be visualized by feeding the contrast medium into the minor papilla.

The greater majority of choledochoduodenal fistulas have been reported to be due to erosion of a duodenal ulcer into the common bile duct. This patient had recurrent episodes of upper abdominal pain for about 8 years probably due to a gallstone, but then completely recovered. Formation of a persistent fistula in this patient can probably be explained by a gallstone becoming impacted in the distal biliary tract and then eroding into the duodenum. Reflux of duodenal



contents through the fistula to the biliary ducts may be a hazard, since various degrees of cholangitis and liver damage may result. The clinical manifestations of choledochoduodenal fistulas are one of the following two types ; symptoms due to an underlying cause such as a duodenal ulcer and symptoms related to a disease within the bile ducts and liver, exemplified by jaundice and hepatitis. Although the patient had no subjective complaints such as fever, jaundice and abdominal pain during the past 65 years, the white portion of capsules in an uneven surface of the liver was observed by peritoneoscopy, and chronic interstitial inflammation of the liver was also found microscopically.

*Acknowledgment.* We are indebted to Drs. H. Imai and K. Suwaki for performing the peritoneoscopic examination and pancreozymin-secretin test, respectively.

#### REFERENCES

1. Kehr, H.: Zweitausend Operationen an den Gallenwegen. *Deutsche Med. Wochenschr.* **39**, 775, 1913.
2. Cogbill, C.L. and Roth, H.P.: Choledochoduodenal fistula : report of 2 cases due to duodenal ulcer. *Am. Surg.* **19**, 480-488, 1953.
3. Iwamoto, T., Fujii, T., Ikeda, A., Tanaka, M., Nakayama, F. and Iwata, A.: Anomalies of the biliary tract. A case with direct drain of the cystic duct proved preoperatively by endoscopic retrograde pancreatico-cholangiography. *Jpn. J. Gastroenterol.* **77**, 1507, 1980.
4. Mester, E. and Molnar, J.: Malformations des voies biliaires extrahepatiques. *Lyon Chir.* **65**, 5-14, 1969.
5. Johnston, E.V. and Anson, B.J.: Variations in formation and vascular relationship of bile ducts. *Surg. Gynecol. Obstet.* **94**, 669-686, 1952.
6. Berman, L.G., Prior, J.T., Abramow, S.M. and Ziegler, D.D.: A study of the pancreatic duct system in man by the use of vinylacetate casts of postmortem preparation. *Surg. Gynecol. Obstet.* **110**, 391-403, 1960.
7. Millbourn, E.: On excretory ducts of the pancreas in man, with special reference to their relations to each other, to the common bile duct, and to the duodenum. *Acta Anat.* **9**, 1-34, 1950.