

Acta Medica Okayama

Volume 57, Issue 1

2003

Article 5

FEBRUARY 2003

Myofibroblasts proliferation of idiopathic and collagen vascular disorders associated nonspecific interstitial pneumonia.

Takashi Niimi*

Takeo Yoshinouchi†

Yuji Ohtsuki‡

Jiro Fujita**

Shigeki Sato††

Yoshiki Sugiura‡‡

Kazutaka Ohta§

Motoharu Kajiura¶

Ryuzo Ueda||

*Nagoya City University,

†Higashi Municipal Hospital of Nagoya,

‡Kochi Medical School,

**Kagawa Medical University,

††Nagoya City University,

‡‡Nagoya City University,

§Higashi Municipal Hospital of Nagoya,

¶Higashi Municipal Hospital of Nagoya,

||Nagoya City University,

Myofibroblasts proliferation of idiopathic and collagen vascular disorders associated nonspecific interstitial pneumonia.*

Takashi Niimi, Takeo Yoshinouchi, Yuji Ohtsuki, Jiro Fujita, Shigeki Sato, Yoshiki Sugiura, Kazutaka Ohta, Motoharu Kajiura, and Ryuzo Ueda

Abstract

Nonspecific interstitial pneumonia (NSIP) has been recognized as a separate histological classification of interstitial lung disease. Similar features are found not only in idiopathic NSIP, but also in NSIP associated with collagen vascular disorder (CVD-NSIP). We examined the clinical symptoms, laboratory findings, and prognosis of 13 cases of idiopathic NSIP and 11 cases of CVD-NSIP. Immunohistochemical staining was performed using the streptavidin/biotin/peroxidase method with anti-alpha-smooth muscle actin antibody. No differences in the distribution of clinical features, laboratory findings, and prognosis were observed between idiopathic NSIP and CVD-NSIP. In immunohistochemical staining of the fibrosing areas, myofibroblasts were observed in 7 of 13 idiopathic NSIP cases, but in 10 of 11 CVD-NSIP cases. With regards to intra-alveolar organization, myofibroblasts were observed in all 10 CVD-NSIP cases, but they were observed in only 2 of 9 idiopathic NSIP cases. We found a significantly higher myofibroblast proliferation in the intra-alveolar organization of CVD-NSIP compared to idiopathic NSIP. Clinically, idiopathic NSIP and CVD-NSIP are similar, but are pathologically different.

KEYWORDS: interstitial pneumonia, nonspecific interstitial pneumonia, myofibroblast, collagen vascular disorder

*PMID: 12765222 [PubMed - indexed for MEDLINE]

Original Article

Myofibroblasts Proliferation of Idiopathic and Collagen Vascular Disorders Associated Nonspecific Interstitial Pneumonia

Takashi Niimi^{a*}, Takeo Yoshinouchi^b, Yuji Ohtsuki^c, Jiro Fujita^d,
Shigeki Sato^a, Yoshiki Sugiura^a, Kazutaka Ohta^b,
Motoharu Kajiura^b, and Ryuzo Ueda^a

^aDepartment of Internal Medicine and Molecular Science, Nagoya City University Graduate School of Medical Science, Nagoya 467-8601, Japan,

^bDepartment of Internal Medicine, Higashi Municipal Hospital of Nagoya, Nagoya 464-8547, Japan,

^cDepartment of Pathology Kochi Medical School, Kochi 783-8505, Japan, and

^dFirst Department of Internal Medicine, Kagawa Medical University, Kagawa 761-0793, Japan

Nonspecific interstitial pneumonia (NSIP) has been recognized as a separate histological classification of interstitial lung disease. Similar features are found not only in idiopathic NSIP, but also in NSIP associated with collagen vascular disorder (CVD-NSIP). We examined the clinical symptoms, laboratory findings, and prognosis of 13 cases of idiopathic NSIP and 11 cases of CVD-NSIP. Immunohistochemical staining was performed using the streptavidin/biotin/peroxidase method with anti- α -smooth muscle actin antibody. No differences in the distribution of clinical features, laboratory findings, and prognosis were observed between idiopathic NSIP and CVD-NSIP. In immunohistochemical staining of the fibrosing areas, myofibroblasts were observed in 7 of 13 idiopathic NSIP cases, but in 10 of 11 CVD-NSIP cases. With regards to intra-alveolar organization, myofibroblasts were observed in all 10 CVD-NSIP cases, but they were observed in only 2 of 9 idiopathic NSIP cases. We found a significantly higher myofibroblast proliferation in the intra-alveolar organization of CVD-NSIP compared to idiopathic NSIP. Clinically, idiopathic NSIP and CVD-NSIP are similar, but are pathologically different.

Key words: interstitial pneumonia, nonspecific interstitial pneumonia, myofibroblast, collagen vascular disorder

Idiopathic interstitial pneumonia (IIP) has been classified into the following pathological types: usual interstitial pneumonia (UIP), desquamative interstitial pneumonia (DIP), acute interstitial pneumonia (DAD), bronchiolitis obliterans organizing pneumonia (BOOP), respiratory bronchiolitis interstitial lung disease (RB-ILD), and nonspecific interstitial pneumonia (NSIP)

[1, 2]. In 1994, Katzenstein and Fiorelli *et al.* reported on the clinical and pathological features of NSIP, the latter being characterized by various degrees of interstitial inflammatory or fibrosing processes that appeared temporally uniform within each case [2]. Frequently, BOOP and the intra-alveolar accumulation of macrophages are observed, but honey-combing is rarely present. Clinically, the condition often affects middle-aged females, who present with coughing, a low-grade fever, and dyspnea for several months, but who respond well to corticosteroid therapy and have a good prognosis [3, 4]. Recent

Received May 29, 2002; accepted September 24, 2002.

*Corresponding author. Phone: +81-52-853-8216; Fax: +81-52-852-0849
E-mail: tniimi@med.nagoya-cu.ac.jp (T. Niimi)

studies have also demonstrated that the clinical features of NSIP, compared with UIP, generally improve with corticosteroid therapy, and that patients with the disease have a good prognosis [4-9]. Similar pathological findings may be exhibited not only by idiopathic interstitial pneumonia, but also interstitial pneumonia associated with collagen vascular disease [3]. However, to our knowledge, there have been no studies comparing idiopathic NSIP and NSIP associated with collagen vascular disorder (CVD-NSIP).

Myofibroblasts are cells which have ultrastructural features intermediate in form to those of fibroblasts and smooth muscle cells. Myofibroblasts vary in the types of contractile and intermediate filaments they express. They have been suggested to play a role in wound contraction and in the retractile phenomena observed during fibrotic diseases. It has been reported that many myofibroblasts were observed in both the intra-alveolar organization and the fibroblastic foci of UIP [10-14]. In our previous study, the appearance of myofibroblasts differed between idiopathic UIP and the UIP of rheumatoid arthritis-associated interstitial pneumonia (RA-IP) [14]. In RA-IP, myofibroblasts were widely observed, together with the pathological patterns of honeycombing, UIP and bronchiolitis obliterans organizing pneumonia (BOOP), whereas in idiopathic pulmonary fibrosis (IPF) cases, the fibrosis was mainly characterized by a lack of myofibroblasts [14]. This suggests that IPF and RA-IP could be differentiated from each other on the basis of myofibroblast proliferation. To investigate whether differences exist between idiopathic NSIP and CVD-NSIP, we compared the clinical features of idiopathic NSIP and CVD-NSIP, and also investigated the immunohistochemical staining of myofibroblasts in the 2 groups.

Materials and Methods

Subjects. Thirteen idiopathic NSIP and 11 CVD-NSIP patients, all diagnosed as NSIP by open lung biopsy from 1993 to 1998, were studied. Of the CVD-NSIP cases, 7 were suffering from polymyositis (PM) or dermatomyositis (DM), 2 from progressive systemic scleroderma (PSS), and 2 from the Sjogren syndrome (SjS). The idiopathic NSIP patients consisted of 8 males and 5 females, with a mean age of 64.3 ± 7.2 (mean \pm SD) years. All CVD-NSIP patients were females with a mean age of 54.5 ± 9.9 years. Six of the

idiopathic NSIP and none of the CVD-NSIP patients were smokers. All pathological specimens were analyzed in accordance with the NSIP criteria described by Katzenstein and Fiorelli [3].

Laboratory examinations and pulmonary function tests. Peripheral blood samples were obtained before breakfast, and the white blood cells (WBC) were assessed. After centrifugation at 1000 g for 10 min, the serum was stored at -70°C , and lactate dehydrogenase (LDH) was then measured. Arterial blood samples were analyzed for PaO_2 and PaCO_2 , and the bronchoalveolar lavage fluid (BALF), cell differentiation count, and OKT4/8 ratio were evaluated. As a pulmonary function test, the percentage of predicted vital capacity (%VC) and percentage of carbon monoxide diffusing capacity of the lung (%DLCO) were also measured.

To assess the therapeutic response, 3 categories based on those established by Nagai *et al.* were defined: condition improved, condition unchanged, and condition worsened (radiographically and functionally). Clearance of $\geq 20\%$ in shadow areas on chest radiographs and changes of $+20\%$ in the measured values of the pulmonary functions were evaluated as the patients' conditions improved. An increase of $\geq 20\%$ or more in the shadow areas, and changes of -20% in the measured values of the pulmonary functions, were evaluated as patients' conditions worsened [5].

Immunohistochemical staining. Specimens from the 13 idiopathic NSIP cases and 11 CVD-NSIP cases studied were examined by immunohistochemical staining. Lung biopsy specimens were fixed in 10% neutral buffered formalin solution, cut into slices, embedded in paraffin, and sectioned at $5\ \mu\text{m}$ for histological evaluation. Immunohistochemical staining was performed using the streptavidin/biotin/peroxidase method with anti-vimentin, anti-desmin (Dakopatts, Glostrup, Denmark) and anti α -smooth muscle actin (α -SMA) antibody (Bio Marker, Rehovot, Israel) (Figs. 1A, 1B). The presence of myofibroblasts within the fibrosing area and intra-alveolar lesions was determined according to immunohistochemical staining, *i.e.*, myofibroblasts are vimentin-positive, α -SMA-positive, and desmin-negative as reported previously [14, 15]. The distribution of myofibroblasts in each section was evaluated according to a 4-point scale: 3 = many myofibroblastic foci, 2 = some myofibroblastic foci in parts, 1 = only focal myofibroblastic foci, 0 = no myofibroblastic foci. Smooth

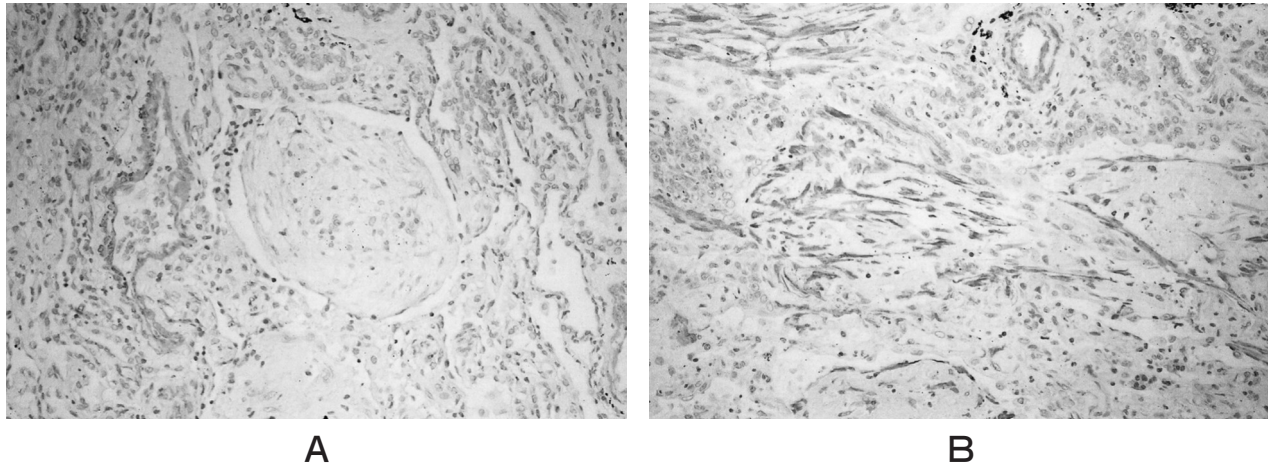


Fig. 1 (A) Negative immunoreactivity of intra-alveolar organization with anti- α smooth muscle actin antibody in idiopathic NSIP ($\times 220$). (B) Positive reaction of myofibroblasts with anti- α smooth muscle actin antibody in intra-alveolar organization of CVD-NSIP ($\times 220$).

muscle cells in the perivascular areas, which were positive for α -SMA, were excluded from the evaluation.

Statistical Analysis. Comparison of the clinical features, laboratory findings, and BALF between the idiopathic NSIP and CVD-NSIP was performed using the Students-*t* or chi-square tests. The relationship between the presence of myofibroblasts and the response to therapy were also analyzed with Fisher's exact test. Kaplan-Meier survival curves were plotted, and the survival curves were compared by the log rank test. A *P* value of < 0.05 was considered significant.

Results

Clinical features, laboratory findings. A higher percentage of CVD-NSIP cases were females, and they were also younger on average than the idiopathic NSIP cases. Smokers were more numerous among cases of idiopathic NSIP. These differences were statistically significant. Regarding clinical symptoms, in idiopathic NSIP, fever, cough, and dyspnea were found in 3 of 13, 10 of 13, and 10 of 13 cases, respectively, and in CVD-NSIP, in 5 of 11, 8 of 13, and 9 of 13 cases. No significant differences in the distribution of these symptoms were observed. A comparison of the laboratory findings (WBC, LDH, %VC, %DLCO, PaO₂, PaCO₂), also revealed no differences between idiopathic NSIP and CVD-NSIP. In BALF, increased lymphocytes were observed in both groups, without, however, significant variation (Table 1).

Therapy and prognosis. Of the 13 idiopathic NSIP patients, corticosteroids were administered to 11, and an immunosuppressive agent plus corticosteroids to 2. Of the 11 CVD-NSIP patients, 7 cases received corticosteroids, and 4 an immunosuppressive agent plus corticosteroids. In the 13 idiopathic NSIP cases receiving therapy, 11 patients improved, 1 case died because of respiratory failure, and 1 case remained alive with no response. In the 11 CVD-NSIP cases receiving therapy, 7 cases improved, 2 cases died of respiratory failure, and 2 cases survived with no response (Table 1). No significant difference in survival was evident between the idiopathic NSIP and CVD-NSIP groups (data not shown).

Immunohistochemical staining. In the immunostaining of the fibrosing areas of the 13 idiopathic NSIP cases, myofibroblasts were observed in 7 cases, and not in the remaining 6 cases, whereas in the 11 CVD-NSIP cases, myofibroblasts were observed in 10 cases, and not in the remaining case. We found a significant increase of myofibroblasts in CVD-NSIP compared with idiopathic NSIP ($P < 0.05$) (Table 2).

Intra-alveolar organization was found in 9 of the 13 idiopathic NSIP cases evaluated. Of the 9 idiopathic NSIP cases with intra-alveolar organization, myofibroblasts were observed in 2 cases, but not in the remaining 7. Of the 11 CVD-NSIP cases evaluated, intra-alveolar organization was found in 10 cases, all of which contained myofibroblasts (Figs. 1A, 1B). The difference in the appearance of myofibroblasts in the areas

Table 1 Patients characteristics

Case	Age/Sex (yrs)	Diagnosis	Myofibroblasts		Fever	Coughing	Dyspnea	WBC (μ l)	LDH (w.u)	%VC (%)	%DLCO (%)	PaO ₂ (Torr)	PaCO ₂ (Torr)	BALF Ly(%)	Treatment	Response
1	60 M	IIP	0	0	—	—	+	5400	410	69.0	70.1	68.0	30.4	95	Steroid	I
2	60 M	IIP	2	2	—	+	+	8600	554	80.2	97.4	80.0	47.7	21	Steroid+CPM	D
3	51 F	IIP	0	0	+	+	—	6300	239		39.2	74.9	41.6	36	Steroid	I
4	74 M	IIP	1	0	—	—	+	10000	600	132.0	103.0	79.4	40.7		Steroid	I
5	66 M	IIP	0	0	+	+	+	10900	441			57.2	30.2	3	Steroid	I
6	74 M	IIP	1	0	—	—	+	5000	286		57.2	65.2	46.9	15	Steroid	I
7	52 F	IIP	2		—	+	—	7500	487	85.7	56.7	88.0	38.3	20	Steroid	I
8	66 F	IIP	2	2	—	+	—	7300	558	62.1	83.0	66.5	36.8	8	Steroid+CPM	N
9	62 F	IIP	0		—	+	+	7000	492	54.9	60.2	52.9	41.0	80	Steroid	I
10	67 F	IIP	2		+	+	+	10900	628		62.1	42.0	35.0	20	Steroid	I
11	69 M	IIP	0	0	—	+	+	4600	288	94.8	101.0	78.8	47.4	5	Steroid	I
12	67 M	IIP	0	0	—	+	+	9800	251		70.8	74.9	35.9	36	Steroid	I
13	69 M	IIP	2		—	+	+	5000	408	40.9	71.3	67.0	35.7	40	Steroid	I
14	40 F	DM	3	3	+	+	+	2500	1582						Steroid+CPM	D
15	55 F	DM	2	2	—	—	+	9600	1068		73.2	68.0	35.4		Steroid+CPM	I
16	44 F	DM	2	3	+	—	+	2700	460	57.7	86.3	84.3	33.8	21	Steroid+CPM	D
17	69 F	DM	3	2	—	—	—	14500	860	104.0	76.5	73.2	45.4		Steroid	I
18	45 F	DM	1	1	—	+	+	10800	318		53.0	72.0	47.0	16	Steroid	I
19	55 F	DM	3	1	—	+	+	4100	254		62.1	72.0	38.0		Steroid	I
20	47 F	PM	0		—	+	+	3900	1019		65.8	68.4	36.8	54	Steroid	I
21	58 F	PSS	3	3	+	+	+	5600	496	42.0	63.0	98.0	35.6	3	Steroid	N
22	56 F	PSS	3	3	+	+	+	10700	520	47.0	104.0	81.5	28.4	6	Steroid+CPM	N
23	71 F	SjS	2	1	—	+	+	5500	506	58.0	60.2	81.6	38.8	91	Steroid	I
24	59 F	SjS	3	2	+	+	—	6300	404	57.3	61.8	71.6	47.7	20	Steroid	I

3 = many myofibroblastic foci, 2 = some myofibroblastic foci in parts, 1 = only focal myofibroblastic foci, 0 = no myofibroblastic foci, CPM = cyclophosphamide, I = improve, N = no changed, D = death

Table 2 Myofibroblasts in fibrosing areas

	Appearance of myofibroblasts	
	Positive	Negative
Idiopathic NSIP (13)	7	6
CVD-NSIP (11)	10	1

$P < 0.05$

Table 3 Myofibroblasts in intraalveolar organization

Intraalveolar organization positive	Appearance of myofibroblasts	
	Positive	Negative
Idiopathic NSIP (9/13)	2	7
CVD-NSIP (10/11)	10	0

$P < 0.001$

of intra-alveolar organization was statistically significant ($P < 0.001$) (Table 3). In the 9 idiopathic NSIP cases with intra-alveolar organization, the 2 myofibroblast positive cases did not improve after therapy, but the 7 myofibroblast negative cases showed improvement. In the 10 intra-alveolar organization positive CVD-NSIP cases, 6 cases improved after therapy, but 4 cases showed no improvement after therapy.

Discussion

In our series of 24 cases of NSIP, 18 (75%) responded well to corticosteroid therapy with a good overall prognosis. However, NSIP is not a separate disease entity, and includes interstitial pneumonia associated collagen vascular disease in 16% of the cases, and various other diseases as reported by Katzenstein [2]. The present comparative study of idiopathic NSIP and CVD-NSIP, however, revealed no significant differences

in clinical symptoms, laboratory data, or BALF cell fractions between the two, with no variation in responsiveness to treatment or prognosis. Pathologically, we noted a significant difference in the presence or absence of myofibroblasts in the fibrosing areas and in the intra-alveolar organization.

Myofibroblasts develop several ultrastructural and biochemical features of smooth muscle cells, including the presence of microfilament bundles and the expression of α -SMA, the actin isoform present in smooth muscle cells. Myofibroblasts have been suggested to play a role in wound contraction and in the retractile phenomena observed during fibrotic diseases. The existence of myofibroblasts in human lung disease, as well as in animal models of airway and interstitial disease, has been recognized for some time [15]. Mitchell *et al.* were the first to demonstrate that these cells often contain SMA [16]. For example, in bleomycin-induced fibrosis in the rat, predominant SMA antibody reactivity is observed in areas of parenchymal damage within days of bleomycin instillation [15, 16]. SMA-positive myofibroblasts also occur in other forms of lung disease, including hypersensitivity pneumonitis, BOOP, and IPF [17]. Myofibroblasts play important roles in the remodeling in pulmonary fibrosis. Following pulmonary injury or inflammation, myofibroblasts differentiate from fibroblasts and migrate from intra-alveolar septa into alveoli, where they produce collagen on stimulation by growth factors, with remodeling to fibrosis [10–13]. Our previous study showed that in IPF which is pathologically diagnosed as UIP, less proliferation of myofibroblasts occurs than in RA-IP [14]. In the present study, myofibroblasts were apparent in intra-alveolar organization in all cases of CVD-NSIP, but in only 2 cases of idiopathic NSIP out of 9. Thus, the background for the induction of myofibroblasts allowing fibrosis to progress differs in CVD-NSIP and idiopathic NSIP. This result may also be in line with the previous findings that IIP differs from interstitial pneumonia associated with collagen vascular disease in terms of the mechanisms underlying fibrosis.

We previously found a correlation between the presence or absence of myofibroblasts in intra-alveolar organization and responsiveness to steroids in cases of BOOP [18]. This is analogous to the relationship between the presence or absence of myofibroblasts in intra-alveolar organization and resistance to treatment in cases of idiopathic NSIP. Therefore, with some types of IIP, the presence or absence of myofibroblasts in intra-alveolar

organization might be associated with responsiveness to therapy. However, there is a possibility that patients with idiopathic NSIP who are positive for myofibroblasts in intra-alveolar organization may develop collagen disease in the future, and we therefore need to follow these patients carefully. Moreover, this relationship between the presence of myofibroblasts and the effect of therapy was not indicated in the CVD-NSIP cases.

On the basis of previous studies of myofibroblasts in fibroblast foci in IPF, pulmonary fibrosis is considered to begin with intra-alveolar fibrosis [2, 19]. In NSIP, however, the foci of fibrosis do not match the proliferation of myofibroblasts in intra-alveolar organization. This observation makes it difficult to conclude that interstitial fibroblasts have infiltrated into the intra-alveolar organization, which may have been formed by a different mechanism in NSIP. Moreover, it is possible that the formation of intra-alveolar organization in idiopathic NSIP and CVD-NSIP is completely different. In any case, it is evident from observations in cases of BOOP alone that a better response to steroids is achieved in cases where myofibroblasts fail to appear in intra-alveolar organization. This is an interesting finding, which is also worth bearing in mind when considering the formation of intra-alveolar organization.

The causes of the differences in the presence of myofibroblasts in NSIP remains unclear. However, several factors, such as transforming growth factor beta (TGF- β) and platelet derived growth factor (PDGF), are reported to influence cell proliferation and the growth of myofibroblasts. TGF- β induces α smooth muscle actin expression in fibroblasts, so that they acquire the myofibroblast phenotype. TGF- β is expressed at significantly high levels in lung fibrosis [10, 11, 20–22]. PDGF is also reported to have mitogenic effects on cells, including myofibroblasts, with importance emphasized in fibroproliferative disease [12, 23, 24]. If the type or amounts of these factors differ between idiopathic NSIP and CVD-NSIP, this might explain the variation in appearance of the myofibroblasts found in this study. Further investigation of these factors is necessary to clarify the role of myofibroblasts in the remodeling of NSIP or other pulmonary fibrosis.

References

1. American Thoracic Society: Idiopathic pulmonary fibrosis: Diagnosis and treatment. International consensus statement. American Thoracic

- Society (ATS), and the European Respiratory Society (ERS). *Am J Respir Crit Care Med* (2000) 161: 646-664.
2. Katzenstein AL and Myers JL: Idiopathic pulmonary fibrosis: Clinical relevance of pathologic classification. *Am J Respir Crit Care Med* (1998) 157: 1301-1315.
 3. Katzenstein AL and Fiorelli RF: Nonspecific interstitial pneumonia/fibrosis. Histologic features and clinical significance. *Am J Surg Pathol* (1994) 18: 136-147.
 4. Michaelson JE, Aguayo SM and Roman J: Idiopathic pulmonary fibrosis: A practical approach for diagnosis and management. *Chest* (2000) 118: 788-794.
 5. Nagai S, Kitaichi M, Itoh H, Nishimura K, Izumi T and Colby TV: Idiopathic nonspecific interstitial pneumonia/fibrosis: Comparison with idiopathic pulmonary fibrosis and BOOP. *Eur Respir J* (1998) 12: 1010-1019.
 6. Bjoraker JA, Ryu JH, Edwin MK, Myers JL, Tazelaar HD, Schroeder DR and Offord KP: Prognostic significance of histopathologic subsets in idiopathic pulmonary fibrosis. *Am J Respir Crit Care Med* (1998) 157: 199-203.
 7. Cottin V, Donsbeck AV, Revel D, Loire R and Cordire JF: Nonspecific interstitial pneumonia. Individualization of a clinicopathologic entity in a series of 12 patients. *Am J Respir Crit Care Med* (1998) 158: 1286-1293.
 8. Daniil ZD, Gilchrist FC, Nicholson AG, Hansell DM, Harris J, Colby TV and du Bois RM: A histological pattern of nonspecific interstitial pneumonia is associated with a better prognosis than usual interstitial pneumonia in patients with cryptogenic fibrosing alveolitis. *Am J Respir Crit Care Med* (1999) 160: 899-905.
 9. Fujita J, Yamadori I, Suemitsu I, Yoshinouchi T, Ohtsuki Y, Yamaji Y, Kamei T, Kobayashi M, Nakamura Y and Takahara J: Clinical features of non-specific interstitial pneumonia. *Respir Med* (1999) 93: 113-118.
 10. Kuhn C and McDonald JA: The roles of myofibroblast in idiopathic pulmonary fibrosis. Ultrastructural and immunohistochemical features of sites of active extracellular matrix synthesis. *Am J Pathol* (1991) 138: 1257-1265.
 11. Phan SH: Role of the myofibroblast in pulmonary fibrosis. *Kidney Int Supple* (1996) 54: S46-S48.
 12. Phan SH, Zhang K, Zhang HY and Gharaee-Kermani M: The myofibroblast as inflammatory cell in pulmonary fibrosis. *Curr Top Pathol* (1999) 93: 173-182.
 13. Low RB: Modulation of myofibroblast and smooth-muscle phenotypes in the lung. *Curr Top Pathol* (1999) 93: 19-26.
 14. Yoshinouchi T, Ohtsuki Y, Ueda R, Sato S and Ueda N: Myofibroblasts and S-100 protein positive cells in idiopathic pulmonary fibrosis and rheumatoid arthritis-associated interstitial pneumonia. *Eur Respir J* (1999) 14: 579-584.
 15. Kapanci Y and Gabbiani G: Contractile cells in pulmonary alveolar tissue; in *The Lung: Specific Foundations*, Crystal RG and West JB eds, Lippincott-Raven, Philadelphia (1997) pp 697-707.
 16. Mitchell J, Woodcock-Mitchell J, Reynolds S, Low R, Leslie K, Adler K, Gabbiani G and Skalli O: Alpha-smooth muscle actin in parenchymal cells of bleomycin-injured rat lung. *Lab Invest* (1989) 60: 643-650.
 17. Leslie K, King TE Jr and Low R: Smooth muscle actin is expressed by airspace fibroblast-like cells in idiopathic pulmonary fibrosis and hypersensitivity pneumonitis. *Chest* (1991) 99: 47S-48S.
 18. Yoshinouchi T, Ohtsuki Y, Kubo K and Shikata Y: Clinicopathological study on two types of cryptogenic organizing pneumonitis. *Respir Med* (1995) 89: 271-278.
 19. Fukuda Y, Basset F, Ferrans VJ and Yamanaka N: Significance of early intra-alveolar fibrotic lesions and integrin expression in lung biopsy specimens from patients with idiopathic pulmonary fibrosis. *Hum Pathol* (1995) 26: 53-61.
 20. Desmouliere A, Geinoz A, Gabbiani F and Gabbiani G: Transforming growth factor- β 1 induces α -smooth muscle actin expression in granulation tissue myofibroblasts and in quiescent and growing cultured fibroblasts. *J Cell Biol* (1993) 122: 1103-1111.
 21. Narayanan AS, Page RC and Swanson J: Collagen synthesis by human fibroblasts. Regulation by transforming growth factor- β in the presence of other inflammatory mediators. *Biochem J* (1989) 262: 463-469.
 22. Zhang HY, Gharaee-Kermani M, Zhang K, Karmiol S and Phan SH: Lung fibroblast α -smooth muscle actin expression and contractile phenotype in bleomycin-induced pulmonary fibrosis. *Am J Pathol* (1996) 148: 527-537.
 23. Bonner JC, Lindroos PM, Rice AB, Moomaw CR and Morgan DL: Induction of PDGF receptor- α in rat myofibroblasts during pulmonary fibrogenesis *in vivo*. *Am J Physiol* (1998) 274: L72-L80.
 24. Ohga E, Matsuse T, Teramoto S, Katayama H, Nagase T, Fukuchi Y and Ouchi Y: Effects of activin A on proliferation and differentiation of human lung fibroblasts. *Biochem Biophys Res Commun* (1996) 228: 391-396.