

Acta Medica Okayama

Volume 61, Issue 6

2007

Article 5

DECEMBER 2007

Routine Transurethral Biopsy of the Bladder is not Necessary to Evaluate the Response to Bacillus Calmette-guerin Therapy

Takanori Murakami, *Himeji St. Mary's Hospital*

Shin Ebara, *Okayama University*

Takashi Saika, *Okayama University*

Shin Irie, *Okayama Central Hospital*

Katsuji Takeda, *Kagawa Prefectural Hospital*

Yoshio Maki, *Konko Hospital*

Sadayuki Miyaji, *Kawasaki Medical School Hospital*

Daisuke Manabe, *Kagawa Prefectural Hospital*

Haruki Kaku, *Okayama University*

Yasutomo Nasu, *Okayama University*

Tomoyasu Tsushima, *National Okayama Hospital*

Hiroki Kumon, *Okayama University*

Routine Transurethral Biopsy of the Bladder is not Necessary to Evaluate the Response to Bacillus Calmette-guerin Therapy*

Takanori Murakami, Shin Ebara, Takashi Saika, Shin Irie, Katsuji Takeda, Yoshio Maki, Sadayuki Miyaji, Daisuke Manabe, Haruki Kaku, Yasutomo Nasu, Tomoyasu Tsushima, and Hiromi Kumon

Abstract

We evaluated the need for transurethral biopsy at first follow-up after intravesical bacillus Calmette-Guerin (BCG) therapy for superficial bladder cancer. The records of 84 patients with superficial bladder cancer who received a 6- or 8-week course of BCG were reviewed. Pathological results before BCG, cystoscopic findings, urinary cytology, and biopsy results for evaluation of BCG therapy were reviewed. All 19 patients with positive urinary cytology had evidence of positive bladder biopsy results. Fifty-three of 54 patients (98.1%) with no visible recurrent tumor and negative urinary cytology demonstrated negative pathological results on bladder biopsy. When not found in conjunction with positive urinary cytology, erythematous mucosa on cystoscopy was not an indicator of tumor recurrence or residual cancer. In conclusion, routine transurethral biopsy of the bladder for evaluating the response to BCG intravesical therapy is not necessary in patients who have no visible tumor on cystoscopy and negative urinary cytology./

KEYWORDS: bladder cancer, BCG therapy, transurethral biopsy, cystoscopy, urinary cytology

Original Article

Routine Transurethral Biopsy of the Bladder Is Not Necessary to Evaluate the Response to Bacillus Calmette-Guerin Therapy

Takanori Murakami^a, Shin Ebara^b, Takashi Saika^{b*}, Shin Irie^c,
Katsuji Takeda^d, Yoshio Maki^e, Sadayuki Miyajiri^f, Daisuke Manabe^d,
Haruki Kaku^b, Yasutomo Nasu^b, Tomoyasu Tsushima^g, and Hiromi Kumon^b

^aDepartment of Urology, Himeji St. Mary's Hospital, Himeji, Hyogo 670-0801, Japan,

^bDepartment of Urology, Okayama University Graduate School of Medicine,
Dentistry and Pharmaceutical Sciences, Okayama 700-8558, Japan,

^cDepartment of Urology, Okayama Central Hospital, Okayama 700-0017, Japan,

^dDepartment of Urology, Kagawa Prefectural Hospital, Takamatsu 760-8557, Japan,

^eDepartment of Urology, Konko Hospital, Asakuchi, Okayama 719-0104, Japan,

^fDepartment of Urology, Kawasaki Medical School Hospital, Kurashiki,
Okayama 701-0192, Japan, and

^gDepartment of Urology, National Okayama Hospital, Okayama 701-1192, Japan

We evaluated the need for transurethral biopsy at first follow-up after intravesical bacillus Calmette-Guerin (BCG) therapy for superficial bladder cancer. The records of 84 patients with superficial bladder cancer who received a 6- or 8-week course of BCG were reviewed. Pathological results before BCG, cystoscopic findings, urinary cytology, and biopsy results for evaluation of BCG therapy were reviewed. All 19 patients with positive urinary cytology had evidence of positive bladder biopsy results. Fifty-three of 54 patients (98.1%) with no visible recurrent tumor and negative urinary cytology demonstrated negative pathological results on bladder biopsy. When not found in conjunction with positive urinary cytology, erythematous mucosa on cystoscopy was not an indicator of tumor recurrence or residual cancer. In conclusion, routine transurethral biopsy of the bladder for evaluating the response to BCG intravesical therapy is not necessary in patients who have no visible tumor on cystoscopy and negative urinary cytology.

Key words: bladder cancer, BCG therapy, transurethral biopsy, cystoscopy, urinary cytology

Ta or T1 and G3 superficial bladder cancer patients have a lifelong risk of progression and require particular attention [1, 2]. Bacillus Calmette-Guerin (BCG) is currently the most effective intravesical therapy for managing this high-risk

group, including carcinoma *in situ* (CIS) [3, 4]. Evaluations after BCG intravesical therapy are based on cystoscopic findings, urinary cytology and routine transurethral bladder biopsy. Because bladder biopsy is a more invasive and costly procedure than cystoscopy and urinary cytology, some urologists suggest omitting routine biopsy [5] while many urologist teams advocate biopsy in all patients following BCG therapy regardless of cystoscopic and/or cytologic

Received June 18, 2007; accepted August 10, 2007.

*Corresponding author. Phone: +81-86-235-7287; Fax: +81-86-231-3986

E-mail: saika@cc.okayama-u.ac.jp (T. Saika)

findings. We reviewed the records of patients with high-grade superficial bladder cancer who received BCG therapy and assessed the need for routine trans-urethral biopsy.

Materials and Methods

The records of 84 patients with superficial bladder cancer who received a 6- or 8-week course of BCG intravesical therapy consisting of intravesical administration of 80 mg BCG in 40 ml saline solution were reviewed.

The criteria for patients receiving BCG therapy were 1) recurrence of tumors at least 3 times, 2) grade 3 pathological results, or 3) CIS disease. All 84 patients underwent a bladder biopsy after 1-2 months of BCG therapy. The biopsy was performed on target lesions and with a routine random biopsy procedure [5]. Tumors were staged according to the TNM (tumor, node, metastases) staging system. Post-treatment cystoscopic findings and urinary cytology were analyzed: cystoscopic findings were documented as recurrent tumor, erythematous mucosa, or negative; urinary cytology was categorized as positive if malignant cells or suspicious cells were seen and negative if cells were described as negative or atypical.

Results

Eighty-four patients aged 48 to 87 years old (median 68) received BCG intravesical therapy. Thirty-seven patients had tumor recurrence 3 times or

Table 1 Patient characteristics

	No. of patients	
Tumor size (mm)	< 10	31
	10~30	21
	> 30	3
	unclear	29
Grade	G1	3
	G2	24
	G3	57
T stage	Tis	36
	Ta	21
	T1	27

more, 57 had grade 3 pathological findings and 65 had Tis disease before therapy. All 29 patients with unclear tumor size had a CIS lesion. Table 1 shows the patient characteristics.

Table 2 shows the results of BCG therapy in the 84 patients as evaluated by routine biopsy. All 19 patients with positive urinary cytology had evidence of positive bladder biopsy results. Of the 65 cases with negative cytology, 53 patients demonstrated negative bladder biopsy results. Seven of 13 patients (53.8%) with erythematous bladder mucosa on cystoscopic findings and 6 of 53 patients (11.3%) with negative cystoscopic findings had positive biopsy results. Fifty-three of 54 patients (98.1%) with negative/erythematous mucosa on cystoscopic findings and negative urinary cytology had negative bladder biopsy results. Overall, urine cytology for all patients had a sensitivity, specificity and positive predictive value of 61.3%, 100% and 1.00, respectively.

Table 3 shows the results in patients with CIS lesions. Urine cytology for patients with CIS had a sensitivity, specificity and positive predictive value of 83.3%, 100% and 1.00, respectively. We focused on the 43 patients with Tis disease before treatment and

Table 2 Results of Post-BCG biopsy (all patients)

Cystoscopic findings	Positive cytology		Negative cytology		Total
	biopsy positive	biopsy negative	biopsy positive	biopsy negative	
Tumor	7	0	11	0	18
Erythema	7	0	0	6	13
Negative	5	0	1	47	53
Total	19	0	12	53	84

Table 3 Results of Post-BCG biopsy (patients with CIS)

Cystoscopic findings	Positive cytology		Negative cytology		Total
	biopsy positive	biopsy negative	biopsy positive	biopsy negative	
Tumor	4	0	2	0	6
Erythema	6	0	0	5	11
Negative	5	0	1	42	48
Total	15	0	3	47	65

negative urinary cytology and negative cystoscopic findings after BCG therapy. Only 1 patient (2.1%) demonstrated G2, Ta urothelial carcinoma (Fig. 1) by biopsy.

Discussion

Evaluations of response to BCG therapy are usually based on cystoscopic findings, urinary cytology and histological results on routine biopsy. Urinary cytology results in patients with high-grade cancer (especially CIS) are mostly positive, and cystoscopic findings in such patients are commonly abnormal [6]. Our criteria for BCG intravesical therapy were symptoms of high-risk superficial bladder cancer, including frequent tumor recurrence, grade 3 pathology, and CIS histological findings. All 19 of 19 patients (100%) with positive cytology and/or positive cystoscopic findings had positive bladder biopsy results. Moreover, there was no patient with positive cytology and negative biopsy results. These results might indicate that patients with positive urinary cytology after BCG could be defined as treatment failure without routine bladder biopsy evaluation.

Dalbagni *et al.* [7] were the first to question the need for routine biopsy after BCG treatment. After

reviewing the data, they concluded that biopsy at 3 months after BCG is not necessary if cystoscopy is normal or erythema is seen with normal urine cytology. Skemp *et al.* [8] concluded that patients with negative cystoscopy and negative urine cytology can safely be spared transurethral bladder biopsy but recommended biopsy after BCG treatment for patients with CIS because suspicious cytology and abnormal cystoscopic findings were common.

Our results also demonstrated that 98% of biopsies might be spared in patients with erythematous mucosa or negative findings on cystoscopy, combined with negative cytology. Only 1 patient demonstrated positive bladder biopsy results (G2 and Ta) with negative cystoscopic findings and negative urinary cytology. This histological result was not high grade or high stage including G3/CIS, which is why urinary cytology and cystoscopy might have been normal. Such superficial low-grade, very early-phase recurrent cancer would be detected several months later by follow-up cystoscopy.

In summary, routine transurethral biopsy of the bladder for evaluating the response to BCG intravesical therapy is not necessary in patients who have no visible tumor on cystoscopy and negative urinary cytology.

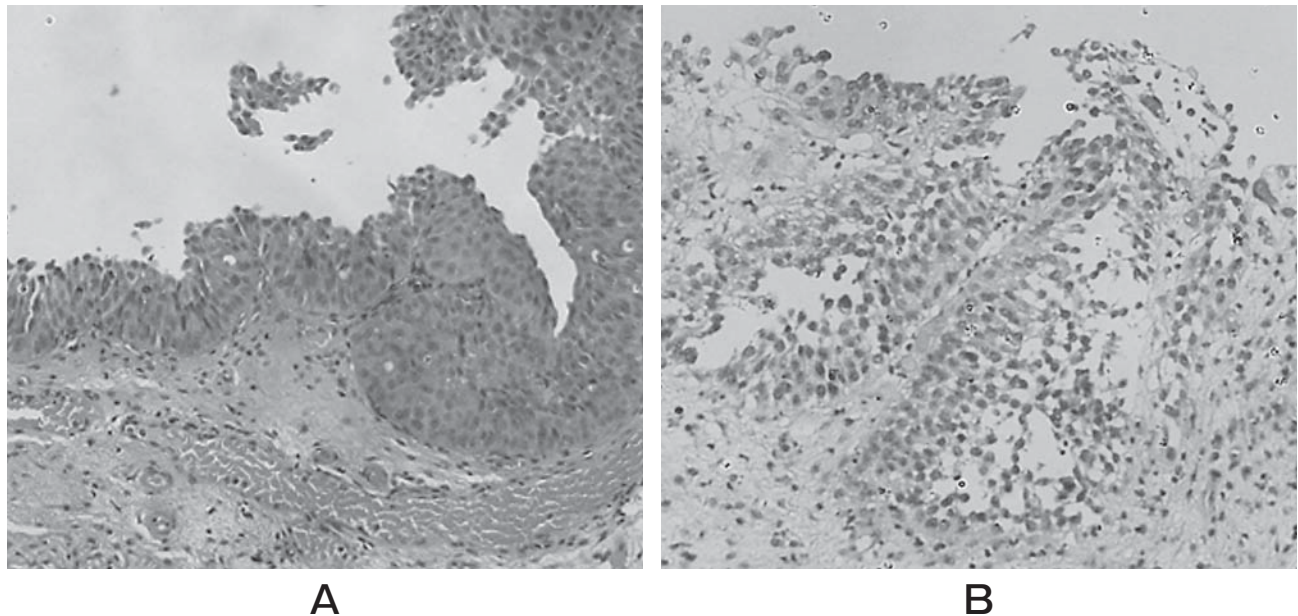


Fig. 1 Pathological findings of a patient with negative cytology and cystoscopy: A, Before BCG: urothelial carcinoma, G3, Tis.; B, After BCG: urothelial carcinoma, G2, Ta.

References

1. Herr HW: Tumour progression and survival in patients with T1G3 bladder tumours: 15-year outcome. *Br J Urol* (1997) 80: 762-765.
2. Saika T, Tsushima T, Nasu Y, Arata R, Kaku H, Kusaka N and Kumon H: Clinical study of G3 superficial bladder cancer without concomitant CIS treated with conservative therapy. *Jpn J Clin Oncol* (2002) 32: 461-465.
3. Morales A, Eidingen D and Bruce AW: Intracavitary bacillus Calmette-Guerin in the treatment of superficial bladder tumors. *J Urol* (1976) 116: 180-183.
4. Lamm DL, Blumenstein BA, Crawford ED, Montie JE, Scardino P, Grossman HB, Stanisc TH, Smith JA Jr, Sullivan J, Sarosdy MF, Crissmann J and Coltman CA: randomized trial of intravesical doxorubicin and immunotherapy with Bacille Calmette Guerin for transitional cell carcinoma of the bladder. *New Engl J Med* (1991) 325: 1205-1209.
5. Highshaw RA, Tanaka ST, Evans CP and deVere White RW: Is bladder biopsy necessary at three or six months post BCG therapy? *Urol Oncol* (2003) 21: 207-209.
6. Zein TA and Milad MF: Urine cytology in bladder tumors. *Int Surg* (1991) 76: 52-54.
7. Dalbagni G, Rechtschaffen T and Herr HW: Transurethral biopsy of the bladder necessary after 3 month to evaluate response to bacillus calmette-guerin therapy? *J Urol* (1999) 162: 708-709.
8. Skemp NM and Fernandes ET: Routine bladder biopsy after bacilli calmette-guerin treatment: Is it necessary? *Urology* (2002) 59: 224-226.