

Acta Medica Okayama

Volume 23, Issue 1

1969

Article 5

FEBRUARY 1969

Establishment of new ascites hepatomas

Katsuhiko Kimoto*

*Okayama University,

Copyright ©1999 OKAYAMA UNIVERSITY MEDICAL SCHOOL. All rights reserved.

Establishment of new ascites hepatomas*

Katsuhiko Kimoto

Abstract

The hepatomas of the Donryu rats induced by feeding 4-dimethyl. aminoazobenzene for more than 191 days were transplanted into the brain of newborn rats of the same strain and the formed tumors were transplanted into the peritoneal cavity of adult rat of the same strain for the purpose to obtain transplantable strain of ascites hepatoma. As the result 4 lines of transplantable ascites hepatomas have been established. The cells of these 4 hepatomas resembled their original liver tumor cells, respectively, showing the similar morphologic appearance to their mother cell. They showed less differentiated or more malignant characteristics in those taken from the tumor at the more advanced stages of DAB feeding. The liver tissues from the rat fed on DAB for 191 days had no tumor inducing activity when they were inoculated into the brains of the newborn rats (C 74). The liver tumors of the rats fed for more than 236 days produced the tumors in brain, which was serially transplantable (C 82), and kept the original morphologic pattern through serial transplantation and even in those growing in ascites. The tumor cells of the C 82 line showed the least malignancy among the 4 lines of ascites hepatoma established. Those of the C 83 line, which originated from the rat fed on DAB for 264 days, demonstrated the type of well-differentiated liver cell carcinoma with the trabecular arrangement of the tumor cells, but in ascites form they grew more rapidly than those of C 82. Those having most malignant characteristics were the cells of C 84.A which were derived from the rat fed on DAB for 312 days, and they were of the type of undifferentiated liver cell carcinoma. The island forming capacity of the C 84-A cells was the weakest among those of the 4 lines. C 84-B cells were also those derived from the same rat as that from which C 84.A originated and also showed the type of poorly differentiated liver cell carcinoma, but less malignant than those of C 84.A.

*PMID: 4309665 [PubMed - indexed for MEDLINE] Copyright ©OKAYAMA UNIVERSITY
MEDICAL SCHOOL

Acta Med. Okayama 23, 27-46 (1969)

ESTABLISHMENT OF NEW ASCITES HEPATOMAS

Katsuhiko KIMOTO

*Division of Pathology, Cancer Institute of Okayama University Medical
School, Okayama, Japan (Director: Prof. J. Sato)*

Received for publication, December 18, 1968

Transplantable rat ascites hepatomas are important tools for the study of cancer. In Japan we have many papers reporting the conversion of the tumor cells of solid type into ascitic one (1). YOSHIDA and his coworkers were the first to establish the transplantable ascites hepatomas with the tumor cells induced in rats by feeding azo dyes and, in their further studies, more than 50 strains of rat ascites hepatomas of different biological characteristics have been established (2, 3).

In connection with the chemical transformation of liver cells, we have reported in the previous paper that in the primary culture of the liver tissues of the rats fed on the azo dye for the periods from 44 to 312 days, liver cells of different types from apparently normal to typical cancer cells have proliferated depending upon the DAB-feeding duration (4).

In the present experiment, the hepatomas of the rats induced by feeding DAB* for more than 191 days were transplanted into the brains of newborn rats of the same strain and the tumors formed in the brains were then inoculated into the peritoneal cavity of adult rats of the same strain for the purpose to convert the cells into ascites hepatoma. As the result 4 lines of transplantable ascites hepatoma were obtained. In this paper the transplantability and biological characteristics of these 4 lines of hepatoma are reported and the relation between the DAB feeding duration and the convertibility of the tumor cells of solid type into ascites one are discussed.

MATERIALS AND METHODS

Animals: Newborn and adult rats of the Donryu line were used in this experiment. They were kept in cages and provided with water and pellet diet (Oriental Co.) *ad libitum*.

Tumors: Original hepatomas were induced in rats by feeding a carcinogenic pellet diet containing 0.06 per cent of 4-dimethylaminoazobenzene, supplied from the Central Laboratory for Experimental Animals (Tokyo). The tumor-bearing animals induced with azo dye were sacrificed at different intervals by bleeding. Four rats produced tumor nodules in the livers, out of the

* 4-dimethylaminoazobenzene

16 rats fed on the dye for 44 to 312 days and the tumorous tissues from these four rats were employed as the transplants. Each tumor from 4 rats was designated as C 74, C 82, C 83, C 84-A and C 84-B. The C 84-A and the 84-B were derived from the liver of the same rat. The former was removed from other than nodular portion of the liver and the latter from the nodular lesion of the same liver. The details of these 4 rats, sex, age, duration of DAB feeding, the total amount of DAB and their histology are illustrated in Table 1.

Table 1. History of original tumor-bearing rats

Experimental number	C 74	C 82	C 83	C 84
Sex	male	female	female	female
Age (days)	247	330	358	406
Duration of DAB-feeding (days)	191	236	264	312
Total amount of DAB (gm)	1.80	1.96	2.42	2.38
Histology of transplant*	H.	H. C.	H.	H.

* H.: hepatoma

C.: cholangioma

Transplantation methods: The tumor nodules were removed from the livers, minced with scissors using sterile technique and the minced tissues were suspended in a small amount of Hanks' solution containing 100 unit per ml of penicillin G. The minced tumor gruel was filtered through the platinum mesh ($\# 150$). A dose of 0.03 ml of the cell suspension containing approximately 5×10^4 cells was injected with a hypodermic needle and syringe into newborn rats, intraperitoneally, intracranially and subcutaneously. The adult rats were injected with 0.5 ml of the suspension in the same manner.

Observation of tumors: The solid tumors were fixed in 10 per cent formalin. Specimens were prepared in the usual way and stained with the hematoxylin and eosin for microscopic examination. At various intervals the tumor cells were investigated in the accumulated ascites of the rats transplanted intraperitoneally with cancer cells. Preparation of the ascites tumors was stained with 30 per cent aceto-gentianviolet solution. When the cancer cells were detected in the ascites, they were retransplanted to other normal rats. In order to observe the structure of the tumor 'islands', the tumor 'islands' gathered by centrifugation were fixed in Carnoy's solution, embedded in paraffin, sectioned and stained with hematoxylin eosin.

Chromosome observation: After the conversion to ascites form, the chromosome numbers of the cancer cells were examined in 4 or 5 days after the animal transplantation. Each tumor-bearing animal was injected with 100 μ g colchicine 90 minutes before the preparation. The cells were treated with water for 10 to 20 minutes, stained with acetic acid solution containing 0.75 per cent Dalia violet and squashed under cover slips.

Preservation of the ascites tumor: After the conversion to ascites form, these ascites hepatomas were preserved by freezing with dimethylsulphoxide at cer-

tain intervals. Tumor cells were suspended in the medium supplemented with 10 per cent dimethylsulphoxide. The medium for the liver culture consisted of 20 per cent bovine serum, 0.4 per cent lactalbumin hydrolysate and saline D (5, 6). The tumor cell suspension was sealed in ampoules and placed in dry-ice chest at $-75^{\circ}\text{C} \sim -80^{\circ}\text{C}$ for storage. For the recovery of the frozen cells, these ampoules were thawed rapidly by shaking in 37°C water bath and the suspension were reinoculated into the abdominal cavity of normal rats.

RESULTS

1. *Primary transplantation*

The brains or the subcutans of newborn rats were employed as transplantation sites in the primary transfer. The incidence of tumor growth in the primary transplantation is shown in Table 2.

In the intracranial transplantation, the transplants from a rat fed DAB for 191 days (C 74) produced no tumor at all in 3 months after transplantation, but tumors developed by the transplantation of liver tissues from other rats fed on DAB for 236 days (C 82), 264 days (C 83) and 312 days (C 84-A and C 84-B), respectively. In the present study, the rat bearing tumor in brains were sacrificed under agonal condition and the tumor foci were sought for in their brains. The nodule formation outside of the skull was noticed in some cases. In the cranium, most of tumor growths were detected in the cerebral ventricles as hemorrhagic lesions with hydrocephalus of various grades. The rats bearing C 82 tumors in brains survived 13 to 38 days after the transplantation. The rats developing the C 83 tumor in brains were killed at 38 to 40 days after the tumor inoculation. It took 23 to 24 days in C 84-A and 32 to 42 days in C 84-B, respectively, for the tumors in the brain to bring the rats to the agonal condition.

In the subcutaneous transplantation, the growth pattern differed somewhat among individual tumors. In one of the 3 other lines, C 83, no nodule of tumor was found 3 months after the transplantation. In the C 82, subcutaneous tumors were noticed initially in all the 3 rats about 30 days after the inoculation, but one of the tumors regressed spontaneously thereafter. And another was used in the succeeding transplantation on 52nd day after the transplantation. The remaining one grew gradually large and brought the animal to moribund condition 115 days after the inoculation. The subcutaneous tumors of the C 82 were grossly firm, slightly pinkish, encapsulated and contained fragil foci of necrosis, with no sign of invasion to the adjacent tissues. In the C 84-B, tumor growth was found in 2 out of the 3 rats 40 days after transplantation. The rats

under the agonal condition were killed 60 days after the injection. The tumors were developed earlier than those of the C 82. The tumors were cystic and this was evident by external palpation. These tumors contained dark-reddish fluid in most areas and red-brown or yellow-gray, irregular masses were observed in other parts.

Table 2. Transplantability of the original tumors induced by DAB

Experimental number	Inoculation site*	Transplatability	Survival (days)
C 74	i. c.	0/2	nt **
	"		nt
C 82	i. c.	3/3	13
	"		21
	"		38
	s. c.	2/3	52
	"		115
"	nt		
C 83	i. c.	3/3	38
	"		40
	"		40
	i. p.	3/3	58
	"		59
	"		63
	s. c.	0/3	nt
	"		nt
"	nt		
C 84-A	i. c.	3/3	23
	"		23
	"		24
C 84-B	i. c.	2/2	32
	"		42
	s. c.	2/3	60
	"		60
	"		nt

* i. c. : intracranial i. p. : intraperitoneal s. c. : subcutaneous

** nt. : no tumor growth.

2. Serial transplantations

Serial transplantations were started by using the brain as the transplantation site, and the transplantability to the adult rats of the tumors

produced in brains of newborn rats was confirmed at each transfer generation.

a) *Transplantation of tumors produced in brains*: The minced gruel from the tumors in brains of each line was inoculated intracranially, intraperitoneally and subcutaneously into newborn and adult rats. From the first to the 3rd or 4th transplant generation, the results of the transplantation of tumors in brains are described in Tables 3, 4, 5, and 6. The transplantation history until the ascites conversion of each line is shown in Figs. 1, 2, and 3.

Most tumors in brains were transplanted successfully by the intracranial or intraperitoneal route into newborn rats, but the transplantability of tumors was low in the case of subcutaneous route. The present data of the transplantation showed that the tumors of all hepatoma lines in brains were sufficient to transplant into adult rats as well as into newborn rats.

Table 3. Transplantability of C 82 tumor cells produced in brains

Transplant generation	Age*	Inoculation site**	Survival (days)
2nd	n. b.	i. c.	15
	"	"	18
	"	"	18
	"	"	18
	"	"	21
	25-d.	i. p.	55
	60-d.	"	nt***
3rd	"	"	nt
	n. b.	i. c.	14
	"	"	14
	"	"	16
	n. b.	s. c.	38
	"	"	38
4th	"	"	45
	30-d.	s. c.	32
	n. b.	i. c.	17
	"	"	17
	n. b.	s. c.	34
"	"	38	
"	"	42	

* n. b.: newborn rat

d. : days-old rat

** i. c. : intracranially

i. p. : intraperitoneally

s. c. : subcutaneously

*** nt : no tumor growth

Table 4. Transplantability of C 83 tumor cells produced in brains

Transplant generation	Age*	Inoculation site**	Survival (days)
2nd	n. b.	i. c.	23
	"	"	40
	"	"	41
	n. b.	s. c.	197
	"	"	nt***
3rd	40-d.	"	119
	n. b.	i. c.	28
	"	"	35
	n. b.	i. p.	82
	"	"	nt
4th	31-d.	i. p.	71
	"	"	103
	22-d.	i. p.	59
	"	s. c.	nt

* n. b. : newborn rat d. : day-old rat
 ** i. c. : intracranial i. p. : intraperitoneal s. c. : subcutaneous
 *** nt : no tumor growth

Table 5. Transplantability of C 84-A tumor cells produced in brains

Transplant generation	Age*	Inoculation site**	Survival (days)
2nd	n. b.	i. c.	15
	"	"	16
	"	"	13
	"	"	15
	"	"	21
	n. b.	i. p.	13
	"	"	14
	4-d.	i. p.	13
	"	"	17
	n. b.	s. c.	30
3rd	37-d.	i. p.	9
	88-d.	"	11

* n. b. : newborn rat d. : day-old rat
 ** i. c. : intracranial i. p. : intraperitoneal s. c. : subcutaneous

b) *Transplantation of the subcutaneous tumors* : The subcutaneous transplantation of the original liver tumors was carried out in three of five lines, that is, C 82, C 83 and C 84-B. The original liver tissues from the

Table 6. Transplantability of C 84-B tumor cells produced in brains

Transplant generation	Age*	Inoculation site**	Survival (days)
2nd	n. b.	i. c.	20
	"	"	22
	"	"	24
	n. b.	i. p.	16
	"	"	17
	"	"	22
3rd	n. b.	i. c.	14
	"	"	14
	"	"	14
	n. b.	i. p.	20
	"	"	21
	"	"	21
	n. b.	s. c.	nt***
"	"	nt	
"	"	nt	
4th	25-d.	i. p.	15
	"	"	nt
	"	"	nt

* n. b. : newborn rat d. : day-old rat
 ** i. c. : intracranial i. p. : intraperitoneal s. c. : subcutaneous
 *** nt : no tumor growth

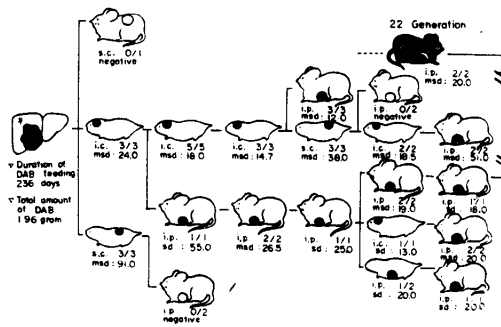


Fig. 1. Transplantation history of ascites conversion of C 82 line

i. c. : intracranial msd : mean servival time in day
 i. p. : intraperitoneal ascites transplantation
 s. c. : subcutaneous — solid tumor transplantation
 sd : survival time in day striped animal : ascites hepatoma developed

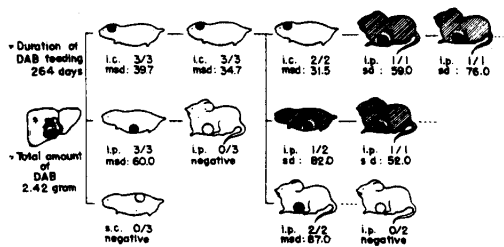


Fig. 2. Transplantation history of ascites conversion of C 83 line
 i. c. : intracranial msd : mean survival time in day
 i. p. : intraperitoneal ascites transplantation
 s. c. : subcutaneous — solid tumor transplantation
 sd : survival time in day striped animal : ascites hepatoma developed

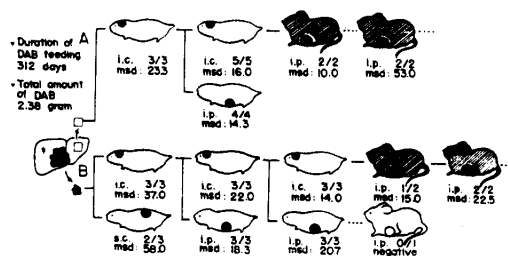


Fig. 3. Transplantation history of ascites conversion of C 84 line
 i. c. : intracranial A : transplants from nonodural tissue
 i. p. : intraperitoneal B : transplants from nodural tissue
 s. c. : subcutaneous ascites transplantation
 sd : survival time in day — solid tumor transplantation
 msd : mean survival time in day striped animal : ascites hepatoma developed

C 82 and C 84-B lines produced tumors in the subcutan, but those from the C 83 line no tumor. The subcutaneous tumors of two lines were transferred into the peritoneal cavity or the subcutan of adult rats. In the C 82, the tumor was not found two months after the transplantation. But in the C 84-B, the tumor nodule developed in the subcutan seven days after the transplantation but the tumor could not be transplanted serially.

3. Establishment of ascites hepatoma

When the minced hepatoma tissues from transplanted animals were inoculated at various transfer generations into the abdominal cavity, ascites accumulated amounting to 20 to 40 ml. During the periods previous to the conversion of the solid tumor to the ascites hepatoma, a little of ascites was centrifuged and the sediment was examined microscopically. Along with these techniques, the sediment was injected into the peritoneal cavity of the normal rat to investigate whether or not tumor cells were contained

in it. By these procedures, all four of solid tumor lines were converted into ascites tumor, as summarized in Figs. 1, 2 and 3.

In the C 82, it took the longest time in all the strains, 360 days, for the solid tumor to be changed into the ascites form. No ascites conversion occurred by transfers of tumors produced in brains until the sixth transplant generation, but the tumor-cell islands happened to exfoliate into ascitic fluid at the twenty-second generation with the intraperitoneal inoculation of transplanted tumors.

The tumors of the C 83 line became the ascites hepatoma by the intraperitoneal inoculation with the tumor produced in the brain after the third transplant generation on 162nd day.

The ascites conversion of the C 84-A hepatoma line took place in the third transplant generation on day 46. The ascites conversion of this line was the earliest of all the lines. Ascites hepatoma of the C 84-B was produced with the tumor in brains in the fourth transplant generation. The ascites hepatoma was detected 86 days after the primary transplantation. These four solid tumors changed into ascites form. Three of the four lines of ascites hepatomas were produced by the transplantation of the tumors in the brain into the peritoneal cavities and another line (C 82) obtained through intraperitoneal passages of tumor tissues.

4. *Characteristics of the four lines of ascites hepatomas*

The four lines of ascites hepatomas have been maintained by transplantation to animals. The intraperitoneal transplantation was performed with about 10^7 to 2×10^7 tumor cells once every five to ten days. After 10 to 20 transplant generations, they were stored by freezing to be used for experiment. Some characteristics observed during these serial transplantations were as follows:

a) *Transplantability*: All the animals used for the present study were 14- to 70-day old rats of Donryu line. The data of transplantability and survival time are summarized in Table 7. The transplantability was 92 to 98 per cent in all lines. In comparing the average rate of transplantability from the first to the tenth transfer generations with the average of later transfer generations, no apparent changes were observed except in the C 83 line which showed slightly decreased transplantability by serial animal passages. No definite correlation was recognized between the transplantability and the duration of DAB feeding.

b) *Survival*: Mean survival time in days was obtained by averaging the survival days of every five transplant generations of each line. All lines had a tendency to decrease the survival time on the average and the survival time of the recent ten transplant generations of all lines were

Table 7. Biological data of 4 lines of ascites hepatomas

Line	C 82	C 83	C 84-A	C 84-B
Conversion to ascites				
transfer generation	22nd	3rd	3rd	4th
total days required	360	162	46	86
Transplantability (%)	97.7	92.4	96.7	97.7
Survival time in average (days)	16.5	13.6	8.9	9.9
Number of cells composing islet				
single	2.0	10.8	69.0	63.3
twin	1.5	4.0	19.4	7.3
triple	0.5	0.8	6.0	0
4 cells	0	0.4	3.6	0
5—10 cells	1.5	4.0	1.6	3.7
over 11 cells	94.5	80.0	0.4	25.7
Modal chromosome number	76	56	44	43

constant. The rats inoculated with C 82 cells were alive for 15 to 17 days and the rats with C 83 cells for 12 to 14 days, the rats with C 84-A for 6 to 8 days and the rats with C 84-B for 7 to 9 days. This fact provides the evidence that the shorter the duration of the DAB feeding the longer is the survival time of the rats.

c) *Gross finding of tumor-bearing rats* : The autopsy was performed in most tumor-bearing animals. The infiltration and the metastasis of tumor cells appeared to be related to the survival time of the animals. The cell infiltration increased with the prolongation of life-span of tumor-bearing rats. By observing the intraperitoneal nodule formation, however, each line could be distinguished from one another.

The rats inoculated with the line C 82 cells were found to have accumulated 40 ml hemorrhagic ascites at the autopsy. A number of small, soft and dark reddish tumor nodules were observed on the peritoneal tissues and many nodules resembling tufts of grapes were found on the omentum. Infiltrating nodules were observable on the lesser omentum, the mesenterium, the genitourinary tissues and the diaphragm. No metastasis into the lung was revealed macroscopically. The rats inoculated with the line C 83 ascites hepatoma also developed hemorrhagic ascites to the volume of 30—40 ml. The volume of ascites fluid was rather less on the average than that of the rats injected with C 82 tumor cells. The autopsy demonstrated a moderate number of large gray and elastic tumor nodules, especially in the hypogastric and the intestinal regions, often

accompanied by the tumorous adhesion to the intestine. The tumor development in the rat with C 84-A cells was most rapid among the 4 lines. The volume of ascites was about 15 ml and detectable tumor nodules were hardly observed. Miliary gray nodules were found in the hypogastric-pancreatic region and on the mesenteric membrane. Few tumor nodules were on the thickened omentum. The rats transplanted with tumor cells of the C-84-B line had the short life-span and the ascites volume was about 18 ml. The autopsy findings were similar to those of the rats with C 84-A cells, but gray and soft tumor nodules were scarcely detected on the omentum.

d) *Morphology of original and transplantable tumors*: The original tumor of the C 82 line showed transitional type of the liver tumor (18). This type has been maintained during serial animal transplantation. The glands of irregular shape were observed with sparse connective tissue and were composed of cuboidal cells which had a little amount of eosinophilic cytoplasm containing round or oval clear nuclei (Photo. 1). The original and transplantable tumors of the C 83 line demonstrated well differentiated hepatoma, showing trabecular arrangement as generally observed in the liver. The large round and clear nuclei contained prominent nucleoli (Photo. 3). After the ascitic conversion occurred, tumors formed by subcutaneous transplantation of the C 83 ascites tumor demonstrated poorly or undifferentiated hepatoma. The tumors of the C 84-A line consisted of undifferentiated liver cell carcinoma. The tumor cells were loosely arranged and showed loose trabecular pattern with poor stroma. The original tumor consisted of small cells with oval or round basophilic nuclei (Photo. 5). The tumors of the C 84-B line were poorly differentiated hepatoma. The cell nestle and the dense trabecular arrangement were observed in the tumor composed of rather large cuboidal cells with eosinophilic cytoplasm. The degree of the dedifferentiated state was less than that of C 84-A from the histological view point (Photo. 7).

e) *Ascites picture*: The tumor cell population of these four lines in the ascites showed different patterns from one another, but the characteristics of the islands and free tumor cells were maintained in four lines during the serial transplantation. It was easy to distinguish these lines from one another by their pictures.

Hepatoma islands of the line C 82 were very large and of cudge-like shapes and most of them were visible with naked eyes, about 5 mm in length. Neither the islands composed of tumor cells less than ten cells nor the isolated cells were observed. The border of each island was generally smooth and the adhesion of each cell in the island was rather loose. The

cells forming each island showed the characteristics of transitional type of liver cell carcinoma by the sectioned specimens. The cells on the periphery of the island showed the gland-like arrangement. This pattern resembled that of the original tumor (Photo. 2).

The ascites picture of the line C 83 demonstrated both a number of free cells and islands composed of ten to fifty tumor cells. The border of most islands was uneven and appeared cluster-like. There were sometimes ring-like islands of which the center was empty and each cell was firmly adhered. The arrangement of the cells showed incomplete glands, suggesting poorly differentiated hepatocarcinoma (Photo. 4).

Though the lines C 84-A and C 84-B being derived from the liver of the same rat, each ascites picture differed remarkably. In that of the C 84-A line, the percentage of free cells was more than 69 per cent and a few islands were composed of more than ten cells. Islets formed of two cells, that is "twin", were prominent. These tumor cells were rather small and uniform in size (Photo. 6).

The ascites picture of the line C 84-B was made up of about sixty per cent of free cells and a number of cell islands. The numbers of the islands composed of more than ten cells reached about twenty-five per cent of all clusters. These oval or round islands were larger than those of the C 83. The border of the islands was even, and it was sometimes covered by flat, endothelial cells, differing markedly from the islands of the C 82 and C 83. The cells composing islands of C 84-B adhered to one another not uniformly and no trabecular or gland-like arrangement was observed (Photo. 8).

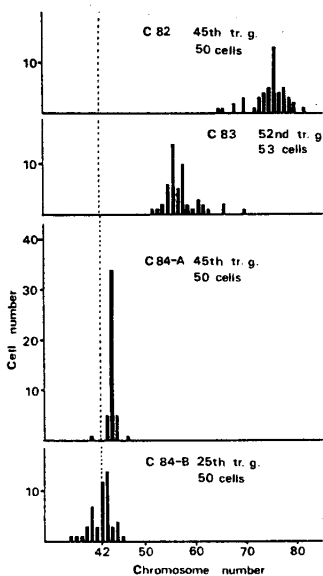


Fig. 4. Distribution of chromosome numbers in the ascites hepatomas C 82, C 83, C 84-A and C 84-B

f) *Chromosome number of the ascites hepatomas*: For comparative studies of these ascites hepatomas, fifty metaphases of the cells of each ascites hepatoma were counted, by preparing squash specimens of stained wet smears. The chromosome number distribution was analyzed during twenty-fourth to fifty-second transplant generations. As shown in Fig. 4, the modal number and the distribution of the chromosomes were markedly different. The modal chromosome number was 76 in the C 82, 56 in the C 83,

44 in the C 84-A and 43 in the C 84-B, respectively. The chromosomes of the C 84-A and C 84-B were distributed in the diploid range and the modal chromosome number of the line C 84-A was 44 and it reached about 75 per cent of all metaphases observed, but the chromosomes of the line C 82, C 83 and C 84-B were distributed very widely and the modal chromosome number of them was not so prominent as that of the line C 84-A.

DISCUSSION

Transplantable hepatomas induced in rats by feeding azo-dye have been reported by many investigators (1, 2, 3). Consequently, the morphological changes of the rat liver have been described as dependent upon the duration of azo-dye feeding. Generally, when the duration of DAB feeding is prolonged, the morphological differentiation of the rat liver tumor is lost and the transplantability is increased (8, 9). These transitional changes were demonstrated even by the methods of tissue culture (4).

The present work was started with intention to obtain the transplantable hepatomas in which the transitional changes of tumors are maintained, through the brains of newborn rats, and to accomplish ascites conversion by intraperitoneal inoculation of these tumor tissues.

The brains as "an immunologically privileged site" have been used for the inoculation site of tumor homotransplants, isotransplants and heterotransplants (10, 11, 12, 13). Therefore, by selecting the brain of newborn animals as the site of isotransplantation, it was intended to obtain tumors of such a nature that they can be readily transplanted and be less malignant, even when the tumor cells in the inocula are few. By this means, with growing intracerebral implants, the animals show marked clinical indications of the nervous system, and further, the brains are so soft from the tissue-structural aspects that the transplant tissues can be easily identified and obtained. In the present experiment, the transplantations were performed by way of the brain of newborn rats. Thereby tumors inoculated in brains became transplantable to the adult rats for a short period.

The transplantability serves as one of the criteria in determining the malignancy of liver cancers in rats. The C 74 liver tumor in this experiment could not be transplanted even by using the brains of newborn rats. However, after the tissue culture of these C 74 tumor cells for 159 days, tumor developed in the brains (4). The tumorigenicity of the C 74 cultured cells may depend upon its increase with the prolongation of the culture duration, the cell selection in culture conditions or the spontaneous trans-

formation of the cells in culture (22). These phenomena seem to indicate that the C 74 hepatoma is of such a nature that it lies in the borderline between the transplantable and untransplantable ones.

The relation between the duration of azo-dye feeding and the malignancy or transplantability of induced hepatomas has been reported (9). However, there are few reports about the correlation between the duration of azo-dye feeding and the conversion of solid form to ascites one. In the investigation of the correlation just mentioned, it has been demonstrated that, when the transplantation is performed under optimal conditions, the hepatomas induced by azo-dye might be converted into ascites form and the ease of the ascites conversion has depended upon the DAB-feeding duration. This indicates that the ascites conversion may be related to the malignancy of the original tumors. Even after the conversion to ascites form, the gradational changes of liver tumors of the 4 lines have continued. These hepatomas having malignancy of varying degrees may be used for the elucidation of the mechanisms of malignant changes of liver cells.

The reason why not all of tumors could be converted into the ascites form remains unsolved. It is related to fundamental problem of selection and adaptation of the degree of malignancy of the tumor cells. The results of KLEIN indicate that the ability of tumor to convert itself into as ascites form is due in part to a rapid growth rate and/or high degree of anaplasia and to the process of selection of cells possessing a predilection for growth in the ascites form (14, 15, 16, 17). YOSHIDA advocated that a transplantable hepatoma converting into the ascites form might be accounted for the gradation of malignancy. This fact suggests that the determination whether or not a tumor can be converted to the ascites form depends upon the inherited character of the tumor (19). The mechanism of the tumorous change of normal cells might differ from that of increasing tumor malignancy by serial animal passages. The conversion from solid tumors into ascites form seems to be related to enhancing the changes in malignancy of a tumor, but the precise mechanism of ascites conversion is not clarified as yet.

This investigation suggested probably that the ability of the invasion of each tumor determined the period to ascites conversion, as inferred from the fact that the invasive tumor cells happened to exfoliate and that the ascites tumor developed. Therefore, if the site, favourable for the invasion of tumor cells that is, the brain of a newborn animal is used as the route of transplantation, the invasiveness of tumor cells might be promoted and the ascites tumor might be established with ease (20, 21).

The histological observation indicated that the tumor cells with invasive character increased with transplant generation. This fact was observed especially in the tumor line, C 82, which maintained in transfer the solid form for a long period. As the result of ascites conversion, the solid tumors formed by the transfer were more malignant histologically than respective original hepatoma.

SUMMARY

The hepatomas of the Donryu rats induced by feeding 4-dimethyl-aminoazobenzene for more than 191 days were transplanted into the brain of newborn rats of the same strain and the formed tumors were transplanted into the peritoneal cavity of adult rat of the same strain for the purpose to obtain transplantable strain of ascites hepatoma. As the result 4 lines of transplantable ascites hepatomas have been established. The cells of these 4 hepatomas resembled their original liver tumor cells, respectively, showing the similar morphologic appearance to their mother cell. They showed less differentiated or more malignant characteristics in those taken from the tumor at the more advanced stages of DAB feeding.

The liver tissues from the rat fed on DAB for 191 days had no tumor inducing activity when they were inoculated into the brains of the newborn rats (C 74). The liver tumors of the rats fed for more than 236 days produced the tumors in brain, which was serially transplantable (C 82), and kept the original morphologic pattern through serial transplantation and even in those growing in ascites. The tumor cells of the C 82 line showed the least malignancy among the 4 lines of ascites hepatoma established. Those of the C 83 line, which originated from the rat fed on DAB for 264 days, demonstrated the type of well-differentiated liver cell carcinoma with the trabecular arrangement of the tumor cells, but in ascites form they grew more rapidly than those of C 82. Those having most malignant characteristics were the cells of C 84-A which were derived from the rat fed on DAB for 312 days, and they were of the type of undifferentiated liver cell carcinoma. The island forming capacity of the C 84-A cells was the weakest among those of the 4 lines. C 84-B cells were also those derived from the same rat as that from which C 84-A originated and also showed the type of poorly differentiated liver cell carcinoma, but less malignant than those of C 84-A.

ACKNOWLEDGEMENT

The author wishes to express sincere thanks to Prof. J. SATO and Dr. M. NAMBA for their helpful advices and discussions for this work. Grateful acknowledgement is also made to Prof. I. NISIDA for his constant interest and guidance in this investigation.

REFERENCES

1. YOSHIDA, T.: On the ascites hepatoma. Summary of the results of studies obtained during 10 years from 1951 to 1960. *Tokyo J. Med. Sci.*, **68**, 717, 1960 (in Japanese)
2. YOSHIDA, T., SATO, H. and ARUJI, T.: original of the Yoshida sarcoma I. Experimental production of "ascites hepatoma" in rat. *Proc. Jap. Acad. Tokyo*, **27**, 485, 1951
3. ODASHIMA, S.: Establishment of ascites hepatoma in the rat, 1951—1962. Cancer Inst. Monograph No. **16**, 51, 1964
4. SATO, J. and YABE, T.: Carcinogenesis in tissue culture. VI. Tissue culture of liver cells from DAB-feeding rats. *J. Exp. Med.*, **35**, 491, 1965
5. DOUGHERTY, R. M.: Use of dimethyl sulphoxide for preservation of tissue culture cells by freezing. *Nature*, **193**, 550, 1962
6. HAUSHKA, T. S., MITCHELL, J. T. and NEIDERPRUEN, D. J.: A reliable frozen tissue bank: Viability and stability storage at -78°C . *Cancer Res.*, **19**, 643, 1959
7. NOVIKOFF, A. B.: A transplantable rat liver tumor induced by 4-dimethylaminoazobenzene. *Cancer Res.*, **17**, 1010, 1957
8. ODASHIMA, S.: Development of liver cancer in the rat by 20-methylcholanthrene painting following initial 4-dimethylaminoazobenzene feeding. *GANN*, **50**, 321, 1959
9. ODASHIMA, S.: Comparative studies on the transplantability of liver cancer induced in rats fed with 3'-methyl-4-dimethylaminoazobenzene for 3—6 months. *GANN*, **53**, 325, 1962
10. GREEN, H. S. N.: Transplantation of tumors to brains of heterologous species. *Cancer Res.*, **11**, 529, 1951
11. SHEINBERG, L. C., EDELMAN, F. A. and LEVY, W. A.: Is the brain "an immunologically privileged site?" I. Studies based of intracerebral tumor homotransplantation and isotransplantation to sensitized hosts. *Arch. Neural.*, **11**, 248, 1964
12. KUROKI, T. and SATO, H.: Studies on heterotransplantation of tumor cell. IV. Subcutaneous and intracranial transplantation of YOSHIDA sarcoma cells in newborn mice. *Kosankin Kenkyu Zasshi*, **18**, 397, 1966 (in Japanese)
13. HARRIS, M.: Cell culture and somatic variation. Holt, Reinhardt and Winston, Inc., **51**, 1964
14. KLEIN, G.: Conversion of solid into ascites tumors. *Nature*, **171**, 398, 1953
15. KLEIN, E.: Gradual transformation of solid into ascites tumors. Permanent difference between the original and the transformed sublines. *Cancer Res.*, **14**, 482, 1954
16. KLEIN, E. and KLEIN, G.: Differential survival of solid tumor cells after inoculation into established ascites tumors. *Cancer Res.*, **14**, 139, 1954
17. KLEIN, G.: Some recent studies of the production and growth characteristics ascites tumors. *A Review. Z. Krebsforsch.*, **61**, 99, 1956
18. ODASHIMA, S.: Carcinogenicity and target organs of methoxyl derivatives of 4-aminoazobenzene in rats I. 3-methyl-and 3, 4'-dimethoxy-4-aminoazobenzene. *GANN*, **59**, 131, 1968
19. YOSHIDA, T.: Cytogenetical studies of ascites hepatomas. *Ann. Rep. Co-ope. Res. (Cancer) Minisi. Educ.*, **86**, 1966

20. SAIO, T.: Experimental studies on ascitic conversion of mammary cancer of C3H mice. Establishment of ascites tumor FM3A. *Fukushima Igaku Zasshi*, **12**, 335, 1962 (in Japanese)
21. FERNANDES, M. R. A. and KOPROWSKA, I.: The usefulness of tissue culture cell line in the development of ascites tumors from a transplantable squamous cell mouse carcinoma. *Cancer Res.*, **25**, 444, 1965
22. SATO, J., NAMBA, M., USUI, K. and NAGANO, D.: Carcinogenesis in tissue culture. VIII. Spontaneous malignant transformation of rat liver cells in long-term culture. *Japan. J. Exp. Med.*, **38**, 105, 1968

Explanation of plates

- Photo. 1. Transitional type of liver tumor. The glands of irregular shape are observed with sparse connective tissue. From a rat given DAB for 236 days (C 82).
- Photo. 2. The cells forming each island show similar arrangement to the original tumor. The cells on the periphery of the island show the gland-like arrangement by sectioned specimen of ascites hepatoma islands (C 82).
- Photo. 3. Well-differentiated hepatoma. The tumor shows trabecular arrangement as generally observed in the liver. The large round and clear nuclei contained prominent nucleoli. From a rat given DAB for 264 days (C 83).
- Photo. 4. The cells show incomplete glands, suggesting differentiated hepatocarcinoma. The border of islands is uneven and appears cluster-like and there are sometimes ring-like islands (C 83).
- Photo. 5. Undifferentiated liver cell carcinoma. The tumor consisted of small cells with oval or round basophilic nuclei and show loose trabecular pattern with poor stroma. From a rat given DAB for 312 days (C 84-A).
- Photo. 6. Few small islands and twin of tumor cells are observed. Many free tumor cells are seen (C 84-A).
- Photo. 7. Poorly differentiated hepatocarcinoma. The cell nestle and the dense trabecular arrangement are observed in the tumor composed of rather large cuboidal cells with eosinophilic cytoplasm. From a rat given DAB for 312 days (C 84-B).
- Photo. 8. The cell in islands adhered to one another not uniformly and no trabecular or gland-like arrangement was observed by sectioned specimen of tumor islands (C 84-B).

