

Acta Medica Okayama

Volume 20, Issue 4

1966

Article 1

AUGUST 1966

Effect of injection of adenovirus type 12 in adult hamsters

Yoshiro Yabe*

Katsuo Ogawa†

Katsumi Iwata‡

Sakae Murakami**

*Okayama University,

†Okayama University,

‡Okayama University,

**Okayama University,

Effect of injection of adenovirus type 12 in adult hamsters*

Yoshiro Yabe, Katsuo Ogawa, Katsumi Iwata, and Sakae Murakami

Abstract

Large doses of adenovirus type 12 were injected intraperitoneally into adult hamsters, and development of tumors and other pathological findings were studied in comparison with those in hamsters injected when newborn. Doses of 38~47 TCID₆₀ per gram body weight produced tumors in 3 of 12 hamsters injected at 37~57 days of age. A dose of 170 TCID₆₀ per gram body weight produced tumors in one of 18 hamsters injected at 61~71 days of age, but in none of 18 hamsters injected at 147~174 days of age, while the same dose per gram body weight produced tumors in 24 of 26 hamsters injected when newborn. In hamsters injected at adult ages, the number of tumors per animal decreased and the latent period for tumor development became very long as compared with those in hamsters injected when newborn. Regardless of the age at the time of injection, acute inflammatory change was observed in the peritoneum which later developed into various degrees of peritoneal adhesion. Adenovirus type 3 also induced the peritoneal adhesion. Histology of tumors was studied and discussed.

*PMID: 4226975 [PubMed - indexed for MEDLINE] Copyright ©OKAYAMA UNIVERSITY
MEDICAL SCHOOL

Acta Med. Okayama 20, 147—154 (1966)

EFFECT OF INJECTION OF ADENOVIRUS TYPE 12 IN ADULT HAMSTERS*

Yoshiro YABE**, Katsuo OGAWA***, Katsumi IWATA*** and
Sakae MURAKAMI****

*Institute for Cancer Research***, *Second Department of Pathology****
*and Department of Microbiology*****, *Okayama University Medical*
School, Okayama, Japan

Received for publication, May 19, 1966

The age of animals is a very important consideration in tumor virus experiments. Human adenovirus type 12 induced tumors in hamsters when injected at birth or at very young ages, but did not when injected at adult ages^{1,2}. In these experiments, tumors mostly developed at the site of injection suggesting that the local concentration of virus might be one of the important factors for tumor induction³. In the present experiment, large doses of adenovirus type 12 were injected into adult hamsters and the development of tumors and of other pathological changes has been studied.

MATERIALS AND METHODS

Virus: Adenovirus type 12, strain "Huie" was obtained from the American Type Culture Collection and adenovirus type 3, strain "G. B." was obtained from the Institute for Infectious Diseases, Tokyo University. Virus was cultured in HeLa cells. The virus culture fluid was frozen and thawed 3 times, centrifuged at 1,000 rpm for 5 minutes, and its supernatant was used for experiment.

Virus titration: Virus fluid was diluted in tenfold series with Earle solution containing 0.5% lactalbumin hydrolyzate and 0.1% yeast extract (YLE). One-tenth milliliter of each virus dilution was inoculated into HeLa cell tubes (4 tubes for each dilution) containing 1 ml of YLE as the maintenance medium. These tubes were incubated at 36.5°C and observed for cytopathogenic effect for 5 days. The 50% tissue culture infectious dose per 0.1 ml (TCID₅₀/0.1 ml) was calculated by REED and MUENCH's method⁴.

Animal: The breeding colony was established in our laboratory with Syrian hamsters from the Medical Section of Fukuyama Detachment of Japan

*This work was supported by a grant CA-06813 from the National Cancer Institute, U.S. Public Health Service, and by grants from the Ministry of Education of Japan.

Self Defense Forces and from Fujii Farm, Kobe. Only the hamsters bred in this colony were used in the present experiment. Virus was injected intraperitoneally.

Preparation of tissue sections: Tissues were fixed in formalin, and sections were stained with hematoxylin-eosin and silver impregnation.

RESULTS

Development of tumors and peritoneal adhesion: As shown in Table 1, doses of 38~47 TCID₅₀ per gram body weight produced tumors in 2 of 6

Table 1 Development of Tumors and Peritoneal Adhesion in Hamsters Intraperitoneally Injected with Adenovirus Type 12 at Various Ages

Virus	Age at injection (days)	Average body weight at injection (grams)	Virus titer (TCID ₅₀ /0.1 ml)	Virus dose injected			No. of injected hamsters ^a	No. of hamsters developing tumors	No. of hamsters with peritoneal adhesion
				ml	TCID	TCID/gram body weight			
Type 12	1-2	2.8	103.5	0.015	480	171	26	24(31-107) ^b	26
"	37	68	"	0.1	3200	47	6	2(100,264)	0
"	51-57	85	"	0.1	3200	38	6	1(393)	0
"	61-71	94	"	0.5	16000	170	18	1(112)	6
"	147-174	132	"	0.7	22400	170	18	0	15
Type 3	222-238	116	"	0.7	22400	193	10	0	10 ^c
Control fluid	1-2	2.8		0.015			13	0	0
"	61-71	94		0.5			14	0	0
"	222-238	116		0.7			10	0	0

a: Number of injected hamsters surviving over 21 days after injection, b: Days from injection to death or sacrifice from tumors, given in parentheses, c: The peritoneal adhesion in hamsters injected with type 3 was more marked than in those injected with type 12.

All animals were observed for 23-563 days from injection to death or sacrifice.

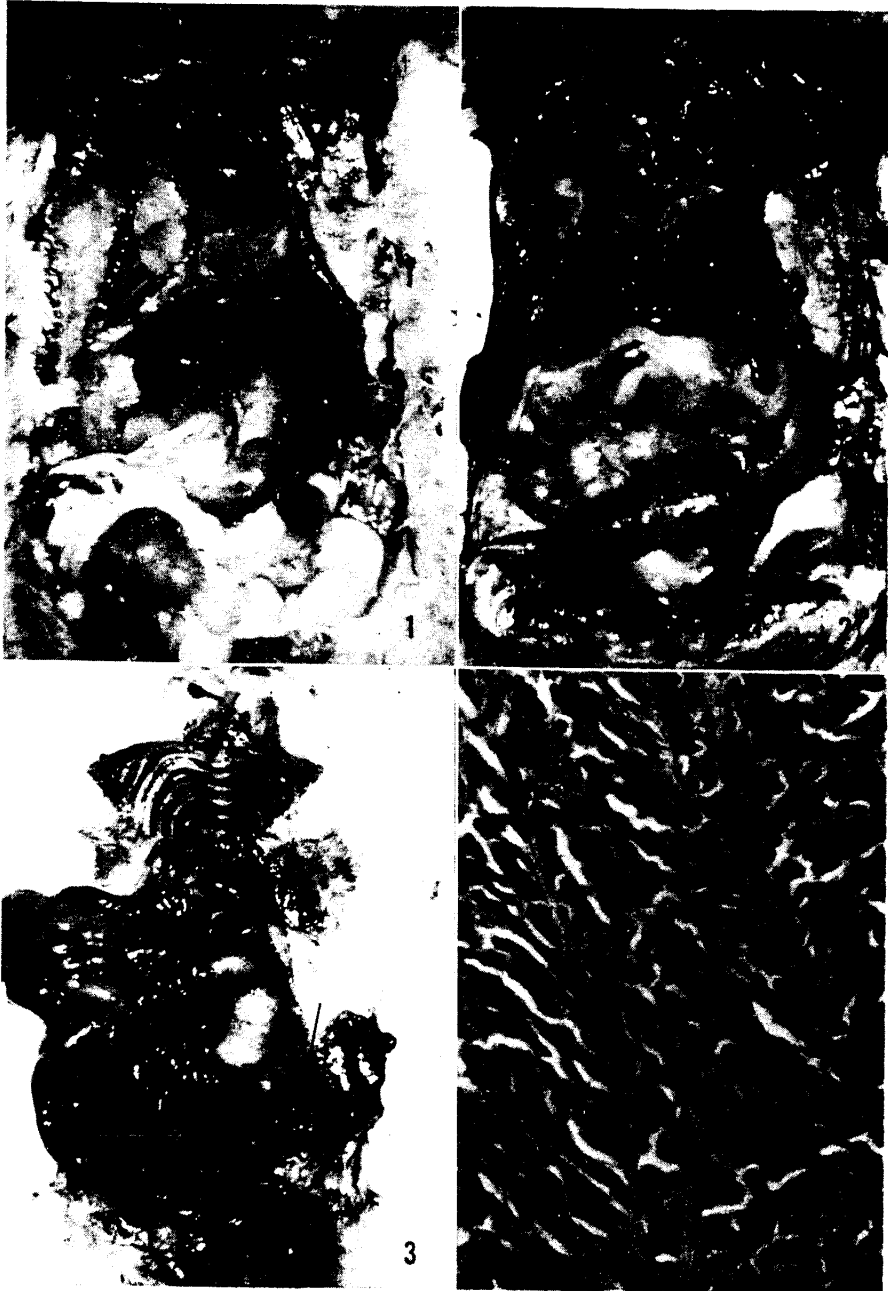
hamsters injected at 37 days of age, and in one of 6 injected at 51~57 days of

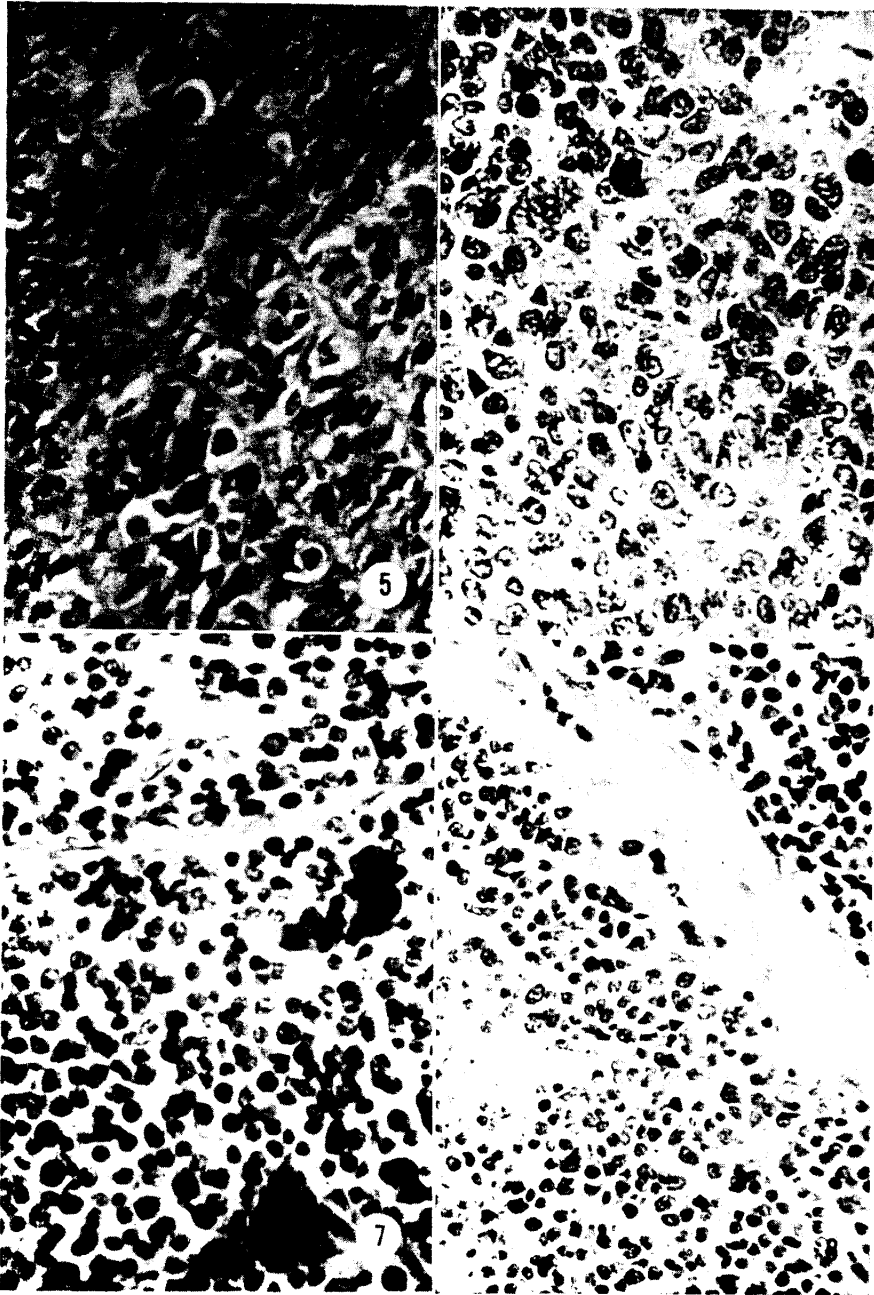
Fig. 1 One of hamsters intraperitoneally injected with adenovirus type 12 (170 TCID₅₀/gram body weight) at 147-174 days of age and killed without tumors 222 days after injection. Fibrinous adhesion is observed among liver lobes, gallbladder and diaphragm. $\times 1$

Fig. 2 One of hamsters intraperitoneally injected with adenovirus type 3 (193 TCID₅₀/gram body weight) at 222-238 days of age and killed 65 days after injection. Marked adhesion is observed among liver, stomach, intestine and diaphragm. $\times 1$

Fig. 3 Tumors at the retrorectal region of one of hamsters intraperitoneally injected with adenovirus type 12 (170 TCID₅₀/gram body weight) at 61-71 days of age and dead 112 days after injection. $\times 1/2$

Fig. 4 Spindle-shaped cells are arranged almost parallel to each other and attach to the fine stroma resembling cycad leaves. One of common patterns. $\times 400$





age. A dose of 170 TCID₅₀ per gram body weight produced tumors in one of 18 hamsters injected at 61~71 days of age, while the same dose per gram body weight produced tumors in 24 of 26 hamsters injected within 2 days after birth.

In hamsters injected at adult or young adult ages, one or two tumors developed in the abdomen in 100~393 days after injection. In one of these tumorous hamsters, besides a colossal abdominal tumor, several (probably metastatic) tumors were also observed in the liver. In hamsters injected when newborn, multiple tumors developed in the abdomen in 31~107 days after injection.

In many hamsters injected with 170 TCID₅₀ per gram body weight, regardless of age at the time of injection or of tumor development, various degrees of adhesion of the peritoneum including the liver capsule were macroscopically observed; liver lobes were adhering to each other, to the diaphragm, the intestine or the kidney (Fig. 1). The peritoneal adhesion was also observed in hamsters injected with adenovirus type 3, and the adhesion was more marked than in those injected with nearly the same dose of type 12 (Fig. 2). None of the hamsters similarly injected with the control tissue culture fluid developed tumors or the peritoneal adhesion.

Histo-morphological appearance of tumors and peritoneum: All tumors which developed in hamsters injected at 1~57 days of age, were histo-morphologically similar to the adenovirus-type-12-induced tumors developing in hamsters injected at birth which had been reported previously⁵. In sections of these tumors, tumor cells were usually spindle- or polygonal-shaped and packed closely to each other, but with narrow artificial spaces among them suggesting a behavior of epithelial cells. The cell arrangement appeared mostly irregular, but, in places, spindle-shaped cells took palisade arrangement or rosette-like structure. The spindle-shaped cells, and even the polygonal cells attached to the stroma with their extending cytoplasmic process (Figs. 4~6). There were observed only a few argyrophil fibers among tumor cells. On the other hand, tumors, which developed 112 days after injection at the retrorectal region of one of hamsters injected at 61~71 days of age, resembled histologically lymphosarcoma in appearance (Figs. 3, 7). The nuclei of these tumor cells were mostly spherical and the cytoplasm was scanty. In some parts, however, a

Fig. 5 A characteristic cell arrangement of the adenovirus-12-induced tumors showing a palisade pattern. Giant cells are observed among spindle-shaped cells. One of common patterns. $\times 400$

Fig. 6 Tumor cells are large and polygonal in shape. One of common patterns. $\times 400$

Fig. 7 Round-shaped cells with scanty cytoplasm are packed disorderly resembling lymphosarcoma-like neoplasm. Two giant cells are observed. A section of tumors in Fig. 3. $\times 500$

Fig. 8 Several cells have a fine cytoplasmic process extending to the stroma. A section of tumors in Fig. 3. $\times 400$

small number of cells attached to the stroma with their extending cytoplasmic process (Fig. 8). Numerous multinuclear giant cells were observed in all types of tumors which developed in the present experiment.

Two of hamsters injected with adenovirus type 12 at 61~71 days of age were sacrificed 6 days after injection. The histological observation of the peritoneum of these animals revealed the degeneration of serosa cells, the infiltration of leucocytes and the proliferation of fibroblasts. In hamsters injected with this virus when newborn, similar findings were observed and reported previously⁵. In none of two hamsters similarly injected with the control tissue culture fluid and sacrificed, such findings were observed.

Development of tumors and peritoneal adhesion in breeder hamsters : Thus far, 97 and 111 untreated hamsters in the breeder room have been observed for 12~28 and 6~12 months respectively. Of these, none have developed tumors or the peritoneal adhesion.

DISCUSSION

In our previous work, adenovirus type 12 induced tumors only in hamsters younger than 2 weeks of age². In the present experiment, tumors were induced even in hamsters as old as 2 months of age by increasing the virus dose. But, in hamsters injected at adult ages, the tumor incidence and the number of tumors per animal decreased and the latent period for tumor development became very long compared with those in hamsters injected when newborn. On the other hand, the peritoneal adhesion, which is obviously the result of early inflammatory change of the peritoneum, was observed regardless of the age of hamsters at the time of injection. All these results suggest that adenovirus type 12 more or less produces inflammatory change—the early non-fatal manifestation of its infection—in both newborn and adult hamsters, but usually produces tumors—the late fatal manifestation of its infection—only in those injected at very young ages. Isolations of adenovirus type 12 from children with acute inflammatory symptoms—the early manifestation of its infection—have been reported⁶⁻⁸. But presently nothing is known about the late manifestation of its infection in man. Our serological study have suggested that man, except for some 3% of them, has little chance to be severely infected with adenovirus type 12 within 6 months after birth⁹.

As reported previously, our histo-morphological study of the hamster tumors induced by adenovirus type 12 suggested that the tumors would have originated from neuroectodermal supporting cells⁵. In the present experiment, tumors which developed in one of hamsters injected at adult ages, were mostly composed of round or polygonal cells resembling lymphocytic cells. Develop-

ment of a tumor resembling lymphosarcoma had been also reported in one of hamsters injected intravenously with adenovirus type 12 at birth³. But the relation of some spindle-shaped cells to the stroma would suggest the possibility that this type of tumors might be also one of the neoplastic manifestations of primitive neuroectodermal, possibly neuroblastic, cells.

SUMMARY

Large doses of adenovirus type 12 were injected intraperitoneally into adult hamsters, and development of tumors and other pathological findings were studied in comparison with those in hamsters injected when newborn. Doses of 38~47 TCID₅₀ per gram body weight produced tumors in 3 of 12 hamsters injected at 37~57 days of age. A dose of 170 TCID₅₀ per gram body weight produced tumors in one of 18 hamsters injected at 61~71 days of age, but in none of 18 hamsters injected at 147~174 days of age, while the same dose per gram body weight produced tumors in 24 of 26 hamsters injected when newborn. In hamsters injected at adult ages, the number of tumors per animal decreased and the latent period for tumor development became very long as compared with those in hamsters injected when newborn. Regardless of the age at the time of injection, acute inflammatory change was observed in the peritoneum which later developed into various degrees of peritoneal adhesion. Adenovirus type 3 also induced the peritoneal adhesion. Histology of tumors was studied and discussed.

REFERENCES

1. TRENTIN, J. J., YABE, Y. and TAYLOR, G.: The quest for human cancer viruses. *Science* 137, 835, 1962
2. YABE, Y., TRENTIN, J. J. and TAYLOR, G.: Cancer induction in hamsters by human type 12 adenovirus. Effect of age and of virus dose. *Proc. Soc. Exp. Biol. Med.* 111, 343, 1962
3. YABE, Y., SAMPER, L., TAYLOR, G. and TRENTIN, J. J.: Cancer induction in hamsters by human type 12 adenovirus. Effect of route of injection. *Proc. Soc. Exp. Biol. Med.* 113, 221, 1963
4. REED, L. J. and MUENCH, H.: A simple method of estimating fifty per cent endpoints. *Am. J. Hyg.* 27, 493, 1938
5. OGAWA, K., TSUTSUMI, A., IWATA, K., FUJII, Y., OHMORI, M., TAGUCHI, K. and YABE, Y.: Histogenesis of malignant neoplasm induced by adenovirus type 12. *Gann* 57, 43, 1966
6. KIBRICK, S., MELNEDEZ, L. and ENDERS, J. F.: Clinical association of enteric viruses with particular reference to agents exhibiting properties of the ECHO group. *Ann. N. Y. Acad. Sci.* 67, 311, 1957
7. PEREIRA, M. S. and MACCALLUM, F. O.: Infection with adenovirus type 12. *Lancet* i, 198, 1964

154

Y. YABE, K. OGAWA, K. IWATA and S. MURAKAMI

8. OLSON, L. C., MILLER, G. and HANSHAW, J. B.: Acute infectious lymphocytosis presenting as a pertussis-like illness: its association with adenovirus type 12. *Lancet* **i**, 200, 1964
- 9 YABE, Y.: Antibody to adenovirus type 12 among infants. *Lancet* **i**, 1447, 1964