

# *Acta Medica Okayama*

---

*Volume 17, Issue 1*

1963

*Article 1*

FEBRUARY 1963

---

## Tissue culture of spleen : Studies on the growing pattern and its evaluation for clinical diagnosis of leukemias and other hematologic disorders

Kiyoshi Hiraki\*

Tadashi Ofuji†

Hiroshi Sunami‡

Zensuke Ota\*\*

Koichi Kitajima††

Koji Shinagawa‡‡

Masayoshi Kibata§

Isao Miyoshi¶

Atsumasa Hanazawa||

\*Okayama University,

†Okayama University,

‡Okayama University,

\*\*Okayama University,

††Okayama University,

‡‡Okayama University,

§Okayama University,

¶Okayama University,

||Okayama University,

# Tissue culture of spleen : Studies on the growing pattern and its evaluation for clinical diagnosis of leukemias and other hematologic disorders\*

Kiyoshi Hiraki, Tadashi Ofuji, Hiroshi Sunami, Zensuke Ota, Koichi Kitajima, Koji Shinagawa, Masayoshi Kibata, Isao Miyoshi, and Atsumasa Hanazawa

## Abstract

It has been found that the clinical tissue culture method devised in our laboratory for bone marrow is satisfactorily applicable to the in vitro study of human and animal splenic tissues. The present experiments have shown that the growth pattern, migration mode or cellular population of the cultured splenic cells is fairly characteristic of each disease condition, and the technic appears to be a valuable diagnostic aid in the practice of hematology. Direct vision biopsy with the laparoscope is safe and unattended by untoward side effects, enabling us to obtain excellent biopsy material from the enlarged spleen in various blood dyscrasias.

Acta Med. Okayama 17, 1-17 (1963)

**TISSUE CULTURE OF SPLEEN : STUDIES ON THE GROWING  
PATTERN AND ITS EVALUATION FOR CLINICAL  
DIAGNOSIS OF LEUKEMIAS AND OTHER  
HEMATOLOGIC DISORDERS**

Kiyoshi HIRAKI, Tadashi OFUJI, Hiroshi SUNAMI, Zensuke OTA,  
Koichi KITAJIMA, Koji SHINAGAWA, Masayoshi KIBATA,  
Isao MIYOSHI and Atsumasa HANZAWA

*Department of Internal Medicine, Okayama University Medical School,  
Okayama (Director : Prof. K. Hiraki)*

*Received for publication, January 23, 1963*

Using the tissue culture method devised by HIRAKI *et al.*,<sup>1-3</sup> we have succeeded in elucidating the mechanism of platelet formation from megakaryocytes and in establishing a new method valuable for the differential diagnosis of granulocytic, lymphocytic and monocytic leukemias. These results were reported at the VI,<sup>4</sup> VII<sup>5</sup> and VIII<sup>6</sup> International Congress of Hematology.

Application of the same tissue culture technic has enabled us to observe splenic cells *in vitro* which were obtained by biopsy from patients suffering from leukemias and other various blood dyscrasias.

The present paper deals with the growth pattern of cultured splenic tissue and cell morphology as studied mainly under the phase contrast microscope.

**MATERIALS AND METHODS**

Splenic tissue obtained from experimental animals (mouse, rat, guinea pig, rabbit, dog, and cat) and patients with various blood disorders were used. Only the hospitalized patients were subjected to laparoscopy. They were brought to an operating room and under local anesthesia splenic tissue was removed with the aid of a laparoscope. In addition, exploration of the liver and other abdominal organs was fully performed and liver biopsy was also done whenever indicated. The fresh tissues were cut into small pieces with sterile knives and cultured in the HIRAKI's tissue culture slide No. 1 (Fig. 1). As described in the previous papers,<sup>1-3</sup> a small piece of the tissue, about 1 mm. in size, was placed in the center of circle marked on the culture slide which was perviously mounted with one drop of homologous blood serum and one drop of vitamin B<sub>12</sub> (100  $\gamma$  per ml.), and sealed with the coverslip as illustrated in Fig. 2. For the study of megakaryocytic functions, the HIRAKI's tissue culture slide No. 2 was used (Fig. 1).<sup>7,8</sup>

After incubation at 37°C, the observation was carried out under the phase contrast and fluorescence microscope for 48 hours at various intervals of 6, 12, and 24 hours. In some instances, microcinematography was taken with or without vital staining with Janus green and neutral red.<sup>9</sup>

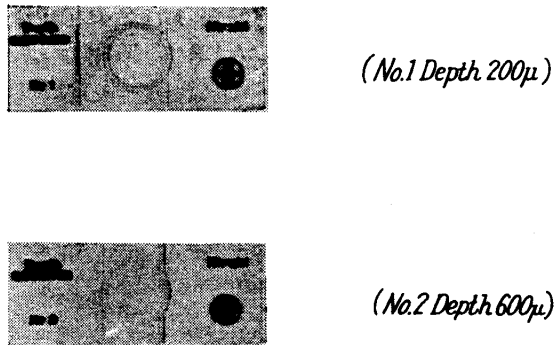


Fig. 1. Hiraki's tissue culture slide.

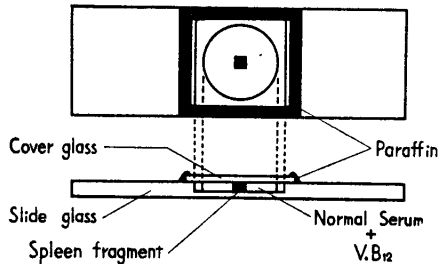


Fig. 2. Schema of our clinical tissue culture method

For the observation of reticulum cells, use was made of the roller tube method, in which rectangular coverslips explanted with tiny splenic tissue were placed in the test tubes (Fig. 3). Plasma clot was obtained from fowl plasma and the medium was prepared in the

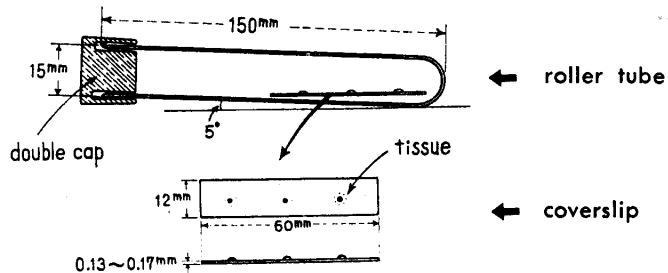


Fig. 3. Roller-tube and rectangular coverslip (60×12mm).

following proportions: inactivated fowl serum, 2 parts, chick embryo extract, 2 parts, and HANKS' solution, 6 parts. From time to time, the rectangular coverslips were removed from the test tubes and mounted with media on a glass slide in the center of which was a very shallow trough (Fig. 4). Vital observations were made on this preparation in a warm box at 37°C by means of a phase contrast microscope and microcin camera. It was found that reticulum cells began to appear in the growth zone of the 24 hour culture, and peak mitosis

occurred between 72 and 96 hours.

The vascular structure of the bone marrow was studied by means of the Spalteholz technic.

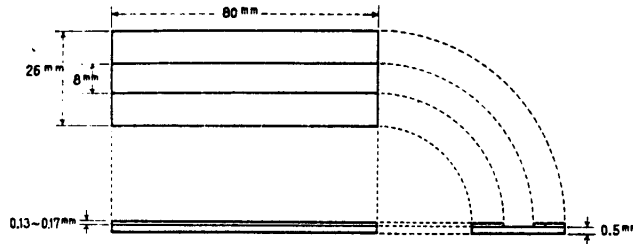


Fig. 4. Rail-formed slide glass for PCM observation.

#### OBSERVATIONS AND COMMENTS

##### 1. *Splenic tissue of the normal mouse.*

The pattern of tissue growth of normal mouse splenic tissue had much resemblance to that of normal mouse bone marrow. Generally, the cellular density was marked in the central portion around the explant and gradually decreased in the peripheral zone (Plate 1 a). The cellular composition, however, was quite different from that of bone marrow. Up to 12 hours the growth zone consisted almost entirely of mature lymphocytes with a few mature neutrophils, eosinophils and monocytes, while in the bone-marrow culture the area was largely occupied by neutrophils. The growth zone under the fluorescence microscope at this time looked yellowish green, which was mainly due to the nuclear fluorescence of lymphocytes. After 12 to 24 hours reticulum cells began to appear in the growth zone. They were followed by fibroblasts. After 48 hours the degenerative changes of the cells became marked.

##### 2. *Splenic tissue of mice with leukemia or leukemoid reaction.*

Splenic tissue from several strains of mice with leukemia were studied. Some of these leukemias were spontaneous in origin, some were induced by 20-methylcholanthrene painting or X-irradiation, and some were transplanted from other leukemic mice.<sup>10,11</sup> The pattern of tissue growth was similar to that of human acute leukemia; <sup>12-14</sup> cells in the growth zone were extremely dense and its boundaries were sharply demarcated both in acute lymphocytic and myelogenous leukemias (Plate 1 b). In acute lymphocytic leukemia the growth zone was occupied mainly by lymphoblasts and young lymphocytes, while in acute myelogenous leukemia, by myeloblasts and immature cells of the myeloid series. The fluorescence microscopic pattern of splenic tissue in mouse leukemia was similar to that of human leukemic bone marrow. The splenic tissue from chronic myelogenous leukemia induced in RF mice with methylcholanthrene did not show the pattern what we call "double growth zone" but assumed the pattern of acute

leukemia. This might have been due to the fact that in chronic myelogenous leukemia maturation of leukemic cells did not proceed in the spleen as in the bone marrow, which in culture exhibited the "double growth zone". Differential cell counts of splenic and bone marrow imprints gave support to this view.

In leukemoid reactions induced in pure strain mice by either saponin poisoning or M-Y sarcoma transplantation, the cell composition of the growth zone was quite different from that of normal spleen, although the pattern of tissue growth was rather similar (Fig. 5). Young granulocytes and megakaryocytes predomi-




Fig. 5. Spleen of mouse intoxicated by saponin. 6 hour culture.

nated. Fluorescence microscopy revealed the growth zone of diffusely reddish orange color, which was due to the fluorescence of granules of young granulocytic cells that appeared in a large number in the growth zone.

In the leukemoid reactions, the vascular beds of the bone marrow demonstrated some destruction of the walls of the venous sinusoids (Figs. 6, 7 and 8),

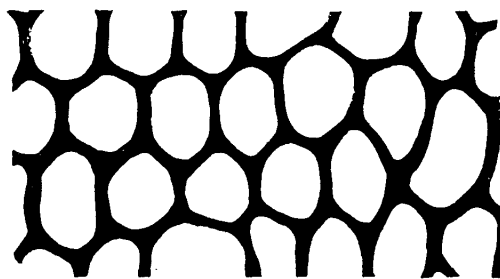


Fig. 6. Schema of bone marrow sinusoid in mouse.

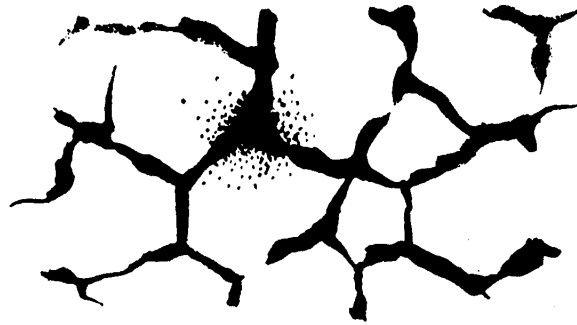

Fig. 7. Schema of bone marrow sinusoid in mouse intoxicated by saponin injection.



Fig. 8. Schema of bone marrow sinusoid in mouse transplanted with MY sarcoma.

indicating that the extramedullary hematopoiesis in the spleen was the result of colonization from the bone marrow.

### 3. *Splenic reticulum cells.*

Some of the reticulum cells demonstrated remarkable motility as well as phagocytosis. From the findings of vital observation, the reticulum cells were classified into three types. Type I: The most primitive or immature reticulum cells belonged to this type (Plate 1 c). They were four to five times as large as a small lymphocyte. Type II: To this type more differentiated cells than Type I reticulum cells were classified and they were further subdivided into Type II-a (Plate 1 d) and Type II-b (Plate 2 a). The former showed remarkable motility and the latter complicated branch-like pseudopodia. Type III: This was regarded as most differentiated reticulum cells (Plate 2 b). They contained many kinds of granules, phagocytized lymphocytes and erythrocytes in their cytoplasm. There was some resemblance between Type I reticulum cells and monoblasts or lym-

phogonias (AMANO),<sup>15</sup> between Type II-a reticulum cells and monocytes, between Type II-b reticulum cells and fibroblasts (Plate 2 c), and between Type III reticulum cells and ascitic phagocytes or histiocytes. But judging from their migratory form, mitochondrial distribution, appearance of granules and vacuoles with vital stains, and findings with fluorescence microscopy, we were able to differentiate one from another.

#### 4. Megakaryocytes in the spleen.

Megakaryocytes were found in the spleen of human and several kinds of mammals during their embryonic, newborn, infant, adolescent and adult ages. Using our clinical tissue culture slide No. 2, we investigated their motility and the mechanism of platelet separation (Fig. 9). The function of the megakaryo-

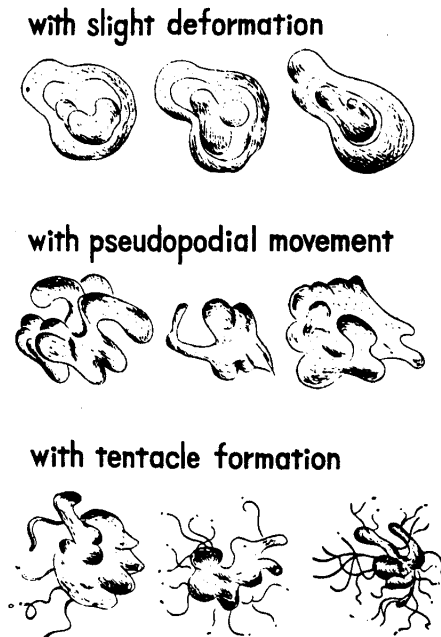


Fig. 9. Behaviors of megakaryocytes.

cytes of human subjects, guinea pigs, and rabbits decreased or vanished in the mid-embryonic stage (Plates 2 d and 3 a). In the cat it decreased after birth. In the mouse, rat, and dog, it remained during infancy but markedly decreased during adolescent and adult life (Plate 3 b). We found a close relationship between the function of the megakaryocytes and erythropoiesis in the spleen. The megakaryocytes in the spleen kept their motility and ability to separate off platelets only during the embryonic period or shortly after birth, coinciding with erythropoiesis in the spleen.



### 5. *Human splenic tissue.*

A number of observations on tissue culture of splenic tissue have been reported.<sup>16,17</sup> Most of these, however, were experimental studies with animals. Use of this technic on patients with splenomegaly has been generally unsatisfactory, probably because the fear of bleeding during biopsy did not permit to obtain a sufficient quantity of splenic tissue. To overcome this problem, we employed laparoscopy in performing direct vision splenic biopsy. The method assured that the biopsied tissue was adequate in size and allowed control of bleeding from the biopsy site even in cases with hemorrhagic diatheses (Table 1). We could perform biopsy if the patient's bleeding time was under 20 minutes. The biopsy material obtained in this fashion was used not only for tissue culture but also for histological and cytological observations.

#### a. *Splenic tissue from normal human subjects.*

Normal human spleens behaved in culture much like those of normal animals as already described. The pattern of splenic tissue growth was similar to that of normal human bone marrow, whereas cells found in the growth zone were mostly mature lymphocytes with a few neutrophils, eosinophils, monocytes, and reticulum cells.

#### b. *Leukemia* (Fig. 10).

In acute leukemia, including monocytic leukemia, either leukemic or aleukemic, the pattern of tissue growth was quite characteristic (Plate 3 c). The growth zone was heavily packed with increased immature cells and the boundaries of the growth zone were well-defined and clear-cut. Cells in the growth zone were mostly lymphoblasts and young lymphocytes in the case of acute lymphocytic leukemia, myeloblasts and immature granulocytic cells in the case of myelogenous leukemia, and monoblasts and promonocytes in the case of monocytic leukemia. This was clearly demonstrated under the fluorescence microscope. In chronic myelogenous leukemia, we cultured splenic tissue before, during and after chemotherapy. Even before treatment, the pattern of cell growth was somewhat different from that observed in cultures of bone marrow or peripheral leukocytes.

Table 1 CASES OF CULTURED SPLEEN

<i>Blood diseases</i>	
<i>acute lymphocytic leukemia</i> .....	2
<i>monocytic leukemia</i> .....	1
<i>chronic myelogenous leukemia</i> .....	5
<i>myelofibrosis</i> .....	1
<i>leukemic reticuloendotheliosis</i> .....	1
<i>Banti's disease</i> .....	12
<i>aplastic anemia</i> .....	6
<i>I. T. P.</i> .....	1
<i>iron deficiency anemia</i> .....	1
	30
<i>Other diseases</i>	
<i>liver cirrhosis</i> .....	6
<i>infectious disease</i> .....	2
<i>hemochromatosis in early stage</i> .....	1
<i>gastric cancer</i> .....	1
<i>hyperthyroidismus</i> .....	1
<i>splenomegaly of unknown pathogenesis</i> .....	2
	13
<i>Total</i> .....	43







Leukemia tissue	Leukemia		
	<i>non-leuk.</i>	<i>acute leuk.</i>	<i>chronic leuk.</i>
<i>spleen</i>			
<i>bone marrow</i>			

Fig. 10. Schematic patterns of tissue of spleen and bone marrow.

The "double growth zone" was not evident and the boundary of the growth zone was relatively well-defined. The growth zone consisted of 70—80% granulocytic leukemic cells (Plate 3 d) and, in most cases, a great number of mitoses were seen after 72 hours; in some cases basophils were markedly increased. In cases treated with Myleran, cell growth was diminished and fibroblasts were markedly increased. Hemoconiae were characteristically abundant.

c. *Leukemoid reaction due to myelofibrosis.*

Splenic tissue culture from a patient who had extreme splenomegaly and increased numbers of immature granulocytic cells in the peripheral blood for eight years showed in the growth zone numerous granulocytic cells, many of which were immature (Plate 4 a). Some erythroblasts were found near the explant and, furthermore, some megakaryocytes were scattered in the growth zone. From these results we could identify this disease as chronic myelofibrosis associated with extramedullary hematopoiesis and leukemoid reaction.

d. *Leukemic reticuloendotheliosis.*

Recently we encountered a case in which small lymphoblastoid cells with clear nucleoli and serrated protoplasmic membranes appeared in the peripheral blood in 50 per cent of the leukocytes during the terminal stage of the illness. Tissue culture of the bone marrow showed increased fat cells in the explant and decreased cell growth. On the other hand, culture of the splenic tissue showed the acute leukemic pattern with sharply defined growth zone and extremely high cell density. The growth zone was composed of the same cells as seen in the peripheral blood and larger malignant cells with abundant mitochondria and giant nucleoli (Plate 4 b). Many mitotic cells were also observed. Cytologically these cells showed a close resemblance to reticulum cells. The diagnosis of leukemic reticuloendotheliosis was confirmed by autopsy.

e. *Aplastic anemia.*

In aplastic anemia the growth pattern was almost normal in contrast to hypoplastic bone marrow. A few promyelocytes and myelocytes were always found in the growth zone. However, in some cases, plasma cells and eosinophils were definitely increased; in one case, we observed many wandering reticulum cells which phagocytized erythrocytes (Plate 4 c).

f. *Banti's disease.*

Compared with normal controls, most cases showed reduced growth rate and cell density. The growth zone consisted predominantly of mature lymphocytes and a few neutrophils. In the terminal stage, splenic reticulum cells and fibroblasts were relatively increased.

g. *Idiopathic thrombocytopenic purpura.*

In idiopathic thrombocytopenic purpura, it was of interest to note that many megakaryocytes with diminished motility and platelet separation appeared in the growth zone as in the bone marrow culture.

h. *Splenomegaly due to infection.*

The pattern of tissue growth resembled the normal but its growth rate was very high and mature neutrophils were increased up to 30~40 per cent of the total cells in the growth zone, while immature granulocytic cells did not appear in contrast to myelogenous leukemia and leukemoid reaction (Plate 4 d).

#### SUMMARY

It has been found that the clinical tissue culture method devised in our laboratory for bone marrow is satisfactorily applicable to the *in vitro* study of human and animal splenic tissues. The present experiments have shown that the growth pattern, migration mode or cellular population of the cultured splenic cells is fairly characteristic of each disease condition, and the technic appears to be a valuable diagnostic aid in the practice of hematology.

Direct vision biopsy with the laparoscope is safe and unattended by untoward side effects, enabling us to obtain excellent biopsy material from the enlarged spleen in various blood dyscrasias.

#### REFERENCES

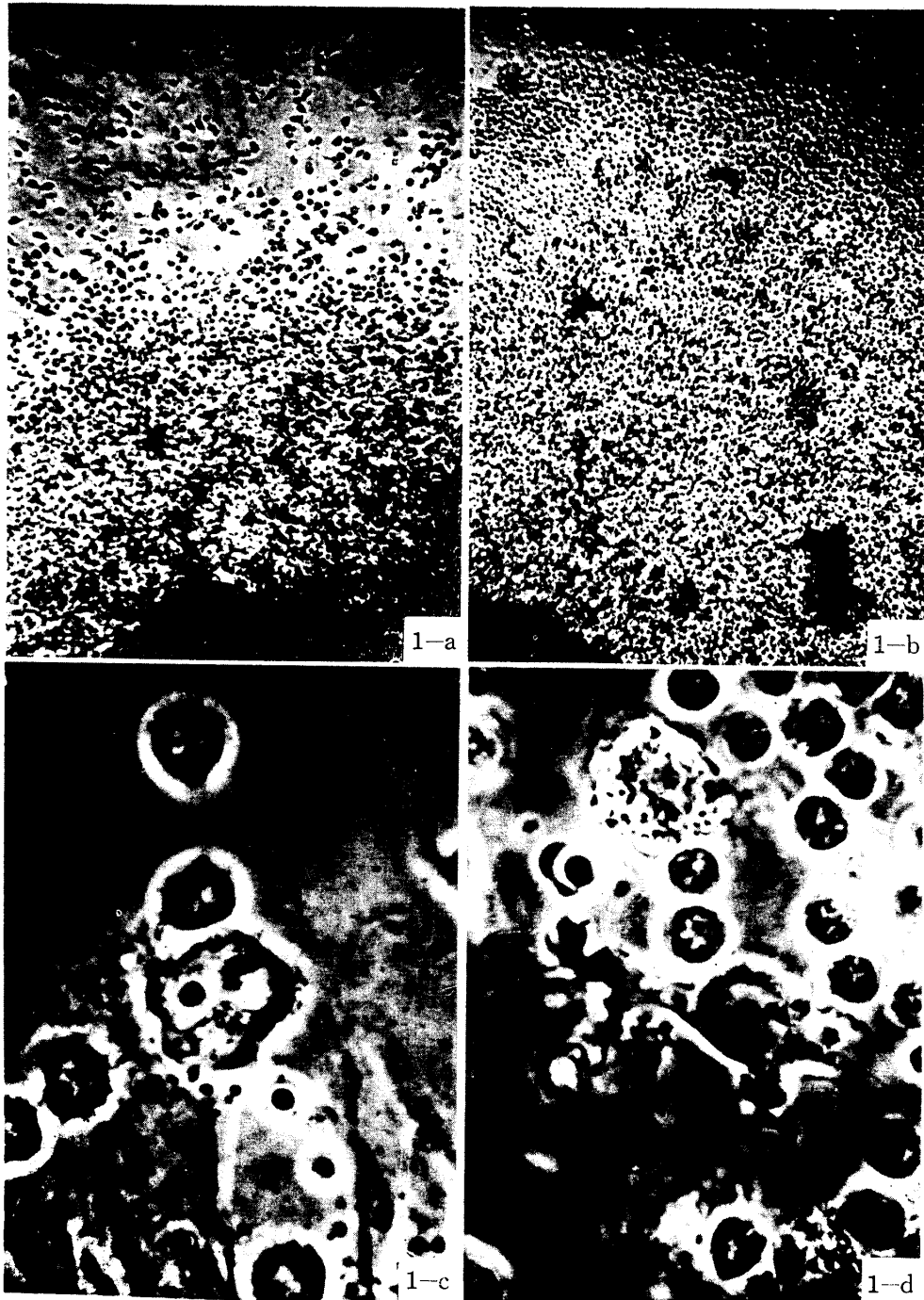
1. HIRAKI, K., OFUJI, T. and SUNAMI, H.: The method of tissue culture (mainly of the bone marrow) and a simple method of observing tissue. *Acta Med. Okayama* 10, 99, 1956
2. HIRAKI, K., OFUJI, T. and WATARI, Z.: Observation of various living blood cells by tissue culture of the bone marrow. *ibid.* 10, 110, 1956
3. HIRAKI, K., SUNAMI, H. and SOGAWA, T.: Fundamental studies on the peripheral leukocyte culture and its clinical application. *ibid.* 10, 139, 1958

4. HIRAKI, K.: The function of the megakaryocyte (motility, separation of the platelet and phagocytosis): observations both in idiopathic thrombocytopenic purpura and in normal adults. *Proc. 6th Intern. Congr. Intern. Soc. Hemat.* 537, 1958
5. HIRAKI, K.: Studies on diagnosis of leukemia by tissue culture. *Proc. 7th Intern. Congr. Intern. Soc. Hemat.* 307, 1960
6. HIRAKI, K.: Studies on chemotherapy of leukemia by a new bone-marrow tissue culture technic. *Proc. 8th Intern. Congr. Intern. Soc. Hemat.* 371, 1962
7. HIRAKI, K., OFUJI, T., KOBAYASHI, T., SUNAMI, H. and AWAI, K.: On the function of the megakaryocyte (motility, separation of the platelet, phagocytosis). Observations both in idiopathic thrombocytopenic purpura and normal adult. *Acta Med. Okayama* 10, 57, 1950
8. HIRAKI, K., SUNAMI, H. and OGAWARA, K.: Studies on the megakaryocytes, platelets separation and degeneration. *ibid.* 12, 187, 1958
9. OTA, Z.: A study on the cytomorphologic structure of blood cells by vital staining. Part 1. Normal human blood cells in the bone marrow. Part 2. Leukemic cells in the bone marrow. *ibid.* 14, 22, 1960
10. OKADA, K., MIYOSHI, I., KAWAMURA, N. and SATO, M.: Studies on leukemogenesis by cell-free filtrates of AKR mouse leukemia, *Acta Haemat. Jap.* 25, 1, 1962
11. HIRAKI, K., IRINO, S. and SOTA, S.: Studies on cytogenesis of RF mouse leukemia induced by X-ray irradiation. *Proc. 8th Congr. Europ. Soc. Haemat.* 347, 1962
12. HIRAKI, K., OFUJI, T. and HATTORI, Y.: Diagnosis of leukemia, and aplastic anemia by the bone marrow culture. *Acta Med. Okayama* 10, 130, 1956
13. HIRAKI, K.: Studies on diagnosis of leukemia by tissue culture. *ibid.* 12, 84, 1958
14. HIRAKI, K.: Étude de la chimiothérapie des leucémies par une nouvelle technique de culture de moelle osseuse. *N. R. F. Hémat.* 1, 410, 1961
15. AMANO, S., UNNO, G., HANAOKA, M. and TAMAKI, Y.: Studies on the discrimination of lymphocytes and plasma cells. Supplements on advocacy of the lymphogonia-theory. *Acta Path. Jap.* 1, 117, 1951
16. FAZZARI, J.: Culture "in vitro" di milza embryonale ed adulta *Arch. exper. Zellforsch.* 2, 307, 1926
17. ERDMANN, R., EISNER, H. und LASEO, H.: Das Verhalten der foetalen, postfoetalen und ausgewachsenen Rattenmilz unter verschiedene Bedingungen in vitro. *Arch. exper. Zellforsch.* 2, 361, 1926

#### EXPLANATION FOR PLATE 1

- a. Normal mouse spleen. 6 hour culture.
- b. RF mouse spleen with acute lymphocytic leukemia. 6 hour culture.
- c. Splenic reticulum cell (Type I) in normal mouse. 72 hour culture.
- d. Splenic reticulum cell (Type IIa) showing active movement in normal mouse.

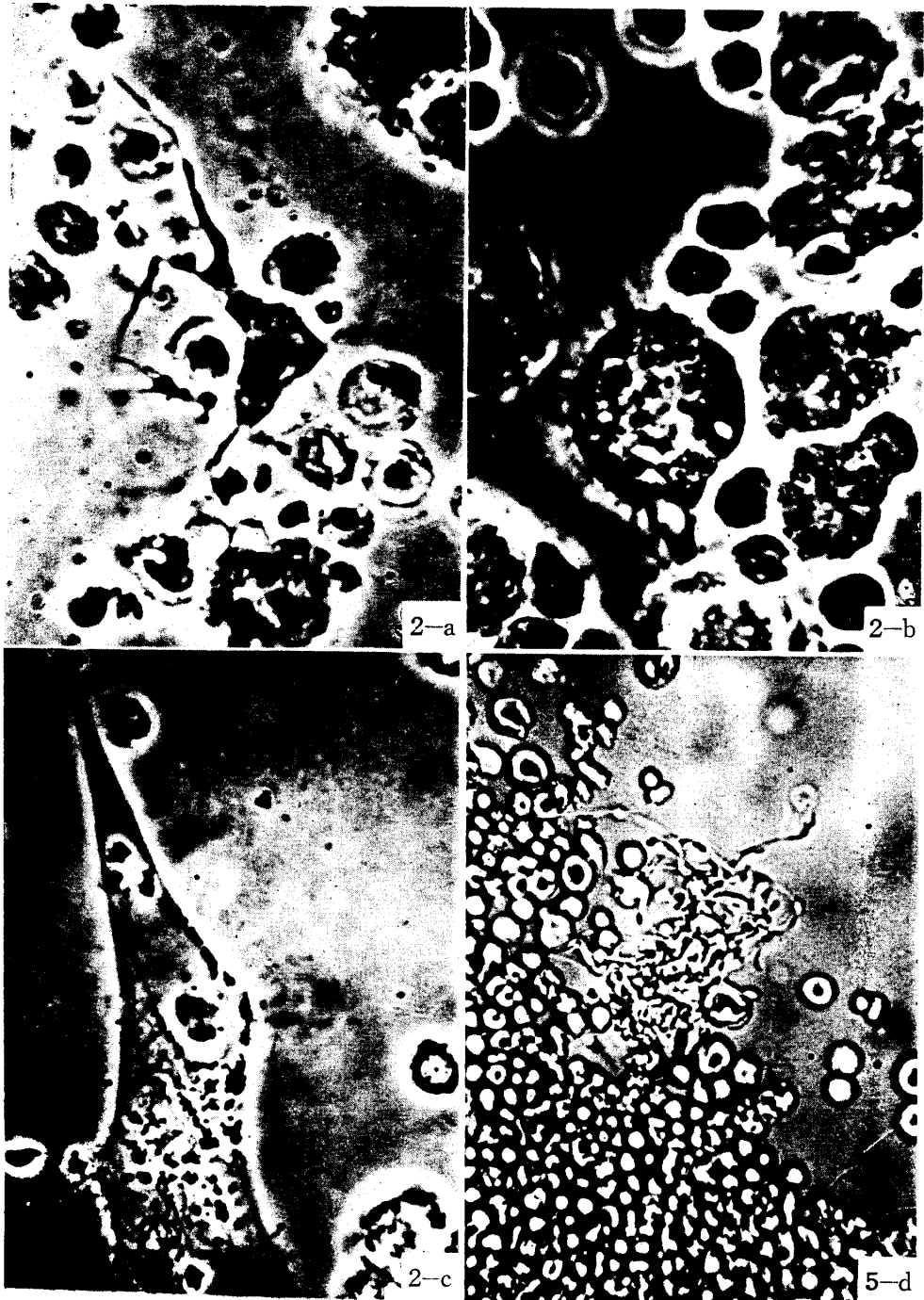
Plate 1



EXPLANATION FOR PLATE 2

- a. Splenic reticulum cell (Type II-b) in normal mouse.
- b. Splenic reticulum cell (Type III) with many phagocytized granules in normal mouse.
- c. Fibroblast in normal mouse spleen.
- d. Human splenic megakaryocyte in 4-month-old fetus with tentacle formation. 18 hour culture.

Plate 2

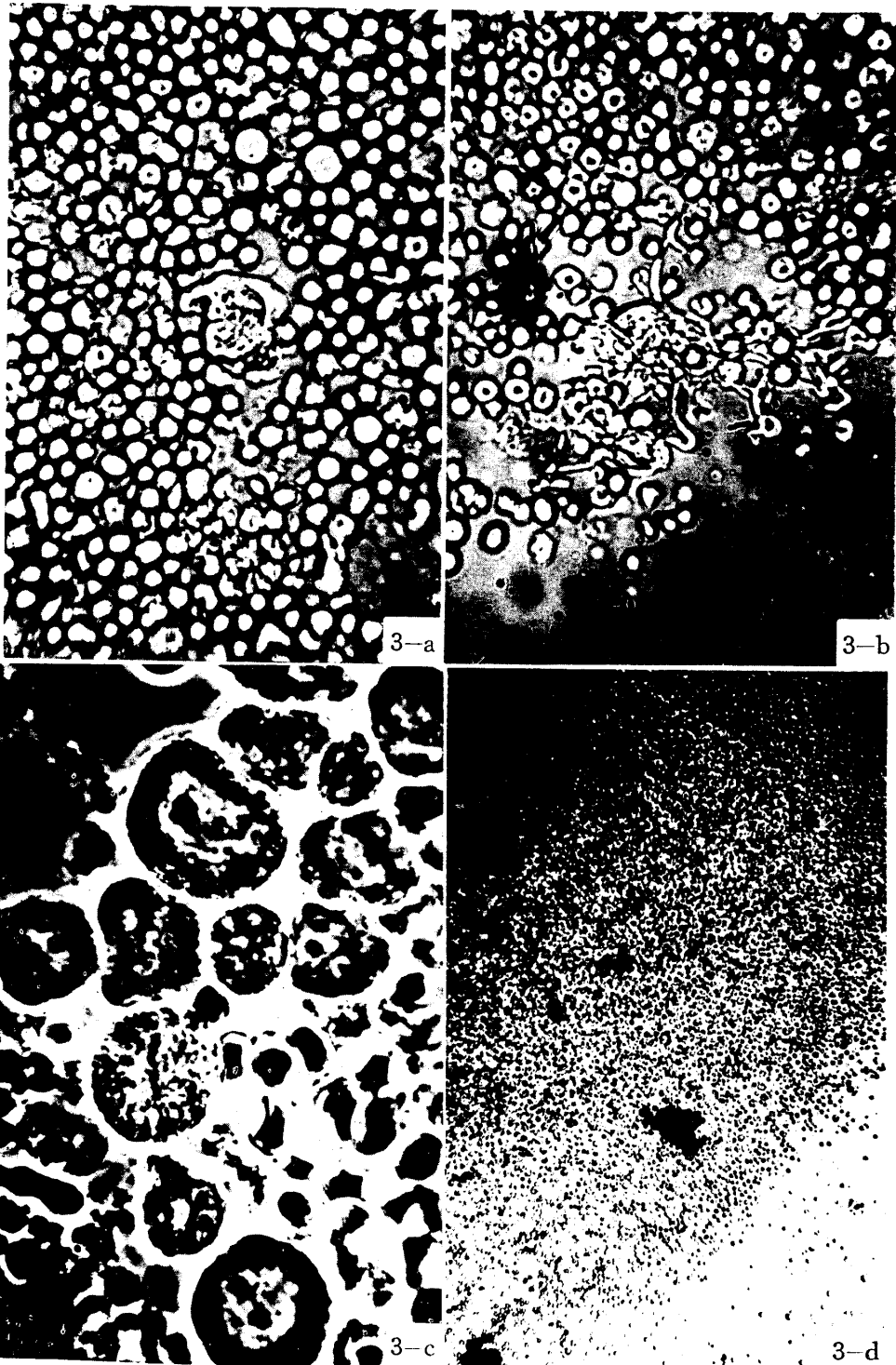


EXPLANATION FOR PLATE 3

- a. Human splenic megakaryocyte in 5-month-old fetus with pseudopodial movement. 18 hour culture.
- b. Megakaryocyte with tentacle formation in young mouse. 18 hour culture.
- c. Human spleen in acute lymphocytic leukemia. 6 hour culture.
- d. Human spleen in chronic myelogenous leukemia. 48 hour culture.



Plate 3



EXPLANATION FOR PLATE 4

- a. Human spleen in leukemoid reaction due to myelofibrosis. 6 hour culture.
- b. Human spleen in leukemic reticuloendotheliosis. 48 hour culture.
- c. Human reticulum cell with phagocytized erythrocytes in aplastic anemia. 48 hour culture.
- d. Human spleen in infectious disease. 6 hour culture.

Plate 4

