

Acta Medica Okayama

Volume 58, Issue 2

2004

Article 4

APRIL 2004

Talonavicular joint abnormalities and walking ability of patients with rheumatoid arthritis.

Noriyoshi Miyamoto*

Masuo Senda[†]

Masanori Hamada[‡]

Yoshimi Katayama**

Atsushi Kinoshita^{††}

Kensuke Uchida^{‡‡}

Hajime Inoue[§]

*Okayama University,

[†]Okayama University,

[‡]Okayama University,

**Okayama University,

^{††}Okayama University,

^{‡‡}Okayama University,

[§]Okayama University,

Talonavicular joint abnormalities and walking ability of patients with rheumatoid arthritis.*

Noriyoshi Miyamoto, Masuo Senda, Masanori Hamada, Yoshimi Katayama,
Atsushi Kinoshita, Kensuke Uchida, and Hajime Inoue

Abstract

Rheumatoid arthritis (RA) is often associated with deformities of the feet, and foot pain often arises in the talonavicular joint of patients with RA. The object of this study was to assess the relationship between magnetic resonance imaging (MRI) findings of the talonavicular joint and walking ability. The subjects were 35 RA patients (10 feet in 5 males and 56 feet in 30 females) aged 34-87 years (mean: 70 years +/- 12.1), with a disease duration from 1-54 years (mean: 14 years +/- 12.1). MRI findings were classified as follows: Grade 1, almost normal; Grade 2, early articular destruction; Grade 3, moderate articular destruction; Grade 4, severe articular destruction; and Grade 5, bony ankylosis dislocation. Walking ability was classified into one of 9 categories ranging from normal gait to bedridden status according to the system of Fujibayashi. As the grade of MRI images became higher the walking ability decreased, and these parameters showed a correlation by Spearman's rank correlation coefficient analysis ($P = 0.003$). Thus, in the present cohort group of patients with RA, the deterioration of walking ability increased with the severity of destruction of the talonavicular joint.

KEYWORDS: ?rheumatoid arthritis, magnetic resonance imaging, talonavicular joint, walking ability

*PMID: 15255509 [PubMed - indexed for MEDLINE]

Copyright (C) OKAYAMA UNIVERSITY MEDICAL SCHOOL

Original Article

Talonavicular Joint Abnormalities and Walking Ability of Patients with Rheumatoid Arthritis

Noriyoshi Miyamoto*, Masuo Senda, Masanori Hamada, Yoshimi Katayama, Atsushi Kinoshita, Kensuke Uchida, and Hajime Inoue

Department of Orthopaedic Surgery, Okayama University Graduate School of Medicine and Dentistry, Okayama 700-8558, Japan

Rheumatoid arthritis (RA) is often associated with deformities of the feet, and foot pain often arises in the talonavicular joint of patients with RA. The object of this study was to assess the relationship between magnetic resonance imaging (MRI) findings of the talonavicular joint and walking ability. The subjects were 35 RA patients (10 feet in 5 males and 56 feet in 30 females) aged 34-87 years (mean: 70 years \pm 12.1), with a disease duration from 1-54 years (mean: 14 years \pm 12.1). MRI findings were classified as follows: Grade 1, almost normal; Grade 2, early articular destruction; Grade 3, moderate articular destruction; Grade 4, severe articular destruction; and Grade 5, bony ankylosis dislocation. Walking ability was classified into one of 9 categories ranging from normal gait to bedridden status according to the system of Fujibayashi. As the grade of MRI images became higher the walking ability decreased, and these parameters showed a correlation by Spearman's rank correlation coefficient analysis ($P = 0.003$). Thus, in the present cohort group of patients with RA, the deterioration of walking ability increased with the severity of destruction of the talonavicular joint.

Key words: rheumatoid arthritis, magnetic resonance imaging, talonavicular joint, walking ability

Deformity of the foot occurs frequently in patients with rheumatoid arthritis (RA). Bone and joint deformities are gradually caused by the thickening and proliferation of the synovium and articular capsule and loosening of muscles and ligaments. For abnormalities of the hip or knee joint in RA patients, favorable results have long been obtained by using artificial joints. In contrast to the hip or knee, few reports have been published on abnormalities of the foot in RA. In particular, there have been few studies based on X-ray and magnetic resonance imaging (MRI) examination of foot

abnormalities in RA. Mark *et al.* [1-4] reported that deformity and pain of the talonavicular joint are common in RA patients. Higashi *et al.* [5, 6] reported that deformity of the foot occurs due to the depression of the vertical axis arch. Such deformity may progress depending on the severity of talonavicular joint subluxation and may come to have a considerable influence on walking. The talonavicular joint thus has a significant influence on quality of life (QOL) in RA patients. To date, however, there have been no few extensive evaluations of this joint. And while both total knee replacement (TKR) and total hip replacement (THR) are established treatments, the best therapy for foot abnormalities in RA remains controversial. There is thus need of further investigation into deformity of the talonavicular joint in patients with RA.

Received April 18, 2003; accepted November 26, 2003.

*Corresponding author. Phone: +81-86-273-6073; Fax: +81-86-273-6073

We recently classified talonavicular joint abnormalities based on MRI findings and evaluated their relationship to walking ability in a general cohort. The objective of the present study was to extend our exploration of the relationship between MRI findings of the talonavicular joint and walking ability to patients with RA.

Materials and Methods

Studied patients. We studied 66 feet of 35 patients with RA who had not undergone surgical treatment of the foot. There were 10 feet in 5 men and 56 feet in 30 women, and the patients ranged in age from 34 to 87 years (mean age: 70 years \pm 12.1). The duration of RA varied from 1 to 54 years (mean: 14 years \pm 12.1). The patients had been treated with nonsteroidal anti-inflammatory agents, steroids, gold preparations, and immunosuppressants. There were 8 patients who had been on steroid therapy with methylprednisolone (2 mg/1 day) for at least 1 year. Two patients had undergone unilateral total hip replacement and 4 patients had received unilateral total knee replacement. Laboratory test values for rheumatoid factor (RAF), C reactive protein (CRP), and erythrocyte sedimentation rate (ESR), as well as X-ray and MRI views of the talonavicular joints, were reviewed. Walking ability was assessed using Fujibayashi's classification [7].

X-ray films. Lateral X-ray films of the talonavicular joint and views obtained at 30 degrees from the ankle axis were reviewed. Talonavicular joint abnormalities were classified according to Larsen's classification. [8]

MRI examination and assessment of talonavicular joint abnormalities. Using a brace, the foot was fixed with the ankle joint at 0 degrees, and sagittal and coronal T1- and T2-weighted images were obtained (Fig. 1). The sagittal T2-weighted images were used for evaluation. The MRI apparatus was a Toshiba MRT-50GP (0.5 T). The routine study protocol consisted of T1-weighted images (reverse time (TR)/ echo time (TE) = 600–650/20–25 ms) and T2-weighted images (TR/TE = 600–650/20–25 ms). The conditions were as follows: matrix, 128 \times 256; field of volume (FOV), 18 cm; slice, 5-mm thick with a 0.7-mm gap.

The severity of talonavicular joint destruction was classified as Grade 1–5 on the basis of MRI findings. Grade 1 joints showed no cartilage or bone deformity. Early joint destruction with mild cartilage or bone changes

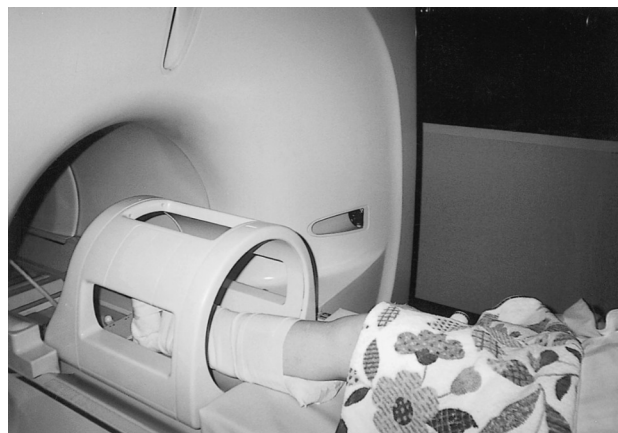

Fig. 1 Plastic gyps fixation. The foot was fixed with the ankle joint at 0 degrees.

was classified as Grade 2, while moderate joint destruction was classified as Grade 3. Severe destruction of the talonavicular joint with marked cartilage or bone changes was classified as Grade 4, while ankylosis or dislocation of the joint was classified as Grade 5 (Fig. 2).

All MRI scorings were reviewed by 2 independent orthopaedists on the same day.

Assessment of walking ability. Walking ability was classified according to the method of Fujibayashi [7] as follows: Class 2 patients walked normally. Class 3a patients could walk 500 to 1,000 m, but were unable to ascend stairs, Class 3b patients could walk with a walking stick, Class 3c patients could walk only in the hospital garden, and Class 3d patients could walk only indoors. Class 4a patients could walk minimally, Class 4b patients could not use a wheelchair effectively, and Class 4d patients were bedridden.

Statistical Analysis. Statistical analysis was performed using Spearman's rank correlation analysis procedure, with the level of significance set at $P < 0.05$.

Results

MRI findings and laboratory values. The RA factor values ranged from (–) to (2+), the CRP values from 0.15–11.9 (mean: 4.12 \pm 3.31), and the ESR values (1-h value) from 1.0–124 (mean: 55.5 \pm 25.4). No correlation was found between abnormalities of the talonavicular joint on MRI and any of the laboratory test values.

X-ray findings. The X-ray changes could be

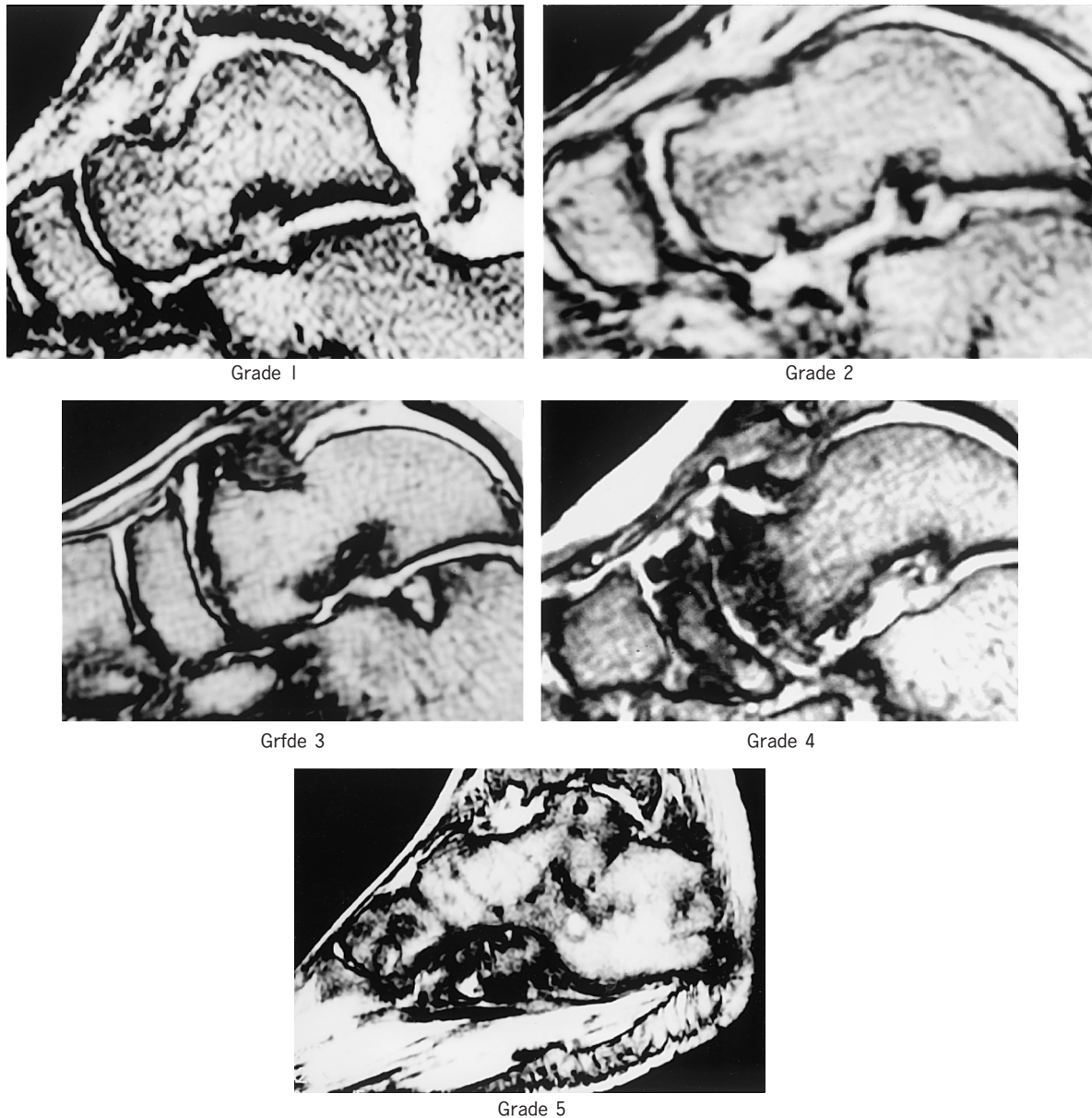


Fig. 2 MRI classification of the talonavicular joint in T2-weighted image. Grade 1, Normal, no cartilage or bone deformity; Grade 2, Early joint destruction with mild cartilage or bone changes; Grade 3, Moderate joint destruction; Grade 4, Severe destruction of the talonavicular joint with marked cartilage or bone changes; Grade 5, Ankylosis or dislocation of the talonavicular joint.

followed in only 52 joints of 27 patients, because some patients died and others changed hospitals. According to Larsen's classification, there was one Grade 0 foot, 6 Grade 1 feet, and 16 Grade 5 feet. No relationship was detected between the plain X-ray findings and walking ability.

Relationship between the MRI

classification of talonavicular joint and Walking ability. According to the MRI findings, the talonavicular joint classification was Grade 1 in 7 joints (10.6%), Grade 2 in 21 joints (31.8%), Grade 3 in 13 joints (19.7%), Grade 4 in 15 joints (22.7%), and Grade 5 in 10 joints (15.2%). The mean duration of disease was 2.5 years for Grade 1 joints, 9.5 years for Grade 2 joints,

13 years for Grade 3 joints, 17 years for Grade 4 joints, and 28 years for Grade 5 joints.

Among patients with a Grade 1 joint on MRI, there was one patient who was Class 2 and one who was Class 3a with respect to walking ability, and these patients had almost no problems with walking. Among patients with a Grade 2 talonavicular joint, walking ability was judged as Class 2 in 2 patients, Class 3a in 2, Class 3b in 3, Class 3c in 2, Class 4c in 1, and Class 4d in 1. The patients with Class 4c or Class 4d walking performance had cerebral infarction as well as RA. Among patients with a Grade 3 talonavicular joint, the walking performance was Class 3a in 1 patient, Class 3b in 3, Class 3c in 3, and Class 4b in 1. Among patients with a Grade 4 talonavicular joint, the walking performance was Class 3a in 2 patients, Class 3b in 1, Class 3c in 1, Class 3d in 1, Class 4a in 1, and Class 4d in 1. Among patients with a Grade 5 talonavicular joint, walking performance was Class 4a in 1 patient and Class 4d in 5 patients (Fig. 3).

Among patients in whom the MRI views of the bilateral talonavicular joints were obtained, both joints were usually of the same grade. When the 2 joints were of different grades, the joint with the higher grade was evaluated.

Using Spearman's rank correlation analysis, a significant correlation was detected between the MRI classification of talonavicular joint abnormalities and walking performance ($P = 0.003$).

Discussion

Deformity of the foot occurs relatively often in RA and tends to cause disturbance of daily activities. Calabro

et al. [9] reported that valgus flat foot is a common deformity in patients with RA and that talonavicular joint abnormality is the main cause of such deformity. Mark and Wigren *et al.* [1, 10] reported that deformity and pain of the talonavicular joint are frequent problems among RA patients with valgus flat foot. Cracchiolo, Elbor, and Hollinshead [11, 12, 13] proposed that the talonavicular joint participate the deformity and pain of the foot. The deformity and pain due to this joint are located at the crest of the arch of the foot, often consist of plantar flexion and dorsiflexion of the ankle. Because the ankle joint is not surrounded by muscles, it sustains the body weight on the articular surfaces of the bones (tibia, fibula, talus, and navicular), and pressure is transmitted to the talonavicular joint. Therefore, talonavicular joint deformity is gradually caused by such pressure. Higashi *et al.* [5] stated that shearing of the talonavicular joint can rapidly cause depression of the vertical axis of the foot arch, resulting in deformity of the foot. Therefore, we considered that the talonavicular joint was important in the etiology of foot pain in RA patients. Evaluation of this joint is important when assessing pedal involvement by RA. Despite these facts, there have been no few recent reports on MRI evaluation of the talonavicular joint. We considered that MRI may be an accurate method for the assessment of talonavicular joint abnormalities, since it more precisely visualizes the joint space, bones, and synovial membrane than plain X-ray. When MRI was performed to assess the talonavicular joint in our RA patients, the ankle joint was fixed at 0 degrees. We initially devised a wooden brace to fix the foot, but switched to plastic-brace fixation because our patients with advanced RA had pes equines and suffered severe pain during MRI. Our use of 0-degree fixation may have affected the results and thus may represent a limitation of the present study. Although both T1-weighted and T2-weighted images were obtained, the latter were more suitable for investigation of synovial inflammation proliferation and joint destruction. In addition, intra- and extra-articular soft tissues and effusions can be quantified by T2-weighted images.

We investigated the severity of synovial inflammation, narrowing of the joint space, and bone destruction, and classified the changes using a 5-grade scale. Among patients with Grade 1 changes on MRI, there was mild bone destruction and, in most cases, a walking performance of Class 2 or 3-*i.e.*, no influence on daily activities. Most patients with Grade 2 changes on MRI were Class

MRI grade	Walking ability					
	2	3a	3b	3c	4c	4d
Grade1	2		3a			
Grade2	2	3a	3b	3c	4c	4d
Grade3	3a	3b	3c		4b	
Grade4	3a	3b	3c	3d	4a	4d
Grade5	4a	4d				

Fig. 3 MRI classification of talonavicular joint abnormalities were significantly correlated with walking ability ($P = 0.003$ by Spearman's rank correlation analysis).

2 or 3 with respect to walking status, although 2 patients with Grade 2 changes were almost bedridden due to cerebral infarction and were Class 4 with respect to walking. Patients with Grade 3 or Grade 4 changes on MRI had advanced joint destruction and often were confined to a wheelchair. Most patients with Grade 5 changes on MRI were bedridden. The significant correlation between MRI grade and walking performance suggested that the severity of talonavicular joint changes had an influence on walking ability.

The hip and knee joint have been extensively studied in RA patients, and there are established treatment modalities for damages to these joints, including total joint replacement. However, deformity of the foot has an impact on activities of daily living (ADL) in RA. It is thus necessary to pay attention to the talonavicular joint as well as the hip and knee joints. It may be beneficial to perform surgical fixation when the joint is Grade 3 or worse in order to reduce pain [3, 14, 15]. MRI revealed advanced bone changes and Grade 3 joints, even in patients who were Larsen's Grade 2 on plain X-ray films. Thus, MRI showed the condition of the joint more precisely than plain X-ray (Fig. 4), and MRI was considered to be a more appropriate tool for assessing talonavicular joint destruction in RA. Akagi *et al.* [16]

reported that foot disease was rarely the main factor causing impairment of ADL and that there was no consistent influence of deformity or X-ray changes of the foot on ADL. However, we showed a correlation between the MRI severity of talonavicular joint changes and Fujibayashi's classification of walking performance (Spearman's rank correlation analysis, $P = 0.003$). This difference in results was likely due to the fact that Akagi *et al.* used X-ray film data, whereas we used MRI data, which more precisely visualizes pathological changes of the bones and joints. In conclusion, not only the hip and knee joints, but also the talonavicular joint can influence ADL and walking ability in patients with RA. It is therefore necessary to pay more attention to the talonavicular joint when assessing RA patients.

References

1. Figgie MP, Sobel M and Geppert MJ: The hind foot; in Surgical Treatment of Rheumatoid Arthritis, Sculco TP ed, 1 th Ed, Mosby, New York (1992) pp 273-313.
2. Vidigal E, Jacoby RK, Dixon A, Ratliff AH and Kirkup J: The foot in chronic rheumatoid arthritis. *Ann Rheum Dis* (1975) 34: 292-297.
3. Ljung P, Kaij J, Knutson K, Pettersson H and Rydholm U: Talonavicular arthrodesis in the rheumatoid foot. *Foot Ankle* (1992) 13: 313-316.
4. Vaino K: The rheumatoid foot. A clinical study with pathological and

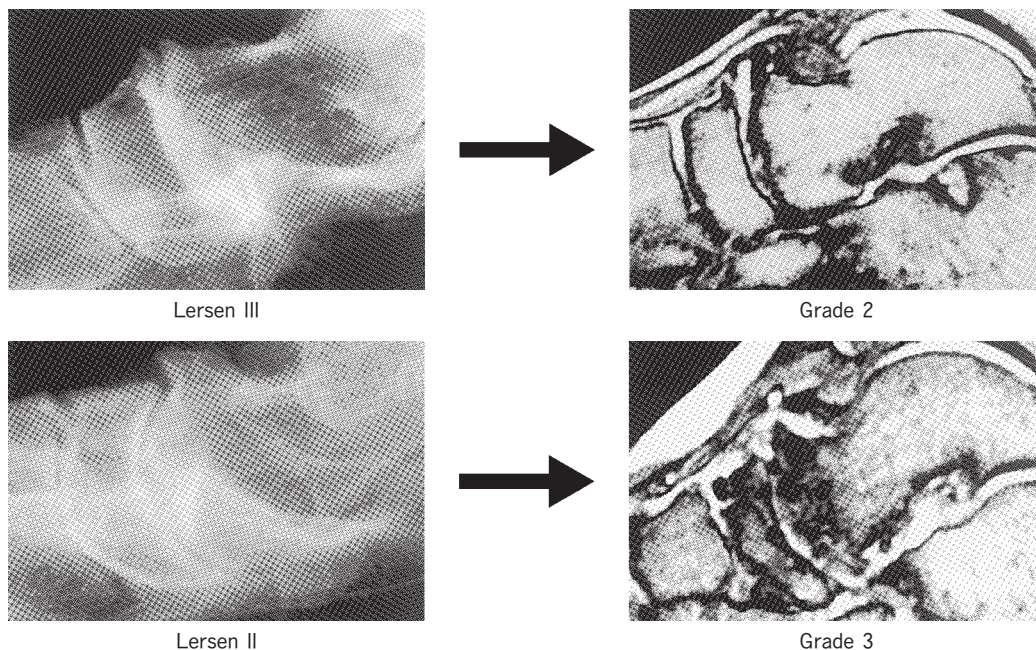


Fig. 4 MRI visualized the talonavicular joint more precisely than plain X-ray.

- roentgenographical comments. *Ann Chir Gynaecol Suppl* (1956) 45: 1.
5. Higashi B, Yamamoto T, Kimura T, Oti T and Ono K: Natural course and surgical treatment of hind foot deformity in Rheumatoid Arthritis. *Rinsyouryumati (Clin Rheumatol)* (1991) 4: 121-127 (in Japanese).
 6. Katsuki I and Torisu T: The pathomechanics of the deformity of rheumatoid foot. *Seikeisaigaigeka (Orthopaedic Surgery and Traumatology)* (1984) 11: 1605-1609 (in Japanese).
 7. Fujibayashi H, Gouda H, Maeno K, Kobayashi M, Fukumoto K, Kitakawa T, Yokota M, Hamaguti M and Wada M: Effect of Rehabilitation on the arthritis patients; Due to follow-up studies. *Rigakuryouhou To Sagyoryouhou (The Japanese journal of physical therapy and occupational therapy)* (1977) 11: 209-217 (in Japanese).
 8. Larsen A, Dale K and Eek M: Radiographic evaluation of rheumatoid arthritis and related conditions by standard reference films. *Acta Radiol Diagn* (1977) 18: 481-491.
 9. Calabro JJ: A critical evaluation of the diagnostic features of the feet in rheumatoid arthritis. *Arthritis Rheum* (1962) 5: 19-29.
 10. Wigren A: Operative treatment with special regard to the hind foot. *Arthritis Rheum* (1987) 11: 100-103.
 11. Cracchiolo A: Surgical for rheumatoid disease. *Instr Course Lect* (1984) 33: 386-411.
 12. Elbar JE, Thomas WH, Weinfeld MS and Potter TA: Talonavicular arthrodesis for rheumatoid arthritis of the hindfoot. *Orthop Clin North Am* (1976) 7: 821-826.
 13. Hollinshead WH: *Functional anatomy of the limbs and back*. 3rd Ed, WB Saunders company, Philadelphia (1969) p 342.
 14. Figgie MP, O'malley MJ, Ranawat CR, Inglis AE and Sculco TP: Triple arthrodesis in rheumatoid arthritis. *Clin Orthop* (1993) 292: 250-254.
 15. Cracchiolo A IIIrd, Pearson S, Kitaoka H and Grace D: Hindfoot arthrodesis in adults utilizing a dowel graft technique. *Clin Orthop* (1990) 257: 193-203.
 16. Akagi S, Saitou T, Morimoto T, Sugano H and Ogawa R: Hind deformity and its significance for ADL in rheumatoid arthritis patients of long duration. *Seikeisaigaigeka (Orthopaedic Surgery and Traumatology)* (1993) 36: 1623-1630 (in Japanese).