

Acta Medica Okayama

Volume 61, Issue 1

2007

Article 7

FEBRUARY 2007

Multiple gastrointestinal stromal tumors in neurofi bromatosis type 1 treated with laparoscopic surgery

Kazunori Tsukuda, *Okayama Red Cross General Hospital*

Eiji Ikeda, *Okayama Red Cross General Hospital*

Shoji Takagi, *Okayama Red Cross General Hospital*

Takayoshi Miyake, *Okayama Red Cross General Hospital*

Takayuki Muraoka, *Okayama Red Cross General Hospital*

Keitaro Watanabe, *Okayama Red Cross General Hospital*

Ryuji Hirai, *Okayama Red Cross General Hospital*

Shigeharu Moriyama, *Okayama Red Cross General Hospital*

Sugato Nawa, *Okayama Red Cross General Hospital*

Tadayoshi Kunitomo, *Okayama Red Cross General Hospital*

Hisashi Tsuji, *Okayama Red Cross General Hospital*

Multiple gastrointestinal stromal tumors in neurofibromatosis type 1 treated with laparoscopic surgery*

Kazunori Tsukuda, Eiji Ikeda, Shoji Takagi, Takayoshi Miyake, Takayuki Muraoka, Keitaro Watanabe, Ryuji Hirai, Shigeharu Moriyama, Sugato Nawa, Tadayoshi Kunitomo, and Hisashi Tsuji

Abstract

Gastrointestinal stromal tumors (GISTs) have been reported to occasionally occur in patients with neurofibromatosis type 1 (NF-1), and many cases have had multiple lesions predominantly involving the small intestine. We report herein a case of multiple GISTs associated with NF-1 from whom laparoscopic surgery was beneficial. In a 79-year-old female admitted with anemia and melena, the abdominal computed tomography revealed a tumor arising from the small intestine. Laparoscopic surgery was performed, and another small tumor was revealed during laparoscopic observation. Extracorporeal partial and wedge resection of the small intestine were undertaken. Both lesions were diagnosed as typical GISTs of low risk. Laparoscopic surgery would be useful for examination and a minimally invasive approach to tumors of the small intestine, especially on cases with the possibility of multiple tumors.

KEYWORDS: gastrointestinal stromal tumor, neurofibromatosis type 1, laparoscopic surgery

*PMID: 17332842 [PubMed - in process]

Case Report

Multiple Gastrointestinal Stromal Tumors in Neurofibromatosis Type 1 Treated with Laparoscopic SurgeryKazunori Tsukuda^{a*}, Eiji Ikeda^a, Shoji Takagi^a, Takayoshi Miyake^b,
Takayuki Muraoka^a, Keitaro Watanabe^a, Ryuji Hirai^a, Shigeharu Moriyama^a,
Sugato Nawa^a, Tadayoshi Kunitomo^b, and Hisashi Tsuji^a*Departments of ^aSurgery and ^bPathology, Okayama Red Cross General Hospital, Okayama 700-8607, Japan*

Gastrointestinal stromal tumors (GISTs) have been reported to occasionally occur in patients with neurofibromatosis type 1 (NF-1), and many cases have had multiple lesions predominantly involving the small intestine. We report herein a case of multiple GISTs associated with NF-1 from whom laparoscopic surgery was beneficial. In a 79-year-old female admitted with anemia and melena, the abdominal computed tomography revealed a tumor arising from the small intestine. Laparoscopic surgery was performed, and another small tumor was revealed during laparoscopic observation. Extracorporeal partial and wedge resection of the small intestine were undertaken. Both lesions were diagnosed as typical GISTs of low risk. Laparoscopic surgery would be useful for examination and a minimally invasive approach to tumors of the small intestine, especially on cases with the possibility of multiple tumors.

Key words: gastrointestinal stromal tumor, neurofibromatosis type 1, laparoscopic surgery

Gastrointestinal stromal tumors (GISTs) are mesenchymal tumors of the gastrointestinal tract arising from the Cajal's cells expressing c-kit [1]. GISTs commonly occur sporadically but have been reported to occur with increased tendency in patients with neurofibromatosis type 1 (NF-1). NF-1, also known as von Recklinghausen disease, is one of the most common human single gene disorders, affecting at least 1 million persons throughout the world. It encompasses a spectrum of multifaceted disorders and may present with a wide range of clinical manifestations, including abnormalities of the skin, nervous tissue, bones, and soft tissues. The clinicopathologi-

cal characteristics of GISTs in NF-1 are different from those of sporadic cases; most cases show multiple GISTs predominantly involving the small intestine, and mutations of *c-kit* or *platelet-derived growth factor receptor A (PDGFRA)* are rare [2-7]. Those multiple tumors are sometimes problematic for surgical treatments.

Laparoscopic surgery is a minimally invasive approach to common surgical problems in the abdomen that results in much less surgical trauma and postoperative pain. Another advantage of laparoscopic surgery is providing a magnified view of the patient's internal organs on a television monitor, which helps with precise observation of the whole abdominal cavity. We present herein a case of multiple GISTs of the small intestine in which laparoscopic surgery was useful for examination and treat-

Received August 21, 2006; accepted October 24, 2006.

*Corresponding author. Phone: +81-86-222-8811; Fax: +81-86-222-8841
E-mail: kazu.tsukuda@nifty.com (K. Tsukuda)

ment.

Case Report

A 79-year-old female patient, with known NF-1, felt general fatigue and consulted a physician. Severe anemia and melena were found and the patient was referred to our institution for the exploration of gastrointestinal bleeding. The patient presented café-au-lait spots over her whole body, but no abdominal mass or tenderness was noted. Laboratory analysis showed severe anemia with a hemoglobin count of 4.8 g/dl (Table 1). Upper gastroendoscopic and colonoscopic examinations were negative. Computed tomography revealed a round, approximately 3.0 cm × 2.5 cm, lower abdominal mass that seemed to arise from the small intestine (Fig. 1). The tumor was suspected to be a GIST and the cause of gastro-

intestinal bleeding. After blood transfusion, laparoscopic surgery was undertaken.

A laparoscope was inserted through a 10-mm canula on the left side of the navel. Two additional 5-mm side ports were inserted to manipulate the intestine. Laparoscopy clearly located the main tumor protruding from the ileum and showed another 5 mm × 4 mm tumor of the terminal ileum (Fig. 2). There was no sign of peritoneal dissemination. By lengthening the canula incision, extracorporeal partial and wedge resection of small intestine were undertaken. The main tumor had ulcer formation on the mucosa (Fig. 3). Upon histological examination, both lesions were diagnosed as typical GISTs, with

Table 1 Preoperative data of blood test

WBC	6900 /mm ³	LDH	194 IU/l
RBC	216 × 10 ⁴ /mm ³	γ-GTP	9 U/l
Hb	4.8 g/dl	T.Bil	0.2 mg/dl
Ht	16.4 %	BUN	20.9 mg/dl
Plt	33.0 × 10 ⁴ /mm ³	Cr	0.58 mg/dl
T.P	5.8 g/dl	Na	137 mEq/l
Alb	3.6 g/dl	K	4.4 mEq/l
AST	18 IU/l	Cl	105 mEq/l
ALT	9 IU/l	CEA	0.9 ng/ml
CRP	0.3 mg/dl	CA19-9	3 U/dl
ALP	240 IU/l		

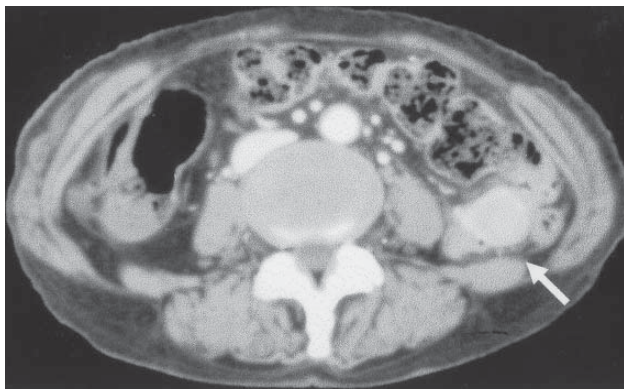


Fig. 1 The contrast-enhanced computed tomography revealed a lower abdominal tumor arising from the small intestine (arrow).

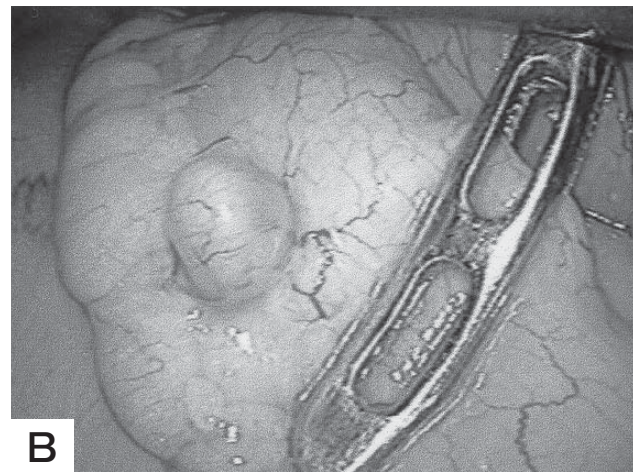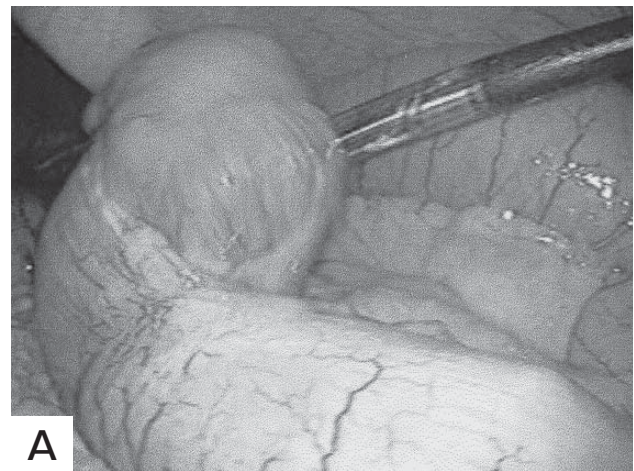


Fig. 2 **A**, Laparoscopic view of the main tumor, which protrudes from the ileum; **B**, Laparoscopic view of a smaller tumor of the terminal ileum.

a low risk of malignancy and CD117 (*c-kit*)- and CD34-positive. The patient had an uneventful postoperative course and was discharged on the 12th day following the surgery. No adjuvant treatment was performed, and there had been no evidence of recurrence at 1 year.

Discussion

Laparoscopic surgery is a minimally invasive approach to abdominal problems, including cancers, obesity, functional diseases of the gut, and parietal defects, carried out through small openings while watching the internal organs on a television monitor. Less surgical trauma results in less postoperative pain, a shorter hospital stay, a faster return to a solid food diet, and a quicker return of bowel function. Another advantage of laparoscopic surgery is providing a magnified view of the patient's internal organs, which allows better visualization of the operative site for more precise work [8]. Nguyen *et al.* have attempted laparoscopic surgery for GISTs, and most tumors were successfully removed laparoscopically with intracorporeal or extracorporeal anastomoses [9]. In their study, the conversion to open surgery was associated with coincidental pathology in addition to the GIST. Recent consensus reports have stated that GISTs are of uncertain malignant potential, and that all tumors should be resected despite an uncertain diagnosis. Therefore, laparoscopic sur-

gery is advantageous for observation and treatment for tumors in the small intestine. However, laparoscopic procedures also have several limitations. The surgeon should be careful not to destroy the capsule of the GIST because destruction of GIST may cause peritoneal dissemination. It is important to hold the adjacent normal intestine but to avoid directly holding the tumor with laparoscopic devices. The limited observation of stomach and colon, especially their posterior walls, may explain why multiple lesions are sometimes overlooked. We chose laparoscopic surgery in the present case because the patient had undergone upper gastroendoscopic and colonoscopic examinations, and the issue of limited observation also exists in open surgery.

¹⁸F-Fluorodeoxyglucose (FDG)-positron emission tomography (PET) is a useful technique for assessing GIST, and the FDG uptake is considered to predict the malignant potential of GIST because of the correlation between FDG uptake and both the Ki67 index and the mitotic index [10]. In addition, combined PET and CT offers several advantages over PET alone, and the use of this technique has spread widely over the past few years [11]. Some studies have described PET/CT imaging of GISTs [12]. The sensitivity has been found to be 93% for CT and 86% for PET for the diagnosis of GIST, and a false negative on PET scan appears to be related to small lesions. The minimum lesion detected has been reported to be 0.4 cm, which is almost the same size as our smaller tumor. PET/CT is often used to monitor the response to imatinib with malignant GIST, but our case also appeared to be a good candidate for follow-up with PET/CT scan, because the patients with NF-1 tend to have multiple GISTs.

The phenotypic and genotypic characteristics of GIST in NF-1 patients have been described recently. A great majority of tumors occur in the jejunum or ileum, and most cases are multi-focus. Though most tumors are stained for CD117 and CD34 and are morphologically indistinguishable from sporadic GISTs, few GISTs with NF-1 have a *c-kit* mutation or *PDGFRA* mutation, which is typically seen in sporadic GISTs [2-6, 13, 14]. These characteristics indicate that GISTs in NF-1 patients have a different pathogenesis than sporadic GISTs. The genetic disorder of NF-1 is a germline mutations of *NF1* which encodes neurofibromin and functions as a negative

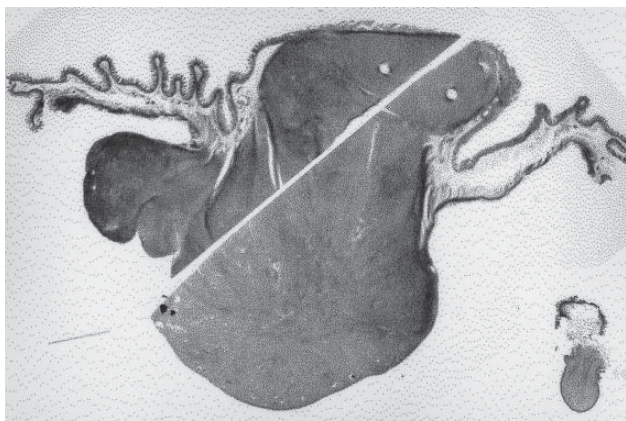


Fig. 3 Macroscopic appearances of large intestinal GIST involving the intestinal wall and small GIST protruding to the serosa.

regulator of Ras activity. Additional somatic inactivation of the wild-type *NF1* allele has recently been shown in GISTs; the homozygous inactivation of *NF1* may therefore favor GIST formation [15]. Because of these genetic disorders, patients with NF-1 are estimated to develop GISTs at a rate at least 45 times greater than sporadic cases, but most GIST patients with NF-1 have revealed a good prognosis with long-term follow up [2].

In conclusion, we have described a NF-1 patient with multiple GISTs for whom laparoscopic surgery was useful for finding another small lesion. Laparoscopic surgery appears to be useful for examination and a minimally invasive approach to tumors of the small intestine, especially in cases with the possibility of multiple tumors.

References

1. Fletcher CD, Berman JJ, Corless C, Gorstein F, Lasota J, Longley BJ, Miettinen M, O'Leary TJ, Remotti H, Rubin BP, Shmookler B, Sobin LH and Weiss SW: Diagnosis of gastrointestinal stromal tumors: a consensus approach. *Hum Pathol* (2002) 33: 459-465.
2. Miettinen M, Fetsch JF, Sobin LH and Lasota J: Gastrointestinal stromal tumors in patients with neurofibromatosis 1. *Am J Surg Pathol* (2006) 30: 90-96.
3. Takazawa Y, Sakurai S, Sakuma Y, Ikeda T, Yamaguchi J, Hashizume Y, Yokoyama S, Motegi A and Fukayama M: Gastrointestinal stromal tumors of neurofibromatosis type I (von Recklinghausen's disease). *Am J Surg Pathol* (2005) 29: 755-763.
4. Kinoshita K, Hirota S, Isozaki K, Ohashi A, Nishida T, Kitamura Y, Shinomura Y and Matsuzawa Y: Absence of c-kit gene mutations in gastrointestinal stromal tumours from neurofibromatosis type 1 patients. *J Pathol* (2004) 202: 80-85.
5. Yantiss RK, Rosenberg AE, Sarran L, Besmer P and Antonescu CR: Multiple gastrointestinal stromal tumors in type I neurofibromatosis: a pathologic and molecular study. *Mod Pathol* (2005) 18: 475-484.
6. Andersson J, Sihto H, Meis-Kindblom JM, Joensuu H, Nupponen N and Kindblom G: NF1-associated gastrointestinal stromal tumors have unique clinical, phenotypic, and genotypic characteristics. *Am J Surg Pathol* (2005) 29: 1170-1176.
7. Maertens O, Prenen H, Debiec-Rychter M, Wozniak A, Sciot R, Pauwels P, De Wever I, Vermeesch JR, de Raedt T, De Paepe A, Speleman F, van Oosterom A, Messiaen L and Legius E: Molecular pathogenesis of multiple gastrointestinal stromal tumors in NF1 patients. *Hum Mol Genet* (2006) 15: 1015-1023.
8. Cueto J, Vazquez-Frias JA, Castaneda-Leeder P, Baquera-Heredia J and Weber-Sanchez A: Laparoscopic-assisted resection of a bleeding gastrointestinal stromal tumor. *JLS* (1999) 3: 225-228.
9. Nguyen SQ, Divino CM, Wang JL and Dikman SH: Laparoscopic management of gastrointestinal stromal tumors. *Surg Endosc* (2006) 20: 713-716.
10. Kamiyama Y, Aihara R, Nakayayashi T, Mochiki E, Asao T, Kuwano H, Oriuchi N and Endo K: 18F-fluorodeoxyglucose positron emission tomography: useful technique for predicting malignant potential of gastrointestinal stromal tumors. *World J Surg* (2005) 29: 1429-1435.
11. Rosenbaum SJ, Stergar H, Antoch G, Veit P, Bockisch A and Kuhl H: Staging and follow-up of gastrointestinal tumors with PET/CT. *Abdom Imaging* (2006) 31: 25-35.
12. Gayed I, Vu T, Iyer R, Johnson M, Macapinlac H, Swanston N and Podoloff D: The role of 18F-FDG PET in staging and early prediction of response to therapy of recurrent gastrointestinal stromal tumors. *J Nucl Med* (2004) 45: 17-21.
13. Corless CL, Fletcher JA and Heinrich MC: Biology of gastrointestinal stromal tumors. *J Clin Oncol* (2004) 22: 3813-3825.
14. Shinomura Y, Kinoshita K, Tsutsui S and Hirota S: Pathophysiology, diagnosis, and treatment of gastrointestinal stromal tumors. *J Gastroenterol* (2005) 40: 775-780.
15. Maertens O, Prenen H, Debiec-Rychter M, Wozniak A, Sciot R, Pauwels P, De Weber I, Vermeesch JR, de Raedt T, DePaepe A, Speleman F, van Oosterom A, Messiaen L and Legius E: Molecular pathogenesis of multiple gastrointestinal stromal tumors in NF1 patients. *Hum Mol Genet* (2006) 15: 1015-1023.