

Acta Medica Okayama

Volume 61, Issue 5

2007

Article 8

OCTOBER 2007

Vogt-Koyanagi-Harada Syndrome in Two Patients with Immunoglobulin A Nephropathy

Toshihiko Matsuo*

Ikuya Masuda[†]

Kosuke Ota[‡]

Ichiro Yamadori**

Reiko Sunami^{††}

Soichiro Nose^{‡‡}

*Okayama University,

[†]Okayama University,

[‡]National Hospital Organization Okayama Medical Center,

**National Hospital Organization Okayama Medical Center,

^{††}Okayama Saiseikai Hospital,

^{‡‡}Okayama Saiseikai Hospital,

Vogt-Koyanagi-Harada Syndrome in Two Patients with Immunoglobulin A Nephropathy*

Toshihiko Matsuo, Ikuya Masuda, Kosuke Ota, Ichiro Yamadori, Reiko Sunami, and Soichiro Nose

Abstract

We describe herein 2 patients who developed Vogt-Koyanagi-Harada syndrome in the course of renal biopsy-proven immunoglobulin A (IgA) nephropathy. A 61-year-old man with an 11-year history of IgA nephropathy and a 16-year history of thyroiditis, and a 56-year-old man with a 5-year history of IgA nephropathy developed Vogt-Koyanagi-Harada syndrome. At the time of the eye disease presentation, IgA nephropathy was stable without corticosteroids in both patients. Vogt-Koyanagi-Harada syndrome was successfully treated with intravenous administration of prednisolone tapered from 200 mg daily. Vogt-Koyanagi-Harada syndrome is associated with IgA nephropathy, suggesting a similar autoimmune mechanism for both diseases.

KEYWORDS: immunoglobulin A (IgA) nephropathy, Vogt-Koyanagi-Harada syndrome (disease)

Case Report

Vogt-Koyanagi-Harada Syndrome in Two Patients with Immunoglobulin A Nephropathy

Toshihiko Matsuo^{a*}, Ikuya Masuda^a, Kosuke Ota^b,
Ichiro Yamadori^c, Reiko Sunami^d, and Soichiro Nose^e

^aDepartment of Ophthalmology, Okayama University Graduate School of Medicine,
Dentistry and Pharmaceutical Sciences, Okayama 700-8558, Japan,

^bNephrology and ^cPathology, National Hospital Organization
Okayama Medical Center, Okayama 701-1192, Japan, and

^dNephrology and ^ePathology, Okayama Saiseikai Hospital, Okayama 700-8511, Japan

We describe herein 2 patients who developed Vogt-Koyanagi-Harada syndrome in the course of renal biopsy-proven immunoglobulin A (IgA) nephropathy. A 61-year-old man with an 11-year history of IgA nephropathy and a 16-year history of thyroiditis, and a 56-year-old man with a 5-year history of IgA nephropathy developed Vogt-Koyanagi-Harada syndrome. At the time of the eye disease presentation, IgA nephropathy was stable without corticosteroids in both patients. Vogt-Koyanagi-Harada syndrome was successfully treated with intravenous administration of prednisolone tapered from 200 mg daily. Vogt-Koyanagi-Harada syndrome is associated with IgA nephropathy, suggesting a similar autoimmune mechanism for both diseases.

Key words: immunoglobulin A (IgA) nephropathy, Vogt-Koyanagi-Harada syndrome (disease)

Vogt-Koyanagi-Harada syndrome is a bilateral, diffuse granulomatous uveitis associated with poliosis, vitiligo, alopecia, and central nervous system and auditory signs [1]. Autoimmune mechanisms, probably directed against melanocytes, are considered to underlie the inflammation [1]. Idiopathic immunoglobulin A (IgA) nephropathy is the most common glomerulonephritis and is characterized by the varying extent of mesangial proliferation and mesangial immune complex deposition, consisting of IgA as the predominant or codominant immunoglobulin type [2]. We encountered 2 patients who developed Vogt-

Koyanagi-Harada syndrome in the long course of IgA nephropathy.

Case Reports

Case 1. A 61-year-old man noticed blurred vision and eye pain in both eyes, together with headache, occurring for the past few months. The best-corrected visual acuity was 0.6 in the right eye and 1.0 in the left eye. He showed 2+ aqueous cells, 1+ fine keratic precipitates, and hyperemic, swollen optic discs in both eyes (Fig. 1). The fundi of both eyes appeared depigmented, characteristic of Vogt-Koyanagi-Harada syndrome (Fig. 1). Fluorescein angiography disclosed marked leakage from the optic discs as well as dotted leakage points from the retinal

Received March 5, 2007; accepted May 14, 2007.

*Corresponding author. Phone: +81-86-235-7297; Fax: +81-86-222-5059
E-mail: matsuo@cc.okayama-u.ac.jp (T. Matsuo)

pigment epithelium in the posterior pole of both eyes (Fig. 1).

The patient had been diagnosed with IgA nephropathy by renal biopsy 11 years previously at another hospital (Fig. 2). Dominant IgA deposition was found

in the mesangium by immunohistochemistry, and electron dense deposits were observed in the mesangial and paramesangial areas by electron microscopy. Based on low activity of IgA nephropathy, he had been followed without treatment and had been showing

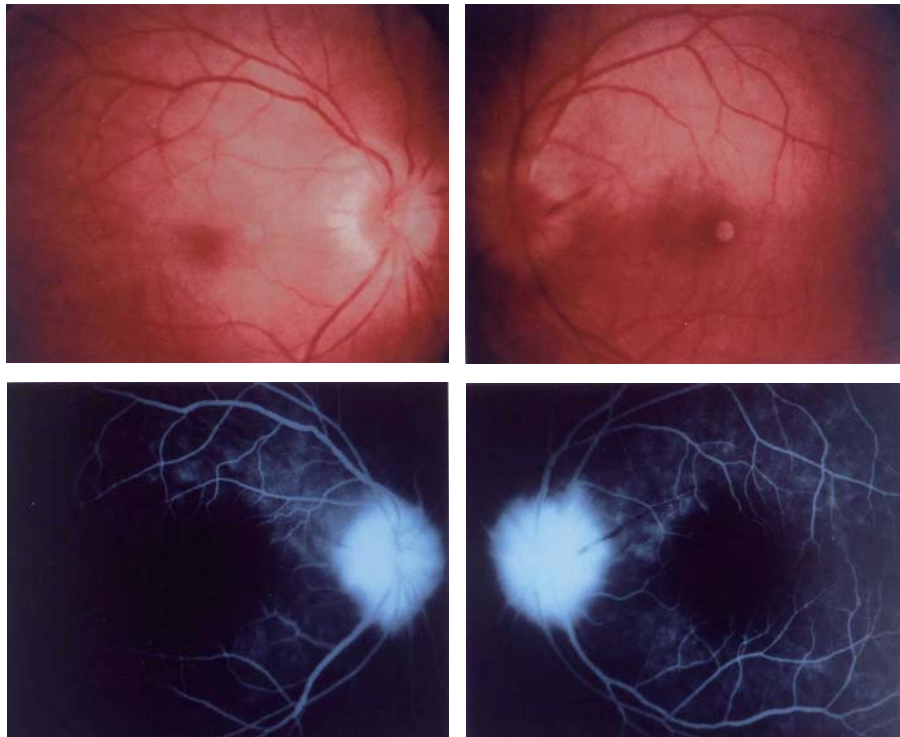


Fig. 1 Case 1, a 61-year-old man, as presented a few months after the onset of eye symptoms. Fundus photographs (top) and fluorescein angiograms (bottom) in the late phase. The right eye (left column) and the left eye (right column). Both fundi appear depigmented, and angiograms show dye leakage from the optic discs as well as multiple weak leakage points from the retinal pigment epithelium, characteristic of Vogt-Koyanagi-Harada syndrome in the chronic stage.

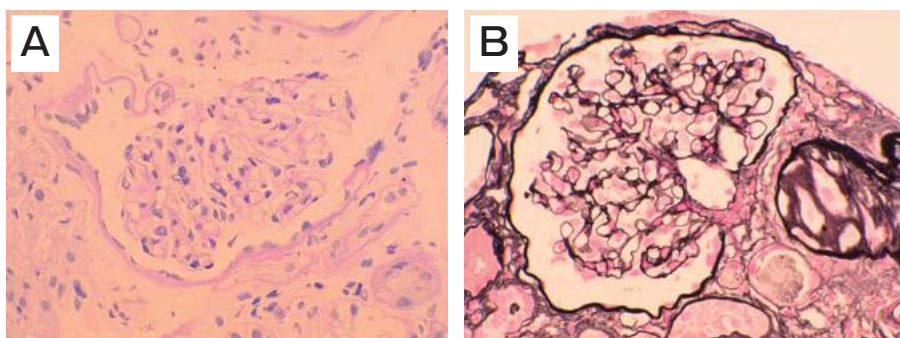


Fig. 2 Case 1. Photomicrographs of glomerular specimens obtained by renal biopsy 11 years before the onset of Vogt-Koyanagi-Harada disease. Periodic acid Schiff (PAS) stain (**A**) and Periodic acid-methenamine-silver (PAM) stain (**B**), showing low-grade mesangial cell proliferation. Immunohistochemistry showed dominant IgA deposition in the mesangium (data not shown).

a low level of proteinuria and an elevation of serum creatinine at 1.2–1.7 mg/dL. At the time of the eye disease, blood urea nitrogen was 24 mg/dL and serum creatinine was 1.56 mg/dL. Hyperthyroidism had been diagnosed 16 years previously and had been controlled well with propylthiouracil 50 mg daily. The patient had also suffered from temporal arteritis 1 year previously and treated with prednisolone tapered from 60 mg daily.

Intravenous administration of prednisolone 200 mg daily for 3 days was followed by its tapering to 150 mg daily, 100 mg daily, 80 mg daily, and 60 mg daily, each for 3 days; the patient was then switched to oral prednisolone 30 mg daily, which was then tapered and discontinued over a period of half a year. The inflammation subsided and the visual acuity became 1.0 in the right eye and 1.5 in the left eye. Systemically, IgA nephropathy and hyperthyroidism were stable during this period.

Case 2. A 56-year-old man had noticed visual reduction in both eyes 2 days before examination. The best-corrected visual acuity was 0.3 in the right eye and 0.09 in the left eye. The aqueous cells and keratic precipitates were absent in both eyes. He showed serous retinal detachment with slightly hyperemic optic discs in both eyes (Fig. 3). Fluorescein angiography revealed multiple leakage points from the retinal pigment epithelial cells (Fig. 3), typical of Vogt-Koyanagi-Harada syndrome.

The patient had developed proteinuria and hematuria, and had been diagnosed with IgA nephropathy by renal biopsy 5 years previously at another hospital (Fig. 4). Since IgA nephropathy showed high activity, as evidenced by glomerular crescent formation, he underwent one course of pulse corticosteroid therapy consisting of 3 days of intravenous methylprednisolone 500 mg daily. Oral prednisolone was then tapered from 40 mg daily and discontinued over a

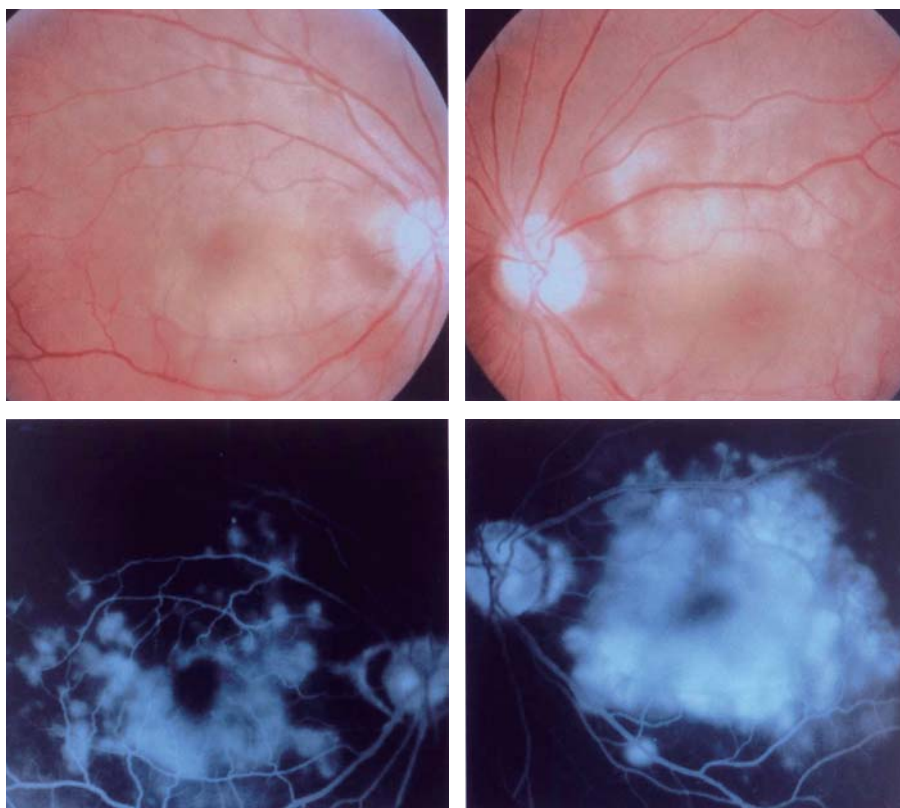


Fig. 3 Case 2, a 56-year-old man. Fundus photographs (top) and fluorescein angiograms (bottom) in the late phase. The right eye (left column) and the left eye (right column). Serous retinal detachment and multiple fluorescein leakage from the retinal pigment epithelium, typical of Vogt-Koyanagi-Harada syndrome at the early stage.

period of half a year. The patient had undergone bilateral tonsillectomy 2 years previously due to the deterioration of proteinuria. At the time of the eye disease, he showed a low level of proteinuria, and the renal function was maintained at normal levels, as evidenced from blood urea nitrogen levels of 13.1 mg/dL and serum creatinine levels of 1.03 mg/dL, without treatment.

Intravenous administration of prednisolone 200 mg daily for 3 days was followed by its tapering to 150 mg daily, 100 mg daily, 80 mg daily, and 60 mg daily, each for 3 days; the patient was then switched to oral prednisolone 30 mg daily, which was then tapered and discontinued over a period of half a year. The visual acuity returned to 1.2 in both eyes.

Discussion

In the present 2 patients, Vogt-Koyanagi-Harada disease was diagnosed based on the typical clinical

features such as bilateral uveitis with serous retinal detachment in the posterior pole, blurred and swollen optic discs, and multiple leakage points from the retinal pigment epithelium revealed by fluorescein angiography [1]. The fundi of the first patient (Case 1) appeared depigmented, and fluorescein dye leakage from the retinal pigment epithelium was weak in the chronic phase of the disease as he presented to us a few months after the onset of eye symptoms. In contrast, the second patient (Case 2) showed typical serous retinal detachment without aqueous inflammation in the early phase of the disease. Both patients showed sensorineural hearing loss in high pitch sound, also characteristic of Vogt-Koyanagi-Harada syndrome.

At the initial diagnosis of IgA nephropathy by renal biopsy, Case 1 showed low disease activity with low-grade mesangial cell proliferation, while Case 2 showed high disease activity with glomerular crescent formation. Based on these clinical characteristics,

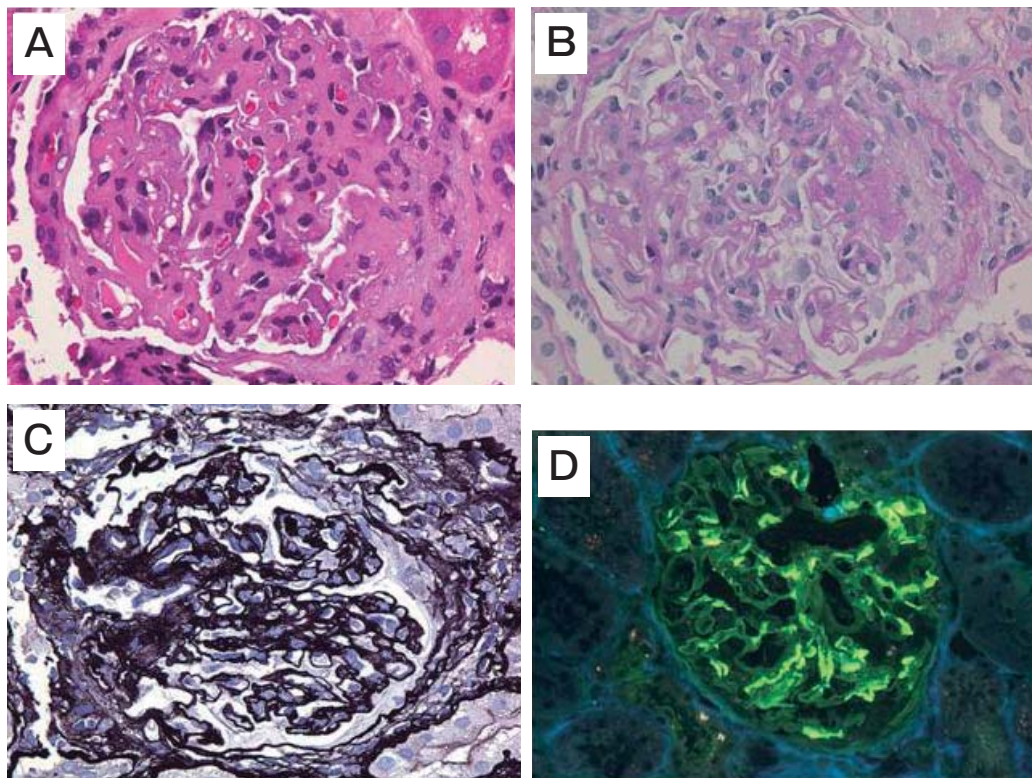


Fig. 4 Case 2. Photomicrographs of glomerular specimens obtained by renal biopsy 5 years before the onset of Vogt-Koyanagi-Harada disease. Hematoxylin-eosin (HE) stain (A), periodic acid Schiff (PAS) stain (B), periodic acid-methenamine-silver (PAM) stain (C), and immunohistochemical IgA stain (D), showing mesangial cell proliferation, glomerular loop thickening, and IgA deposition.

Case 1 was followed without treatment while Case 2 underwent pulse corticosteroid therapy with oral prednisolone tapering. IgA nephropathy was stable in both patients without corticosteroid treatment at the time of the eye disease presentation.

Both Vogt-Koyanagi-Harada syndrome and IgA nephropathy are well known to be sometimes preceded by common cold-like symptoms. Furthermore, past reports have shown that Vogt-Koyanagi-Harada syndrome develops in association with autoimmune thyroiditis [3] and that IgA nephropathy occurs in association with autoimmune thyroiditis [4]. The first patient (Case 1) in this study developed Vogt-Koyanagi-Harada syndrome in the background of IgA nephropathy and autoimmune thyroiditis, consistent with these previous case reports [3, 4].

Vogt-Koyanagi-Harada syndrome is also reported to occur in association with ulcerative colitis [5]. The association of Vogt-Koyanagi-Harada syndrome with IgA nephropathy in 2 patients of the present study raises the possibility of a common underlying immune mechanism of these 2 diseases. For instance, both diseases show immunological abnormalities and have genetic predisposition such as familial occurrence and strong association with human leukocyte antigens (HLA) [1, 6]. In marked contrast with IgA nephropathy, no histopathological or immunohistochemical study of active lesions of Vogt-Koyanagi-Harada syndrome is available because the intraocular tissue cannot be obtained by biopsy [1]. Such clinical limitations surrounding Vogt-Koyanagi-Harada syndrome hinder detailed analysis of the underlying immune mechanism. The association with IgA nephropathy might provide insight into the pathogenesis of Vogt-Koyanagi-Harada syndrome.

At present, the most common ophthalmic complication of IgA nephropathy reported thus far is scleritis [7]. To the best of our knowledge, this study is the first to show an association between IgA nephropathy and Vogt-Koyanagi-Harada syndrome. Until now, Vogt-Koyanagi-Harada syndrome has been reported to occur only in 2 patients with renal failure of unknown cause, as described in separate case reports [8, 9]. Vogt-Koyanagi-Harada syndrome might be added to the list of ophthalmic complications in patients with IgA nephropathy.

References

1. Moorthy RS, Inomata H and Rao NA: Vogt-Koyanagi-Harada syndrome. *Surv Ophthalmol* (1995) 39: 265-292.
2. Tomino Y, Sakai H and Special Study Group (IgA Nephropathy) on Progressive Glomerular Disease: Clinical guidelines for immunoglobulin A (IgA) nephropathy in Japan, second version. *Clin Exp Nephrol* (2003) 7: 93-97.
3. Wiesli P, Bernauer W and Furrer J: Headache and bilateral visual loss in a young hypothyroid Indian man. *J Endocrinol Invest* (1999) 22: 141-143.
4. Enríquez R, Sirvent AE, Amoros F, Andrada E, Cabezuelo JB and Reyes A: IgA nephropathy and autoimmune thyroiditis. *Clin Nephrol* (2002) 57: 406-407.
5. Federman DG, Kravetz JD, Ruser CB, Judson PH and Kirsner RS: Vogt-Koyanagi-Harada syndrome and ulcerative colitis. *South Med J* (2004) 97: 169-171.
6. Wada J, Sugiyama H and Makino H: Pathogenesis of IgA nephropathy. *Semin Nephrol* (2003) 23: 556-563.
7. Nomoto Y, Sakai H, Endoh M and Tomino Y: Scleritis and IgA nephropathy. *Arch Intern Med* (1980) 140: 783-785.
8. Cavalli C, Gobbi PG, Colombo R, Riccardi A, Gorini M and Ascari E: A case of scleroderma with sclerodermic renal crisis and association with the Vogt-Koyanagi-Harada syndrome. *Presse Med* (1985) 14: 1131-1134 (in French).
9. Zalts R, Hayek T, Baruch Y, Nakhoul F and Miller B: Vogt-Koyanagi-Harada syndrome associated with renal failure: a case report. *J Nephrol* (2006) 19: 225-228.