

Acta Medica Okayama

Volume 54, Issue 5

2000

Article 4

OCTOBER 2000

Fracture of the penis: treatment and complications.

Alexander Hinev*

*Varma Medical University, Us,

Copyright ©1999 OKAYAMA UNIVERSITY MEDICAL SCHOOL. All rights reserved.

Fracture of the penis: treatment and complications.*

Alexander Hinev

Abstract

Fracture of the penis is an unusual blunt traumatic injury of the erect penis. Twenty-five such cases, treated at the 2 main urological departments in the town of Varna between 1984 and 1999, were analyzed retrospectively. The average annual incidence in this series was 0.33 per 100,000 inhabitants. Most of the injuries occurred during vigorous sexual intercourse. Clinical diagnosis was mainly based on the patient's history and the physical findings. The diagnosis was verified by ultrasonography. In a few cases retrograde urethrography and cavernosography were used as additional diagnostic tools. Cavernosography was complicated by postprocedural priapism in 1 case. Unilateral tear of the corpora cavernosa was found in 24 cases. In 3 cases, partial (in 2) or complete (in 1) disruption of the corpus spongiosum and the urethra was found as well. The trauma was bilateral in 1 case in which 2/3 of the entire circumference of the penis was ruptured, including both corpora cavernosa and the urethra. Seventeen patients received immediate surgical repair. Most of them experienced an uneventful postoperative period with no serious consequences affecting their sexual function. Surgery was delayed in 6 and rejected in 2 cases. In all cases in which conservative (nonsurgical) management was the first treatment option, late complications (penile aneurysm, induration, penile curvature, erectile dysfunction) were observed and the final results were assessed as satisfactory or poor. We recommend immediate surgical treatment of all cases of penile fracture. Emergency surgical repair offers a chance for complete recovery and is the best method for providing a good functional prognosis.

KEYWORDS: penis, penile fracture, treatment, complications

*PMID: 11061570 [PubMed - indexed for MEDLINE]

Copyright (C) OKAYAMA UNIVERSITY MEDICAL SCHOOL

Fracture of the Penis: Treatment and Complications

Alexander HINEV*

Clinic of Urology, Department of Surgery, Varna Medical University, Varna 9002, Bulgaria

Fracture of the penis is an unusual blunt traumatic injury of the erect penis. Twenty-five such cases, treated at the 2 main urological departments in the town of Varna between 1984 and 1999, were analyzed retrospectively. The average annual incidence in this series was 0.33 per 100,000 inhabitants. Most of the injuries occurred during vigorous sexual intercourse. Clinical diagnosis was mainly based on the patient's history and the physical findings. The diagnosis was verified by ultrasonography. In a few cases retrograde urethrography and cavernosography were used as additional diagnostic tools. Cavernosography was complicated by post-procedural priapism in 1 case. Unilateral tear of the corpora cavernosa was found in 24 cases. In 3 cases, partial (in 2) or complete (in 1) disruption of the corpus spongiosum and the urethra was found as well. The trauma was bilateral in 1 case in which 2/3 of the entire circumference of the penis was ruptured, including both corpora cavernosa and the urethra. Seventeen patients received immediate surgical repair. Most of them experienced an uneventful postoperative period with no serious consequences affecting their sexual function. Surgery was delayed in 6 and rejected in 2 cases. In all cases in which conservative (nonsurgical) management was the first treatment option, late complications (penile aneurysm, induration, penile curvature, erectile dysfunction) were observed and the final results were assessed as satisfactory or poor. We recommend immediate surgical treatment of all cases of penile fracture. Emergency surgical repair offers a chance for complete recovery and is the best method for providing a good functional prognosis.

Key words: penis, penile fracture, treatment, complications

Fracture of the penis is a blunt traumatic injury of the erect penis, which results in a tear of the *tunica albuginea* of the *corpora cavernosa*, occasionally complicated by rupture of *corpus spongiosum* and the urethra. This is a rare and probably under-reported entity. Until 1982, a total of 93 such cases have been reported in the English literature, and in the Japanese literature 231 such cases have been reported (1, 2). A few new cases have been reported since 1982. In general, quite a limited number of patients from various institutions and countries have been discussed in the literature (3-12). Six cases from our hospital were reported in 1990 (7).

The present retrospective study was conducted with the aim of determining the outcome of the accepted treatment strategy of a number of cases of penile fracture that were diagnosed and treated during the last 15 years (1984-1999) at the 2 main urological institutions situated in the town of Varna, Bulgaria (the Clinic of Urology at Varna University Hospital and the Urologic Ward at Varna Military Hospital).

Subjects and Methods

The medical records of all patients with blunt traumatic penile injuries who had been registered at the urologic departments of the abovementioned medical institutions between September 1, 1984 and September 1, 1999 were retrospectively reviewed. A total of 32 cases of acute penile pain and a growing subcutaneous penile hematoma were identified and analyzed. Neither preoperative cavernosography nor subsequent surgical exploration successfully revealed corporeal tears in 7 of these cases. Hence, these cases were excluded from the study. The remaining 25 cases with radiologically and/or surgically confirmed rupture of the *tunica albuginea* of the *corpora cavernosa* entered the study. Twenty-two of these patients had been hospitalized at the University

* To whom correspondence should be addressed.

Hospital; two of the patients were seen at the Military Hospital and 1 patient had been treated in an outpatient setting without hospitalization. These 2 urological institutions cover a population of approximately 500,000 inhabitants. Thus, the average annual incidence of traumatic rupture of the *corpus cavernosum* in our series of patients has been calculated to be approximately 0.33 per 100,000 inhabitants. The age of the patients ranged between 17 and 76 years (mean age, 35 years). Of the patients in our series, 22/25 (88%) were less than 45 years old. Most of the patients were poorly educated and had left school at various ages after a basic grade school. Only 2 of the patients had a higher (university) education. In 18/25 of the cases (72%), the traumatic lesion had occurred during vigorous sexual intercourse. In 4/25 (16%) of the cases the wound was self-inflicted by crude manipulation of the erect penis (either during masturbation or during an attempt to alter manually the position of the rigid penis and suppress the erection). One patient (4%) reported that the trauma occurred due to a fall (from bed). Another patient fell from a bicycle and 1 patient had been kicked by a cow. The clinical symptoms did not vary greatly between subjects, who reported "a cracking sound", violent pain and rapid penile flaccidity. In addition, hematoma and recurvatum of the penis were present and reported by all patients. In 2/25 (8%) cases, bleeding from the meatus was also present. The symptoms were extreme enough to cause all of the patients to seek medical care during the very first hours after the injury. In 7/25 cases (28%), however, the patients first consulted with a physician and were then treated conservatively (nonsurgically) by the general practitioner or by a specialist (general surgeon). In these 7 cases, the period from the onset of trauma until admittance to one of the 2 institutions varied between 2 days and 2 months. One of these patients consulted a specialist on the 14th day after the trauma occurred. The patient complained of painful erections and reported an unusual swelling at the base of the intumescent penis that impeded sexual intercourse. The objective examination revealed an encapsulated hematoma that covered a small penile aneurysm (2/1 cm) just between the *pars pendula* and the *pars fixa penis*. The rupture of the *tunica albuginea* was confirmed by ultrasonography and cavernosography. This particular patient refused the proposed surgical treatment. Another similar case also involved conservative treatment for 2 months in a small regional hospital. The physical examination revealed a penile aneurysm as well. The patient's

hematoma was entirely removed surgically. The defect in the *tunica albuginea* was thus restored. No postoperative complications were observed in this case. One patient was seen for erectile dysfunction in our polyclinical consulting room 1 month after the trauma. Until he was seen in our clinic, he had been treated conservatively by his family physician. The physical examination established the presence of a massive induration at the penile base. The patient rejected surgery and was treated in an outpatient setting for a month with local applications of Hylase (in a single dose of 300 UI), combined with vitamin E (500 mg daily), prescribed *per os* for 3 months. At the check-up examination 6 months later, we found that, although still persistent, the penile induration had significantly decreased in size. The patient informed us that his sexual life had not returned to normal, but he was able to realize sexual intercourse. All of the remaining patients had been admitted to either of the 2 hospitals' emergency rooms right after diagnosis and immediately underwent surgery. A delay of the operation until the next day occurred only in 1 case because of the attending urologist's conservative approach to the malady.

In most of the cases, the clinical diagnosis was based entirely on the patient's history and on the typical physical signs. Most patients underwent surgery immediately, without any additional diagnostic procedures. In 12 cases, the diagnosis of penile fracture was verified by ultrasound. In 5 cases, the diagnosis was made after cavernosography. The ultrasound was falsely negative in 2 patients, however, cavernosography identified a rupture of the *corpus cavernosum* in all cases (Fig. 1, 2). In 1 case, the patient experienced priapism as a complication of the administration of contrast medium (20 ml Urographin 60%) into the *corpora cavernosa*. The intumescence of the penis was preserved even after the surgical exposure of the lesion and the removal of the hematoma. In this case, spongio-cavernoanastomosis was necessary. For diagnostic purposes, preoperative retrograde urethrography was performed in 2 cases in which urethral injury was suspected.

The accepted surgical approach at both urological institutions was to create a subcoronal degloving incision in the penile skin. The procedure allowed careful exploration of the urethra and corpora. The surgical repair included evacuation of the hematoma, careful hemostasis, and closure of the corporeal tear with slowly resorbable sutures. Intraoperatively, the length of the traumatic lesion of the *tunica albuginea* usually varied between 0.5

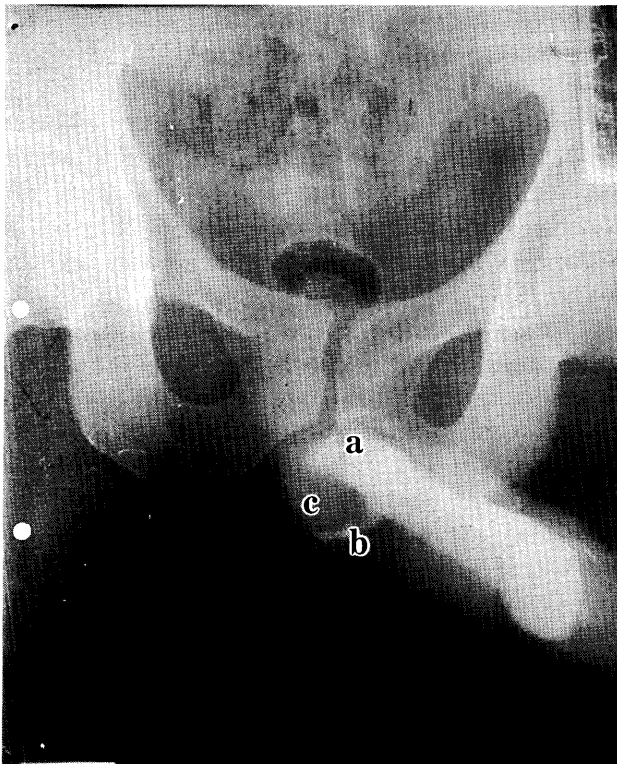


Fig. 1 Caverosogram, demonstrating the site of tear of tunica albuginea (a), the extravasation of the contrast medium (b) and the hematoma formation (c).

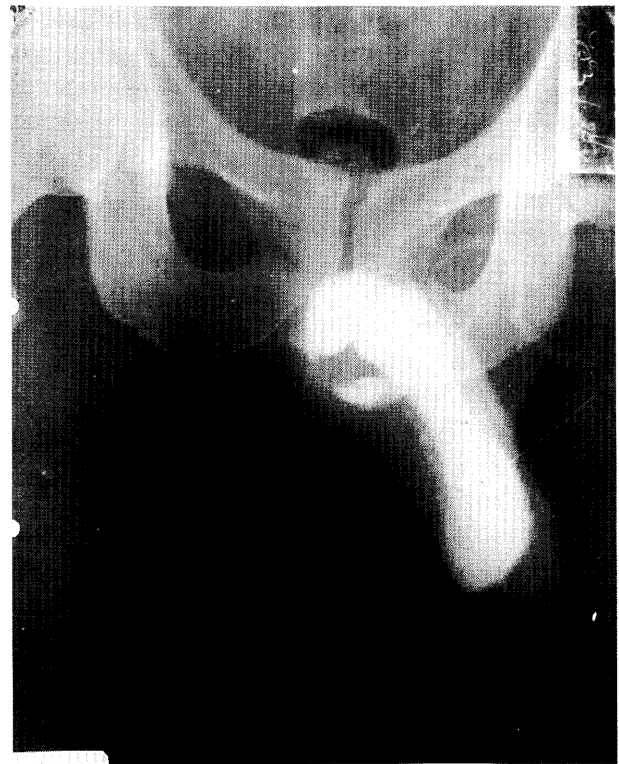


Fig. 2 Late caverosogram of the same patient.

and 2 cm (mean: 1.5 cm). In 1 case only, almost two thirds of the entire circumference of the penis was ruptured, including both the *corpora cavernosa* and the urethra. An unilateral tear of the *corpora cavernosa* was found by surgical exploration and/or caverosography in all of the remaining 24 patients (96%); (10 on the left and 14 on the right side). In 3 cases (12%), partial (in 2) or complete (in 1) disruption of the *corpus spongiosum* and the urethra was found intraoperatively. Percutaneous suprapubic drainage of the bladder, a postsurgical compressive wound dressing, and fixing the penis in a prone position usually completed the operation.

The assessment of the results included a standard physical examination as well as an inquiry about the presence of penile deformity, the quality of erections, the presence of painful erections, and about other sexual disorders. All complications were taken into account in the evaluation of the results, which were finally assessed as excellent, good, satisfactory, or poor.

Results

The hospitalization period varied from 3 to 20 days (mean: 6 days). All postoperative periods proceeded uneventfully, with no complications. Most patients were carefully followed after the operation. Only 2 patients in this series could not be found for follow up. In 22/25 (88%) of the cases, the follow up period exceeded 1 year.

In most of the patients, especially in those treated by emergency surgery, the trauma did not impede sexual activity and did not lead to any negative consequences whatsoever. Complications were observed later in 10 cases (40%): one "foreign body" granuloma at the site of the tear, which formed around the silk sutures on the *tunica albuginea* and required a second cosmetic operative procedure; slight penile curvature that did not impede sexual intercourse in 2 cases (8%); penile aneurysm in 2 cases (8%), one of which was successfully repaired surgically; permanent penile induration in 4 cases (16%), and erectile dysfunction in 3 cases (12%). Among the

latter, insufficient erections occurred in 2 cases and total erectile impotence occurred in 1 case. The long-term results were assessed as excellent in 16 cases (64%); good in 4 cases (16%); satisfactory in 4 cases (16%) and poor in 1 case (4%); (Table 1).

Discussion

Fracture of the penis is a relatively uncommon type of urologic trauma; there are less than 800 cases described in the specialized medical literature. In the present study, the traumatic lesion occurred with an annual frequency of 0.33 per 100,000 inhabitants; the cases were unequally distributed over time.

Penile fracture occurs only when the penis is erect. During erection, the *tunica albuginea* of the *corpora cavernosa* is very thin and rigid and thus is more susceptible to damage. Most penile lesions occur as a result of sexual activity, *i.e.*, "a false step" during coitus, for example, during impact of the erect penis against the female perineum or the pubic symphysis. Al Saleh *et al.* (1985) reported that most of the patients in their series

were expatriates unaccompanied by their wives (13). This factor is significant in the social etiology of this injury. Vigorous sexual intercourse caused the trauma in 72% of our cases. Although rare, lesions during masturbation or manipulation of the rigid penis, fighting, rolling over in bed, and falling out of bed are also described (3-6, 11). Single reports indicate that penile fracture may follow penile venous surgery (14) or intracavernous injection therapy (15).

Fracture of the penis occurs as an emergency with pathognomonic clinical symptoms that can be easily recognized by a physician. Data from the patient's history and from the physical examination are essential for the correct diagnosis. A sudden "cracking" or "snapping" sound is often heard and described as such by the patient. The latter is followed by violent pain, rapid detumescence and deformity of the penis on the distal side of the lesion. The latter is due to the slow progression of a hematoma, which can reach quite large dimensions. Voiding is possible if the urethra is not injured. If the urethra is damaged, urethrorrhagia (bleeding meatus) is observed as well. These symptoms are so typical of such injuries that

Table 1 Mode of treatment, late complications and final results in 25 consecutive cases of penile fracture

Case N	Treatment	Complications	Final result
1	Surgery	None	Excellent
2	Surgery	"Foreign body" granuloma	Good
3	Surgery	Slight penile curvature	Good
4	Conservative	Penile aneurism	Satisfactory
6	Surgery	None	Excellent
7	Surgery	None	Excellent
8	Surgery	None	Excellent
9	Surgery	None	Excellent
10	Surgery	None	Excellent
11	Conservative/Surgery	Penile induration	Satisfactory
12	Surgery	None	Excellent
13	Surgery	None	Excellent
14	Surgery	None	Excellent
15	Conservative/Surgery	Priapism; induration; impotence	Poor
16	Surgery	None	Excellent
17	Surgery	None	Excellent
18	Conservative/Surgery	Penile aneurism-none	Excellent
19	Surgery	None	Excellent
20	Conservative/Surgery	Partial erectile dysfunction	Satisfactory
21	Surgery	Slight penile curvature	Good
22	Surgery	None	Excellent
23	Conservative	Penile induration; partial erectile dysfunction	Satisfactory
24	Conservative/Surgery	Penile induration	Good
25	Surgery	None	Excellent

in most cases the patient can undergo surgical exploration right away, without any delay caused by additional diagnostic procedures that do not contribute much to the final diagnosis (11, 16). In obscure or atypical cases, however, additional diagnostic methods should be used.

Echotomography is the cheapest method of diagnosis and is usually available in urological departments. This method may be helpful in some cases, as it can reveal the presence of hematoma and hypoechoic areas along the *tunica albuginea* or the urethra that appear irregular. The exact site of a tear in the *tunica albuginea* can be detected by echotomography (17, 18). Using a 5 Mhz linear probe, color Doppler ultrasonography can further demonstrate the vascular disintegrity of the penis, the disruption of the arteries and cavernous veins, and the pulsation of the hematoma (19). Recently, magnetic resonance imaging (MRI) has been considered the most accurate (although the most expensive) imaging procedure. MR images can demonstrate the location and the extent of the ruptured *tunica albuginea* (16). However, this diagnostic tool is still not available in many hospitals and it thus cannot be used in cases of emergency. Preoperative cavernosography and retrograde urethrography may show additional sites of tears in the corpora and urethra because hematoma formation may mask some ruptures. However, the urologist also should be aware of a false-negative imaging study (20). Most authors consider cavernosography as the method of choice for such cases; however, this method leads to diagnostic difficulties (6, 20). The administration of contrast medium into the *corpora cavernosa* convincingly demonstrates the site of rupture of *tunica albuginea* and clearly differentiates a penile fracture from other cases. Similar symptoms can be distinguished from each other; for example, cases without a tear of the *tunica* can be recognized. In 1990 we reported 2 such cases with the same pathogenetic mechanism and similar clinical picture as those of a penile fracture, but in which the surgical exploration revealed no rupture of the *tunica albuginea* (7). However, cavernosography can be dangerous and may lead to iatrogenic priapism with poor consequences, as in the case described above. Searching the literature for such complications, we found another similar case of post-procedural priapism, reported by Gray *et al.* in 1984 (21).

Penile fracture is sometimes associated with a rupture of the urethra—either partial or complete. The latter is found in 33% of the cases reported before 1971 and in 14% of cases in the more recent papers (1). When urethral

rupture is suspected, the application of retrograde urethrography is suggested (5). This method should be applied in all suspicious cases, with or even without bleeding from the meatus, because the presence or absence of a bloody meatus may not necessarily correlate with the status of the urethra (20).

There has been quite a large amount of controversy concerning the treatment of penile fracture (1, 2, 22). In most of the earlier reports, especially those published before 1970, conservative (nonsurgical) treatment was usually recommended, including bed rest, catheterization, pressure dressing, and ice packs for 24 to 48 h. Drug treatment included the use of antibiotics, fibrinolytics (Streptokinase, Trypsin), oestrogens, and Diazepam against the erection (23, 24). The results of such management showed, however, that between 10% and 30% of the patients experienced permanent deformity, suboptimal coitus, or impaired erections (11). Kalash and Joung (1) reported even a higher (53%) percent of complications, including pseudodiverticula, penile deformity, and painful erections. The hospitalization period of patients treated conservatively ranged between 4 and 71 days (mean: 14 days). Duration of hospitalization was significantly shorter in those cases that had been explored surgically in emergency (1, 25). Nowadays most penile injuries are treated surgically. Surgery obtains better results and avoids consequences such as recurvatum of the penis or the development of fibrotic areas (6, 7, 9, 10–12). The percentage of postoperative complications is lower (about 10%) and the hospitalization period is shorter (between 1 and 14 days, mean: 3.5 days) when a surgical approach has been applied (1, 5).

Our review of 25 cases, most of which had been treated immediately upon admission with surgery, confirms this conclusion. The results were much better and the complication rate was much lower when surgical repair was performed immediately after diagnosis of the trauma. In all cases in which surgical treatment was delayed or rejected, late complications, including penile aneurysm, induration, and erectile dysfunction were observed and the final results were assessed as satisfactory or even poor. Most of these cases had either been misdiagnosed or erroneously managed by conservative procedures by other specialists (general practitioners, general surgeons). Such delays of correct diagnosis and proper treatment explain the high complication rate in our series. We recommend immediate surgical treatment of all cases of penile fracture. Emergency surgical repair offers

a chance for complete recovery, even in the presence of urethral injury, and is the best method for providing a good functional prognosis.

Acknowledgments. We would like to thank Dr. J Hadjiev, Chief of the Urologic Ward at the Military Hospital of Varna, for his significant contribution to the study, and Mrs. S Koleva for her technical assistance.

References

- Kalash SS and Young JD Jr: Fracture of penis: Controversy of surgical versus conservative treatment. *Urology* (1984) **24**, 21-24.
- Hirasawa S, Tsuboi N, Abe H, Kawamura N, Kanamori S, Okumura S, Nishimura T and Akimoto M: Fracture of the penis: Report of 10 cases and a review of 231 cases in Japan. *Hinyokika Kyo* (1983) **29**, 1047-1052.
- Asgari MA, Hosseini SY, Safarinejad MR, Samadzadeh B and Baridideh AR: Penile fractures: Evaluation, therapeutic approaches and long-term results. *J Urol* (1996) **155**, 148-149.
- Dincel C, Caskurlu T, Resim S, Bayraktar Z, Tasci AI and Sevin G: Fracture of the penis. *Int Urol Nephrol* (1998) **30**, 761-765.
- Fergany AF, Angermeier KW and Montague DK: Review of Cleveland Clinic experience with penile fracture. *Urology* (1999) **54**, 352-355.
- Karadeniz T, Topsakal M, Ariman A, Erton H and Basak D: Penile fracture: Differential diagnosis, management and outcome. *Br J Urol* (1996) **77**, 279-281.
- Khinev A, Gochev D, Ralichkova L, Denchev Kh and Ailadunov V: Fracture of the penis. *Khirurgiia* (1990) **43**, 71-74.
- Kuyumcuoglu U, Erol D, Baltaci L, Tekgul S and Ozkardes H: Traumatic rupture of corpus cavernosum. *Int Urol Nephrol* (1990) **22**, 137-140.
- Nane I, Esen T, Tellaloglu S, Selhanoglu M and Akinci M: Penile fracture: Emergency surgery for preservation of penile functions. *Andrologia* (1991) **23**, 309-311.
- Nouri M, Koutani A, Tazi K, el Khadir K, Ibn Attya A, Hachimi M and Lakrissa A: Fractures of the penis: Apropos of 56 cases. *Prog Urol* (1998) **8**, 542-547.
- Ozen HA, Erkan I, Alkibay T, Kendi S and Remzi D: Fracture of the penis and long-term results of surgical treatment. *Br J Urol* (1986) **58**, 551-552.
- Uygun MC, Gulerkaya B, Altug U, Germiyanoglu C and Erol D: 13 years' experience of penile fracture. *Scand J Urol Nephrol* (1997) **31**, 265-266.
- Al Saleh BM, Ansari ER, Al Ali IH, Tell JY and Saheb A: Fractures of the penis seen in Abu Dhabi. *J Urol* (1985) **134**, 274-275.
- Motiwala HG: Fracture of corpus cavernosum following penile venous surgery. A case report. *Int Urol Nephrol* (1994) **26**, 559-561.
- Fazeli-Matin S, Montague DK, Angermeier KW and Lakin MM: Penile fracture after intracavernous injection therapy. *J Urol* (1998) **159**, 2094.
- Fedel M, Venz S, Andreessen R, Sudhoff F and Loening SA: The value of magnetic resonance imaging in the diagnosis of suspected penile fracture with atypical clinical findings. *J Urol* (1996) **155**, 1924-1927.
- Cecchi M, Pagni GL, Ippolito C, Summonti D, Sepich CA and Fiorentini L: Fracture of the penis: Description of a case. *Arch Ital Urol Androl* (1997) **69**, 137-139.
- Koga S, Saito Y, Arakaki Y, Nakamura N, Matsuoka M, Saita H, Yoshikawa M and Ohyama C: Sonography in fracture of the penis. *Br J Urol* (1993) **72**, 228-229.
- Catala Deniz L, Rapariz Gonzalez MA, Valero Puerta J, Belon Lopez-Tomasetti JA, Martinez de la Riva SI and Aleman Flores P: Fracture of the penis: Value of echo-Doppler-color. *Arch Esp Urol* (1998) **51**, 831-834.
- Mydlo JH, Hayyeri M and Macchia RJ: Urethrography and cavernosography imaging in a small series of penile fractures: A comparison with surgical findings. *Urology* (1998) **51**, 616-619.
- Gray R, Grosman H, St Louis EL and Leekam R: The uses of corpus cavernosography. A review. *J Can Assoc Radiol* (1984) **35**, 338-342.
- Wespes E, Libert M, Simon J and Schulman CC: Fracture of the penis: Conservative versus surgical treatment. *Eur Urol* (1987) **13**, 166-168.
- Farah RN, Stiles R Jr and Cerny JC: Surgical treatment of deformity and coital difficulty in healed traumatic rupture of the corpora cavernosa. *J Urol* (1978) **120**, 118-120.
- Jallu A, Wani NA and Rashid PA: Fracture of the penis. *J Urol* (1980) **123**, 285-286.
- Palomar JM, Halikiopoulos H and Polanco E: Primary surgical repair of the fractured penis. *Ann Emerg Med* (1980) **9**, 260-261.

Received September 27, 1999; accepted April 5, 2000.