

Acta Medica Okayama

Volume 18, Issue 2

1964

Article 4

APRIL 1964

Studies on the treatment of malignant tumors with fibroblast-inhibiting agent IV. Effects of chloroquine on malignant lymphomas

Kiyoshi Hiraki*

Ikuro Kimura†

*Okayama University,

†Okayama University,

Studies on the treatment of malignant tumors with fibroblast-inhibiting agent IV. Effects of chloroquine on malignant lymphomas*

Kiyoshi Hiraki and Ikuro Kimura

Abstract

Eleven cases of malignant lymphomas were treated with a fibroblast-inhibiting agent, chloroquine, and of these, one case of lymphosarcoma, two of acute and chronic lymphocytic leukemia, respectively, and two of giant follicle lymphoma showed regression of the enlarged lymph nodes and also of the enlarged spleen in some of the splenomegalic patients. In contrast, the drug proved ineffective in two cases of reticulum cell sarcoma and Hodgkin's disease, respectively. The side effects of the drug were minimal, and three of the 11 cases complained of nausea, anorexia or palpebral ptosis, which disappeared by decreasing the drug dosage or combining ATP preparation. The tissue culture study of biopsied lymph nodes from lymphocytic leukemia showed inhibition of the growth zone in a medium containing chloroquine indicating a possibility of the drug action not only upon the stromal tissue but also upon the parenchymal tumor cell.

*PMID: 14204462 [PubMed - indexed for MEDLINE] Copyright ©OKAYAMA UNIVERSITY
MEDICAL SCHOOL

**STUDIES ON THE TREATMENT OF MALIGNANT TUMORS
WITH FIBROBLAST-INHIBITING AGENT**

**IV. EFFECTS OF CHLOROQUINE ON MALIGNANT
LYMPHOMAS**

Kiyoshi HIRAKI and Ikuro KIMURA

*Department of Internal Medicine, Okayama University Medical School,
Okayama, Japan (Director: Prof. K. Hiraki)*

Received for publication, March 23, 1964

In the preceding papers we described our unique approach to cancer chemotherapy in which a fibroblast-inhibiting agent, chloroquine, was used against various human and animal tumors with considerable therapeutic effects.^{1,2,3,4,5,6} The mechanism of the drug action appeared to be in the inhibition of the growth of stromal connective tissue leading secondarily to the damage of parenchymal tumor cells. Importance of its possible anti-inflammatory and humoral effects upon the host was also discussed.

The present experiment was initiated on a speculation that chloroquine might also be effective against malignant lymphomas having the same mesodermal origin as fibroblasts which are particularly sensitive to the drug. In this paper are presented the results of chloroquine treatment in malignant lymphomas and effects of chloroquine on biopsied lymph node cultured *in vitro*.

MATERIALS AND METHODS

A total of 11 cases of malignant lymphomas were studied and included one case of lymphosarcoma, two of acute lymphocytic leukemia, two of chronic lymphocytic leukemia, two of giant follicle lymphoma, two of reticulum cell sarcoma, and two of Hodgkin's disease.

As a fibroblast-inhibiting agent, either 250mg of chloroquine diphosphate or 200mg of chloroquine diorotate were administered slowly by an intravenous route, usually once or twice daily, and the longest duration of therapy ever attained was 14 months. Many other patients are still placed on the continued treatment.

The treatment effects were evaluated, as in carcinoma patients, according to the degrees of objective and subjective improvement and classified as effective, slightly effective and non-effective.^{3,6}

RESULTS

A 63-year-old male with a history of generalized lymphadenopathy of 3 years' duration was hospitalized in a severely ill condition with pleural effusion,

ascites and pretibial edema. As shown in the Fig. 1, there were many 2 to 5 cm lymph nodes in the right side of the neck, both axilla and groins. He had pleural effusion on the right and marked ascites. The liver was palpable 2 fingerbreadths and spleen 8 fingerbreadths down the costal margin. Enlarged mesenteric lymph nodes were also palpable around the umbilicus.

Table 1 Therapeutic effect of chloroquine on malignant lymphomas

	No. cases	Enlarged lymph node	Enlarged spleen
Lymphosarcoma	1	Regression	Regression
Acute lymphocytic leukemia	2	"	No change
Chronic lymphocytic leukemia	2	"	"
Giant follicle lymphoma	2	"	/

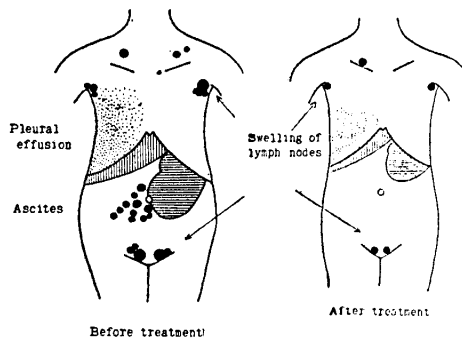


Fig. 1 Therapeutic effect of chloroquine on lymphosarcoma

Laboratory examination revealed moderate anemia, and hemorrhagic ascites with a strongly positive TPT reaction. Biopsied axillary lymph nodes showed lymphosarcoma.

He was started on 200 mg of chloroquine diorotate twice daily, and after one week the enlarged lymph nodes began to regress and after about one month they were hardly palpable. The spleen became smaller and was palpable 4 fingerbreadths below the costal margin. There was a gradual decrease of both pleural and ascitic effusions. His appetite returned and there was an increase of his body weight. After about 6 months' treatment, he was discharged to be followed in the clinic. On his return visit after 14 months of treatment, he continued to be in a satisfactory condition (Figs. 1, 2).

Histological comparison of biopsied lymph nodes indicated that before treatment there was a diffuse proliferation of lymphosarcoma cells completely obliterating the normal structure while 4 months after treatment there was a decrease of the infiltrating lymphosarcoma cells with a tendency to structural normalization.

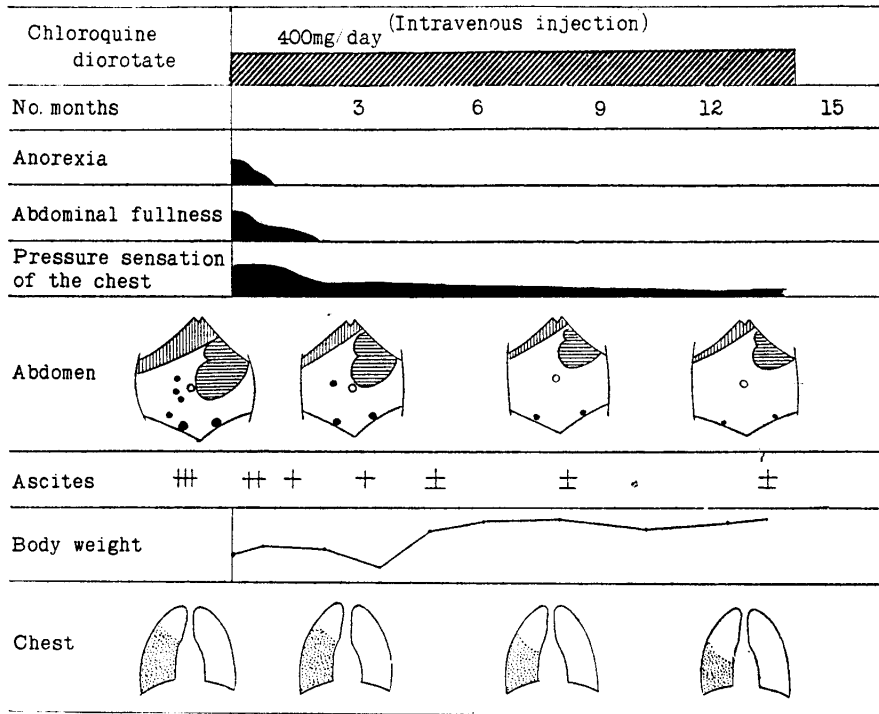


Fig. 2 Lymphosarcoma, I. S. 64y. ♂

In one patient with acute lymphocytic leukemia, enlarged cervical lymph nodes on both sides began to regress after 3-4 days of chloroquine diphosphate treatment. In the other case of acute lymphocytic leukemia, only the cervical lymph nodes became smaller after 4-5 days of treatment, but there was no response of the axillary and inguinal groups.

One case of chronic lymphocytic leukemia had a pigeon's-egg-sized mass in the right supraclavicular region which became smaller after about one week of treatment. The other case of chronic lymphocytic leukemia with bilateral cervical lymph node enlargement showed regression of the lymph node after one week of treatment. These 4 cases of lymphocytic leukemia are still under observation and none of them has thus far showed significant hematological changes.

In two cases of giant follicle lymphoma, there was generalized lymphadenopathy, which showed a distinct regression after treatment. In the first case, for instance, regression of the enlarged lymph nodes was noted after one week and in the second case after 3 weeks from the start of treatment. Both cases were discharged in a state of continued remission. A lymph node biopsy specimen from the second case after 2 months of treatment revealed only chronic inflammation, showing improvement in comparison with the pre-treatment specimen.

In two cases of reticulum cell sarcoma and Hodgkin's disease, respectively, no significant improvement was obtained by treatment, and this point is now under investigation.

The side effects of the drug were slight. Three of the 11 patients complained of nausea, anorexia or palpebral ptosis, but could continue the drug by decreasing the dosage or combining ATP preparation.

Lymph node tissue obtained from one case of acute and chronic lymphocytic leukemia was cultured using Hiraki's tissue culture slides No. 2⁷ in a medium containing chloroquine. At the chloroquine concentration of over 20%, inhibition of the growth zone was noted, more so in the chronic form than in the acute form (Figs. 3, 4).

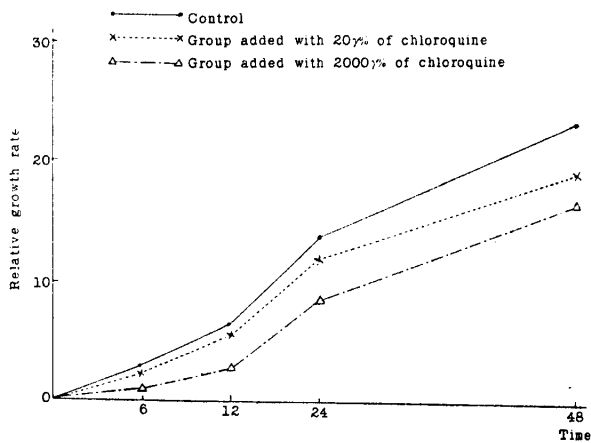


Fig. 3 Relative growth rate of leukemic cells in tissue culture of lymph node of acute lymphocytic leukemia added with chloroquine

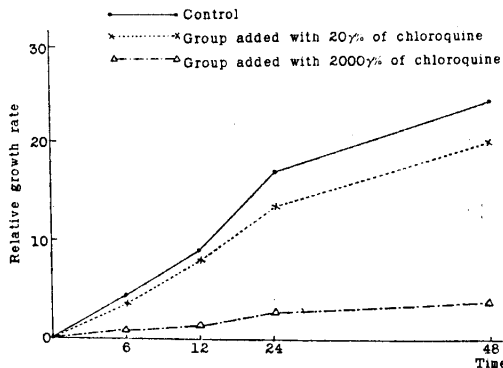


Fig. 4 Relative growth rate of leukemic cells in tissue culture of lymph node of chronic lymphocytic leukemia added with chloroquine

DISCUSSION

Having obtained favorable therapeutic effects of chloroquine in cancer patients, we have used the drug in the treatment of malignant lymphomas, and observed regression of the enlarged lymph nodes and spleen in lymphosarcoma, lymphocytic leukemia and giant follicle lymphoma.

From the fact that chloroquine exerts deleterious effects on fibroblasts, the drug was employed in the hope to induce similar effects on immature lymphoid cells having the same mesodermal origin. These predicted effects of chloroquine appear to have been substantiated by the findings of tissue culture and histological studies of biopsied lymph nodes.

Our previous study using normal rabbit bone marrow cells indicated that chloroquine exerted no influences at the concentrations of 2 and 20% , and inhibition of their growth was noted at the concentration of over 200% . On the other hand, the growth of cultured lymph node tissue from lymphocytic leukemia was found to be suppressed at the medium concentration of 20% , suggesting an excellent *in vivo* action of the drug in this disease. Serum chloroquine levels in humans after administration of 250 mg of chloroquine diphosphate varied considerably from case to case, but were between 25 and 75% 5 minutes after intravenous injection of the drug, being far below the level of 200% known to be toxic to normal bone marrow cells. Therefore, our present method of drug administration is considered to provide the effective serum levels against lymphoid cells as well as fibroblasts without doing any harm to normal bone marrow elements. In other words, the drug is working not only upon stromal fibroblasts but also upon parenchymal tumor cells.

SUMMARY

Eleven cases of malignant lymphomas were treated with a fibroblast-inhibiting agent, chloroquine, and of these, one case of lymphosarcoma, two of acute and chronic lymphocytic leukemia, respectively, and two of giant follicle lymphoma showed regression of the enlarged lymph nodes and also of the enlarged spleen in some of the splenomegalic patients. In contrast, the drug proved ineffective in two cases of reticulum cell sarcoma and Hodgkin's disease, respectively.

The side effects of the drug were minimal, and three of the 11 cases complained of nausea, anorexia or palpebral ptosis, which disappeared by decreasing the drug dosage or combining ATP preparation.

The tissue culture study of biopsied lymph nodes from lymphocytic leukemia showed inhibition of the growth zone in a medium containing chloroquine indicating a possibility of the drug action not only upon the stromal tissue but also upon the parenchymal tumor cell.

REFERENCES

1. HIRAKI, K. & KIMURA, I.: Studies on the treatment of malignant tumors with fibroblast-inhibiting agent (Report 1), *SOGORINSHO (Clinic all-round)* 11, 1807, 1962
2. HIRAKI, K. *et al.*: Studies on the treatment of malignant tumors with fibroblast-inhibiting agent (I), (II), *Proceedings of the Japanese Cancer Association (the 21st General Meeting)* 1, 2, 1962
3. HIRAKI, K. *et al.*: Studies on the treatment of malignant tumors with fibroblast-inhibiting agents. Basic and clinical studies of chloroquine derivatives (I), *Okayama-Igakkai-Zasshi*, 75, 297, 1963
4. HIRAKI, K. & KIMURA, I.: Studies on the treatment of malignant tumors with fibroblast-inhibiting agent I. Fibroblast-inhibiting action of chloroquine, *Acta Med. Okayama* 17, 231, 1963
5. HIRAKI, K. & KIMURA, I.: Studies on the treatment of malignant tumors with fibroblast-inhibiting agent II. Effects of chloroquine on animal tumors, *Acta Med. Okayama* 17, 239, 1963
6. HIRAKI, K. & KIMURA, I.: Studies on the treatment of malignant tumors with fibroblast-inhibiting agent III. Effects of chloroquine on human cancers, *Acta Med. Okayama* (in press)
7. HIRAKI, K. *et al.*: The method of tissue culture (mainly of the bone marrow) and a simple method of observing living tissue, *Acta Med. Okayama* 10, 99, 1956
8. HAYASHI, N. *et al.*: Effects of quinoline derivatives on haematopoietic function of bone marrow I. Studies on bone marrow function by clinical tissue culture method, *Acta Haem. Jap.* 26, 421, 1963