

Acta Medica Okayama

Volume 61, Issue 6

2007

Article 7

DECEMBER 2007

Vaginoplasty with an M-Shaped Perineo-Scrotal Flap in a Male-to-female Transsexual

Yuzaburo Namba* Narushi Sugiyama[†] Shuji Yamashita[‡]

Kenjiro Hasegawa** Yoshihiro Kimata^{††}

Kazushi Ishii^{‡‡} Yasutomo Nasu[§]

*Okayama University,

[†]Okayama University,

[‡]Okayama University,

**Okayama University,

^{††}Okayama University,

^{‡‡}Okayama University,

[§]Okayama University,

Vaginoplasty with an M-Shaped Perineo-Scrotal Flap in a Male-to-female Transsexual*

Yuzaburo Namba, Narushi Sugiyama, Shuji Yamashita, Kenjiro Hasegawa,
Yoshihiro Kimata, Kazushi Ishii, and Yasutomo Nasu

Abstract

To date, many techniques have been reported for vaginoplasty in male-to-female trans-sexual (MTFTS) patients, such as the use of a rectum transfer, a penile-scrotal flap and a reversed penile flap. However, none of these procedures is without its disadvantages. We developed a newly kind of flap for vaginoplasty, the M-shaped perineo-scrotal flap (M-shaped flap), using skin from both sides of the scrotum, shorn of hair by preoperative laser treatment. We applied this new type of flap in 7 MTFTS patients between January 2006 and January 2007. None of the flaps developed necrosis, and the patients could engage in sexual activity within 3 months of the operation. The M-shaped flap has numerous advantages: it can be elevated safely while retaining good vascularity, it provides for the construction of a sufficient deep vagina without a skin graft, the size of the flap is not influenced entirely by the length of the penis, and it utilizes skin from both sides of the scrotal area, which is usually excised.

KEYWORDS: vaginoplasty, male-to-female transsexual, perineo-scrotal flap

Original Article

Vaginoplasty with an M-shaped Perineo-scrotal Flap in a Male-to-female Transsexual

Yuzaburo Namba^{a*}, Narushi Sugiyama^a, Shuji Yamashita^a, Kenjiro Hasegawa^a,
Yoshihiro Kimata^a, Kazushi Ishii^b, and Yasutomo Nasu^b

*Departments of ^aPlastic and Reconstructive Surgery and ^bUrology, Okayama University Graduate School of
Medicine, Dentistry and Pharmaceutical Sciences, Okayama 700-8558 Japan*

To date, many techniques have been reported for vaginoplasty in male-to-female transsexual (MTFTS) patients, such as the use of a rectum transfer, a penile-scrotal flap and a reversed penile flap. However, none of these procedures is without its disadvantages. We developed a newly kind of flap for vaginoplasty, the M-shaped perineo-scrotal flap (M-shaped flap), using skin from both sides of the scrotum, shorn of hair by preoperative laser treatment. We applied this new type of flap in 7 MTFTS patients between January 2006 and January 2007. None of the flaps developed necrosis, and the patients could engage in sexual activity within 3 months of the operation. The M-shaped flap has numerous advantages: it can be elevated safely while retaining good vascularity, it provides for the construction of a sufficient deep vagina without a skin graft, the size of the flap is not influenced entirely by the length of the penis, and it utilizes skin from both sides of the scrotal area, which is usually excised.

Key words: vaginoplasty, male-to-female transsexual, perineo-scrotal flap

Recently, many vaginoplasties in male-to-female transsexual patients have utilized either a penile-scrotal flap or a reversed penile flap, either of which methods can result in an adequately deep vagina. However, the proximal parts of both a penile flap and a reversed penile flap are also used to cover the perineal area. Thus, in cases with a short penis, we can not obtain a sufficiently large penile flap and a skin graft has to be added to resurface the vaginal cavity. The grafted skin may become constricted and the vagina might become narrow and short as the result. Ideally, a reconstructed vagina should be fully lined

with a hairless flap without a skin graft. In our M-shaped flap vaginoplasty, the penile flap is used only to cover the perineal region, making even a small penile flap adequate; the M-shaped flap, using bilateral scrotal skin is large enough to line the entire cavity of the vagina. When a penile-scrotal flap or a reversed penile flap is employed, a dog-ear deformity always remains after the scrotal-flap labioplasty, and the deformed area is usually discarded. We have utilized the pudendal thigh flap in treatment of a congenital vaginal aplasia case. It is well known that this flap contains the posterior pudendal vessels and can be elevated safely [1-5]. We modified this flap to an M-shaped perineo-scrotal flap, which requires no skin excision, and have applied it for vaginoplasty in the treatment of male-to-female transsexual patients.

Received July 3, 2007; accepted September 5, 2007.

*Corresponding author. Phone:+81-86-235-7212; Fax:+81-86-235-7210
E-mail: y-namba@cc.okayama-u.ac.jp (Y, Namba)

This M-shaped flap also contains the posterior pudendal vessels and can be elevated safely; furthermore, it can be made hairless using several laser depilation treatments before the operation.

Patients and Methods

Case 1, 53-year-old male-to-female transsexual. The M-shaped flap was created from not only the perineal region, which was almost 9 cm wide, but also from the skin from the lower part and both sides of the scrotum (Fig. 1). The flap was shorn of hair by laser treatment prior to the operation. The oval-shaped prepuce over the glans penis was used to form the clitoris hood (Fig. 2). During elevation of the the M-shaped flap, we took extreme caution to prevent injury to the posterior scrotal vessels. We included pedicles on both sides of the M-shaped flap to ensure the survival of the flap. An incision was made at the center of the scrotum and the scrotal flaps were elevated. We left only the tunica vaginalis testis attached to the testicles; the other soft tissues remained within the scrotal flap. Then, the testicles with the spermatic cords were removed up to the level of the external inguinal ligament (Fig. 3). During elevation of the penile flap, we kept it as thick as possible to allow the circulation to be maintained, while observing caution to prevent injury to the dorsal penile neurovascular bundle. The elevated scrotal flaps were used for the construction of the labia majora on both sides, and the penile flap was used only for perineoplasty (Fig. 4). The lower tips of the scrotal flaps were pulled down

to the bases of the M-shaped flap to construct the labia majora. The dorsal penile neurovascular bundle was dissected with a part of the glans (Fig. 5). Next, the corpora cavernosa were resected to the maximum possible depth (Fig. 6). If the stump ends remain superficial, erection sometimes occurs and patients may experience pain while engaging in sexual activity. The cavity for the vagina was created in the space between the prostate and the rectum (Fig. 7). For this part of the surgery, finger dissection is considered to be the easiest and most reliable method. We introduced one index finger into the rectum and dissected with the other index finger. We constantly confirmed the thickness between the cavity and the rectum with both index fingers to ensure lack of injury to the rectum.

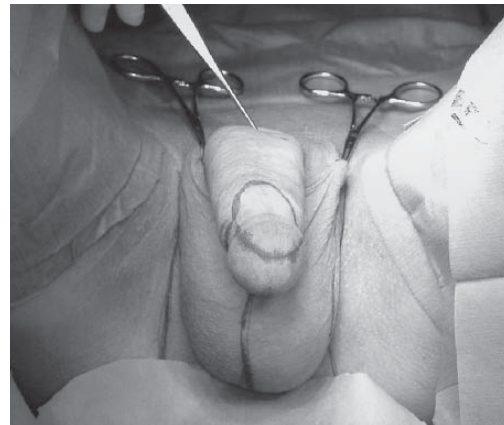


Fig. 2 Oval shape of a portion of the glans penis with overlying prepuce for clitoroplasty.

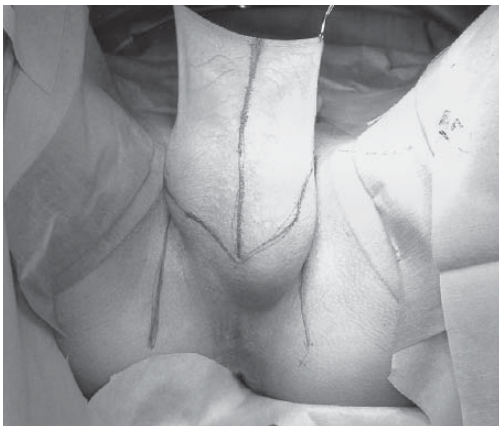


Fig. 1 Design of the M-shaped perineo-scrotal flap.

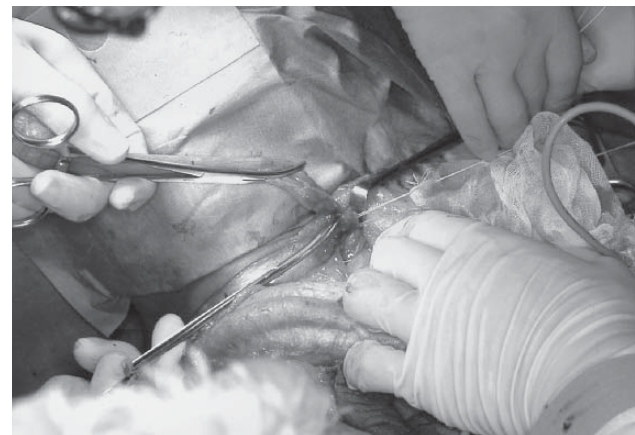


Fig. 3 Testicle and spermatic cord excision.

The depth of the cavity was over 12 cm. The edges of the M-shaped flap were sutured together to form a sac lining the vaginal cavity (Fig. 8). The top of the sac was fixed at the bottom of the cavity with 2 or 3 anchor sutures (Fig. 9). The urethra was shortened and a new meatus was formed (Fig. 10). Part of the glans penis was sutured to form the clitoris. The penile flap was pulled down and marks for the clitoris and the new meatus were drawn on it. Then, a

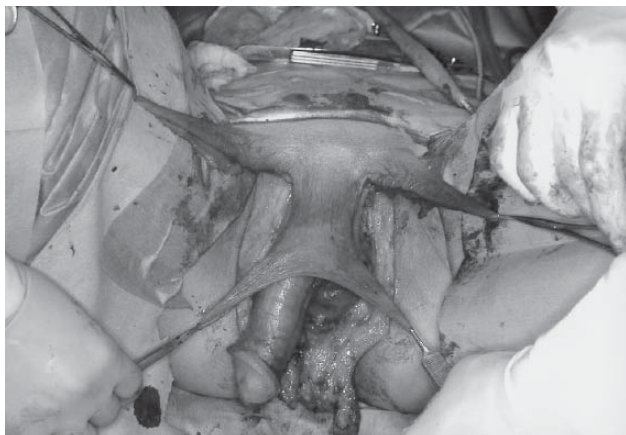


Fig. 4 Penile flap for perineum resurfacing and scrotal flap for labioplasty.

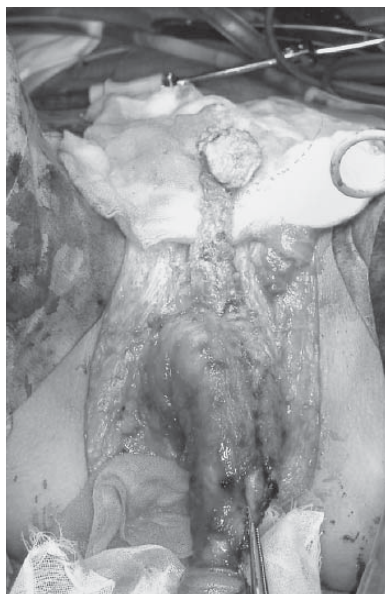

Fig. 5 A part of the glans penis with the dorsal penile neurovascular bundle.

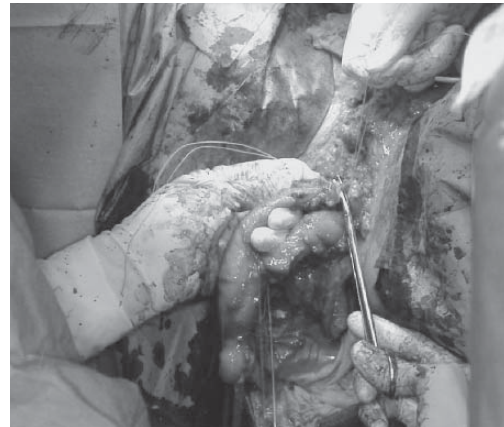


Fig. 6 Resection of the corpora cavernosa.

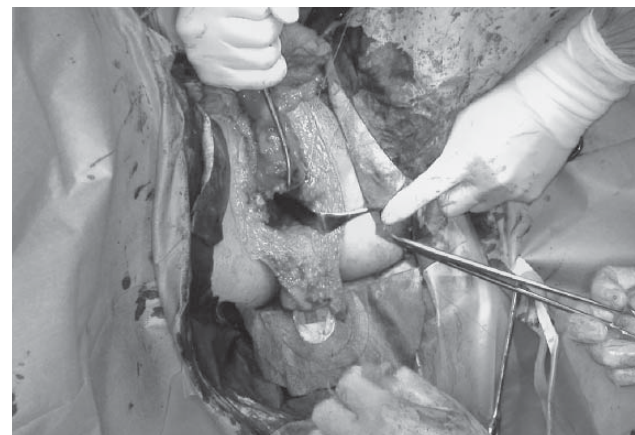

Fig. 7 Cavity formation in vaginoplasty.

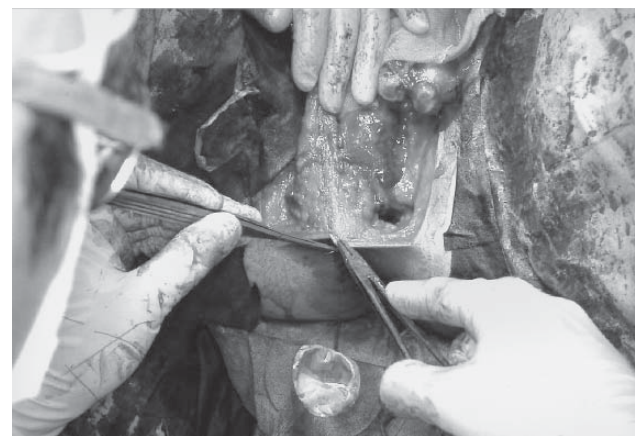

Fig. 8 Suturing together of the M-shaped flap to form a sac to line the vagina cavity.

Y-shaped incision for the clitoris and a vertical incision for the new meatus were made. The clitoris, partially covered with the penile skin hood, was pulled out and fixed beneath the pubic tuberosity, and the new urethral meatus was fixed at the center of the penile flap (Fig. 11). The scrotal flaps of both sides were fixed at the bases of the M-shaped flap and the penile flap at the superior edge of the vagina (Fig. 12). There appears to be no need to retain any implement, such as a prosthesis, in the vagina; we usually insert only isodine-soaked gauze into the cavity. The urethral catheter and the drains were removed within 5 days of the operation. Sexual activity was permitted and vaginal dilation with a dilator was started within

3 months of the operation.

Case 2, 52-year-old male-to-female transsexual. We designed an M-shaped perineo-scrotal flap for vaginoplasty (Fig. 13). An almost 12-cm long sac could be formed from the scrotum, which was of average size (Fig. 14). There was some tension at the superior edge of the vagina immediately after the operation; however, the tension resolved itself thereafter. The reconstructed vagina retained an almost 12-cm depth and an almost 3-cm diameter 1 year after the operation (Fig. 15) and the index finger could be smoothly inserted until beyond the MP joint (Fig. 16).

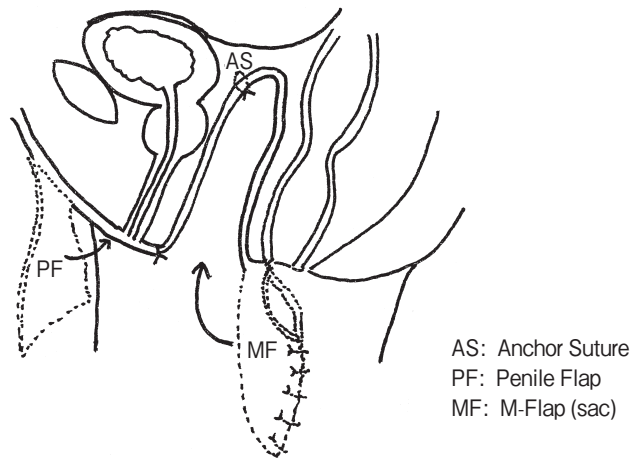


Fig. 9 Schema of vagina cavity lining.

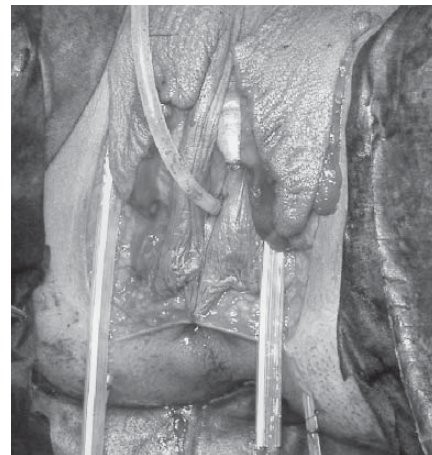

Fig. 11 Covering of the perineum with the penile flap fixed at the superior edge of the vaginal orifice.

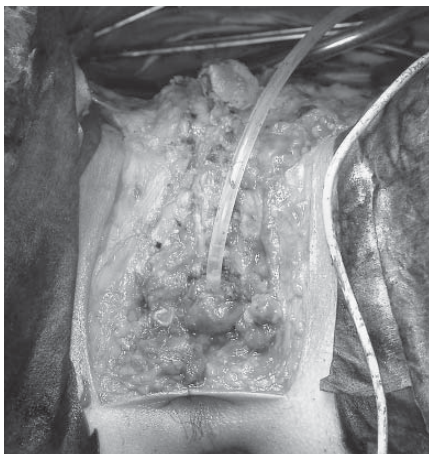


Fig. 10 Shortening of the urethra to form a new meatus.

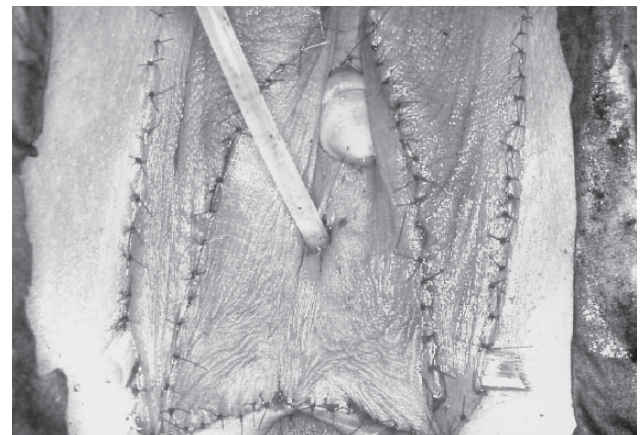


Fig. 12 Immediately after the operation.

Results

We operated on 6 MTFTS patients using the conventional penile-scrotal flap for vaginoplasty between 2001 and 2005. In this series, partial necrosis of the scrotal flap occurred in 2 cases and a rectovaginal fistula developed in 1 case. However, since

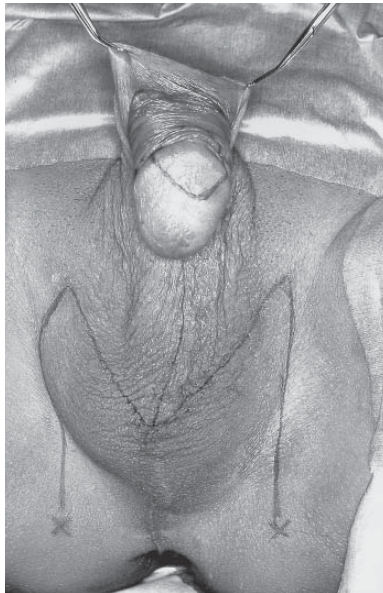

Fig. 13 Intra-operative flap design.

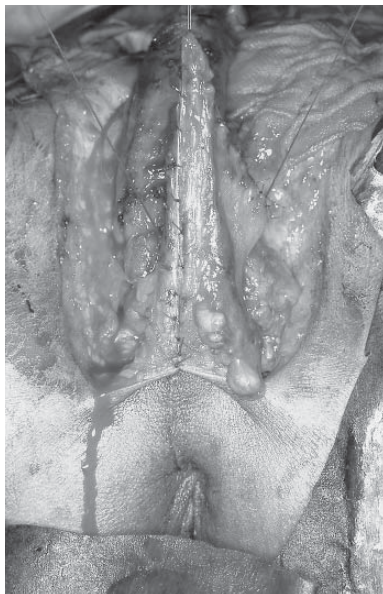

Fig. 14 Sac measuring 12-cm long for lining the vaginal cavity.

the introduction of the M-shaped flap procedure in 2006, we have operated on 7 cases and have encountered no problems such as flap necrosis in any of the 7 cases. There have been no complications such as ischuria or urethral stricture, but some patients have complained of spray-like urination. All the patients are satisfied with the results.

Discussion

Sex reassignment surgery in MTFTS patients involves 3 main procedures, namely, clitoroplasty, new urethral meatoplasty and vaginoplasty. Several designs have been proposed for formation of the clitoris from the glans penis [6–10]; however, no differences have been recognized among these from the standpoint of using the dorsal penile neurovascular bundle as the pedicle. We usually adopt an oval-shaped design, which is attached using some prepuccial skin to form a hood as some patients complain of hypersensitivity of the new clitoris in the absence of this hood. We reconstruct the new urethral meatus by simply shortening the urethra; one of the problems with this procedure, however, is that the direction of urine stream is uncertain. Therefore, we fix the urethral meatus above the orifice of the vagina by suturing it with the soft tissue. The most important aspect of vaginoplasty is the formation of a deep, pliable and hairless vagina. To date, a number of procedures have been reported for vagino-

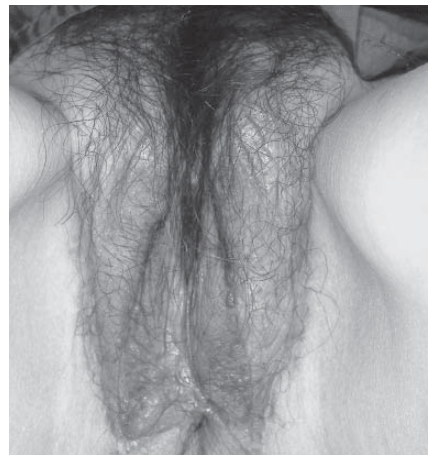

Fig. 15 One year after the operation.

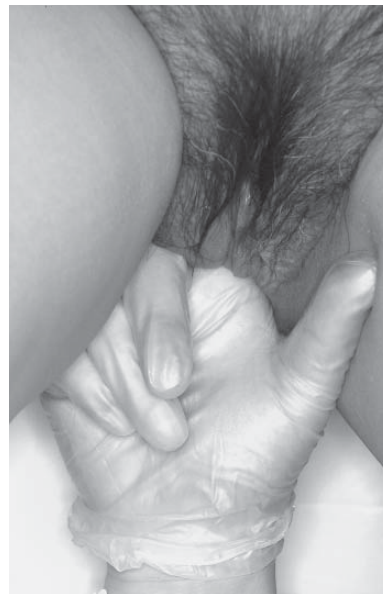

Fig. 16 Free space remaining after introduction of the index finger.

plasty in MTFTS patients, including rectum transfer [11–13] and use of a penile-scrotal flap or reversed penile flap [14–17]; each of these has disadvantages. In the case of rectum transfer, the subject may suffer from uncomfortable discharge per rectum. In the case of a penile-scrotal flap, the scrotal flap is designed from the center of the scrotum; the penile flap is used for lining the anterior surface of vagina and the scrotal flap for its posterior surface. However, it is actually difficult to use the penile flap to cover the entire anterior surface of the vagina, because the flap is used to resurface the perineum as well as to form the vagina lining. Thus, a vagina of adequate depth is difficult to obtain. If the scrotal flap is designed to be longer than usual to gain length, partial necrosis sometimes occurs. We encountered 2 such cases in our previous series. In the case of using of a reversed penile flap, the perineal triangular flap covers a part of the posterior vaginal surface and the remainder of the cavity is covered with the reversed penile flap. A skin graft is sometimes needed, especially in cases with a short penis, because a short reversed penile flap cannot be used to line the entire vagina. When a skin graft is used, the grafted skin may become constricted and the vagina might become narrow and short as the result. In the case of skin grafting, the lateral scrotal area is usually excised and used for the skin grafting. Compared to these methods, our M-shaped flap has several advantages. It has very good circulation because it contains both the posterior scrotal vessels and supplies the length of the vagina and it is not influenced entirely by the length of the penis because the penile flap is not used for vaginal reconstruction. Furthermore, it utilizes the lateral scrotal skin, which is often excised to correct dog-ear deformities. If the flap is shorn of hair by preoperative laser treatment, it is possible to get a hairless flap for reconstruction of a hairless vagina.

Conclusions. One of the most important points of sex reassignment surgery in male-to-female trans-sexual patients is to achieve the creation of a deep, hairless and pliable vagina. Conventional procedures for vaginoplasty sometimes require an additional skin graft. An M-shaped perineo-scrotal flap that is depilated by preoperative laser treatment can always provide ideal coverage for the entire cavity of the reconstructed vagina. We think the M-shaped flap is very useful, especially in the case of a shorter-than-

normal penis.

References

1. Wee JT and Joseph VT: A new technique of vaginal reconstruction using neurovascular pudendal thigh flaps: A preliminary report. *Plast Reconstr Surg* (1989) 83: 701–709.
2. Woods JE, Alter G, Meland B and Podratz K: Experience with vaginal reconstruction utilizing the modified Singapore flap. *Plast Reconstr Surg* (1992) 90: 270–274.
3. Joseph VT: Pudendal- thigh flap vaginoplasty in the reconstruction of genital anomalies. *J Pediatr Surg* (1997) 32: 62–65.
4. Giraldo F, Mora MJ, Solano A, González C and Fernández VS: Male perineogenital anatomy and clinical application in genital reconstructions and male-to female sex reassignment surgery. *Plast Reconstr Surg* (2002) 109: 1301–1310.
5. Selvaggi G, Monstrey S, Depypere H, Blondeel P, Landuyt KV, Hamdi M and Dhont M: Creation of neovagina with use of a pudendal thigh fasciocutaneous flap and restoration of uterovaginal continuity. *Fertility and Sterility* (2003) 80: 607–611.
6. Brown J: Creation of a functional clitoris and aesthetically pleasing introitus in sex Inversion; in Transactions of the sixth International Congress of Plastic and Reconstructive Surgery. Marchac and Hueston JT eds, Masson, Paris (1976) pp 654–655.
7. Rubin SO: A method of preserving the glans penis as a clitoris in sex conversion. *Scand J Urol Nephrol* (1980) 14: 215–217.
8. Fang RH, Chen CF and Ma S: A new method for clitoroplasty in male-to-female sex reassignment surgery. *Plast Reconstr Surg* (1992) 89: 679–682.
9. Hage JJ and Karim RB: Sensate pedicled neoclitoroplasty for male transsexuals: Amsterdam experience in the first 60 patients. *Ann Plast Surg* (1996) 36: 621–624.
10. Giraldo F, Esteva I, Bergero T, Cano G, Gonzalez C, Salinas P, Rivada E, Lara JS and Soriguer F: Corona glans clitoroplasty and urethroepreputial vestibuloplasty in male-to-female transsexuals: The vulval aesthetic refinement by Andalusia gender team. *Plast Reconstr Surg* (2004) 114: 1543–1550.
11. Laub D and Laub DR II: Rectosigmoid vaginoplasty; in *Plastic Surgery in the Sexually Handicapped*, Eicher W ed, Springer-Verlag Berlin (1989) pp 98–99.
12. Goligher JC: The use of pedicled transplant of sigmoid or other parts of the intestine for vaginal construction. *Ann R Coll Surg Engl* (1983) 65: 353–355.
13. Karim RB, Hage JJ and Cuesta MA: Rectosigmoid neocolpopoiesis for male-to-female transsexuals: Amsterdam experience. *Ann Plast Surg* (1996) 36: 388–391.
14. Pandya NJ, and Stuteville OH: A one-stage technique for constructing female external genitalia in male transsexuals. *Br J Plast Surg* (1973) 26: 277–282.
15. Karim RB, Hage JJ, Bouman FG, Ruyter R and van Kesteren PJ: Refinement of pre-, intra-, and postoperative care to prevent complications of vaginoplasty in male transsexuals. *Ann Plast Surg* (1995) 35: 279–284.
16. Eldh J: Construction of a neovagina with preservation of the glans penis as a clitoris in male transsexuals. *Plast Reconstr Surg* (1993) 91: 895–900.
17. Huang TT: Twenty years of experience in managing gender dysphoric patients: I. Surgical management of male transsexuals. *Plast Reconstr Surg* (1995) 96: 921–930.