

Acta Medica Okayama

Volume 37, Issue 6

1983

Article 5

DECEMBER 1983

Prostatic malacoplakia: a case report with a review of 49 cases of malacoplakia of various sites in Japan.

Hiromi Kumon*

Masato Furukawa[†]

Masaya Tsugawa[‡]

Yosuke Matsumura**

Hiroyuki Ohmori^{††}

Toshio Tanaka^{‡‡}

*Okayama University,

[†]Okayama University,

[‡]Okayama University,

**Okayama University,

^{††}Okayama University,

^{‡‡}Okayama University,

Prostatic malacoplakia: a case report with a review of 49 cases of malacoplakia of various sites in Japan.*

Hiromi Kumon, Masato Furukawa, Masaya Tsugawa, Yosuke Matsumura,
Hiroyuki Ohmori, and Toshio Tanaka

Abstract

We reported a 62-year-old man with malacoplakia of the prostate, and reviewed 49 cases of malacoplakia hitherto observed in Japan in which the lesions originated from the urogenital tract, except for one gastric case. *E. Coli* was emphasized as a possible causative agent for malacoplakia especially in the urogenital tract. The possible histiocytic origin of von Hansemann cells was stressed by demonstrating cytoplasmic processes and desmosomes in our prostatic case. An adjuvant use of cholinergic agents and ascorbic acid with chemotherapeutic agents was recommended for treating malacoplakia.

KEYWORDS: malacoplakia, prostate, von Hansemann cell

*PMID: 6666677 [PubMed - indexed for MEDLINE]

Copyright (C) OKAYAMA UNIVERSITY MEDICAL SCHOOL

Acta Med. Okayama 37, (6), 493-501 (1983)

PROSTATIC MALACOPLAKIA : A CASE REPORT WITH A REVIEW OF 49 CASES OF MALACOPLAKIA OF VARIOUS SITES IN JAPAN

Hiromi KUMON, Masato FURUKAWA, Masaya TSUGAWA, Yosuke MATSUMURA,
Hiroyuki OHMORI and Toshio TANAKA*

*Department of Urology, and * Pathology Section, Central Laboratories,
Okayama University Medical School, Okayama 700, Japan*

Received August 8, 1983

Abstract. We reported a 62-year-old man with malacoplakia of the prostate, and reviewed 49 cases of malacoplakia hitherto observed in Japan in which the lesions originated from the urogenital tract, except for one gastric case. *E. Coli* was emphasized as a possible causative agent for malacoplakia especially in the urogenital tract. The possible histiocytic origin of von Hansemann cells was stressed by demonstrating cytoplasmic processes and desmosomes in our prostatic case. An adjuvant use of cholinergic agents and ascorbic acid with chemotherapeutic agents was recommended for treating malacoplakia.

Key words : malacoplakia, prostate, von Hansemann cell.

In 1981 Stanton and Maxted (1) made a comprehensive review of malacoplakia concerning its pathogenesis, diagnosis and treatment. Their review was mainly based on English literature, and only one Japanese case with the lesion originating in the stomach reported by Nakabayashi *et al.* (2) was included. In Japan, since Yoneyama *et al.* (3) observed a case of bladder malacoplakia, a total of 49 cases have been reported. Out of these, a gastric case (2), a case originating either from the superficial part of the kidney or from the retroperitoneum (4, 5), and four prostate cases (6, 7) were reported in English ; the remaining cases, including one case each of the epididymis, prostate and retroperitoneal origin, were in Japanese either as full papers or abstracts. We briefly review these 49 cases and add a case of prostate origin recently experienced by us.

CASE PRESENTATION

A 62-year-old male was admitted to the Department of Urology, Okayama University Hospital, on November 16, 1981 complaining of dysuria. He had been well without history of urinary tract infection until one month prior to admission, when he noticed nocturia and dysuria. Digital examination revealed a hard, enlarged left lobe of the prostate with an irregular surface.

ESR was slightly elevated (13/1 h, 40/2 h), CRP was one plus and WBC was 9,800/mm³ with neutrophilia. Other laboratory data including fasting blood sugar, serum lysozyme and prostatic acid phosphatase were normal, and urine culture was negative. Urinalysis, cystoscopy,

excretory urogram and bone scintigram were normal, except for a slight irregularity and elongation of the prostatic urethra by urethrocytogram.

On November 24, a transrectal needle biopsy of the prostate was performed suspecting a prostatic cancer which turned out to be malacoplakia as described below. On December

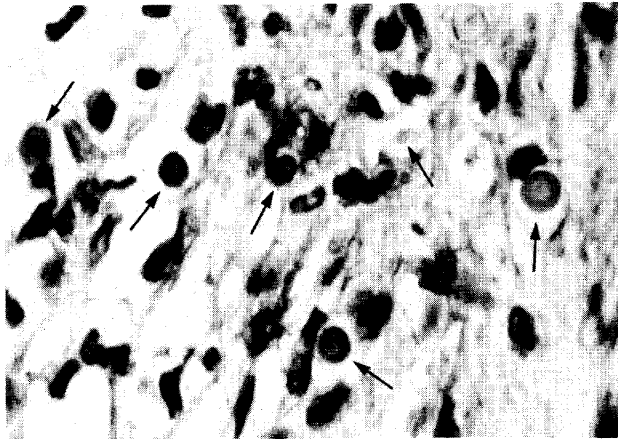


Fig. 1. Several Michaelis-Gutmann bodies having a lamellated structure with so-called target-like or owl's eye appearance (arrows). H & E, $\times 1,000$.

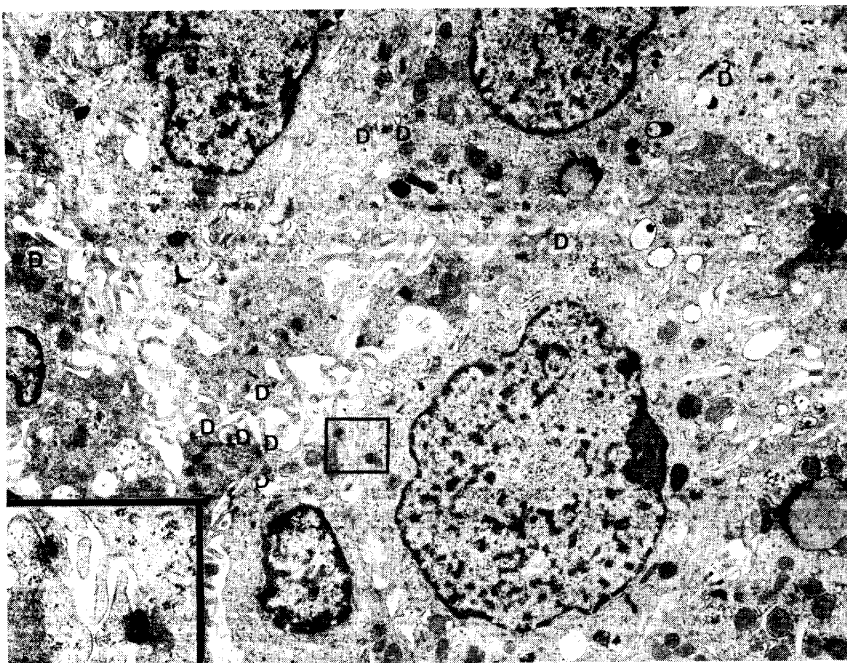


Fig. 2. A few von Hanseman cells having extensive cytoplasmic processes and numerous desmosomes (D). $\times 6,500$. Inset: Enlargement of boxed area showing two desmosomes. $\times 19,200$.

10, a transurethral resection of the prostate was made to solve the dysuria. Thereafter, the patient was discharged, and had been treated with trimethoprim-sulfamethoxazole (320 mg trimethoprim plus 1,600 mg sulfamethoxazole per day) orally for three months. He has been well for 15 months after the transurethral resection.

Light microscopically, two pieces of the needle-biopsied specimen consisted of elongated prostatic tissue. The interductal interstitium was occupied by a granulomatous lesion, composed of foamy histiocyte-like cells, pale-stained spherulites, lymphocytes and moderate vascular proliferation. The cytoplasm of the histiocyte-like cells was eosinophilic and contained coarse granules which were positive for periodic acid-Schiff (PAS) and not digestible (von Hanseman cells). The spherulites were stained deep-pink with a lamellated pattern with PAS (Fig. 1), almost black with von Kossa, and blue with Berlin blue for iron (Michaelis-Gutmann bodies).

Electron microscopically, histiocytes contained numerous phagolysosomes and Michaelis-Gutmann bodies with various stages of maturation. Interestingly, many histiocytes had extensive cytoplasmic processes and desmosomes (Fig. 2). Some of them showed considerable interdigitation of cytoplasmic membranes (Fig. 3). Fig. 4 shows a Michaelis-Gutmann body at the late stage of maturation having prominent calcification in the center and a limiting membrane.

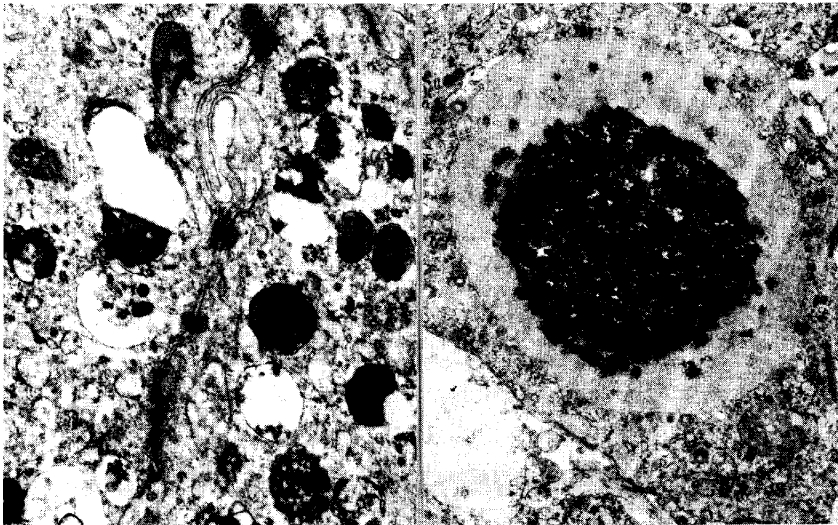


Fig. 3. (left) Two von Hanseman cells showing interdigitation and connection with several desmosomes. $\times 17,400$.

Fig. 4. (right) A Michaelis-Gutmann body with prominent central calcification. $\times 7,200$.

REVIEW OF JAPANESE CASES

Table 1 shows 50 cases of malacoplakia. These consist of 40 bladders, 6 prostates, 2 either retroperitoneum or kidney, and one each of the epididymis and stomach, indicating the predominance of malacoplakia occurring in the urogenital tract. There were 11 males and 39 females with the age ranging from 27 to 88 years. *Escherichia coli* was positive by urine or pus culture in 31 cases (62.0 %).

TABLE 1. REVIEW OF 50 CASES OF MALACOPLAKIA AMONG JAPANESE SUBJECTS^a

Informants ^b (Year reported)	Sex, Age	Chief complaints	Urine culture ^c	Diagnosed by ^d	M-G body	Notes
1 Yoneyama <i>et al.</i> ³ (1965)	F 53	Pollakisuria, dysuria	<i>E. coli</i>	Cyst, Bx	(+)	Complicated by cervical cancer, stage IV
2 Sasaki & Hokano (1966)	F 28	Pollakisuria, miction pain	<i>E. coli</i>	Cyst, Bx	(-)	Complicated by systemic lupus erythematosus
3 Seki (1968)	F 57	Terminal hematuria	<i>E. coli</i>	Cyst, Bx	(+)	
4 Ishibashi <i>et al.</i> (1970)	F 47	Hematuria	<i>E. coli</i>	Cyst, Bx	(-)	
5 <i>ibid.</i>	F 53	Terminal hematuria	<i>E. coli</i>	Cyst, Bx	(+)	Treated with 0.25% AgNO ₃ instillation
6 Hamada <i>et al.</i> (1973)	M 66	Pollakisuria, miction pain	<i>E. coli</i>	Cystectomy	(-)	
7 Soeda <i>et al.</i> (1973)	F 41	Terminal hematuria	<i>E. coli</i>	Cyst, Bx	(+)	
8 Oya <i>et al.</i> (1974)	F 42	Terminal hematuria	<i>E. coli</i>	Cyst, Bx	(+)	
9 Tsuchiya (1975)	F 71	Pollakisuria, miction pain	<i>E. coli</i>	Cyst, Bx	(+)	
10 <i>ibid.</i>	F 57	Pollakisuria, miction pain	<i>E. coli</i> , Proteus	Cyst, Bx	(+)	
11 Inaba <i>et al.</i> (1975)	M 88	Pollakisuria, hematuria	...	Cyst, Bx	(-)	
12 Kohno <i>et al.</i> (1975)	F 42	Hematuria	...	Cyst, Bx, cytology	(+)	
13 Hashimoto <i>et al.</i> (1976)	F 72	Terminal hematuria	Negative	Cyst, Bx	(+)	
14 Fujita (1976)	M 47	Rt. orchitis	<i>E. coli</i>	Cyst, Bx	(+)	
15 Ikeda <i>et al.</i> (1977)	F 48	Terminal hematuria	<i>E. coli</i>	Cyst, Bx	(+)	
16 Tokue <i>et al.</i> (1977)	F 44	Miction pain, hematuria	<i>E. coli</i>	Cyst, Cystectomy	(+)	
17 Nakajima <i>et al.</i> (1978)	F 27	Hematuria	Negative	Cyst, Bx	(+)	Complicated by SLE and nephrosis

TABLE 1. Continued

18	Nakabayashi <i>et al.</i> ² (1978)	F	71	Diarrhea	Gastrectomy	(+)	Stomach origin, and compli- cated by colon cancer	
19	Katayori <i>et al.</i> (1979)	F	66	Pyuria	...	Cyst, Bx		(+)		
20	Washizuka <i>et al.</i> (1979)	F	67	Terminal miction pain		
21	<i>ibid.</i>	F	63	Dysuria	...	Cytology		(+)		
22	<i>ibid.</i>	M	49	Microhematuria		
23	Kobayashi <i>et al.</i> (1979)	F	74	Autopsy		(+)	Complicated by aplastic anemia	
24	Kouchi & Nakayama (1979)	F	53	Pollakisuria, miction pain	E. coli	Cyst, Bx, cytology		(+)		
25	Lui <i>et al.</i> (1979)	F	58	Dysuria, hematuria	E. coli	Cyst, Bx		(+)		
26	Kumon <i>et al.</i> ^{4,5} (1979)	F	61	Rt. flank mass	E. coli	Nephrectomy		(+)	Retroperitoneal or renal origin, and long-term use of steroid	
27	Kobayashi <i>et al.</i> (1980)	F	68	Terminal miction pain, hematuria	Klebsiella	Cyst, Bx		(+)		
28	Ohtaki <i>et al.</i> (1980)	F	67	Pollakisuria, miction pain	E. coli	Cyst, Bx cytology		(+)		
29	Nishida <i>et al.</i> (1980)	F	41	Pollakisuria, hematuria	E. coli	Cyst, Bx		(+)		
30	Kawamura <i>et al.</i> ⁶ (1980)	M	53	Urinary retention	E. coli	Prostatic bx		(+)	Prostate origin	
31	<i>ibid.</i>	M	47	Fever, terminal miction pain	E. coli	Prostatic bx		(+)	Prostate origin	
32	<i>ibid.</i>	M	55	Fever, urinary retention	E. coli	Prostatic bx		(+)	Prostate origin	
33	Masukagami <i>et al.</i> (1981)	F	73	Terminal hematuria	E. coli	Cyst, Bx		(+)		
34	Miura <i>et al.</i> (1981)	F	65	Cloudy urine	...	Cyst, Bx		(+)	Complicated by diabetes mellitus	
35	<i>ibid.</i>	F	60	Hematuria	...	Cyst, Bx		(+)		

TABLE 1. Continued

36	Surmyoshi <i>et al.</i> (1981)	F	62	Pollakisuria	...	Cyst, Bx	(+)
37	<i>ibid.</i>	F	78	Pollakisuria	...	Cyst, Bx	(+)
38	Suyama <i>et al.</i> (1981)	F	72	Terminal hematuria	<i>E. coli</i>	Cyst, Bx	(+)
39	Hisajima <i>et al.</i> (1981)	F	71	Hematuria	...	Cyst, Bx	(+)
40	Shimizu <i>et al.</i> ⁷ (1981)	M	55	Dysuria	<i>E. coli</i>	Prostatic bx	(+)
41	Yoneda <i>et al.</i> (1981)	F	76	Hematuria, miction pain	<i>E. coli</i>	Cyst, Bx	(+)
42	Fujisawa <i>et al.</i> (1981)	M	48	Fever, painful swelling of Rt. scrotal contents	<i>E. coli</i> (pus)	Epididymectomy	(+)
43	Pak <i>et al.</i> (1982)	F	77	Pollakisuria, residual feeling	<i>E. coli</i>	Cyst, Bx	(+)
44	Mitsui <i>et al.</i> (1982)	F	41	General fatigue	<i>E. coli</i>	Cystectomy	(+)
45	Sakai <i>et al.</i> (1982)	M	80	Urinary retention, fever	Serratia, <i>S. faecalis</i>	Prostatic bx	
46	Yamazaki <i>et al.</i> (1982)	F	58	Microhematuria	<i>E. coli</i>	Cyst, Bx	(+)
47	Yasuno <i>et al.</i> (1982)	F	68	Pollakisuria, dysuria	<i>E. coli</i>	Cyst, Bx	(+)
48	Yamada (1982)	F	55	Cyst, Bx	(+)
49	Hirao <i>et al.</i> (1982)	F	40	Rt. flank pain	<i>E. coli</i> (pus)	Laparotomy	(+)
50	Present case	M	62	Dysuria	Negative	Prostatic bx	(+)

a Forty cases originated from the bladder, and the remaining 10 cases from the prostate, retroperitoneum or kidney, epididymis and stomach as stated in the notes.

b Referred to only full papers written in English, except for Yoneyama *et al.*²

c (pus) : Culture was obtained from pus.

d Cyst : cystoscopy ; Bx : biopsy.

DISCUSSION

According to Stanton and Maxted (1), approximately 198 cases of malacoplakia were reported up to 1981. They reviewed 153 of these cases, and found that 40 % were of the bladder and 10 % of the prostate. According to a study by Shimizu *et al.* (7) on prostatic malacoplakia, a total of 21 cases have been reported including a case of their own and three cases reported by Kawamura *et al.* (6). The frequency of the prostatic malacoplakia among Japanese subjects (6/50 cases), including our case and that of Sakai *et al.* (Table 1), corresponds fairly well to the figure of Stanton and Maxted. *E. coli* was identified in 17 cases (77.3 %) of prostatic malacoplakia (7). Therefore, as far as the urogenital tract is concerned, *E. coli* is the most possible inducer of malacoplakia.

Concerning the cyto genesis of von Hansemann cell, we consider the cell to be a histiocyte with rather poor phagocytic activity (5). On the other hand, from cases of the kidney (8, 9), bladder extending to kidney (10), ureter (11), epididymis (12), and testis (13), and from experimental malacoplakia of the renal cortex (14), an epithelial origin of von Hansemann cells has been proposed. Our electron microscopic findings demonstrating extensive cytoplasmic processes and clear-cut desmosomes agree well with the observations made by Chaudhry *et al.* (15, 16). Although no comment was given on the significance of the cytoplasmic processes and desmosomes, they were apparently convinced that 'malacoplakia is caused primarily by *E. coli* and is manifested by an accumulation of histiocytes filled with phagolysosomes and Michaelis-Gutmann bodies'. In fact, the presence of desmosomes especially between infolded and intertwined cytoplasmic processes of dendritic reticulum cells in the germinal centers of lymph nodes is well known (17). These facts may speak further for the possible histiocytic origin of von Hansemann cells.

Although the etiology of malacoplakia is not clearly understood, its association with tuberculosis, sarcoidosis, malignant neoplasm and immune deficiency has been reported. Eleven of 50 cases reviewed had intercurrent disorders: two cases with tuberculosis, one sarcoidosis, two malignant neoplasms, two systemic lupus erythematosus, one aplastic anemia, two diabetes mellitus, and one collagen disease after steroid treatment. Recent studies, as reviewed by Stanton and Maxted (1), have focused on abnormal intraphagolysosomal digestion. Proper microtubule assembly is required during phagocytosis, and cyclic-guanine monophosphate (cyclic-GMP) acts as a signal to the microtubule assembly. Oliver (18) presented the evidence that cholinergic agents in the Chediak-Higashi syndrome increased intracellular cyclic-GMP concentration, enhanced lysosomal degradation and released lysosomal enzymes such as beta-glucuronidase. Abdou *et al.* (19) demonstrated in malacoplakia patients blood monocytes with abnormally-low intracellular levels of cyclic-GMP, which resulted in impaired lysosomal function and bacterial killing. They successfully treated severe retroperitoneal malacoplakia daily with 40 mg of bethanechol. Zornow *et al.* (20) reported favorable results in cases with

bladder malacoplakia using bethanechol. Hisajima *et al.* also reported a Japanese case of bladder malacoplakia treated with a cholinergic agonist, which resolved symptoms with disappearance of almost all lesions after 1.5 months of treatment. Histiocyte dysfunction in the lesion of malacoplakia, however, might be secondary to chronic inflammation in a compromised host, since malacoplakia, especially of the urogenital tract, is related to bacterial infection. Therefore, malacoplakia should be treated essentially with antibiotics sensitive to causative micro-organisms. Trimethoprim-sulfamethoxazole, effective in the present case, and refampin can possibly enter phagocytes and assist intracellular killing of bacteria (21). An adjuvant use of cholinergic agents and ascorbic acid with chemotherapeutic agents could be promising in treating malacoplakia.

REFERENCES

1. Stanton, M.S. and Maxted, W.: Malacoplakia : A study of the literature and current concepts of pathogenesis, diagnosis and treatment. *J. Urol.* **125**, 139-146, 1981.
2. Nakabayashi, H., Ito, T., Izutsu, K., Yatani, R. and Ishida, K.: Malacoplakia of the stomach : Report of a case and review of the literature. *Arch. Pathol. Lab. Med.* **102**, 136-139, 1978.
3. Yoneyama, T., Tazaki, E., Oryu, S., Machida, T., Shirasawa, H. and Seki, M.: Malacoplakia of the urinary bladder : Report of a case with clinical, histopathologic and electron microscopic studies. *Dermatol. Urologica* **19**, 615-619, 1965 (in Japanese).
4. Kumon, H., Morioka, M., Araki, T., Matsumura, Y., Ohmori, H. and Tanaka, T.: Malacoplakia of probable retroperitoneal origin. *Acta Med. Okayama* **33**, 455-462, 1979.
5. Tanaka, T., Sakuma, H., Takahashi, K., Kumon, H. and Ohmori, H.: Extravesical malacoplakia-Possibly originated from a superficial part of the renal cortex. *Acta Pathol. Jpn.* **31**, 323-334, 1981.
6. Kawamura, N., Murakami, Y. and Okada, K.: Three cases of malacoplakia of prostate. *Urology* **15**, 77-80, 1980.
7. Shimizu, S., Takimoto, Y., Niimura, T., Kaya, H., Yamamoto, T., Kawazoe, K. and Okada, K.: A case of prostatic malacoplakia. *J. Urol.* **126**, 277-279, 1981.
8. Ravel, R.: Megalocytic interstitial nephritis : An entity probably related to malacoplakia. *Am. J. Clin. Pathol.* **47**, 781-789, 1967.
9. Miller, O.S. and Finck, F.M.: Malacoplakia of the kidney : The great impersonator. *J. Urol.* **103**, 712-717, 1970.
10. Cederqvist, L.L.: Malacoplakia of the urinary tract : A theory of pathogenesis. *Arch. Pathol.* **80**, 495-499, 1965.
11. Breda, G., Artibanti, W., Vancini, P., Lotto, A., Brunetti, A. and Battaglia, G.: Ultrastructural features in a case of ureteric malacoplakia. *Eur. Urol.* **3**, 132-141, 1977.
12. Green, Jr., W.O.: Malacoplakia of the epididymis (without testicular involvement) : The first reported case. *Arch. Pathol.* **86**, 438-441, 1968.
13. Dionne, G.P., Bovil, E.G. and Seemayer, T.S.: New fine structural observations in testicular malacoplakia : Role of the Sertoli cell. *Urology* **5**, 828-834, 1975.
14. Ormos, J., Mohácsi, G., Kuthy, E. and Böti, Zs.: Renal cortical tubules in experimental malacoplakia. Phagocytic alteration of tubular epithelium. *Exp. Pathol.* **17**, 3-11, 1979.
15. Chaudhry, A.P., Saigal, K.P., Intengan, M. and Nickerson, P.A.: Malacoplakia of the large intestine found incidentally at necropsy : Light and electron microscopic features. *Dis. Colon*

Rectum **22**, 73-81, 1979.

16. Chaudhry, A.P., Satchidanand, S.K., Anthone, R., Baumler, R.A. and Gaeta, J.F.: An unusual case of supraclavicular and colonic malacoplakia-A light and ultrastructural study. *J. Pathol.* **131**, 193-208, 1980.
17. Kojima, M., Imai, Y. and Mori, N.: A concept of follicular lymphoma : A proposal for the existence of a neoplasm originating from the germinal center. In *Malignant Diseases of the Hematopoietic System*. Monograph on Cancer Research 15. Ed. K. Akazaki, H. Rappaport, C.W. Berard, J.M. Bennett and E. Ishikawa. University of Tokyo Press, Tokyo, pp. 195-207, 1973.
18. Oliver, J.M.: Impaired microtubule function correctable by cyclic GMP and cholinergic agonists in the Chediak-Higashi syndrome. *Am. J. Pathol.* **85**, 395-418, 1976.
19. Abdou, N.J., Na Pomejava, D., Sagawa, A., Ragland, C., Stechschulte, D.J., Nilsson, U., Gourley, W., Watanabe, I., Lindsey, N.J. and Allen, M.S.: Malacoplakia : evidence for monocyte lysosomal abnormality correctable by cholinergic agonist *in vitro* and *in vivo*. *N. Engl. J. Med.* **297**, 1413-1419, 1977.
20. Zornow, D.H., Landes, R.R., Morganstern, S.L. and Fried, F.A.: Malacoplakia of the bladder : efficacy of bethanechol chloride therapy. *J. Urol.* **122**, 703-704, 1979.
21. Maderazo, E.G., Berlin, B.B. and Marhardt, C.: Treatment of malacoplakia with trimethoprim-sulfamethoxazole. *Urology* **13**, 70-73, 1979.