

# *Acta Medica Okayama*

---

*Volume 61, Issue 5*

2007

*Article 7*

OCTOBER 2007

---

## Intramesocolic Diverticular Perforation of the Sigmoid Colon Diagnosed by Detecting Air Collection in Anterior Pararenal Space on Computed Tomography: Report of a Case

Tatsuto Ashizawa\*

Koichiro Hama<sup>†</sup>

Hiroaki Tanaka<sup>‡</sup>

Masayuki Ando\*\*

\*Hachioji Medical Center of Tokyo Medical University,

<sup>†</sup>Hachioji Medical Center of Tokyo Medical University,

<sup>‡</sup>Tokyo Metropolitan Toshima General Hospital,

\*\*Tokyo Metropolitan Toshima General Hospital,

# Intramesocolic Diverticular Perforation of the Sigmoid Colon Diagnosed by Detecting Air Collection in Anterior Pararenal Space on Computed Tomography: Report of a Case\*

Tatsuto Ashizawa, Koichiro Hama, Hiroaki Tanaka, and Masayuki Ando

## Abstract

A 64-year-old woman was admitted to our hospital with lower abdominal pain. Routine laboratory values were unremarkable except for the white blood cell count (15,000/micro litter) and the C-reactive protein (CRP) value (22.5 mg/dl). A Computed tomography (CT) scan revealed air collection in the middle of the anterior pararenal space. One day later, CT revealed air collection in the anterior pararenal space spread to the right side and abscess in the sigmoid mesentery. Because an intramesocolic perforation of the sigmoid colon was suspected, an emergency operation was performed. Abscess formation was recognized in the sigmoid mesentery, and sigmoidectomy including the contaminated mesentery and Hartmann's procedure were performed. The perforation was 3 cm in diameter, and some diverticula were present in the vicinity of the perforated site. The specimen microscopically revealed perforation at the edge of the diverticulum in association with sudden disruption of the proper muscle layer. Based on pathological findings, intramesocolic diverticular perforation of the sigmoid colon was diagnosed. The present case is a very rare condition. However, it was possible to make a diagnosis preoperatively by detecting air collection in the anterior pararenal space on CT scan. If a sigmoid perforation occurs between the leaves of the mesocolon, air extends into the root of the sigmoid mesocolon and within the anterior pararenal space.

**KEYWORDS:** colon diverticulosis, intramesocolic perforation, computed tomography, free air

Case Report

## Intramesocolic Diverticular Perforation of the Sigmoid Colon Diagnosed by Detecting Air Collection in Anterior Pararenal Space on Computed Tomography: Report of a Case

Tatsuto Ashizawa<sup>a,b\*</sup>, Koichiro Hama<sup>a</sup>,  
Hiroaki Tanaka<sup>b</sup>, and Masayuki Ando<sup>b</sup>

<sup>a</sup>Department of Surgery, Hachioji Medical Center of Tokyo Medical University, Hachioji, Tokyo 193-0998, Japan, and  
<sup>b</sup>Department of Surgery, Tokyo Metropolitan Toshima General Hospital, Itabashi, Tokyo 173-0015, Japan

A 64-year-old woman was admitted to our hospital with lower abdominal pain. Routine laboratory values were unremarkable except for the white blood cell count (15,000/ $\mu$ l) and the C-reactive protein (CRP) value (22.5 mg/dl). A Computed tomography (CT) scan revealed air collection in the middle of the anterior pararenal space. One day later, CT revealed air collection in the anterior pararenal space spread to the right side and abscess in the sigmoid mesentery. Because an intramesocolic perforation of the sigmoid colon was suspected, an emergency operation was performed. Abscess formation was recognized in the sigmoid mesentery, and sigmoidectomy including the contaminated mesentery and Hartmann's procedure were performed. The perforation was 3 cm in diameter, and some diverticula were present in the vicinity of the perforated site. The specimen microscopically revealed perforation at the edge of the diverticulum in association with sudden disruption of the proper muscle layer. Based on pathological findings, intramesocolic diverticular perforation of the sigmoid colon was diagnosed. The present case is a very rare condition. However, it was possible to make a diagnosis preoperatively by detecting air collection in the anterior pararenal space on CT scan. If a sigmoid perforation occurs between the leaves of the mesocolon, air extends into the root of the sigmoid mesocolon and within the anterior pararenal space.

**Key words:** colon diverticulosis, intramesocolic perforation, computed tomography, free air

**A** gastrointestinal perforation is generally assumed to show the presence of free air on diagnostic imaging. In suspected complicated diverticular disease, computed tomography (CT) is preferred to other imaging modalities to make a diagnosis [1-4]. However, intramesocolic perforation is not

only a rare complication of colonic diverticulitis but is one of the most occult manifestations of the disease. It may present as fever of unknown etiology or generalized lower abdominal pain. We encountered a case of intramesocolic diverticular perforation of the sigmoid colon preoperatively diagnosed on CT, which was useful in detecting air collection in the retroperitoneal space.

Received December 4, 2006; accepted May 9, 2007.

\*Corresponding author. Phone: +81-42-665-5611; Fax: +81-42-665-1796  
E-mail: ashizawa@tokyo-med.ac.jp (T. Ashizawa)

### Case Report

A 64-year-old woman presented at a local hospital with lower abdominal pain and was given medicine. However, abdominal pain persisted and she was referred to our hospital the next day. On admission, her temperature was 37.4 °C, and physical examination of the abdomen revealed left lower quadrant ten-

derness without guarding or rebound. Routine laboratory values were unremarkable except for the white blood cell count (15,000/ $\mu$ l) and the C-reactive protein (CRP) value (22.5 mg/dl). CT revealed ill-defined air collection in the middle of the anterior pararenal space (Fig. 1). One day later, CT revealed air collection in the anterior pararenal space spread to the right side and an abscess in the sigmoid mesentery (Fig. 2A, B). Based on the slight leukocytosis and the elevated CRP values as well as the CT findings, a retroperitoneal perforation of the sigmoid colon was highly suspected. At the time of surgery, the sigmoid mesentery was indurated, foreshortened, and edematous with purulent exudate (Fig. 3), and abscess formation was seen throughout the retroperitoneal space. We diagnosed intramesocolic perforation of the sigmoid colon and performed sigmoidectomy including the contaminated mesentery and Hartmann's procedure. The excised material showed a perforation 3 cm in diameter and some diverticula in the vicinity of the perforated site. The specimen microscopically revealed perforation at the edge of the diverticulum in association with sudden disruption of the proper muscle layer (Fig. 4).

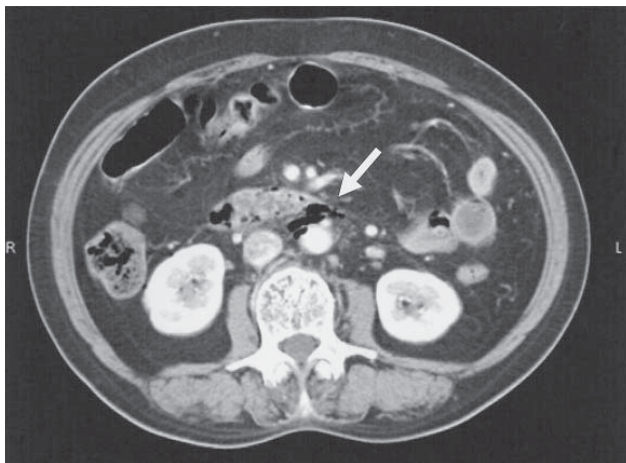
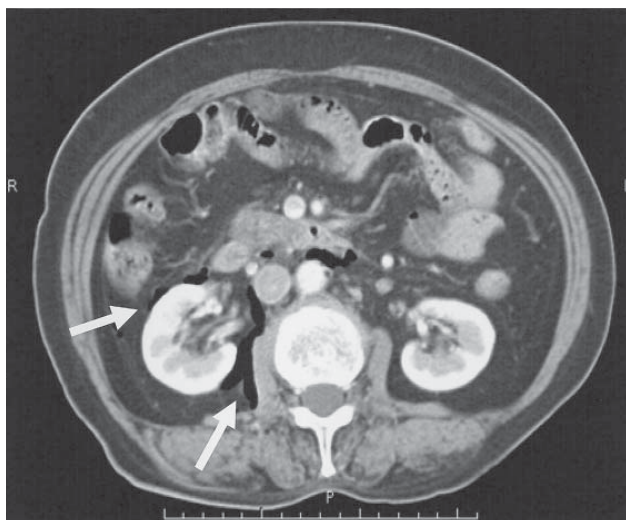
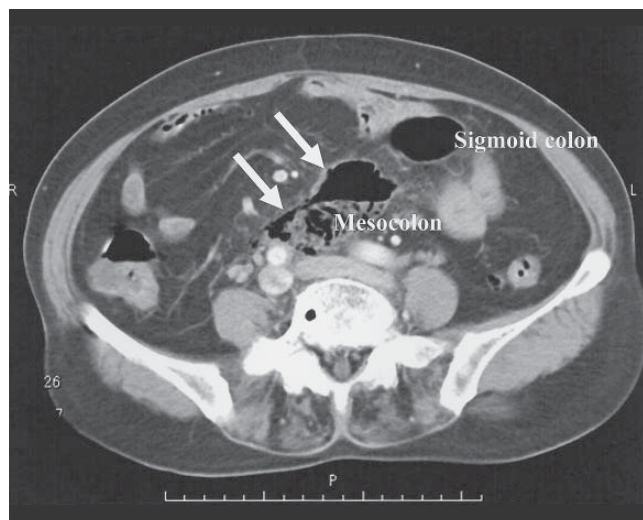


Fig. 1 CT revealed ill-defined air collection in the middle of the anterior pararenal space (arrow).



A



B

Fig. 2 A second CT revealed air collection in the anterior pararenal space spread to the right side (arrow) (A) and abscess in the sigmoid mesentery (arrow) (B).

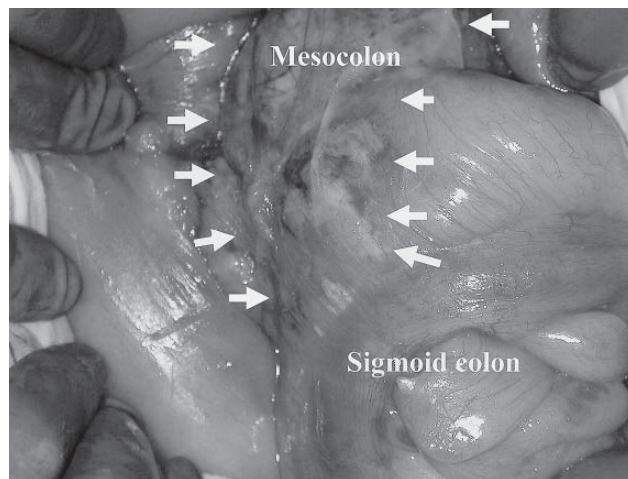
## Discussion

Diverticulosis is an acquired disease of the colon characterized by multiple herniation sacs composed of mucosa and submucosa through areas of the colonic wall at weak points where the blood vessels penetrate it to supply the mucosa [5, 6]. Of all patients with diverticula, 80 to 85 percent are believed to remain asymptomatic. The remaining one fourth develop

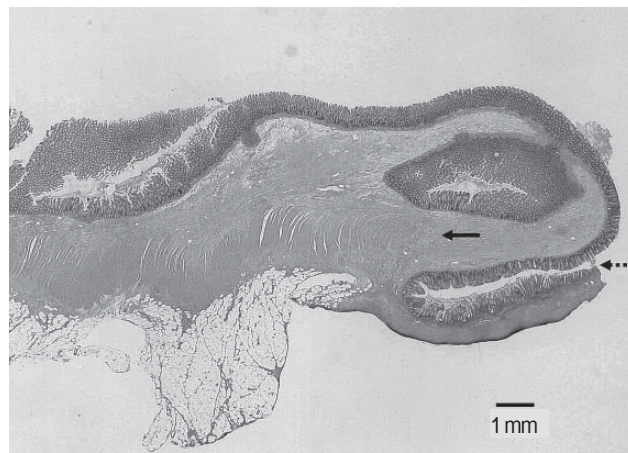
diverticulitis, and a small number will develop complications of diverticulitis such as rupture, fistulas, abscess formation, obstruction, or hemorrhage [7]. Colon diverticulitis is complicated by perforation in approximately 8% of patients, of which 1 to 2% are intramesenteric perforations [8, 9]. In our review of the English and Japanese literature, the first case was reported from Massachusetts General Hospital in 1964 [10], and we found more or less 16 cases of intramesocolic diverticular perforation of the sigmoid colon [8-13]. However, intramesocolic perforation of diverticulitis may be more common than is recognized. If the abscess is small and well-contained in the mesocolon, it may resolve with conservative treatment [11].

In general, rupture of the bowel wall can occur only if there is a sufficient rise in intraluminal pressure, weakness of the bowel wall, or a combination of the 2. Several studies have found the sigmoid colon to be the most frequent site of perforation [14-16]. Weakening of the bowel wall, particularly a poorly supported area such as the antimesenteric border of the rectosigmoid, could predispose it to rupture. The rectosigmoid is the narrowest portion of the colon and therefore is the point most liable to damage in an effort to pass hard fecal masses [15]. Brearley has suggested that impaction of a hard fecal mass on the antimesenteric wall of the bowel, where the blood supply is poorest, may lead to ischemic necrosis and subsequent perforation [17]. Moreover, Slack has described that diverticula are confined almost exclusively to the area between the mesenteric and the antimesenteric taenia [6]. This anatomic location may explain why intramesenteric perforation is seen less often than free or paracolic rupture. On the other hand, the cause of a perforated mesenteric border is suggested to be associated with poor dilatation of the mesenteric border as well as fragility of the circular muscle at the part of the vasa recta passing through the intestinal wall, where diverticula commonly occur due to the rise in intraluminal pressure [16, 18].

Imaging diagnosis of a retroperitoneal perforation of the colon shows air collection in the mesentery or retroperitoneum. CT is the most superior modality for detecting air collection because the settings allow a lower window level and greater window width, allowing it to more easily distinguish free air from fatty tissue than other modalities [3, 19, 20]. It is



**Fig. 3** Intraoperative findings. The sigmoid mesentery was indurated, foreshortened, and edematous with purulent exudate (arrow).



**Fig. 4** Microscopic findings (H.E. stain) The specimen revealed perforation at the edge of the diverticulum (dashed arrow) in association with sudden disruption of the proper muscle layer (arrow).

possible to estimate the location of the perforated colon on the basis of thickening of the wall and the location of free air, or both. Meyers has documented that only if a sigmoid perforation occurs between the

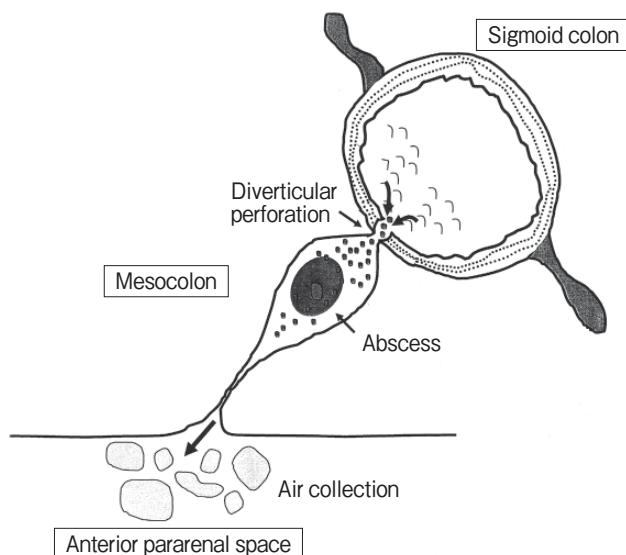


Fig. 5 If a sigmoid perforation occurs between the leaves of the mesocolon, air extends into the root of the sigmoid mesocolon and within the anterior pararenal space.

leaves of the mesocolon does extraperitoneal air rise bilaterally into the anterior pararenal spaces (Fig. 5) [21]. The presence of air collection on the left side of the anterior pararenal space can be thought to indicate sigmoid colon perforation from the mesocolon to the retroperitoneum. However, the diseased side of the air collection in the anterior pararenal space moves to the opposite side of the anterior and/or posterior pararenal space with time, making it difficult to establish a differential diagnosis of the cause of the retroperitoneal air collection (Fig. 6) [22]. Air collection in the retroperitoneal space can be caused by acute pancreatitis, emphysematous pyelonephritis, spondylitis, and infectious aneurysm as well as gastrointestinal perforation [18, 23, 24]. The free air produced by infection generally consists of several small bubbles, while on the other hand the free air produced by gastrointestinal perforation tends to lump together. Therefore, it is not generally difficult to distinguish between the causes of free air [19].

References

1. Hulnick DH, Megibow AJ, Balthazar EJ, Naidich DP and Bosniak MA: Computed tomography in the evaluation of diverticulitis. *Radiology* (1984) 152: 491-495.
2. Labs JD, Sarr MG, Fishman EK, Siegelman SS and Cameron JL:

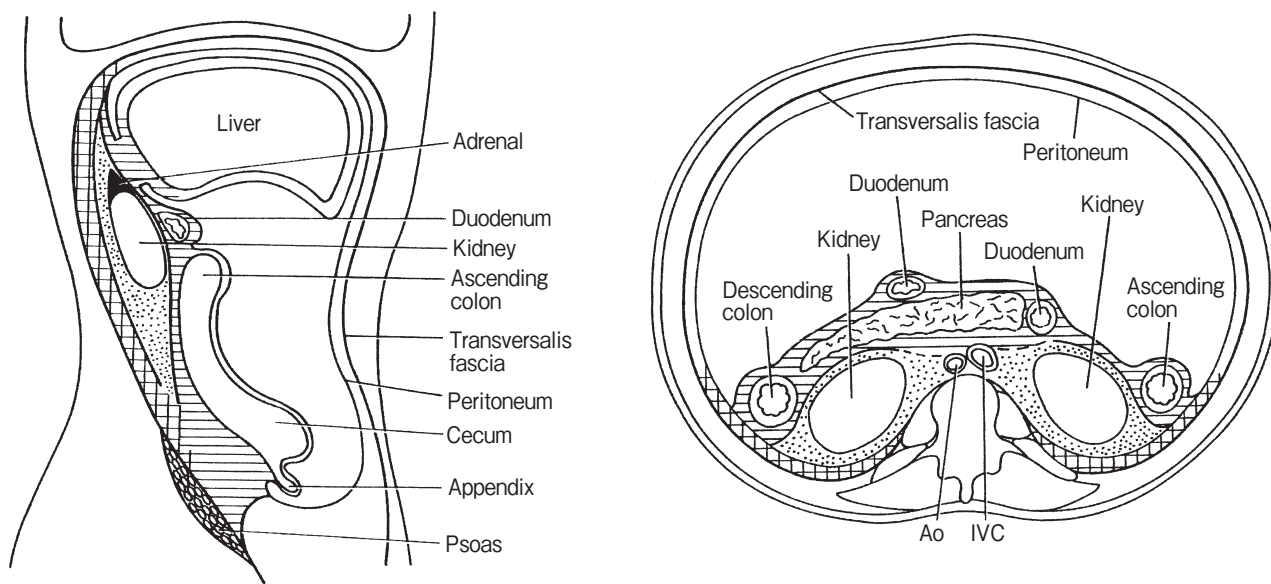


Fig. 6 The three extraperitoneal compartments. Striped areas: anterior pararenal space, stippled areas: perirenal space, cross-hatched areas: posterior pararenal space.

- Complications of acute diverticulitis of the colon: improved early diagnosis with computerized tomography. *Am J Surg* (1988) 155: 331-336.
3. Nakagawa N: Radiographic diagnosis of gastrointestinal perforation: usefulness of computed tomography. *Gazouigakushi (Jpn J Med Imaging)* (1988) 7: 34-45 (in Japanese).
  4. Makino K, Morikawa M, Mori M, Kohzaki S, Amamoto Y, Matsuoka Y, Nagaoki K and Hayashi K: CT findings of non-traumatic colorectal perforation. *Nihon Igaku Houshasen Gakkaizasshi (Nippon Acta Radiologica)* (1999) 59: 510-515 (in Japanese).
  5. Drummond H: Sacculi of the large intestine, with special reference to their relations to the blood-vessels of the bowel wall. *Br J Surg* (1916) 4: 407-413.
  6. Slack WW: Diverticula of the colon and their relation to the muscle layers and blood vessels. *Gastroenterology* (1960) 39: 708-712.
  7. Stollman NH and Raskin JB: Diagnosis and management of diverticular disease of the colon in adults. *Am J Gastroenterol* (1999) 94: 3110-3121.
  8. Bell JW: Intramesenteric perforation of colon diverticulitis. *Arch Surg* (1971) 102: 471-473.
  9. Juler GL, Dietrick WR and Eiseman JI: Intramesenteric perforation of sigmoid diverticulitis with nonfatal venous intravasation. *Am J Surg* (1976) 132: 653-656.
  10. Castleman B and McNeely BU: Case records of the Massachusetts general hospital presentation of case 59-1964. *N Engl J Med* (1964) 271: 1266-1269.
  11. Jensen JA, Tsang D, Minnis JF, Ponn T and Merrell RC: Pneumopylephlebitis and intramesocolic diverticular perforation. *Am J Surg* (1985) 150: 284-287.
  12. Murakami M, Ishida F, Ohta S, Ichihashi T, Iida S and Nakagawara G: A case of intramesenteric penetration of the sigmoid colon diverticulum. *Nihon Gekakei Rengou Gakkaishi (J Japanese College of Surgeons)* (2002) 27: 784-787 (in Japanese).
  13. Kato K, Kanazumi N, Ito F, Suzuki Y, Kimura J and Ishii M: A case of intramesenteric perforation of the sigmoid colon presented with inguinal and scrotal abscess. *Nihon Rinsyou Geka Gakkaizasshi (J Jpn Surg Assoc)* (2003) 64: 687-691 (in Japanese).
  14. Puglisi BS, Kauffmann HM, Stewart ET, Dodds WJ, Adams MB and Komorowski RA: Colonic perforation in renal transplant patients. *Am J Roentgenol* (1985) 145: 555-558.
  15. McPhedran NT: Rupture of the colon in the absence of any pathological abnormality. *Can J Surg* (1964) 7: 293-296.
  16. Itoh S, Kubo A and Yamanouchi T: A case report of intramesocolic abscess caused by penetration of a sigmoid diverticulum. *Nihon Syokakigeka Gakkaizasshi (Jpn J Gastroenterol Surg)* (1993) 26: 962-966 (in Japanese).
  17. Brearley R: Spontaneous perforation of the colon due to alkaline medication. *Br Med J* (1954) 1: 743.
  18. Hunt T: Diverticular disease of the colon. *Spectrum international* (1969) 13: 33-38.
  19. Sagoh T, Sakai T, Arizono S, Yamada A, Negoro Y and Noguchi M: CT findings and pitfalls in acute abdomen: peritonitis, hemoperitoneum, and retroperitoneal disease *Gazoushinndann (Jpn J Diagnostic Imaging)* (2004) 24: 587-600 (in Japanese).
  20. Azuma A, Ashizawa T, Sekine H and Hashimoto D: A case of idiopathic retroperitoneal perforation of the sigmoid colon diagnosed by CT scan. *Nihon Rinsyou Gakkaizasshi (J Jpn Surg Assoc)* (2006) 67: 1148-1152 (in Japanese).
  21. Meyers MA: Radiological features of the spread and localization of extraperitoneal gas and their relationship to its source. An anatomical approach. *Radiology* (1974) 111: 17-26.
  22. Meyers MA: The three extraperitoneal compartments; in *Dynamic radiology of the abdomen: normal and pathologic anatomy*, 1st Ed, Springer-Verlag, New York Heidelberg Berlin (1976) pp 118.
  23. Crepps JT, Welch JP and Orlando R 3rd: Management and outcome of retroperitoneal abscess. *Ann Surg* (1987) 205: 276-281.
  24. Greca GL, Racalbutto A, Greco L, Aronica G, Fraggetta F, Cataldo AD and Licata A: Retroperitoneal abscesses-rare causes and atypical manifestations: report of two cases. *Surg Today Jpn J Surg* (1995) 25: 965-969.