

Acta Medica Okayama

Volume 17, Issue 3

1963

Article 4

JUNE 1963

Absorption of fatty acid-iron from the intestine

I. Absorption of iron after a single oral
administration of fatty acid-iron

Toshio Amano*

*Okayama University,

Copyright ©1999 OKAYAMA UNIVERSITY MEDICAL SCHOOL. All rights reserved.

Absorption of fatty acid-iron from the intestine

I. Absorption of iron after a single oral administration of fatty acid-iron*

Toshio Amano

Abstract

It has been indicated that, when fatty acid iron is administered orally, the iron compound is split into iron and fatty acid and absorbed by different mechanisms.

Acta Med. Okayama. 17, 139—146 (1963)

ABSORPTION OF FATTY ACID-IRON FROM THE INTESTINE

I. ABSORPTION OF IRON AFTER A SINGLE ORAL ADMINISTRATION OF FATTY ACID-IRON

Toshio AMANO

*Department of Pathology, Okayama University Medical School
(Director: Prof. Satimaru Seno)*

Received for publication, July 25, 1963

Daily uptake of iron in human individual is calculated to be the amount of 0.6—1.5 mg^{1,2}. and thus it counterbalances the amount of iron consumed or lost each day. Main features of the iron metabolism are that the absorption of iron is difficult and the amount of iron excreted is extremely small, and in addition, the adjustment of both its absorption and excretion is also quite difficult. Under normal conditions oral administration of a large amount of iron does not bring about its excessive absorption nor would there occur an immediate absorption of iron in sufficient amount under anemic state with marked iron deficiency. The absorption of iron has been explained by the transformation mechanism of ferritin-apoferritin as expounded in Granick's mucosal block theory³⁻⁶, but WÖHLER *et al.*⁷ have proved that, even when ferritin is in a saturated state, the iron absorption proceeds without any relation to this state, and furthermore, SAITO⁸ and WASHINO⁹ have demonstrated the pathway of iron absorption having hemosiderin as its intermediate product. Hence Granick's theory is at present destined to be discarded.

From the observation¹⁰ that the iron absorption is inhibited in the case of steatorrhea, the author has assumed that fats or fatty acids play an indispensable role in the iron metabolism. Under this assumption an attempt has been made to see how fatty acid iron, the compound of ferric iron and fatty acid prepared by hydrolysis of corn oil, would be absorbed from the intestine. In the first report are presented the results of observations on the iron absorption after a single oral administration of fatty acid iron.

MATERIALS AND METHODS

For the experiment 10 hybrid male rats weighing about 150 g were employed. These animals were fasted for 24 hours by giving only iron besides water. The oral administration of iron was done with Nélatons' catheter (No. 4). Fatty acid iron was mixed with an equal volume of corn oil and 1 ml of the

mixture (containing 25 mg of iron) was introduced into the stomach at a time, and at the intervals of 30 min, 90 min, 3 hr, and 5 hr, two animals each to the total of 8 animals were sacrificed and simultaneously the remaining two animals as the control group, kept fasting but not given the iron compound, were killed 24 hr later. The intestines were taken out and cut into five pieces starting from the duodenum to the caecum of these animals. Also the liver and spleen were removed and fixed in neutral formalin and frozen sections were prepared. Observations of the absorption of fat and iron were conducted under light microscope on the specimens stained with Sudan black B for lipids and Berlin blue for iron. On the other hand, the tissue pieces of the intestines similarly obtained were fixed in 1 % osmium tetroxide and embedded in methacrylate resin and ultrathin sections prepared from these tissues were observed under the electron microscope (Hitachi HU-11 Model).

The fatty acid iron to be used in the experiment is prepared as follows: To 100 ml corn oil 600 ml of the solution of sodium hydroxide dissolved in absolute alcohol (containing 15 g sodium hydroxide) is added, and the corn oil is saponified for two hr at 78°C. The saponified corn oil is salted out by adding sodium chloride solution, and the dissolution in water and the salting-out processes are repeated several times in order to remove nonsaponified substances, glycerin and other impurities. The aqueous solution of the saponified substance thus obtained is mixed with 10 % ferric chloride while heating and when the solution is kept slightly acidic, fatty acid iron of a brown color floats up. This is taken up and washed with distilled water several times, and after adding ether it is filtered by a funnel. Ether is removed by evaporation. The fatty acid iron thus prepared contains about 50 mg of iron in 1 ml and it is a brown liquid which is insoluble in water, scarcely soluble in alcohol but is soluble in ether, and when it comes in contact with acidic solution, it readily dissociates iron ions.

RESULTS

When the intestinal sections stained with Sudan black B are observed under a light microscope, there can be seen a few droplets of Sudan positive substance in the cytoplasm between the free surface and the nucleus of epithelial cells 30 minutes after the administration of fatty acid iron and from one and half hours to 3 hours later the number of these droplets increases occupying the entire cytoplasm of the epithelial cell and even the center of villi is occupied by this Sudan positive substance. Five hours later, however, the Sudan positive substance within the epithelial cell is diminished. At an early stage the Sudan positive substance can be observed only in the epithelial cells at the apex of villi but it gradually spreads out to the entire epithelial cells of the villi. Such a picture can be demonstrated in the major portion of the duodenum and

jejunum. In the control kept fasting for 24 hours Sudan positive substance can hardly be recognized. In the electron microscope observation of ultrathin section of intestinal epithelium from animal 30 minutes after the administration of fatty acid iron with corn oil, round fat droplets of about 100 m μ in size can be seen in the cavities of the ER in cytoplasm facing the intestinal lumen, the droplets increase in number by one and half hours later, some of the droplets are fused forming larger and markedly irregular ones and finally the epithelial cells are filled with the droplets. At this stage the fat droplets can also be observed between the cells as well as in the lacteal vessels. What is striking in this instance is, as PALAY¹¹ has pointed out, the finding that the droplets within the epithelial cell are surrounded by endoplasmic membrane. Those droplets found in between the cells and in the lacteal vessel, however, have no membrane. In the brushborder of the epithelial cell, which PALAY has observed as the picture of the fat absorption at its initial stage, no such droplets can be detected.

There is no difference in the findings of the liver and spleen after Sudan black staining between the test animals and the control.

Histologic observation of the intestinal tissue stained with Berlin blue reaction revealed the diffusely-stained epithelial cells at the apex of villi of the duodenum or extremely fine blue granules in the cytoplasm of epithelial cells at the apex of villi already 30 minutes after the oral administration of iron compound. Three hours afterward, the epithelial cells at the villous apex respond more intensely than in the former case and the central part of villi likewise shows iron reaction. In addition, iron granules can be seen even in the interstitium under the epithelial cells and in the lymph apparatus of the mucosa. Five hours afterward, iron in the epithelial cells appears in granules of a small amount but there can be recognized no more diffuse staining and iron granules in the interstitium are increased somewhat in number. The absorption picture of iron in the epithelial cells mentioned in the foregoing is practically all localized at the apex of villi, and this is mainly localized in the duodenum, and the similar picture can hardly be observed in the intestinal tract below the duodenum.

As for the findings of the liver sections stained with Berlin blue, even 3 hours after the iron administration a very slight iron reaction can be observed diffusely on the liver parenchymal cells around lobules, especially in the area surrounding the portal veins. In Kupffer cells located near the parenchymal cells that show iron reaction, there can be seen a minimal amount of fine iron granules. In the spleen, there can be recognized a slight increase of iron in the splenic pulp, peripheral and central regions of follicles, and the iron is marked in the peripheral area of the follicles.

SUMMARY AND DISCUSSION

By the analysis of the iron compound obtained by aforementioned methods, assuming the number of carbon of the fatty acid, which comprises the principal component of corn oil, to be 18, it gives the ratio of Fe : RCOOH = 1 : 3 (molecular ratio) and the chemical structure, R-COO-Fe-OOCR can be deduced.



It has a solubility somewhat similar to neutral fat to the fat solvent. Therefore, if there is a possibility of a neutral fat being absorbed per se, as PALAY¹¹ states, there is a great possibility that this fatty acid iron is absorbed per se. This may explain how fatty acid is associated with the iron absorption. The intestinal tissue stained with Sudan black B after the administration of fatty acid iron gives the picture rather similar to the fat absorption picture as observed by BAKER^{12,13} and HEWITT^{14,15}. Even in the electron microscope picture, the findings similar to those of PALAY¹¹ and THOMAS¹⁶ after oral administration of corn oil are obtained. On the other hand, it has not been possible to obtain the findings that substantiate the passage of fat droplets through the brushborder of intestinal epithelial cells as shown by BAKER and PALAY to confirm histologically Frazer's theory¹⁷⁻²² that fat is taken up by the epithelial cells of the intestines in a fine droplet form. Supposing that fat is absorbed by the mechanism as stated by FRAZER, it is reasonable to assume that fatty acid iron would be absorbed by a similar mechanism and hence iron can be taken up in abundance by the intestinal tract where the iron uptake is considered to be quite difficult. Actually, however, the findings of the intestinal tissues stained with Berlin blue give the results that contradict this assumption. Namely, whereas fat is absorbed by almost the entire area of the duodenum and jejunum²³ and also by the epithelial cells of the entire villi, the absorption of iron in the intestinal tract is limited almost completely in the duodenum and that locally in the epithelial cells of the apex of villi, as observed histologically by SCHMIDT^{24,25}, IWAO²⁶ and GILLMAN²⁷, suggesting that fatty acid iron is split into iron and fatty acid prior to their absorption in the intestine and each is absorbed by a different mechanism. BUNGE²⁸ claimed that iron is most readily absorbed in its organic form. This supposition was refuted by later experiments of SCHMIDT and others, but there arose a new problem when PALAY again observed the possibility of iron combined with fatty acid passing the intestinal tract. However, the experiment again contradicts this supposition, and ever since the report of HEUBNER²⁹ in 1924 to the effect that iron in the ferrous state only can be absorbed by the body passing through the mucous membrane of the digestive canal³⁰⁻³², this mechanism of iron absorption is indirectly explained at present. On the other hand, it seems that the present results indicate a possibility of fat itself being decomposed to fatty acid and

glycerin at the time of its absorption.

CONCLUSION

It has been indicated that, when fatty acid iron is administered orally, the iron compound is split into iron and fatty acid and absorbed by different mechanisms.

REFERENCES

1. MOORE, C. V. and DUBACH, R.: Observation on the absorption of iron from foods tagged with radioiron. *Trans. Assoc. Am. Physicians.* 64, 245, 1951
2. CHODES, R. B. *et al.*: The absorption of radioiron labeled foods and iron salts in normal and iron deficient subjects and in idiopathic hemochromatosis. *J. Clin. Invest.* 36, 314, 1957
3. GRANICK, S.: Ferritin IX. The function of ferritin in the regulation of iron absorption. *J. Biol. Chem.* 164, 737, 1946
4. GRANICK, S.: Ferritin its properties and significance for iron metabolism. *Chem. Rev.* 38, 373, 1946
5. GRANICK, S.: Iron metabolism and hemochromatosis. *Bull. New York Acad. Med.* 25, 403, 1949
6. GRANICK, S.: Iron metabolism. *Bull. New York Acad. Med.* 30, 81, 1954
7. WÖHLER, F. *et al.*: Zur Funktion des Ferritin bei der Eisenresorption. *Arch. exper. Path. u. Pharmacol.* 230, 107, 1957
8. SAITO, H.: Storage iron and transferrin. *Acta Haem. Jap.* 23, 349, 1960
9. WASHINO, N.: Iron absorption in relation to hemosiderin and ferritin in the gastrointestinal mucosa. *Acta Haem. Jap.* 22, 390, 1959
10. BADENOCH, J. and CALLENDER, S. L.: Iron metabolism in steatorrhea, the use of radioactive iron in studies of absorption and utilization. *Blood.* 9, 123, 1954
11. PALAY, S. L. and KARLIN, L. J.: An electron microscopic study of the intestinal villus, II. The pathway of fat absorption. *J. Biophysic. and Biochem. Cytol.* 5, 373, 1959
12. BAKER, J. R.: The histochemical recognition of lipine. *Quart. J. Micr. Sc.* 87, 441, 1946
13. BAKER, J. R.: The observation of lipid by the intestinal epithelium of the mouse. *Quart. J. Micr. Sc.* 92, 79, 1951
14. HEWITT, W.: A histochemical study of fat absorption in the small intestine of the rat. *Quart. J. Micr. Sc.* 95, 153, 1954
15. HEWITT, W.: Further observations on the histochemistry of fat absorption in the small intestine of the rat. *Quart. J. Micr. Sc.* 97, 199, 1956
16. THOMAS, W. A. and O'NEAL, R. M.: Electron microscopy studies of butter and corn oil in jejunal mucosa. *A. M. A. Arch. Path.* 69, 121, 1960
17. FRAZER, A. C.: The absorption of triglyceride fat from the intestine. *Physiol. Rev.* 26, 103, 1946
18. FRAZER, A. C.: Transport of lipid through cell membranes. *Symp. Soc. Exp. Biol.* 8, 490, 1954
19. FRAZER, A. C.: Mechanism of intestinal absorption of fat. *Nature.* 175, 491, 1955
20. FRAZER, A. C.: Fat absorption and its disorders. *Brit. Med. Bull.* 14, 212, 1958
21. FRAZER, A. C.: Further studies on the mechanism of fat absorption. *Biochemistry of Lipids*, edited by G. Popják, Pergam. Press p.47, 1960
22. FRAZER, A. C.: Fate of dietary fat in the body. *Nature.* 194, 908, 1962

23. BORGSTRÖM, B. *et al.*: Studies of intestinal digestion and absorption in the human. *J. Clin. Inv.* 36 (II), 1521, 1957
24. SCHMIDT, M. B.: Der Einfluss eisenarmer und eisenreicher Nahrung auf Blut und Körper. Fischer, Jena. 1928
25. SCHMIDT, M. B.: Störungen des Eisenstoffwechsels und ihre Folgen. *Ergeb. d. allg. Path. u. Pathol. Anat.* 35, 105, 1940
26. IWAO, T. and Kurihara, M.: Histological observation of iron absorption in the intestine of rabbit. *Trans. Soc. Path. Japan.* 23, 196, 1933
27. GILLMAN, T. and ANDREW, C. I.: A histological study of the participation of the intestinal epithelium, the reticulo endothelial system and the lymphatics in iron absorption and transport. *Gastro.* 9, 162, 1947
28. BUNGE, G.: Über die Assimilation des Eisens. *Hoppe-Seylers Z.* 9, 49, 1885
29. HEUBNER, W.: Bemerkungen zur Eisentherapie. *Z. Klin. Med.* 100, 675, 1924
30. STARKENSTEIN, E.: Eisen, Heffters Handbuch d. exptl. Pharmakol. 3, H2, p. 683, 1934
31. KIRCH, E. R. *et al.*: Reduction des Fe durch Nahrungsmittel bei künstlicher Magenverdauung. *J. Biol. Chem.* 171, 687, 1947
32. SENO, S. *et al.*: Iron and hemoglobin metabolism, I. Studies on the absorption of iron. *J. Mie Med. College.* 1, 11, 1950

Explanation for Photos

Photo Plate 1. A section of jejunum stained with Sudan black B, from animal received the oral administration of the fatty acid iron with corn oil, 30 minutes after administration. The picture shows numerous Sudan positive granules in the epithelial cells.

Photo Plate 2. A section of duodenum stained with Berlin blue, from animal received the oral administration of the fatty acid iron with corn oil, 3hr after administration. There can be observed diffuse and fine granular iron localized at the apex of villi and also they can be recognized in the interstitium. The site of iron deposition does not coincide with that of fat.

Photo Plate 3. An electron microgram of the jejunum, from the animal received the oral administration of fatty acid iron with corn oil, 30 minutes after administration. At the upper left the brushborder of epithelial cell appears and numerous fat droplets can be seen in the cytoplasm of epithelial cell.

Photo Plate 4. An electron microgram of the jejunum, from the animal received the oral administration of fatty acid iron with corn oil, 1.5 hr after administration. By this stage fat droplets can be observed in the interspaces between the epithelial cells.



Plate 1.

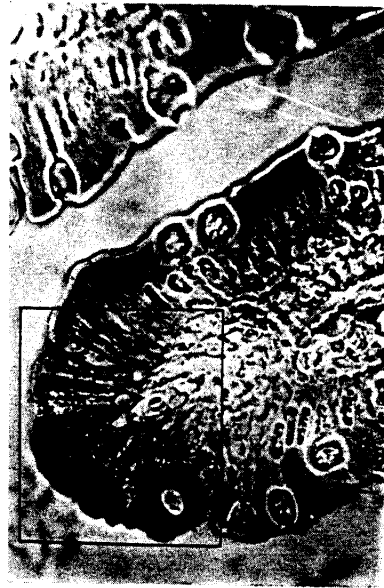

Plate 2.

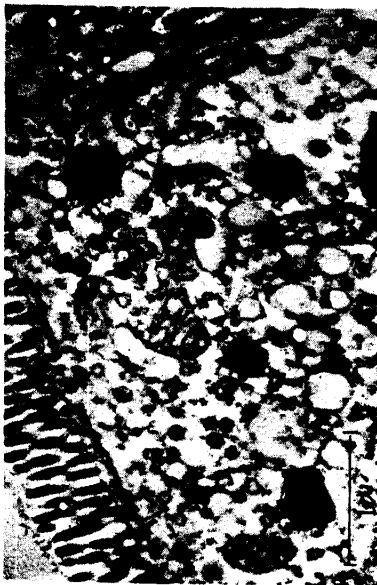


Plate 3.

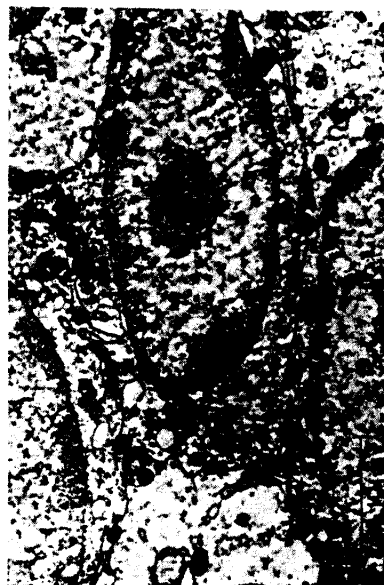

Plate 4.