

Acta Medica Okayama

Volume 45, Issue 2

1991

Article 7

APRIL 1991

Effect of a long-acting somatostatin analogue (SMS 201-995) on a growth hormone and thyroid stimulating hormone-producing pituitary tumor.

Ryoto Hirasawa*

Hozo Hashimoto†

Shinya Makino‡

Shuso Suemaru**

Toshihiro Takao††

Zensuke Ota‡‡

Yoshihiko Hoshida§

Tadashi Yoshino¶

Tadaatsu Akagi||

*Okayama University,

†Okayama University,

‡Okayama University,

**Okayama University,

††Okayama University,

‡‡Okayama University,

§Okayama University,

¶Okayama University,

||Okayama University,

Effect of a long-acting somatostatin analogue (SMS 201-995) on a growth hormone and thyroid stimulating hormone-producing pituitary tumor.*

Ryoto Hirasawa, Hozo Hashimoto, Shinya Makino, Shuso Suemaru, Toshihiro Takao, Zensuke Ota, Yoshihiko Hoshida, Tadashi Yoshino, and Tadaatsu Akagi

Abstract

A 46-year-old woman with acromegaly and hyperthyroidism due to a pituitary adenoma. She had high serum thyroid-stimulating hormone (TSH) levels and very high serum growth hormone (GH) levels. Transsphenoidal removal of the tumor, post-operative irradiation, frontal craniotomy for removal of residual tumor and large-dose bromocriptine therapy were carried out consecutively. After therapy, serum GH levels gradually decreased, but not to the normal range, and serum TSH levels remained at inappropriately normal levels. Using immunoperoxidase techniques, GH-, TSH- and follicle-stimulating hormone (FSH)-containing cells were demonstrated in the adenoma. A long-acting somatostatin analogue (SMS 201-995, 600 micrograms/day) suppressed the serum GH level to the normal range with a concomitant suppression of TSH. Furthermore, the paradoxical serum GH responses to TRH and LH-RH were slightly improved. No important subjective side-effects were noted. Therefore, SMS 201-995 appeared to be a very effective drug in this patient with a GH- and TSH-producing pituitary tumor.

KEYWORDS: TSH- and GH - producing pituitary adenoma, acromegaly, hyperthyroidism, somatostatin analogue (SMS 201-995)

*PMID: 1867112 [PubMed - indexed for MEDLINE]

Effect of a Long-Acting Somatostatin Analogue (SMS 201-995) on a Growth Hormone and Thyroid Stimulating Hormone-Producing Pituitary Tumor

Ryuto Hirasawa*, Koza Hashimoto, Shinya Makino, Shuso Suemaru, Toshihiro Takao, Zensuke Ota, Yoshihiko Hoshida^a, Tadashi Yoshino^a and Tadaatsu Akagi^a

Third Department of Internal Medicine and ^aSecond Department of Pathology, Okayama University Medical School, Okayama 700, Japan.

A 46-year-old woman with acromegaly and hyperthyroidism due to a pituitary adenoma. She had high serum thyroid-stimulating hormone (TSH) levels and very high serum growth hormone (GH) levels. Transsphenoidal removal of the tumor, post-operative irradiation, frontal craniotomy for removal of residual tumor and large-dose bromocriptine therapy were carried out consecutively. After therapy, serum GH levels gradually decreased, but not to the normal range, and serum TSH levels remained at inappropriately normal levels. Using immunoperoxidase techniques, GH-, TSH- and follicle-stimulating hormone (FSH)-containing cells were demonstrated in the adenoma. A Long-acting somatostatin analogue (SMS 201-995, 600 μ g/day) suppressed the serum GH level to the normal range with a concomitant suppression of TSH. Furthermore, the paradoxical serum GH responses to TRH and LH-RH were slightly improved. No important subjective side-effects were noted. Therefore, SMS 201-995 appeared to be a very effective drug in this patient with a GH- and TSH-producing pituitary tumor.

Key words: TSH- and GH-producing pituitary adenoma, acromegaly, hyperthyroidism, somatostatin analogue (SMS 201-995)

Current treatment of GH- and /or TSH-secreting pituitary adenomas involves surgical removal of the adenoma, tumor irradiation and oral administration of the dopamine agonist, bromocriptine (1-10). Even with such treatment, attempts to decrease tumor GH and TSH secretion have proven unsuccessful in some cases. Somatostatin (SRIH) has been shown to reduce GH and/or TSH secretion in patients with GH- and TSH-secreting pituitary adenomas (6, 11).

Recently, a long-acting somatostatin analogue, SMS 201-995 (Sandoz Ltd., Basale, Switzerland), became available for clinical use (12, 16). We used SMS 201-995 in a patient with an invasive mixed (TSH, GH and FSH) pituitary adenoma who had undergone partial surgical removal and irradiation.

Subject and Methods

* To whom correspondence should be addressed.

In December 1974, a 32-year-old woman referred to

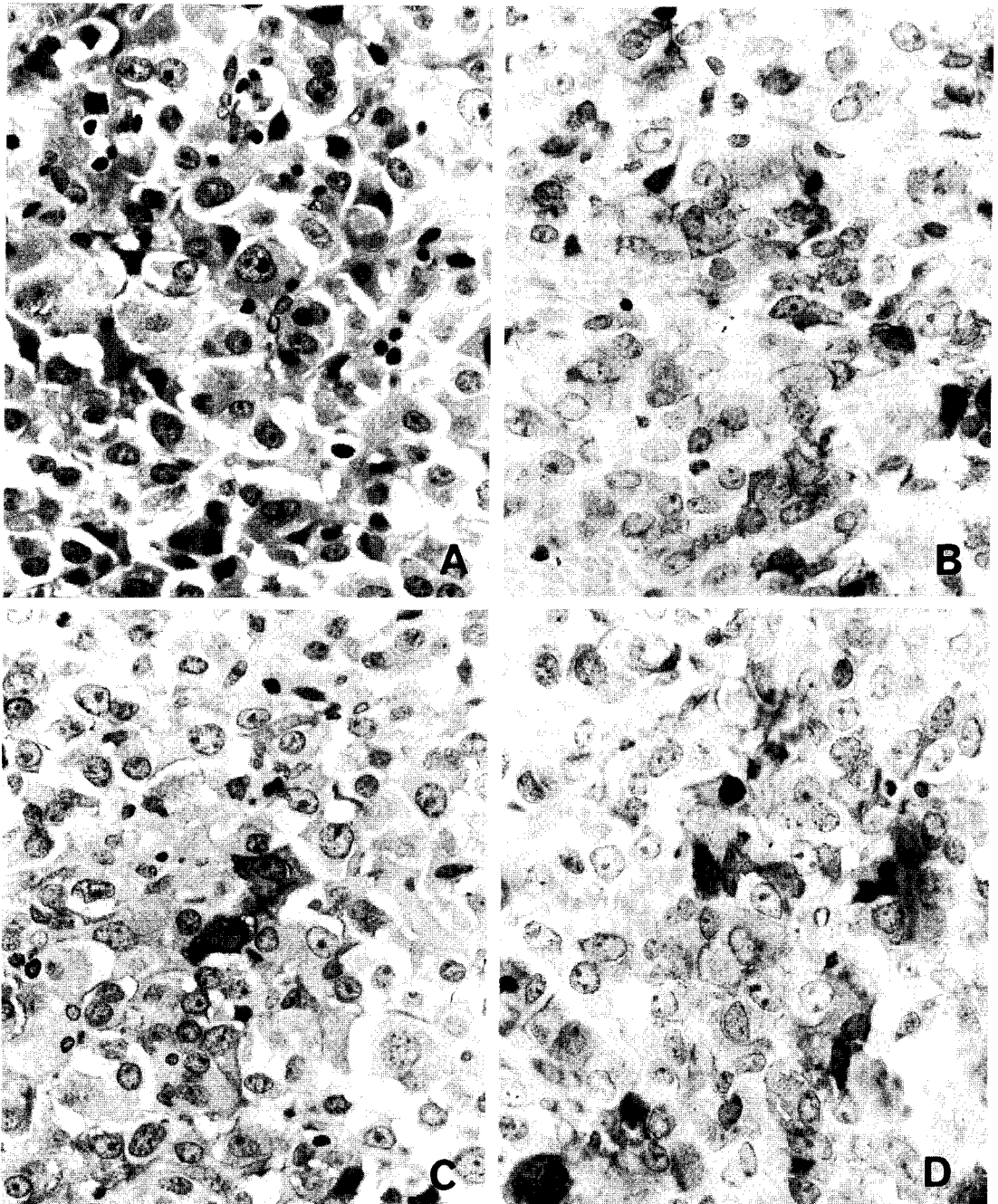


Fig. 1 Examination of the tumor removed.

A. Hematoxylin-eosin staining (original $\times 400$)

B. Corresponding area stained for growth hormone (GH) by the immunoperoxidase technique. Note the positive cytoplasmic reaction for GH in some of the adenoma cells (original $\times 400$)

C. Thyroid-stimulating hormone (TSH) immunostaining (original $\times 400$)

D. Follicle-stimulating hormone (FSH) immunostaining (original $\times 400$)

our hospital with suspected acromegaly and hyperthyroidism. For several years prior to that, she had noticed an increase in the size of her toes, and protrusion of her mandible was pointed out by her dentist. Physical examination revealed the typical signs of acromegaly and homogeneous enlargement of the thyroid, but exophthalmus was not present. A visual fields test showed bitemporal hemianopsia. X-rays showed an enlarged and destroyed sella turcica.

Initial endocrine studies confirmed the diagnosis of thyrotoxicosis and acromegaly. The serum GH levels were markedly elevated (755 ng/ml) and serum TSH levels were increased with the increased serum T4 and T3. Anti-thyroglobulin antibody (TGHA) and anti-microsome antibody (MCHA) were negative, as was thyrotropin receptor antibody. Baseline serum prolactin and FSH (5.4 mIU/ml) level were normal. These findings raised the suspicion of a pituitary tumor producing not only GH but also TSH, which caused secondary

thyrotoxicosis. The patient underwent transsphenoidal surgery with post-operative radiation (40 Gy) in 1975. The treatment reduced serum GH levels to 140 ng/ml. However, neither further reduction of serum GH nor suppression of TSH was observed. Furthermore, TSH hypersecretion persisted. In 1976, she underwent a frontal craniotomy to remove residual tumor. The formaldehydefixed and paraffin-embedded tissue block was subjected to indirect immunoperoxidase staining (Dako Co., USA) for immunohistochemical identification of anterior pituitary hormones in the adenomatous tissue (Fig. 1). It was suggested that this tumor produced GH, TSH, and FSH, but FSH secretion by this tumor did not evoke serum FSH elevation. Propylthiouracil (PTU) was administered, and serum T3 and T4 were normalized, but inappropriately high or normal serum TSH levels continued. Bromocriptine was administered in doses of 2.5 mg/day to 20 mg/day. However, GH hypersecretion persisted. Fig. 2 shows the changes in serum GH and

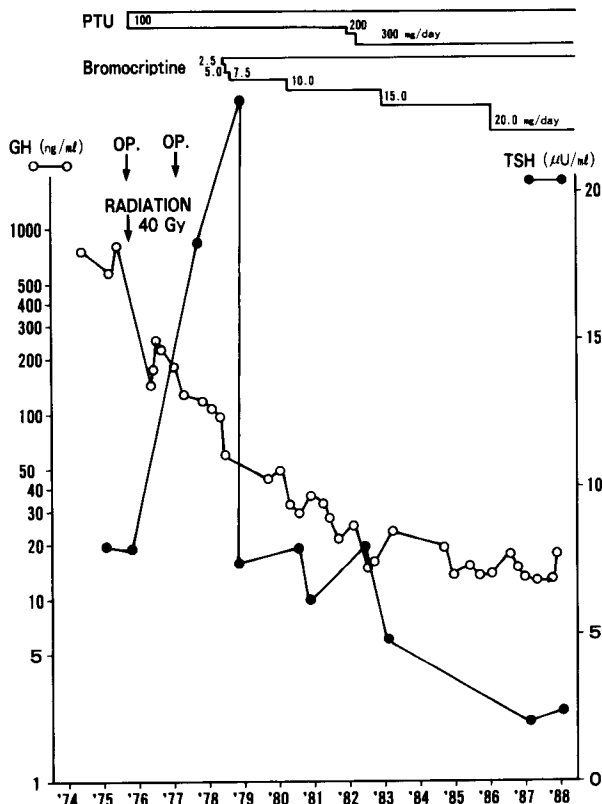


Fig. 2 Serum GH and TSH levels from the first visit to the present admission. Abbreviations: See Fig 1.

TSH levels during the clinical course from the first visit. Hydrocortisone (25 mg per os) replacement for postoperative secondary adrenal hypofunction has continued since the first operation.

She was admitted to our hospital in January of 1988 in order to attempt the therapy with the long-acting somatostatin analogue SMS 201-995.

The entrance physical examination recorded her height as 147.7 cm, body weight as 63.5 kg, and blood pressure as 104/64 mmHg. The initial hospital examination indicated a red cell count of $410 \times 10^4/\text{mm}^3$, white cell count of $2700/\text{mm}^3$ and platelet count of $18.6 \times 10^4/\text{mm}^3$. Urinalysis showed no abnormalities. Serum Na, K, Cl, Ca and P were within normal limits. Blood chemistry showed serum GOT 26 IU/l, GPT 37 IU/l, Alkaline phosphatase 95 IU/l, LDH 725 IU/l, CPK 144 IU/l, blood urea nitrogen 4.6 mg/ml, creatinine 0.72 mg/ml, fasting blood sugar 78 mg/dl, cholesterol 263 mg/dl and triglycerides 93 mg/dl.

Hormone assays and examinations. All hormones were measured with commercially available radioimmunoassay (RIA) kits (GH: Pharmacia hGH RIA, Pharmacia Diagnostic Co., Sweden; TSH, PRL: RIABEAD 2, Dinabot Co., Japan; Cortisol, LH, FSH: cortisol kit, LH kit, FSH kit, Dai-ichi Radioisotope Labs., LTD, Tokyo, Japan; ACTH-RIA kit, CEA-IRE-Sorin, Gif-sur-Yvette, France; Somatomedin C, Otsuka Assay Laboratories, Japan).

A TRH infusion test was performed by bolus intravenous (iv) injection of $500 \mu\text{g}$ TRH, and blood samples were collected for TSH, PRL and GH assay at 0, 30, 60, 90, and 120 min. A luteinizing hormone-releasing hor-

none (LHRH) infusion test was performed by iv bolus injection of $100 \mu\text{g}$ LHRH, and plasma LH, FSH and GH were measured.

Serum GH levels were measured after subcutaneous (sc) administration of $50 \mu\text{g}$ of SMS 201-995 and after oral administration of 2.5 mg bromocriptine. Furthermore, a 24-h profile of serum GH levels was determined after 7 days treatment with 150, 300 and $600 \mu\text{g}$ of SMS 201-995.

Treatment protocol. We first treated the patient with sc injections of $50 \mu\text{g}$ SMS 201-995 three times (9:00, 16:00 and 21:00) per day. The injected dose of SMS 201-995 was then increased to 100 and $200 \mu\text{g}$ three times a day.

Radiological evaluation. Tumor size was examined before and 1 and 2 months after starting treatment by high resolution computerized tomography (CT) and magnetic resonance imaging (MRI).

Results

Table 1a. shows the basal hormone levels of the patient at the time of admission for SMS 201-995 therapy. The serum GH and somatomedin C levels were elevated as shown in Table 1b., thyroid ^{131}I uptake was 56.9% at 24h, and the T3 suppression test showed no response in ^{131}I uptake or serum TSH level. Basal serum prolactin, LH, and FSH levels were normal.

A single sc administration of $50 \mu\text{g}$ SMS 201

Table 1a Basal hormone concentrations at the time of admission for SMS 201-995 therapy

Hormones	GH (ng/ml)	Sm-C (U/ml)	PRL (ng/ml)	LH (mIU/ml)	FSH (mIU/ml)
Values	17.5	<2.9	4.6	5.6	2.5

GH: growth hormone, Sm-C: somatomedin C, PRL: prolactin, LH: luteinizing hormone, FSH: follicle-stimulating hormone

Table 1b Thyroid function test at the time of admission for SMS 201-995 therapy

T3 (ng/dl)	T4 ($\mu\text{g}/\text{dl}$)	TSH ($\mu\text{U}/\text{ml}$)	TGHA	MCHA	TSAb	TBII	^{131}I uptake(%)	T3 suppression test
146.9	8.5	2.41	(-)	(-)	(-)	(-)	56.9	no response

T3: triiodothyronine, T4: thyroxine, TSH: thyroid-stimulating hormone, TGHA: anti-thyroglobulin antibody, MCHA: anti-microsome antibody, TSAb: thyroid-stimulating antibody, TBII: thyrotropin-displacing activity

-995 reduced serum GH levels by 75%. On the other hand, oral administration of 2.5 mg bromocriptine evoked an 18% decrease in the serum GH level. Twenty-four hour profiles of serum GH after 7 days treatment with 150, 300 and 600 μg ($50\mu\text{g} \times 3$, $100\mu\text{g} \times 3$, $200\mu\text{g} \times 3$) of SMS 201-995 are shown in Fig. 3a. Serum GH levels were suppressed more by SMS 201-995 than by bromocriptine, and the greatest suppression was observed after 600 μg SMS 201-995. TSH levels were suppressed more after SMS 201-995 treatment ($100\mu\text{g} \times 3/\text{day}$) than after administration of 20 mg bromocriptine (Fig. 3b).

When SMS 201-995 was increased to 600 μg ($200\mu\text{g} \times 3/\text{day}$), the somatomedin C levels and

the serum GH levels for 24 h fell to the normal range, except for the fasting serum GH level (Fig. 3a, Fig. 4). PTU treatment was stopped in order to evaluate the effect of SMS 201-995 on hypothalamic-hypophyseal-thyroid function. During SMS 201-995 treatment, serum T3, T4, and TSH levels remained within the normal range. However, serum T3 and T4 levels returned rapidly to high levels after SMS 201-995 treatment.

TRH and LHRH tests were performed both before and during SMS treatment ($100\mu\text{g}$, three times a day). Although the responses of serum TSH to TRH did not differ before and during SMS treatment, the serum prolactin response was

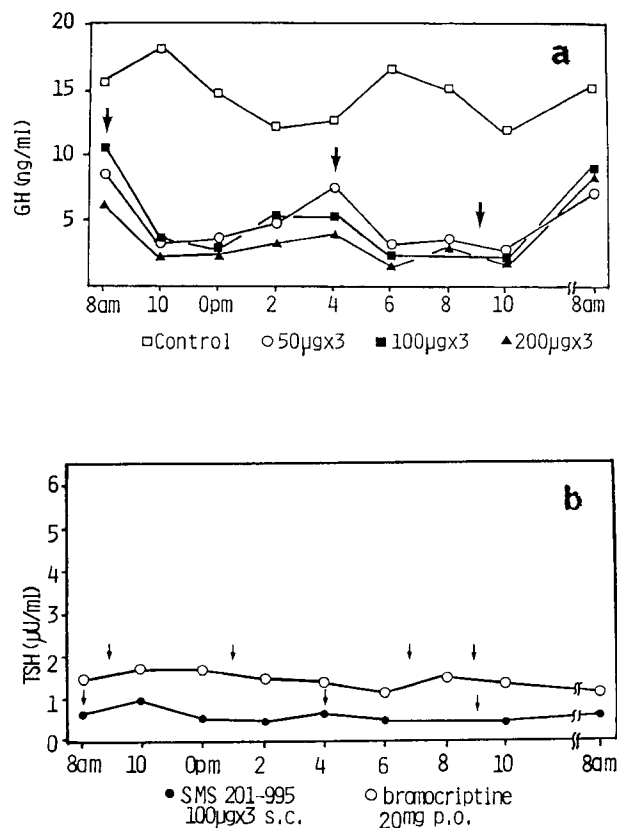


Fig. 3 Twenty-four hour profiles of serum GH and TSH levels.

- (a) Serum GH levels during SMS 201-995 treatment compared to bromocriptine treatment. Arrows indicate times treated with an sc injection of SMS 201-995. (\square) Control, (\circ) SMS $50\mu\text{g} \times 3$, (\blacksquare) $100\mu\text{g} \times 3$, (\blacktriangle) $200\mu\text{g} \times 3$, (\bullet) bromocriptine $5\text{mg} \times 4$
- (b) Serum TSH levels. Abbreviations: See Fig. 1. (\bullet) SMS 201-995: $100\mu\text{g} \times 3$, (\circ) Bromocriptine: $5\text{mg} \times 4$

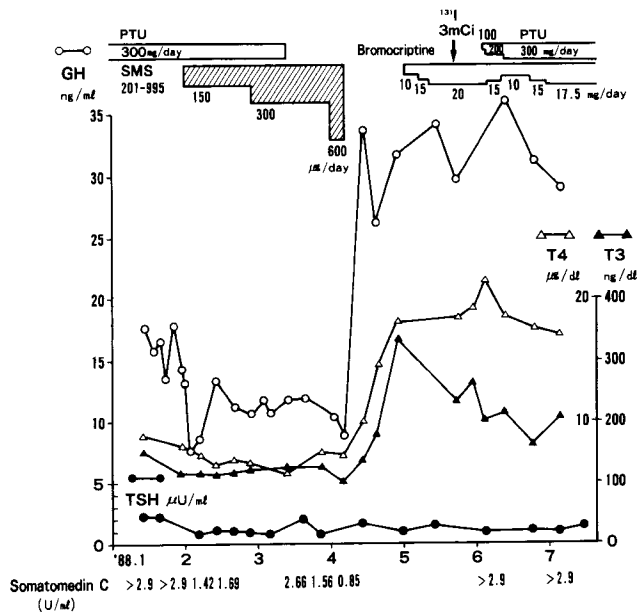


Fig. 4 Clinical course following admission in 1988. Blood samples were taken before breakfast.

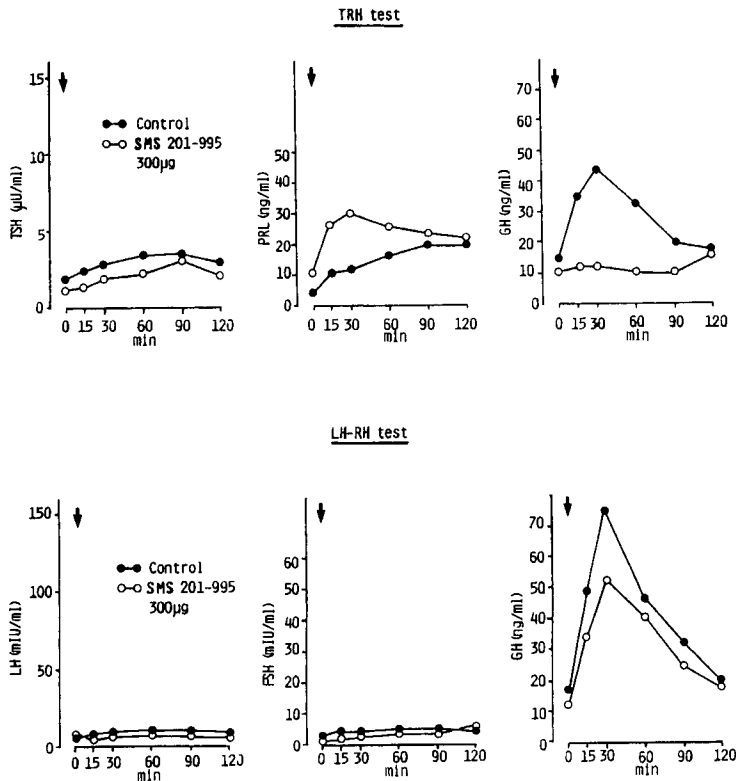


Fig. 5 TRH and LHRH test before and during SMS 201-995 treatment. (●), Control, (○)SMS 201-995: 100μg × 3

greater during therapy, and the paradoxical rise in serum GH after TRH disappeared during SMS treatment (Fig. 5). Serum LH and FSH responses to LHRH stimulation did not differ before and during therapy, while the paradoxical rise in serum GH improved slightly (Fig. 5).

A pituitary CT scan and a MRI scan performed 2 months after the beginning of treatment showed no remarkable changes in volume of residual adenomatous tissue. During SMS treatment, she had transient mild gastric discomfort and pain at the injection sites, however the pain disappeared when a new painless material was used. Gallstones were not detected by ultrasound echogram. Blood glucose and plasma insulin levels stayed within normal limits.

We had to stop SMS treatment as the drug supply was stopped. Shortly thereafter, the patient developed a relapse of her hyperthyroidism and serum GH hypersecretion. In May 1988, 3mCi of radioactive iodine was given and PTU administration was restarted. Bromocriptine was also given again to suppress GH hypersecretion and inappropriate TSH secretion. Serum GH levels continued to be elevated, and thyroid function was gradually normalized.

Discussion

Few cases of acromegaly and hyperthyroidism due to a GH- and TSH- secreting pituitary adenoma have been reported (1-10, 12, 17) since the first case was reported in 1969 (1). The patient described herein presented acromegaly and thyrotoxicosis with an inappropriately high serum TSH concentration due to a GH- and TSH-producing pituitary adenoma. Although this tumor contained FSH without serum FSH elevation, we can not conclude that it produced FSH without analyzing FSH m-RNA expression. Furthermore, it was not clarified whether GH, TSH, and FSH were produced by the same cells or by different ones, because we did not stain the sections continuously. It is also difficult to

explain why the serum TSH levels were elevated transiently after operations and radiation therapy.

SMS 201-995 altered GH secretion in these tumors, suggesting that GH-secreting pituitary adenomas have specific somatostatin receptors. It might also be expected that functional improvement would be followed by shrinkage of the adenoma, as has been found in other endocrine tumors, such as prolactinoma (18), VIPoma (WDHA syndrome) (19), gastrinoma (Zollinger-Ellison syndrome) (20), insulinoma (21), and glucagonoma (22). The clinical use of the long-acting somatostatin analogue SMS 201-995 adds a new dimension to the therapy of GH- or TSH-producing pituitary adenomas, which can not be cured by surgery, radiotherapy, and/or administration of a dopamine agonist (12-16). The effects of preoperative use of SMS 201-995 in acromegaly have been reported (23). Barkan *et al.* consistently observed that SMS rapidly induced pituitary tumor shrinkage; approximately 20-25% tumor shrinkage was evident 1 week after the start of therapy in some cases (23). Furthermore, SMS inhibits paradoxical GH secretion in patients with acromegaly (24, 25). Although SMS reduced basal GH levels, inhibited paradoxical TRH-stimulated GH secretion and tended to improve paradoxical LHRH-stimulated GH secretion in this patient, no significant reduction in tumor size was observed. We have considered a few possible reasons for this. Firstly, she was treated with SMS three times daily (26). Secondly, she was given relatively low doses. More frequent administration and larger doses of SMS 201-995 might have reduced the tumor size. Thirdly, previous therapy (surgery and radiation) might have prevented proper evaluation of the tumor size (23). After we stopped SMS treatment, serum GH levels increased again, possibly because the period of SMS administration was too short.

An inhibitory effect of somatostatin on TSH secretion has been documented (27). Recently, SMS treatment of inappropriate thyrotropin secretion, due to either a TSH-secreting pituitary

tumor or non-neoplastic resistance to thyroid hormone, has been reported (14–16). Long-term treatment with PTU and a large dose of bromocriptine controlled thyroid function within normal limits in the present patient. Although TSH secretion was suppressed by bromocriptine in this case, serum TSH concentration was reduced more by SMS treatment (100 μ g, three times a day) than by bromocriptine treatment (5 mg, four times a day).

In conclusion, SMS 201–995 may be a valuable therapeutic agent for the management of patients with GH- and TSH- secreting pituitary adenomas, although further studies are necessary to confirm this.

References

- Lamberg BA, Ripatti J, Gordin A, Juustila H, Sivula A and Bjorkestén G: Chromophobe pituitary adenoma with acromegaly and TSH hyperthyroidism associated with parathyroid adenoma. *Acta Endocrinol (Copenh)* (1969) **60**, 157–172.
- Linquette M, Herlant M, Fossati P, May JP, Decoulx M and Fourlinnie JC: Adénome hypophysaire à cellules thyrotropes avec hyperthyroïdie. *Ann Endocrinol (Paris)* (1969) **30**, 731–740.
- Yozai S, Goto A, Ogawa N, Suzuki S and Kasai K: A case of acromegaly with hyperthyroidism and diabetes mellitus. *Nippon Naika Gakkai Zasshi* (abstract in Japanese) (1971) **60**, 769.
- Demura R, Saito S, Sakurada T, Iwabuchi T and Fukuda T: Acromegaly with hyperthyroidism due to TSH hypersecretion. *Igaku no Ayumi* (1973) **84**, 637–648 (in Japanese).
- Kourides IA, Ridgway EC, Weintraub BD, Bigos ST, Gershengorn MC and Maloof F: Thyrotropin-induced hyperthyroidism: Use of alpha and beta subunit levels to identify patients with pituitary tumors. *J Clin Endocrinol Metab* (1977) **45**, 534–543.
- Lamberg BA, Pelkonen R, Gordin A, Halta M, Wahlström T, Paetau A and Leppäläuto J: TSH-induced hyperthyroidism and acromegaly due to pituitary tumor. *Acta Endocrinol (Copenh)* (1983) **103**, 7–14.
- Smallridge RC, Wartofsky L and Dimond RC: Inappropriate secretion of thyrotropin: Discordance between the suppressive effects of corticosteroids and thyroid hormone. *J Clin Endocrinol Metab* (1979) **48**, 700–705.
- Meinders AE, Willekens FLA, Barends CAE, Seevinck J and Kruseman ACN: Acromegaly and thyrotoxicosis induced by a GH- and TSH-producing pituitary tumor which also contained prolactin. *Neth J Med* (1981) **24**, 136–144.
- Coculescu M, Pop A, Constantinovici AL, Oprescu M, Temeli E and Marinescu I: Mixed TSH- and HGH- secreting pituitary adenoma. *Rev Roum Med-Endocrinol* (1982) **20**, 209–216.
- Carlson HE, Linfoot JA, Braunstein GD, Kovacs K and Young RT: Hyperthyroidism and acromegaly due to a thyrotropin- and growth hormone-secreting pituitary tumor: Lack of hormonal response to bromocriptine. *Am J Med* (1983) **74**, 915–923.
- Reshini E, Giustina G, Cantalamessa L and Peracchi M: Hyperthyroidism with elevated plasma TSH levels and pituitary tumor: Study with somatostatin. *J Clin Endocrinol Metab* (1976) **43**, 924–927.
- Wemeau JL, Dewailly D, Leroy R, D'herbomez M, Mazuca M, Decoulx M and Jaquet P: Long term treatment with the somatostatin analog SMS 201–995 in a patient with a thyrotropin- and growth hormone-secreting pituitary adenoma. *J Clin Endocrinol Metab* (1988) **66**, 636–639.
- Lamberts SWJ, Uittrelinden P, Verschoor L, van Dongen KJ and Del Pozo E: Long-term treatment of acromegaly with the somatostatin analogue SMS 201–995. *N Engl J Med* (1985) **313**, 1576–1580.
- Comi RJ, Gesundheit N, Murray L and Weintraub BD: Response of thyrotropin-secreting pituitary adenoma to a long-acting somatostatin analogue. *N Engl J Med* (1987) **317**, 12–17.
- Beck-Peccoz P, Medri G, Piscitelli G, Mariotti S, Bertoli A, Barbarino A, Rondena M, Martino E, Pinchera A and Faglia G: Treatment of inappropriate secretion of thyrotropin with somatostatin analog SMS 201–995. *Horm Res* (1988) **29**, 121–123.
- Beck-Peccoz P, Maritti S, Gullausseau JP, Medri G, Piscitelli G, Bertoli A, Barbarino A, Rondena A, Rondena M, Ph Chanson, Pinchera A and Faglia G: Treatment of hyperthyroidism due to inappropriate secretion of thyrotropin with the somatostatin analog SMS 201–995. *J Clin Endocrinol Metab* (1989) **68**, 208–214.
- Malarkey BW, Kovacs K and O'Dorisio MT: Response of a GH- and TSH-secreting pituitary adenoma to a somatostatin analogue (SMS 201–995): Evidence that GH and TSH coexist in the same cell and secretory granules. *Neuroendocrinology* (1989) **49**, 267–274.
- Del Pozo E, Gerber L and Hunziker S: Response to bromocriptine therapy in 115 prolactinoma cases; in Prolactin and Prolactinomas Tolis, Stefanis, Mountokalakis and Labrie eds. Raven Press, New York (1983) pp 403–414.
- Kraenzlin ME, Ch'ng JLC, Wood SM, Carr DH and Bloom SR: Long term treatment of a vipoma with somatostatin analogue resulting in remission of symptoms and possible shrinkage of metastases. *Gastroenterology* (1985) **88**, 185.
- Bonfils S, Ruzsniwski P, Costil V, Laucournet H, Vatié J, René E and Mignon M: Prolonged treatment of Zollinger-Ellison syndrome by long-acting somatostatin. *Lancet* (1986) **1**, 554–555.
- Osei K and O'Donsio TM: Malignant insulinoma: Effect of a somatostatin analogue (Compound SMS 201–995) on

- serum glucose, growth and gastroenteropancreatic hormones. *Ann Intern Med* (1985) **103**, 223-225.
22. Kvols LK, Buck M, Moertel CG, Schutt AJ, Rubin J, O'Connell MJ and Hahn RG: Treatment of metastatic islet cell carcinoma with a somatostatin analogue (SMS 201-995). *Ann Intern Med* (1987) **107**, 162-168.
 23. Barkan AL, Lloyd RV, Chandler WF, Hatfield MK, Gebarski SS, Kelch RP and Beitins IZ: Preoperative treatment of acromegaly with long-acting somatostatin analog SMS 201-995: Shrinkage of invasive pituitary macroadenomas and improved surgical remission rate. *J Clin Endocrinol Metab* (1988) **67**, 1040-1048.
 24. Bankan AL, Keich RP, Hopwood NJ and Beitins IZ: Treatment of acromegaly with the long-acting somatostatin analogue SMS 201-995, *J Clin Endocrinol Metab* (1988) **66**, 16-23.
 25. Piters GFFM, Smals AEM, Smals AGH, van Gennep JA and Kloppenborg PWC: The effect of minisomatostatin on anomalous growth hormone responses in acromegaly. *Acta Endocrinol (Copenh)*(1987) **114**, 537-542.
 26. Ducasse MCR, Tauber JP, Touurre A, Bonafe A, Babin TH, Tauber MT, Harris AG and Bayard F: Shrinking of growth hormone producing pituitary tumor by continuous subcutaneous infusion of the somatostatin analog SMS 201-995. *J Clin Endocrinol Metab* (1987) **65**, 1042-1046.
 27. Gomez-Pan A and Rodriguez-Arno MD: Somatostatin and growth hormone releasing factor: Synthesis, location, metabolism and function. *J Clin Endocrinol Metab* (1983) **12**, 469-507.

Received October 1, 1990 ; accepted November 30, 1990.