

Acta Medica Okayama

Volume 22, Issue 3

1968

Article 5

JUNE 1968

Liposarcoma of stomach: report of a case

Kunzo Orita*

Yoshiaki Kokumai†

Koichi Kawada‡

Toru Kawahara**

Shigeru Takagi††

*Okayama University,

†Okayama University,

‡Nariwa Hospital,

**Nariwa Hospital,

††Nariwa Hospital,

Liposarcoma of stomach: report of a case*

Kunzo Orita, Yoshiaki Kokumai, Koichi Kawada, Toru Kawahara, and Shigeru Takagi

Abstract

A report is made on a case of liposarcoma of stomach in a 42 year old man. This is the first case of liposarcoma of stomach reported in Japan. The patient has remained asymptomatic for five years after operation.

LIPOSARCOMA OF STOMACH: REPORT OF A CASE

Kunzo ORITA, Yoshiaki KOKUMAI, Koichi KAWADA,*
Toru KAWAHARA,* and Shigeru TAKAGI*

*Department of Surgery, Okayama University Medical School, Okayama (Director; Prof. S. Tanaka)
and *Nariwa Hospital, Nariwa-cho, Okayama Prefecture, Japan*

Received for publication, April 28, 1968

The voluminous literature on sarcomas of stomach indicates that the majority of them are leiomyosarcomas and malignant lymphomas, as for instance, according to MARSHALL'S classification(1). Theoretically, sarcoma of the stomach may arise from any of the mesenchymal tissue components of the organ, but malignant sarcomatous tumors arising from fat tissue are extremely rare. The study reported is a case of primary liposarcoma of stomach which, to our best knowledge, is the first in Japan.

CASE REPORT

A Japanese farmer aged 42 was admitted to Nariwa Hospital in January, 1962, because of epigastric pain, full sensation of the abdomen and diarrhea. He had been in good health until two years before admission when he began to have preprandial epigastric pain and diarrhea of 5 to 6 times daily. Since onset of his distress, he had returned occasionally to the out-patient clinic. At first, X-ray examination of gastrointestinal series had revealed no abnormality except for slight gastropnoia and gastritis. Conventional dietary and medicinal therapy were given, but to no avail. At last he was advised to be hospitalized.

Family history and past history were uneventful. Physical examination on admission revealed a well developed, moderately nourished, alert man in no acute distress. Temperature was 36.5°C., pulse rate 82 per minute, respiratory rate 18 per minute and blood pressure 110/80 mmHg. The skin was warm and dry. The palpebral conjunctive was rather anemic. The tongue was slightly coated with white fur. The head and neck were negative. Lymphnodal swelling was not detected anywhere. The lungs were physically clear and the heart was not enlarged. Heart sounds were normal and no murmurs were audible. The abdomen was flat and soft, liver and spleen were not palpable. Slight tenderness on deep palpation in the epigastric region was detected, but there were no

masses. Rectal examination was negative. There was no pitting edema of the lower extremities. Neurological examination was not remarkable.

Laboratory findings on admission consisted of the following: Examination of the blood revealed 3.06 million red cells, 73 per cent hemoglobin, 6,000 white blood cells with a normal differential, 7.8 g/dl serum protein. Blood serological test for syphilis was negative. The stools were soft and light brown in color, negative for occult blood and parasitic ova. Urinalysis was negative. Liver function tests were within normal limits. Gastric analysis revealed achlorhydria. ECG was of normal tracing.

X-ray examination of the stomach revealed slight ptosis and a dime-sized well-defined filling defect in the middle portion of the body near the greater curvature (Fig. 1). Abruption of the mucosal folds at the site of filling defect was noticed, but no malignant mucosal pattern was seen (Fig. 2). Gastrocamera disclosed a semi-spherical protruded tumor on the posterior wall of the middle portion of the stomach. The tumor was covered with smooth gastric mucosa and there were no erosions or ulcers. The mucosal pattern was atrophic. Clinical diagnosis of gastric polyp with chronic gastritis was made on these findings.

The operation was carried out on February 2, 1962. Under general anesthesia the abdomen was entered through an upper midline incision. On entering the peritoneal cavity no free fluid was encountered. A cherry-sized spherical tumor which had smooth surface and elastic consistency was palpated in the posterior wall of the body of the stomach. That was coincident with the roentgenologically detected site. The gastric wall was entirely thickened and rather edematous. There was no lymphnodal swelling around the stomach. In consideration of long-lasting chronic gastritis, two-thirds of the stomach including the tumor were resected and a gastrojejunostomia retrocolica oralis inferior was performed.

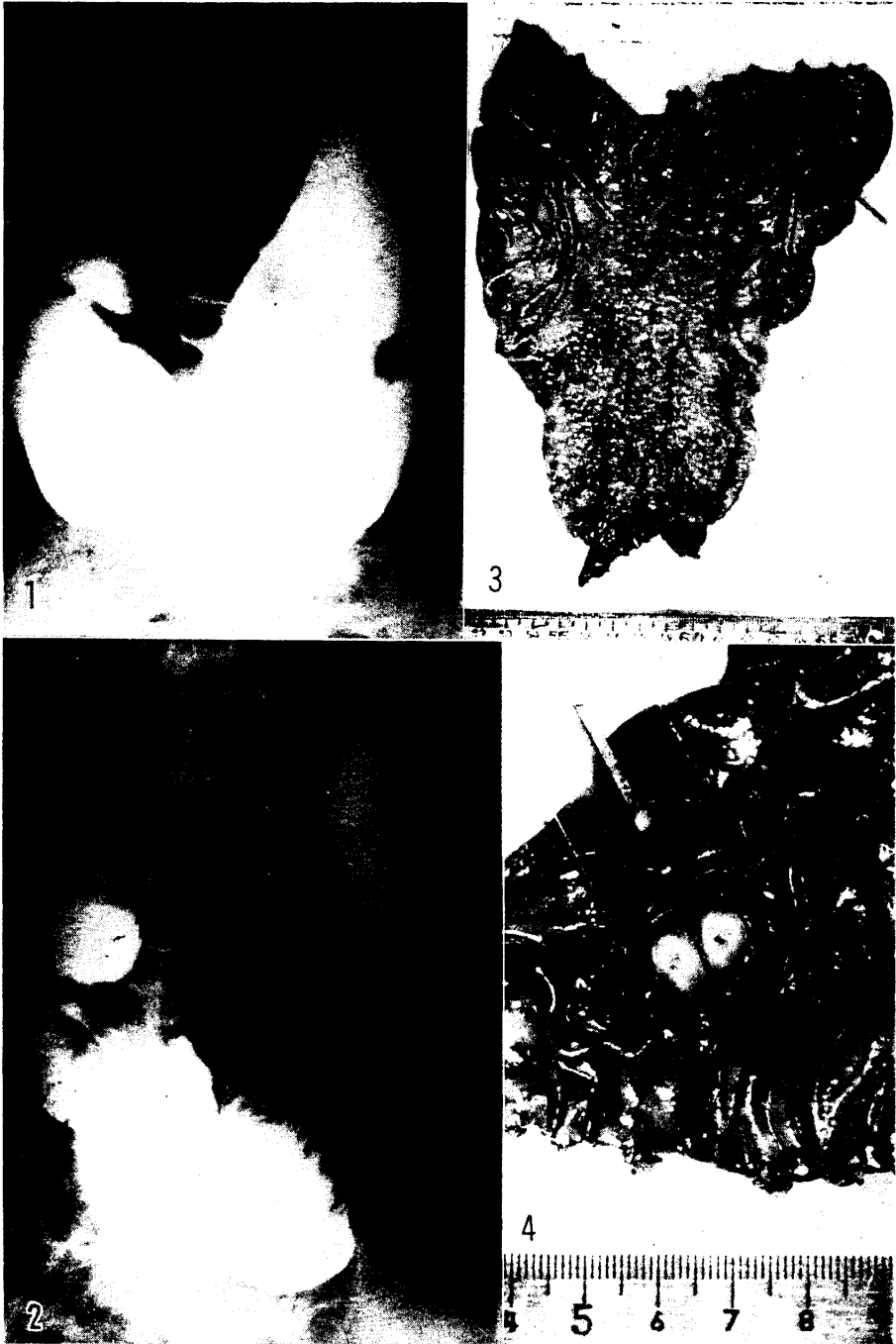When the excised stomach was opened, the tumor was in submucosal layer along the greater curvature at the distance of 15 cm from the pyloric canal. It was spherical in shape, measuring $1.2 \times 1.0 \times 1.0$ cm, and elastic in consistency. The tumor was firmly fixed to the muscular layers, but there was no connection between the tumor and the mucosa (Fig. 3). The incised surface of the tumor was homogenous and light yellowish in color


Fig. 1 X-ray picture of the stomach. A round filling defect near the greater curvature of the body can be seen.

Fig. 2 X-ray picture of the stomach. Note the abruption of the mucosal folds at the site of filling defect showing no malignancy.

Fig. 3 Gross appearance of the resected stomach. The protruded spherical tumor is covered with normal gastric mucosa.

Fig. 4 Incised surface of the tumor. It is similar to adipose tissue.





like adipose tissue, and several bleeding spots were seen in the center of it (Fig. 4).

Sections revealed liposarcoma grown between the muscular layers and the mucosa of the stomach. It was, for the most part, composed of relatively larger cells containing vacuoles in their cytoplasm and also cells having large nuclei were partly visible. Among them there were moderate infiltration of lymphocytes and proliferation of fibrocytes.

Hematoxylin eosin staining revealed marked proliferation of lipoblasts in varying degrees of differentiation but the interstitial tissue was scarcely seen (Fig. 5). Histological picture showed many undifferentiated and anaplastic lipoblasts of various size (Fig. 6). Sudan III staining rendered neutral fat in the interstitial tissue stained red and lipid in the cytoplasm light orange (Fig. 7). PAS staining was negative for mucoid. The mucous membrane of the stomach was slightly edematous and revealed moderate infiltration of plasma cells, lymphocytes and polymorphonuclear leukocytes.

The postoperative course was uneventful. The patient was discharged much improved one month after operation and, has since been followed by occasional check-ups. Five years has passed since, and now he is asymptomatic, having no findings indicative of any growths in other organs or tissues. Therefore this case is assumed to be a primary liposarcoma of the stomach.

COMMENT

It is a well known fact that the tumors arising from fat tissue (exactly the tumors of fat-forming cells) of the stomach are rare. Up to date, only 8 cases of lipoma of stomach have been reported in Japan by MIZUNO (2), HIKIDA (3), NOMURA (4), NISHIMURA (5), AKAZAWA (6), HASHIMOTO (7), AKIYAMA (8), and DEMPO (9). Truly rare is liposarcoma, and no case of liposarcoma of stomach has ever been reported in Japan. Of the 215 instances of sarcomas of stomach reported in Japan till 1961, 78 are reticulosarcomas, 50 are leiomyosarcomas, 28 are round cell sarcomas, 12 are lymphosarcomas and spindle cell sarcomas respectively, 11 are polymorphous cell sarcomas, 9 are fibrosarcomas, 3 are neurofibrosarcomas, 2 are Hodgkin's disease, one is myxosarcoma, and 9 are unknown. Outside Japan, there are doubt-

Fig. 5 Photomicrograph of the section shows marked proliferation of lipoblasts in varying degree of differentiation. Hematoxylin eosin staining. $\times 80$.

Fig. 6 Histologic picture shows many undifferentiated anaplastic lipoblasts of various size. Hematoxylin eosin staining. $\times 400$.

Fig. 7 Photomicrograph of Sudan III staining renders neutral fat in the matrix stained red and lipid in the cytoplasm light orange. $\times 400$.

full cases of liposarcoma of stomach reported by ABRAMS and TURBERVILLE(10) in 1941.

Even today, the histogenesis of liposarcoma is in doubt. It seems safer to regard the lipoblast as an ordinarily specialized fat forming mesenchymal cell which on occasion can produce a very wide variety of different and complex tissues.

Undoubtedly some liposarcomas develop from pre-existing lipomas. This is stressed by SCHILLER(11), and KATZ(12), and reported by STOUT(13). STOUT says, however, that it is difficult to tell how often it occurs because many of the tumors are composed of an intermingling of fully developed fat cells with neoplastic lipoblasts and one has no means of knowing whether or not this state of affairs existed from onset. It seems probable that a large majority of malignant lipoblastic tumors are malignant from their beginning. In our case we have no evidence as to the matter of sarcomatous transformation of lipoma. It seems most likely to be malignant from the onset.

In general, the majority of liposarcomas develop in the later years of life, the mean age being 53 years and both sexes are affected equally, but, as a matter of fact, about the liposarcoma of stomach the incidence is not clear because of its rarity. Gradual accumulation of these cases will make its incidence clearer.

The diagnosis is difficult and indeed, sometimes may be made only with difficulty microscopically. So far as our case is concerned, the clinical impression is a polyp of stomach.

Treatment of liposarcoma is primarily surgical. On liposarcoma of stomach it goes without saying that surgery is the first choice of the treatment and, whenever such is possible, a wide excision. It is said that some liposarcomas are definitely radiosensitive, but we cannot place our hope on radiation therapy in case of liposarcoma of stomach.

Prognosis is questionable, but concerning our case it has passed five years after operation without any signs of recurrence or metastasis.

SUMMARY

A report is made on a case of liposarcoma of stomach in a 42 year old man. This is the first case of liposarcoma of stomach reported in Japan. The patient has remained asymptomatic for five years after operation.

ACKNOWLEDGEMENT

We are indebted to Prof. Emeritus Y. HAMAZAKI and Dr. Y. MURAKAMI of the Department of Pathology, Okayama University Medical School for the guidance in Pathology.

REFERENCES

1. MARSHALL, S. F.: in *Text Book of Surgery* (CHRISTOPER), 621 pp. (Davies, L. ed.), W. B. SUNDERS Co., Philadelphia, 1956
2. MIZUNO, N., et al.: *Tohoku Igaku Zasshi*, **50**, 221, 1954 (in Japanese)
3. HIKIDA, T., and NISHIKAWA, Y.: *Clinical Surgery*, **14**, 153, 1959 (in Japanese)
4. NOMURA, S., and SANO, E.: *Shinshu Igaku Zasshi*, **7**, 419, 1958 (in Japanese)
5. NISHIMURA, T., et al.: *Clinical Surgery*, **14**, 313, 1959 (in Japanese)
6. AKAZAWA, K.: *Chiba Igaku Zasshi*, **35**, 506, 1959 (in Japanese)
7. HASHIMOTO, T., et al.: *Nihon Syokakibyō Gakkai Zasshi*, **58**, 301, 1961 (in Japanese)
8. AKIYAMA, Y., et al.: *Rinsho Hoshasen*, **5**, 636, 1960 (in Japanese)
9. DIMPO, Y., et al.: *Surgical Diagnosis & Treatment*, **3**, 865, 1961 (in Japanese)
10. ABRAMS, M. J., and TURBERVILLE, J. S.: Liposarcoma of stomach. *South Surgeon*, **10**, 891, 1941
11. SCHILLER, H.: Lipomata in sarcomatous transformation. *Surg., Gynec. and obst.*, **27**, 218, 1918
12. KATZ, F.: Über retroperitoneale Lipome. *Beitr. z. klin. Chir.*, **142**, 864, 1928
13. STOUT, A. P.: Liposarcoma-the malignant tumor of lipoblasts. *Ann. Surg.*, **119**, 86, 1944