

Acta Medica Okayama

Volume 33, Issue 6

1979

Article 5

DECEMBER 1979

Malacoplakia of probable retroperitoneal origin.

Hiromi Kumon*

Masaaki Morioka†

Tohru Araki‡

Yosuke Matsumura**

Hiroyuki Ohmori††

Toshio Tanaka‡‡

*Okayama University,

†Okayama University,

‡Okayama University,

**Okayama University,

††Okayama University,

‡‡Okayama University,

Malacoplakia of probable retroperitoneal origin.*

Hiromi Kumon, Masaaki Morioka, Tohru Araki, Yosuke Matsumura, Hiroyuki Ohmori, and Toshio Tanaka

Abstract

A case of extravesical malacoplakia, the first case in Japan, is described in detail. The patient was a 61-year-old woman with a right flank mass. Radiologically, the mass was thought to be of the renal origin. Surgically, however, the tumor was found attached not only to the cortical surface but extended to the retroperitoneum and psoas muscle. Pathological examination confirmed the lesion to be malacoplakia characterized by the presence of von Hansemann cells and Michaelis-Gutmann bodies.

KEYWORDS: malacoplakia, retroperitoneum

Acta Med. Okayama **33**, (6), 455—462 (1979)

MALACOPLAKIA OF PROBABLE RETROPERITONEAL ORIGIN

Hiromi KUMON, Masaaki MORIOKA, Tohru ARAKI,
Yosuke MATSUMURA, Hiroyuki OHMORI
and Toshio TANAKA*

*Department of Urology ; and *Pathology Section, Central Laboratories,
Okayama University Medical School, Okayama 700, Japan*

Received June 1, 1979

Abstract. A case of extravescical malacoplakia, the first case in Japan, is described in detail. The patient was a 61-year-old woman with a right flank mass. Radiologically, the mass was thought to be of the renal origin. Surgically, however, the tumor was found attached not only to the cortical surface but extended to the retroperitoneum and psoas muscle. Pathological examination confirmed the lesion to be malacoplakia characterized by the presence of von Hansemann cells and Michaelis-Gutmann bodies.

Key words: malacoplakia, retroperitoneum.

Since von Hanseman (1) in 1903 proposed the term malacoplakia to a peculiar lesion in urinary bladder, over 190 cases have been reported affecting not only the bladder but various organs, even not relating with urinary tracts. In Japan, according to a comprehensive survey by Tsuchiya (2) in 1975, 10 cases were reported. Our review adds a further 10 cases; these 20 cases of malacoplakia are exclusively found in the urinary bladder (3-5) except for two cases involving the prostate (6), although its details were not given. We present here a case of malacoplakia which most likely originated from the renal cortex or the retroperitoneum itself. To the best of our knowledge, this is the first case of extravescical lesion ever reported in Japan in detail.

CASE PRESENTATION

A 61-year-old woman was admitted for a right flank mass. She had been hospitalized elsewhere for collagen disease with low grade fever and arthralgia, and treated with steroid hormone for 18 months. She had no history of recurrent urinary tract infection except for one episode of pyelonephritis 5 months before the present admission. She also had no history of right flank pain, hematuria or urinary complaints. There was no family history of urological disorder or malignancy except for her elder brother with rectal cancer.

On physical examination, a large, smooth, well circumscribed, fixed and

non-tender mass was palpable in the right flank region. She weighed 68.5 kg and was 154 cm tall, showing moderate obesity. Other physical examinations were normal.

ESR was highly elevated (53-91/1h, 91-132/2h), but complete blood count was normal. Urinalysis demonstrated a few WBCs per high power field and 1 plus bacteria. Urine culture, although performed a few days after retrograde pyelography, yielded 10^7 colonies/ml of *E. coli*. Cystoscopically, there were no particular findings. FBS was slightly elevated and a borderline diabetic pattern was observed on 50 g-GTT. Other blood chemistry studies including BUN, creatinine, LDH were normal. There was no positive finding suggesting collagen disease.

Radiological and surgical findings. An excretory urogram (DIP) revealed a compression of the middle and lower calices, although a fine pyelogram was not obtainable. DIP was re-examined under a pneumoretroperitoneum (PRP) with 1,000 ml of oxygen. The outline of the right kidney was enlarged and the lower and inner margins were not clear (Fig. 1). Selective right renal arteriography demonstrated a clear outline of the right kidney, which was smaller than that obtained by DIP under PRP, suggesting a space occupying lesion (Fig. 2). Arteriography also demonstrated abnormal arteries branching from the right renal artery, which might be considered feeding arteries of the lesion, although there was no evidence of neovascularity or vascular pooling. Retrograde pyelography also revealed a distortion of the middle and lower calices, suggesting that this lesion was intrinsic to the kidney (Fig. 3). The findings as mentioned above were confirmed by computed tomography; the mass lesion pushed the kidney upward, and extended toward the psoas muscle (Fig. 4).

The kidney was explored through a right flank incision and was exposed extraperitoneally. It was difficult to mobilize the lower, posterior portion of the mass, because a solid lesion appeared to be invading the psoas muscle. Biopsy of the mass was examined by a frozen section, which indicated a benign tumor. The kidney and as much of the mass as possible were removed *en bloc*.

Pathological findings. Grossly, the specimen including excised kidney weighed 290 g, and the tumor itself measured approximately $9 \times 6 \times 4.5$ cm. The tumor was solid, elastic firm and somewhat yellowish in some parts on the cut surface (Fig. 5).

Microscopically, tumorous lesion was rather sharply demarcated from the kidney with fibrous strands. The lesion consisted of clusters of cells with eosinophilic cytoplasm; periodic acid-Schiff staining revealed numerous, coarse, intracytoplasmic granules of various sizes (von Hansemann cells) (Fig. 6). Intracellularly and extracellularly, there were massive spherulites with so-called target-like or owl's-eye appearance (Fig. 7); these were described first by

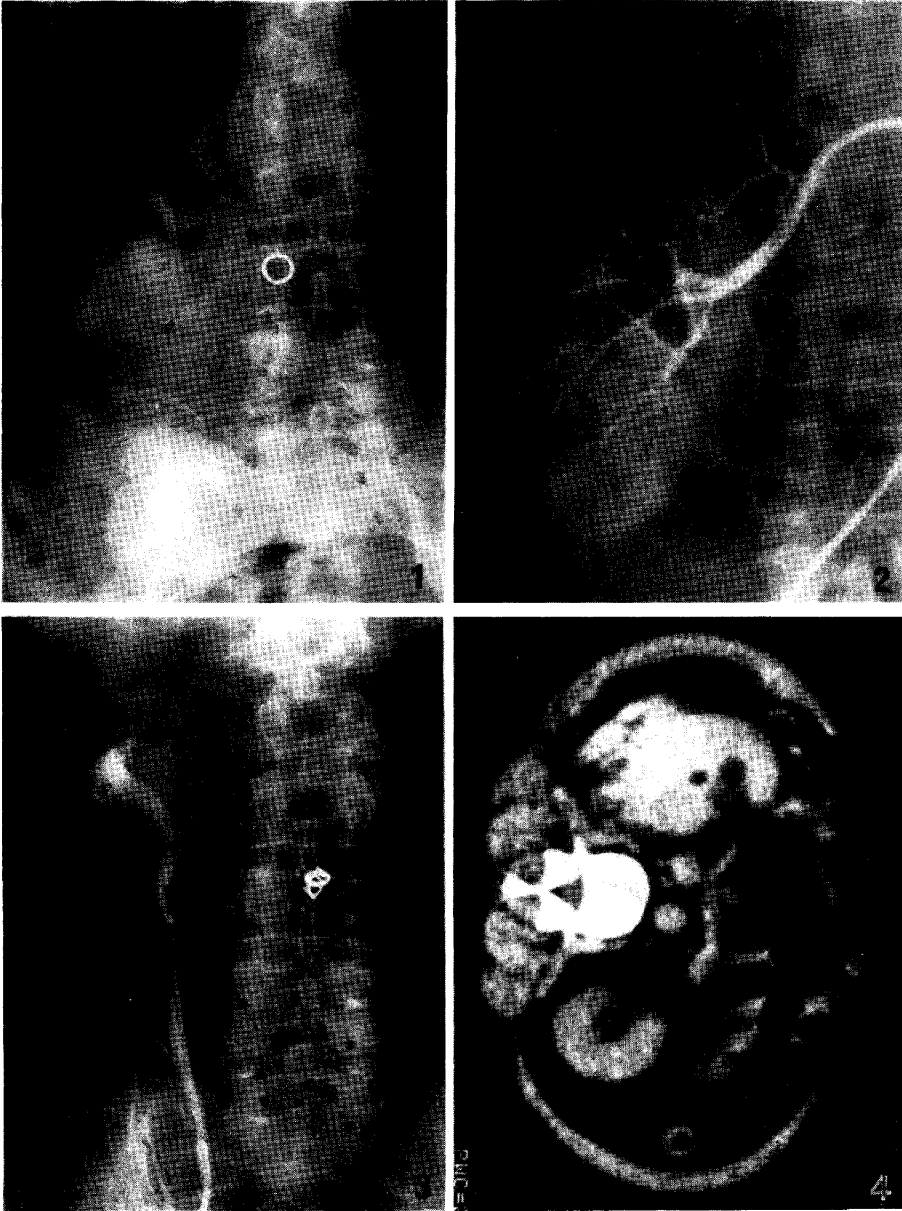


Fig. 1. An excretory urogram combined with pneumoretroperitoneum showing the enlarged right kidney with the indistinct lower and inner margins.

Fig. 2. A selective right renal arteriography demonstrating a clear outline of the kidney and abnormal arteries branching off from the right renal artery.

Fig. 3. A retrograde pyelography revealing the distorted middle and lower calices.

Fig. 4. A computerized tomography disclosing a mass which pushes the kidney upward and infiltrates into the psoas muscle.

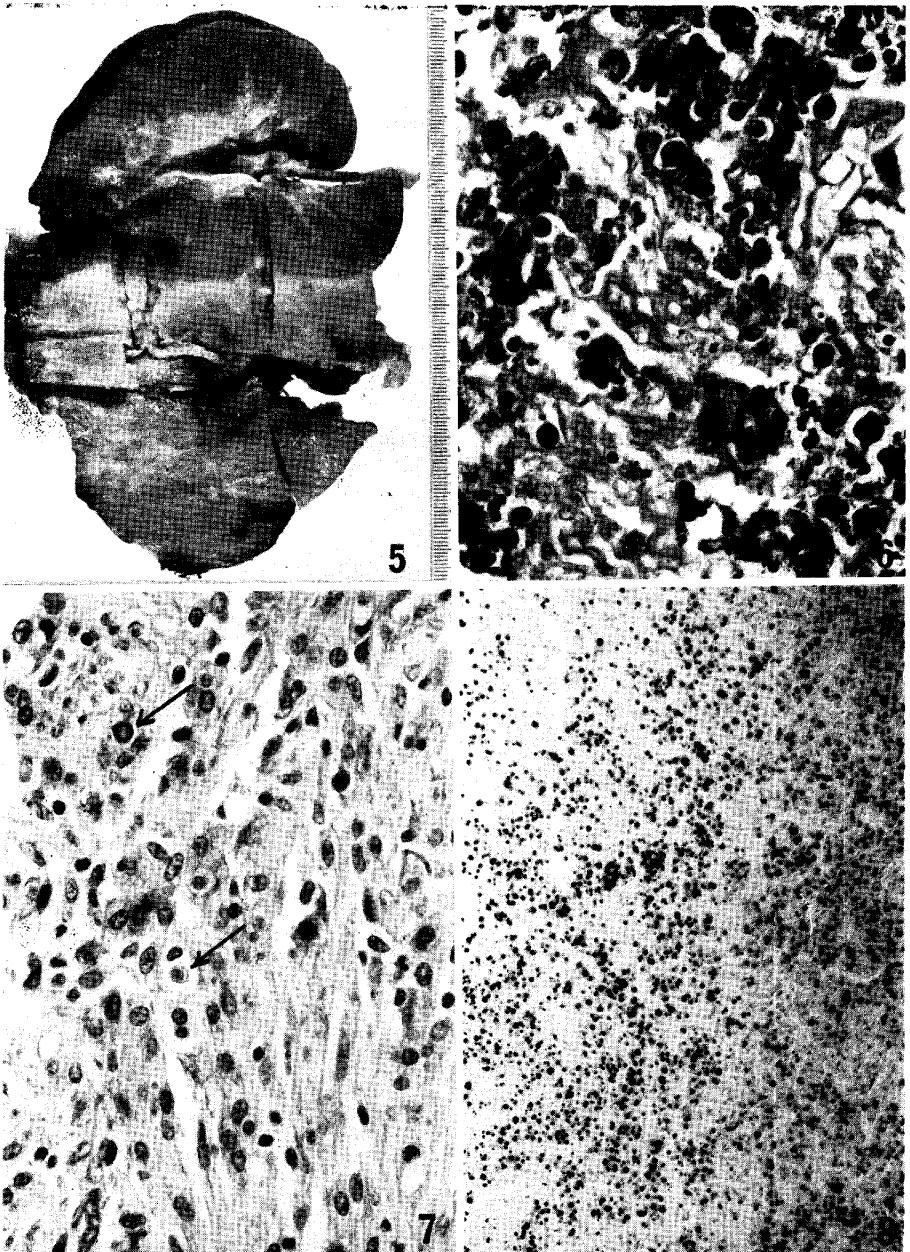


Fig. 5. Excised tumor together with the right kidney.

Fig. 6. Clusters of von Hansemann cells with numerous, coarse, intracytoplasmic granules of various sizes. PAS, $\times 400$.

Fig. 7. Michaelis-Gutmann bodies (arrows) with target-like or owl's-eye appearance. HE, $\times 400$.

Fig. 8. Massive spherulites of the Michaelis-Gutmann bodies. von Kossa, $\times 100$.

Michaelis and Gutmann in 1902 (7). Michaelis-Gutmann bodies were stained strongly with von Kossa (Fig. 8) and weakly with iron staining. Ultrastructural study identified these bodies as well as fingerprint-like inclusions (Fig. 9).

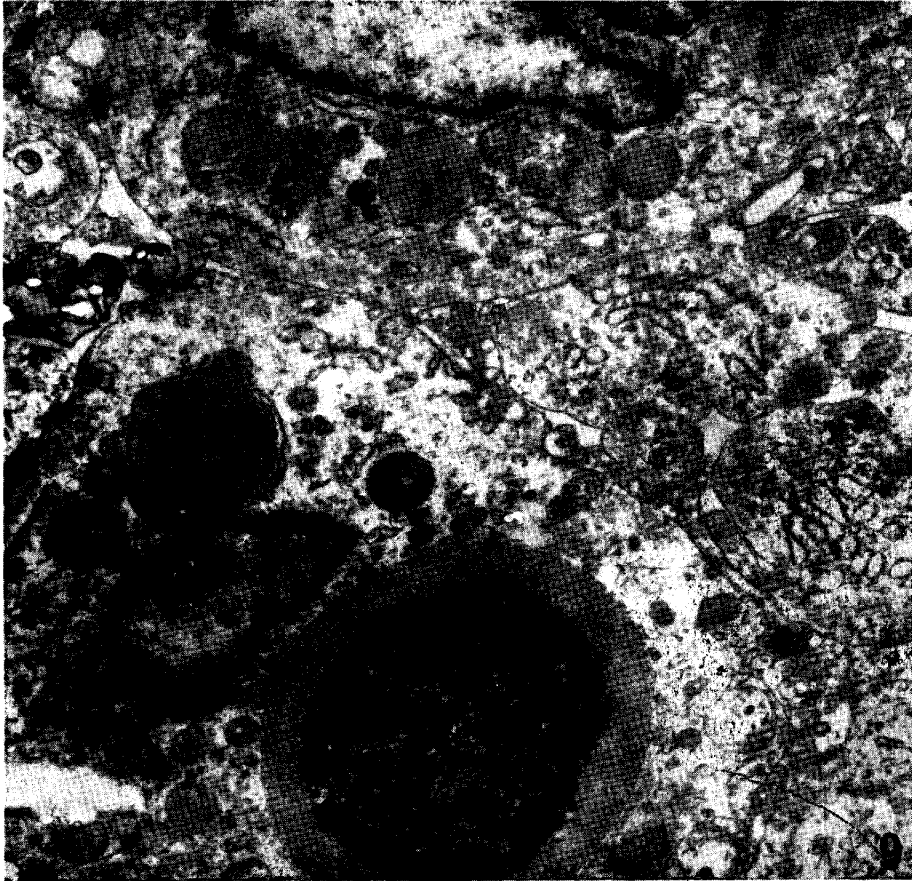


Fig. 9. An intracellular Michaelis-Gutmann body with concentrically located electron-dense material, and several fingerprint-like inclusions. $\times 12,000$.

DISCUSSION

Cases hitherto reported in Japan have been almost exclusively confined to the urinary bladder. According to the oversea literature, however, it is not surprising to find malacoplakia in organs other than the bladder (8), such as the ureter (9), prostate (10), testis and epididymis (11), gastrointestinal tracts (12), broad ligament (13), vagina (14), lung and bone (15), adrenal gland (16), brain (17), and skin (18, 19).

As to the kidney, Miller and Finck (20) in 1970 reviewed a total of 15 cases,

TABLE I. MALACOPLAKIA HITHERTO REPORTED IN JAPAN

Informants	Sex Age	Chief Complaints	Urine Culture	Diagnosed by ^a	M-G Body
1. Suzuki <i>et al.</i> (1965)	F 26	pollakysuria, dysuria	<i>E. coli</i>	cyst., Bx.	—
2. Yoneyama <i>et al.</i> (1965)	F 53	pollakysuria, dysuria	<i>E. coli</i>	cyst., Bx.	+
3. Seki (1968)	F 57	terminal hema- turia	<i>E. coli</i>	cyst., Bx.	+
4. Ishibashi <i>et al.</i> (1970)	F 47	hematuria	<i>E. coli</i>	cyst., Bx.	—
5. <i>ibid.</i>	F 53	terminal hema- turia	<i>E. coli</i>	cyst., Bx.	+
6. Hamada <i>et al.</i> (1973)	M 66	pollakysuria, dysuria, hema- turia	<i>E. coli</i>	cystectomy	—
7. Soeda <i>et al.</i> (1973)	F 41	terminal hema- turia	<i>E. coli</i>	cyst., Bx.	+
8. Oya <i>et al.</i> (1974)	F 42	terminal hema- turia	<i>E. coli</i>	cyst., Bx.	+
9. Tsuchiya (1975)	F 71	pollakysuria, dysuria	<i>E. coli</i>	cyst., Bx.	+
10. <i>ibid.</i>	F 57	pollakysuria, dysuria	<i>E. coli</i> <i>Proteus</i>	cyst., Bx.	+
11. Inaba <i>et al.</i> (1975)	M 88	pollakysuria, hematuria	...	cyst., Bx.	—
12. Hashimoto <i>et al.</i> (1976)	F 72	terminal hema- turia	negative	cyst., Bx.	+
13. Fujita (1976)	M 47	Rt. orchitis	<i>E. coli</i>	cyst., Bx.	+
14. Ikeda <i>et al.</i> (1977)	F 48	terminal hema- turia	<i>E. coli</i>	cyst., Bx.	+
15. Kumazawa (1977)	F 58	pollakysuria	<i>E. coli</i>	cyst., Bx.	+
16. Tokue <i>et al.</i> (1977)	F 44	dysuria, hema- turia	<i>E. coli</i>	cyst., cyst- ectomy	+
17. Kawamura <i>et al.</i> (1978)	M 53 ^b	fever, dysuria	...	prost. Bx.	+
18. <i>ibid.</i>	M 47 ^b	fever	...	prost. Bx.	...
19. Nakajima <i>et al.</i> (1978)	F 27	hematuria	negative	cyst., Bx.	+
20. Katayori <i>et al.</i> (1979)	F 66	pyuria	...	cyst., Bx.	+

^a cyst.: cystoscopy. Bx.: biopsy.

^b Malacoplakia in the prostate.

and found 10 cases involving either the renal pelvis or papilla and 4 cases with focal parenchymal involvement. The remaining one case was that of Ravel (21) under the designation of megalocytic interstitial nephritis. The author preferred

this term to malacoplakia because of exclusive involvement of renal cortex without any bladder lesion, although he conceded a striking similarity between his case and conventional malacoplakia. Concerning the retroperitoneal involvement, there have been two well-documented cases. One apparently originated from the colon as intraluminal polyps, which extended into the retroperitoneal fat forming extraluminal masses (22). The other was a retroperitoneal abscess following left nephrectomy (23); retrospective investigation revealed malacoplakia in the excised kidney and a biopsied specimen from the bladder. In our case, at least macroscopically, the renal cortex was sharply demarcated from the retroperitoneal mass, and, except for a few limited areas, the thickness of cortex and medulla was surprisingly homogeneous throughout. In addition, microscopically, there was no trace of involving the medulla, pelvis or papilla. On the other hand, radiological findings indicate to a certain extent the possibility of renal cortical origin. Therefore, although we would surmise a probable retroperitoneal origin of the tumor, the exact site of its initiation remains to be elucidated.

As to the pathogenesis of malacoplakia, several theories have been put forward (24). At least in bladder and also in some other lesions, coliform organism is most likely a causative agent, and may release glycolipid to form Michaelis-Gutmann bodies (22). In this connection, macrophages may be responsible, of which function can be altered due to infected micro-organisms (12). Secondly, in contrast to almost unanimous understanding of the von Hanseman cells to be of mesenchymal cells, there are a few observations suggesting an epithelial origin (20). If the tumor in our case were in fact originated from the kidney, this possibility ought to be taken into consideration.

In order to investigate the exact originating site of tumor in our case and more precise pathogenesis of Michaelis-Gutmann bodies as well as von Hanseman cells, thorough examinations on the material by means of electron microscopy and histochemistry are currently in progress; and the results obtained will appear elsewhere.

Acknowledgments. Our sincere thanks are due to Mr. K. Ohno, a technical staff member, the Department of Urology, for assisting in the present work.

REFERENCES

1. von Hanseman: Über Malakoplakie der Harnblase. *Virchows Arch.* **173**, 302-308, 1903.
2. Tsuchiya, T.: A studies of ultra-fine structure of vesical malacoplakia and the mechanism of formation of Michaelis-Gutmann bodies. *Hinyo-kiyo* **21**, 487-505, 1975 (in Japanese).
3. Yoneyama, T., Tazaki, E., Oryu, S., Machida, T., Shirasawa, H. and Seki, M.: Malakoplakia of the urinary bladder: report of a case with clinical, histopathologic and electron microscopic studies. *Rinsho-hihi* **19**, 615-619, 1965 (in Japanese).
4. Sasaki, H. and Hokano, M.: Malakoplakia of urinary bladder. *Jpn. J. Urol.* **57**, 203-212, 1966 (in Japanese).

5. Ikeda, Y., Nishimoto, K. and Gomyoda, M.: Malacoplakia of the urinary bladder with bilateral vesico-ureteral reflux: report of a case. *Nishinohon-hinyokika* **39**, 976-979, 1977 (in Japanese).
6. Kawamura, N., Okada, T. and Ogoshi, M.: Two cases of malacoplakia in the prostate. *Jpn. J. Urol.* **69**, 624, 1978 (an abstract in Japanese).
7. Michaelis, L. and Gutmann, C.: Ueber Einschlüsse in Blasen-tumoren. *Z. Klin. Med.* **47**, 208-215, 1902.
8. Thorning, D. and Vracko, R.: Malakoplakia. Defect in digestion of phagocytized material due to impaired vacuolar acidification? *Arch. Patholol.* **99**, 456-460, 1975.
9. Lambird, P. A. and Yardley, J. H.: Urinary tract malakoplakia: report of a fetal case with ultrastructural observations of Michaelis-Gutmann bodies. *Hopkins Med. J.* **126**, 1-14, 1970.
10. Hoffmann, E. and Garrido, M.: Malakoplakia of the prostate: report of a case. *J. Urol.* **92**, 311-313, 1964.
11. Waisman, J. and Rampton, J. B.: Malacoplakia of the testis and epididymis. *Arch. Pathol.* **86**, 431-437, 1968.
12. Lou, T. Y. and Teplitz, C.: Malakoplakia: pathogenesis and ultrastructural morphogenesis. A problem of altered macrophage (phagolysosomal) response. *Human Pathol.* **5**, 191-207, 1974.
13. Rao, N. R.: Malacoplakia of broad ligament, inguinal region, and endometrium. *Arch. Pathol.* **88**, 85-88, 1969.
14. van der Walt, J. J., Marcus, P. B., de Wet, J. J. and Burger, A. J. J.: Malacoplakia of the vagina. First case report. *S. Afr. Med. J.* **47**, 1342-1344, 1973.
15. Gupta, R. K., Schuster, R. A. and Christian, W. D.: Autopsy findings in a unique case of malacoplakia. A cytoimmunohistochemical study of Michaelis-Gutmann bodies. *Arch. Pathol.* **93**, 42-48, 1972.
16. Sinclair-Smith, C., Kahn, L. B. and Cywes, S.: Malakoplakia in childhood. Case report with ultrastructural observations and review of the literature. *Arch. Pathol.* **99**, 198-203, 1975.
17. Mirra, J. M.: Aortitis and malacoplakia-like lesions of the brain in association with neonatal herpes simplex. *Am. J. Clin. Pathol.* **56**, 104-110, 1971.
18. Moore, W. M., Stokes, T. L. and Cabanas, V. Y.: Malakoplakia of the skin: report of a case. *Am. J. Clin. Pathol.* **60**, 218-221, 1973.
19. Price, M. H., Hanrahan, J. B. and Florida, R. G.: Morphogenesis of calcium laden cytoplasmic bodies in malakoplakia of the skin. *Human Pathol.* **4**, 381-394, 1973.
20. Miller, O. S. and Finck, F. M.: Malacoplakia of the kidney: the great impersonator. *J. Urol.* **103**, 712-717, 1970.
21. Ravel, R.: Megalocytic interstitial nephritis. An entity probably related to malacoplakia. *Am. J. Clin. Pathol.* **47**, 781-789, 1967.
22. Terner, J. Y. and Lattes, R.: Malacoplakia of colon and retroperitoneum. Report of a case with a histochemical study of the Michaelis-Gutmann inclusion bodies. *Am. J. Clin. Pathol.* **44**, 20-31, 1965.
23. van Zile Scott, E. and Scott, W. F., Jr.: A fatal case of malakoplakia of the utinary tract. *J. Urol.* **79**, 52-56, 1958.
24. Haukohl, R. S. and Chinchinian, H.: Malakoplakia of the testicle. Report of a case. *Am. J. Clin. Pathol.* **29**, 478-478, 1958,