

# *Acta Medica Okayama*

---

*Volume 24, Issue 4*

1970

*Article 9*

AUGUST 1970

---

## Uncommon cases of foreign bodies in the esophagus—duplex coins

Yoshio Oguri\*

Seido Tasaka†

\*Okayama University,

†Okayama University,

# Uncommon cases of foreign bodies in the esophagus—duplex coins\*

Yoshio Oguri and Seido Tasaka

## **Abstract**

Two cases of multiple foreign bodies, i. e., duplex coins in the esophagus are reported. These foreign bodies were removed by peroral esophagoscopy successfully. Significance of roentgen-ray diagnosis is emphasized, and subtle and yet specific roentgenograms of duplex coins in the esophagus are illustrated.

Acta Med. Okayama 24, 483—487 (1970)

**UNCOMMON CASES OF FOREIGN BODIES IN THE  
ESOPHAGUS  
— DUPLEX COINS —**

Yoshio OGURA and Seido TAsAKA

*Department of Oto-Rhino-Laryngology, Okayama University Medical School,  
Okayama, Japan (Director: Prof. S. Takahara)*

*Received for publication, June 14, 1970*

Although a coin is the most common foreign body to become lodged in the esophagus, its multiple occurrence seems to be rare. We wish to record two cases of two coins lodged in the esophagus, one in the upper esophagus and the other above the third esophageal constriction.

Case 1.

T. N., a boy, two and a half years old was admitted to the hospital on July 21, 1965. His mother gave a history of the boy having swallowed a coin one hour before his admission. An attempt to have him cough it out was not successful.

*Physical Examination*: On inspection the child looked pale and appeared to be in slight distress. His breathing was normal. There was no cough. The rest of the examination was within normal limits.

Roentgenogram showed a round shadow just below the cricopharyngeal pinchcock, (Fig. 1). The shadow was coin-sized but slightly elongated with some indistinct shadow at the upper and lower edges. This was suggestive of the possibility of multiple coins, one on top of the other. A lateral projection gave no additional information.

*Esophagoscopy*: Upon esophagosopic inspection two ten-yen copper coins were lodged one on top of the other at the site, corresponding to the X-ray film. The invading objects were tightly impacted in the esophageal wall. They were removed one at a time (Fig. 2).

Case 2.

M. M. An eight-year-old boy was admitted to the hospital on August 27, 1965 with a history of having accidentally swallowed coins while playing with them in his mouth for two hours prior to his admission. The history given by the family shed no additional light as to the possibility of multiple foreign bodies.

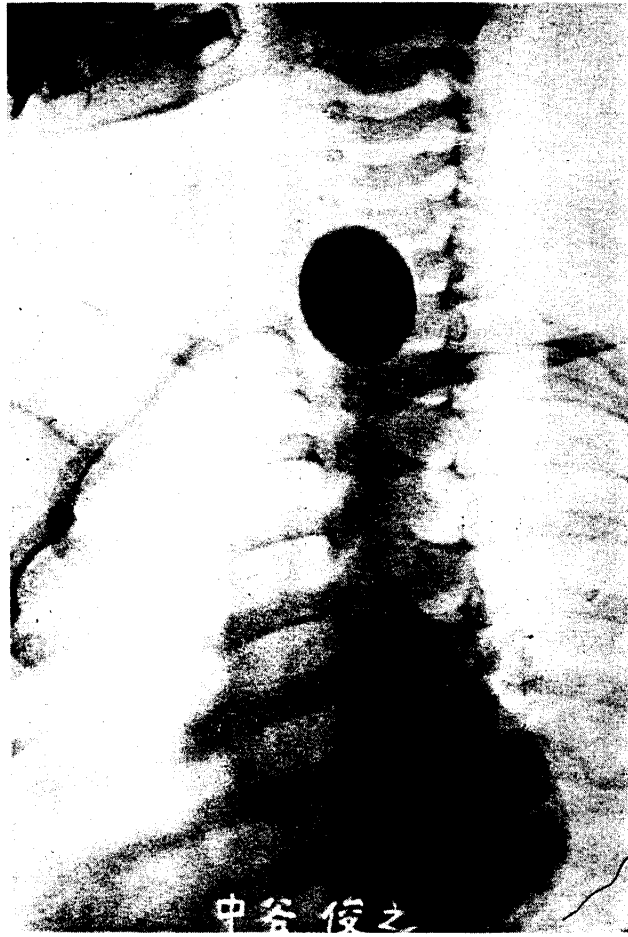


Fig. 1 Roentgenogram of coin in esophagus, Case 1, 2 ½-year old boy.




Fig. 2 Coins removed out from esophagus of Case 1.

*Physical Examination:* Normally developed and well-nourished boy. No respiratory distress or cough. All other physical examinations were normal.

*Roentgenological Findings:* Roentgenogram showed a coin-sized round shadow a little above the third constriction of the esophagus (Fig. 3). On closer inspection this round shadow looked slightly elongated longitudinally with some fading at the upper and lower edges, much similar to the first case. Fluoroscopic examination at various projections failed to give any definite diagnostic information of multiple foreign bodies.

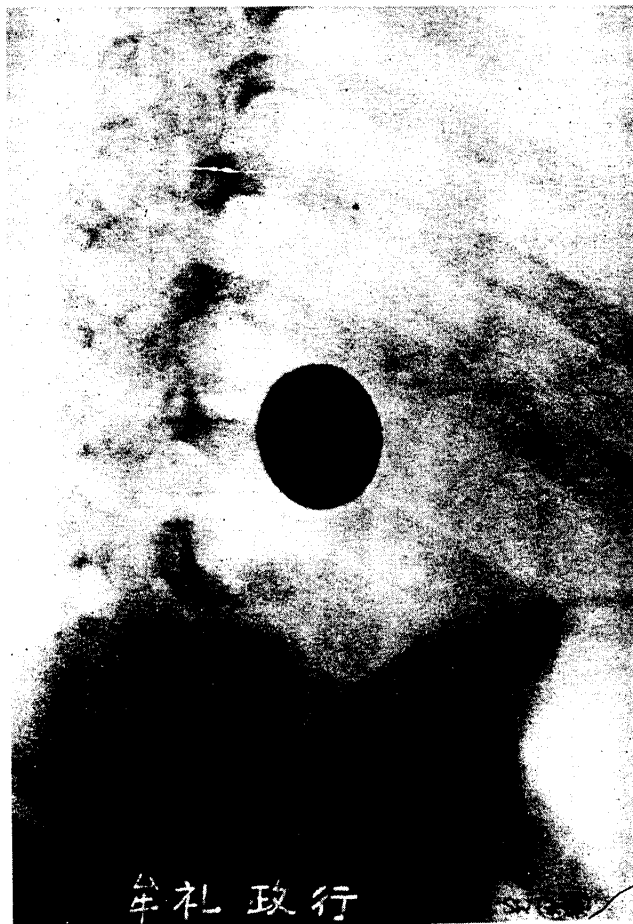

Fig. 3 Roentgenogram of Case 2, an 8-year old boy.

*Course and Treatment:* The boy was kept in the hospital overnight. He was slightly nauseated and vomited once or twice during the night. Fluoro-

scopic study the next morning revealed the foreign body at the same site.

Esophagoscopy showed two ten-yen coins lodged above the third constriction. They were grasped with sharp pointed forceps and extracted together (Fig. 4). The boy was given antibiotic therapy. Two days later he was dismissed with no complications.




Fig. 4 Two coins taken out from Case 2.

#### COMMENT

The occurrence of multiple foreign bodies of coins is rather rare, though a coin is one of the most common objects encountered in the esophagus, especially in children.

In YAMAKAWA'S 21 years' statistics (1), among which were 420 cases of coins as foreign bodies, there were only four instances of multiple coin occurrences.

In our review of Japanese literature over a 40-year period, there were recorded only 30 cases of multiple foreign bodies of coins including the present ones.

SATO (2) recorded a case in which four coins were lodged in one area. This was the largest number listed. IDE (3) reported two cases, each having multiple coin esophageal foreign bodies. SASAKI (4) and YAMADA (5) held the view that coins rarely lodged at the third esophageal constriction. Thus, our second case was considered rare as to the site of the lodging.

No physician can fail to recognize the presence of a coin in the esophageal roentgenogram, but to delineate two objects, such as coins of the same size and shape is truly a challenge. These objects tend to stick together and the double dimensional projections often fail to indicate their presence.

Therefore, it should be borne in mind that all foreign body cases should possibly be multiple, and close and careful evaluation of the roentgenograms only may present a clue to the diagnosis.

In cases of multiple foreign bodies of coin, even though they stick together concentrically as in the above mentioned instances, precisely speaking, they may not be in complete alignment with each other. And so, the figure on the roentgenogram looks a little oval. Moreover, fine sight can catch meniscus-shaped indistinctness at the top and bottom of the round opacity. IDE (3) and UNGERECHT (8) mentioned it, and the textbook of ECKERT-MÖBIUS (9) is illustrated with such a roentgenogram.

#### SUMMARY

Two cases of multiple foreign bodies, i. e., duplex coins in the esophagus are reported. These foreign bodies were removed by peroral esophagoscopy successfully. Significance of roentgen-ray diagnosis is emphasized, and subtle and yet specific roentgenograms of duplex coins in the esophagus are illustrated.

#### ACKNOWLEDGEMENT

Thanks are due to Dr. H. JAMES HARA, Professor Emeritus of Loma Linda University at Los Angeles and Dr. S. TAKAHARA, Professor and Chairman of the Department of Oto-Rhino-Laryngology of Okayama University Medical School for painstaking proof-reading of this manuscript.

#### REFERENCE

1. YAMAKAWA, K.: Foreign body in the esophagus. *Nichijibi-Zensho* 4 (1), 55, 1953 (in Japanese)
2. SATO, M. *et al.*: Double foreign bodies in the esophagus (four ten-yen coins.), *Jibiinkoka* 30, 989, 1958 (in Japanese)
3. IDE, M.: Two cases of double foreign bodies in the esophagus - one, two one-sen coins; the other, three one-sen coins. *Jibiinkoka* 12, 124, 1939 (in Japanese)
4. SASAKI, M.: Foreign body in the esophagus. *Nichijibi-Zensho* 10 (1), 93, 1933 (in Japanese)
5. YAMADA, K. *et al.*: Seven years' statistics of foreign bodies in the air and food passages. *J. Japan Bronchoesphagol. Soc.* 16, 155, 1965 (in Japanese)
6. NAKAO, M.: Double foreign bodies in the esophagus-three 50-sen coins. *Jibiinkoka* 12, 128, 1939 (in Japanese)
7. KOYAMA, H.: Foreign bodies in the esophagus. *J. Japan Oto-Rhino-Laryng. Soc.* 67, 210, 1964 (in Japanese)
8. UNGERECHT, K.: Hals-Nasen-Ohren Heilk. (Berendes-Link-Zöllner) Bd. 2, T. 1, S. 583, 1963
9. ECKERT-MÖBIUS, A.: Lehrbuch der HNO-Heilkunde (2te Auflage), p. 65, 1966
10. JACKSON, C. and JACKSON, C. L.: *Bronchoesophagology*, p. 256, 1955