

Acta Medica Okayama

Volume 61, Issue 2

2007

Article 9

APRIL 2007

Unusual abscesses associated with colon cancer: report of three cases

Atsushi Okita* Yoshiro Kubo† Minoru Tanada‡
Akira Kurita** Shigemitsu Takashima††

*Shikoku Cancer Center,

†Shikoku Cancer Center,

‡Shikoku Cancer Center,

**Shikoku Cancer Center,

††Shikoku Cancer Center,

Unusual abscesses associated with colon cancer: report of three cases*

Atsushi Okita, Yoshiro Kubo, Minoru Tanada, Akira Kurita, and Shigemitsu Takashima

Abstract

Three cases of colon cancer accompanied by unusual abscess formation are reported. Case I : A 77-year-old man was diagnosed with a paracolic abscess formation behind the cecum and a swollen appendix by computed tomography (CT) scan. Case II : An 85-year-old woman was diagnosed with an abscess formation of the right iliopsoas muscle, a swollen appendix, and a thickened right colon wall by CT scan. After antibiotic therapy failed, both patients underwent ileocecal resection urgently under suspicion of appendicitis, but cecal cancer around the entrance to the appendix caused secondary appendicitis in both cases. Case III : A 50-year-old woman was diagnosed with sigmoid colon cancer with an abscess formation in the pelvic cavity concomitant with ovarian tumor. A Hartmann procedure was performed, and a pathological examination revealed that a subserosal abscess behind the sigmoid colon cancer perforated the rectum with abscess formation. All cases were definitively diagnosed intraoperatively. The cancer recurred in cases I and III. We emphasize that precise surgical evaluation has an important role in the diagnosis of these complicated diseases. In addition, surgery affords the patient the best chance of recovery, and in these advanced cases radical treatment is recommended as early as possible.

KEYWORDS: abscess formation, colon cancer

Case Report

Unusual Abscesses Associated with Colon Cancer: Report of Three Cases

Atsushi Okita*, Yoshiro Kubo, Minoru Tanada,
Akira Kurita, and Shigemitsu Takashima

Department of Surgery, Shikoku Cancer Center, Matsuyama 791-0288, Japan

Three cases of colon cancer accompanied by unusual abscess formation are reported. Case I: A 77-year-old man was diagnosed with a paracolic abscess formation behind the cecum and a swollen appendix by computed tomography (CT) scan. Case II: An 85-year-old woman was diagnosed with an abscess formation of the right iliopsoas muscle, a swollen appendix, and a thickened right colon wall by CT scan. After antibiotic therapy failed, both patients underwent ileocecal resection urgently under suspicion of appendicitis, but cecal cancer around the entrance to the appendix caused secondary appendicitis in both cases. Case III: A 50-year-old woman was diagnosed with sigmoid colon cancer with an abscess formation in the pelvic cavity concomitant with ovarian tumor. A Hartmann procedure was performed, and a pathological examination revealed that a subserosal abscess behind the sigmoid colon cancer perforated the rectum with abscess formation. All cases were definitively diagnosed intraoperatively. The cancer recurred in cases I and III. We emphasize that precise surgical evaluation has an important role in the diagnosis of these complicated diseases. In addition, surgery affords the patient the best chance of recovery, and in these advanced cases radical treatment is recommended as early as possible.

Key words: abscess formation, colon cancer

Colorectal cancers are among the common malignancies. Typical presenting symptoms related to colorectal cancer include a change in bowel habits with increasing constipation or spurious diarrhea, lower abdominal pain, pencil-shaped stool, visible blood in the stool, weakness, and weight loss [1]. However, colorectal cancer does not always present with such familiar symptoms [2]. It is another of the "great imitators", and the variability of its presentation is well documented [3]. For example, less com-

mon manifestations include perforation and abscess formation, which are usually intraperitoneal but may also be located in the extraperitoneal spaces [4]. Such cases often present with atypical clinical findings and are difficult to diagnose accurately by radiographic studies. In addition, a delay in diagnosis and inadequate management usually aggravate morbidity and mortality [4]. We report 3 cases of colon cancer presenting with unusual abscess formation. Few reports of this entity have been published. We also discuss the management of this unusual colon cancer through our experience.

Received April 11, 2006; accepted November 27, 2006.

*Corresponding author. Phone: +81-86-472-8111; Fax: +81-86-472-8116
E-mail: hospital@city.kurashiki.okayama.jp (A. Okita)

Case Report

Case I. A 77-year-old man was admitted to a hospital with a 4-day history of fever and abdominal pain. Appendicitis or diverticulitis was suspected. Antibiotic therapy for 7 days did not improve the patient's condition. Moreover, carcinoembryonic antigen was elevated to 14.0 ng/ml (normal range: less than 2.5 ng/ml). From these results, an ileocecal malignancy was suspected to have caused this persistent inflammation, and the patient was referred to our hospital. A physical examination showed that the right lower abdomen was tender. Laboratory data showed a white blood cell (WBC) count of $10,900/\text{mm}^3$ (normal range: $3,500\text{--}8,500/\text{mm}^3$), and a C reactive protein (CRP) level of 17.63 mg/dl (normal range: less than 0.3 mg/dl). A CT scan revealed a thickened cecum wall, a swollen appendix, and the spread of inflammation to the paracolic fat tissue with abscess formation behind the cecum or ascending colon (Fig. 1A, B). An appendicitis caused by malignancy was highly suspected, and emergency laparotomy was performed. The cecum wall and the retroperitoneum were thickened, and the abscess formation was located between the right-sided colon and the retroperitoneum. Ileocecal resection combined with lymph node dissection and partial resection of the renal fascia was performed. There were no distant metastases, and the lesion was completely excised. The resected specimen contained a cecal tumor that had obstructed the entrance to the appendix and that had caused appendicitis (Fig. 1C). Cultures of the abscess fluid yielded *Proteus vulgaris*, *Prevotella bivia*, and *Flavobacterium species*. A wound abscess and herniation developed on the 5th postoperative day (POD). The patient underwent surgery for an abdominal hernia on the 24th POD. However, the wound became also infected and spontaneously opened, and the patient's discharge was delayed until the 55th POD. A pathological examination showed a moderately differentiated adenocarcinoma, ulcerated type with a clear margin, with subserosal invasion and nodal involvement classified as stage IIIB: T3N1M0 according to the TNM classification. On a follow-up examination 6 months after the operation, a CT scan revealed multiple liver metastases, and treatment with 5'-deoxy-5-fluorouridine was begun. Nine months after the initial operation, a tho-

racic aortic aneurysm and pneumonia occurred and the patient received conservative care, but soon thereafter did not visit our hospital.

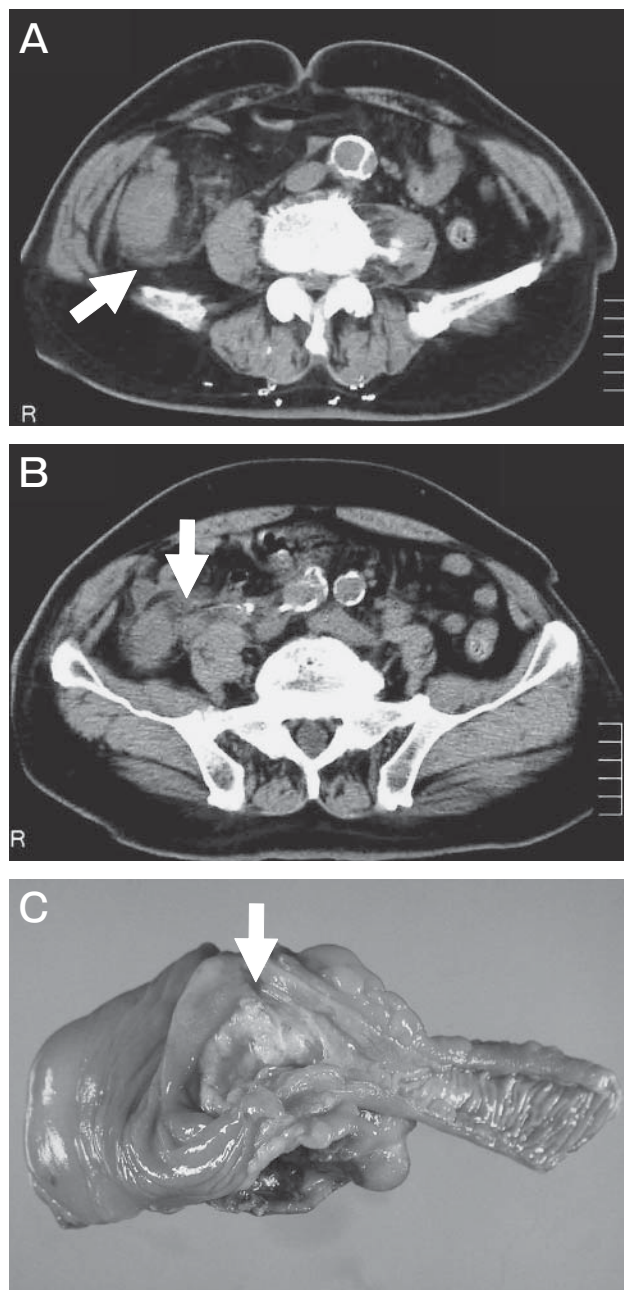


Fig. 1 Case I
A, An abscess between the ascending colon and the retroperitoneum (arrow); **B**, The appendix was swollen (arrow); **C**, A cecal tumor at the entrance to the appendix in the resected specimen (arrow).

Case II. An 85-year-old woman visited a hospital with a 4-day history of an abdominal mass. A tumor in the right lower abdomen with invasion of adjacent organs was identified on a CT scan, and the patient was referred to our hospital. A physical examination revealed a tender, localized mass in the right lower abdomen. Laboratory data showed a WBC count of $10,300/\text{mm}^3$ and a CRP of 18.74 mg/dl . A CT scan revealed a low-density area in the swollen right iliopsoas muscle accompanied by an increased density of surrounding fat tissue and a swollen appendix. In addition, the wall of the ascending colon was thickened with a spiculated contour (Fig. 2A, B). Because acute appendicitis or diverticulitis with right iliopsoas abscess formation was suspected, treatment with fosfomycin was started immediately. However, the patient's condition deteriorated. Two days after admission, a follow-up CT scan revealed the swelling of the right iliopsoas muscle was aggravated with gas and polycystic parts. Fluid was also collecting in the Douglas pouch. The abscess became multilocular and difficult to drain percutaneously, and the patient immediately underwent laparotomy. An abscess formation was found in the retroperitoneum and iliopsoas muscle, which were incised and opened. Ileocecal resection with lymph node dissection was performed because of severe inflammation of the cecum with lymphadenopathy. The resected specimen revealed a tumor at the base of the appendix, which had induced secondary appendicitis and abscess formation (Fig. 2C). Cultures of the abscess yielded *Streptococcus*, *Prevotella buccae*, and *Bacteroides thetaiotaomicron*. There were no malignant cells in the peritoneal effusion. The postoperative course was uneventful, and the patient was discharged on the 11th POD. A pathological examination showed that the tumor was a well differentiated adenocarcinoma, ulcerated with a clear margin and 3.6 by 3.2 cm in size with invasion of non-peritonealized, pericolic tissues. It was classified as stage IIIA: T3N1M0 according to the TNM classification. Adjuvant therapy was not performed, and the patient has been well without any evidence of recurrence for 3 years after surgery.

Case III. A 50-year-old woman went to a hospital with a 3-day history of fever. A right ovarian tumor and abscess formation in the Douglas pouch were identified on a CT scan, and the patient was

referred to our hospital's department of gynecology. A physical examination showed that the lower abdomen was tender. Laboratory data showed a WBC

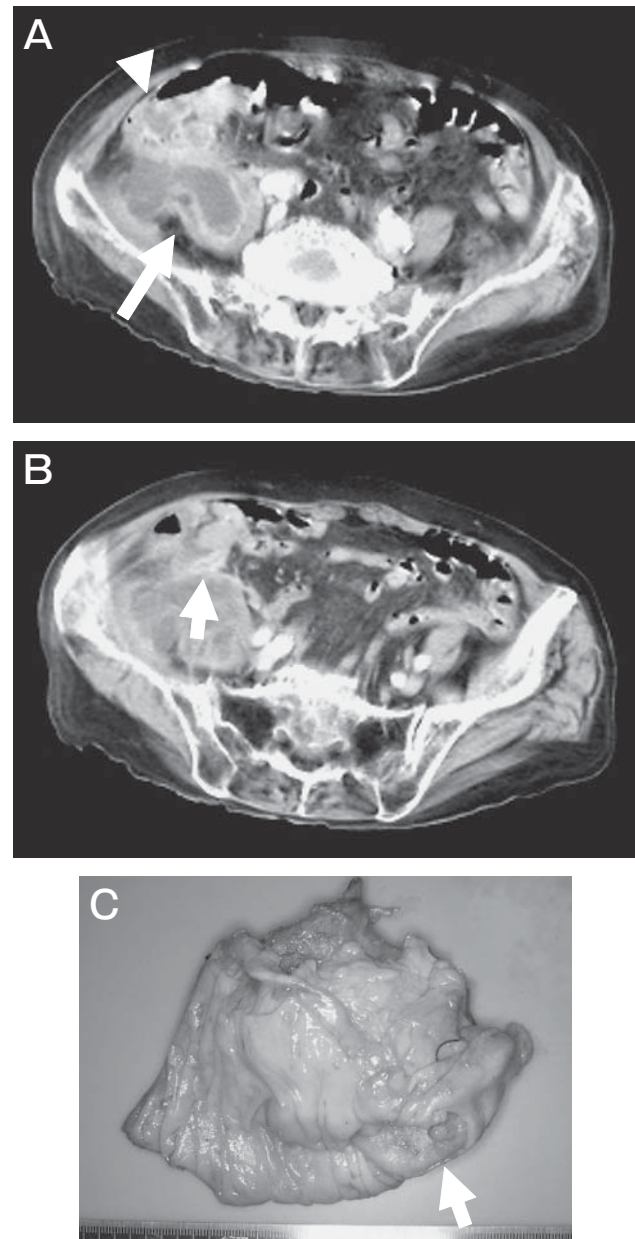


Fig. 2 Case II

A, The swelling iliopsoas muscle included a low-density area (arrow), and the ascending colon showed a thickened wall and a spiculated outer margin (arrowhead); B, The appendix was swollen (arrow); C, A cecal tumor at the entrance to the appendix in the resected specimen (arrow).

count of 10,400/mm³ and a CRP of 9.52 mg/dl. CA125 was elevated to 49.3 U/ml (normal range: less than 35 U/ml). On CT, an air-containing 5.5-cm-diameter round mass was located adjacent to the sigmoid colon in the pelvic cavity and was diagnosed with an abscess (Fig. 3A). In addition, magnetic resonance imaging (MRI) showed that a 7-cm-diameter cystic mass containing a solid component

was found on the right side of the uterus (Fig. 3B). An X-ray examination of the large intestine and a CT scan showed obstruction of the sigmoid colon with a thickened wall (Fig. 3A, C). Because these findings suggested sigmoid colon cancer and an ovarian tumor with abscess formation in the Douglas pouch, the patient was referred to our department 3 days later and underwent an emergency operation. There was

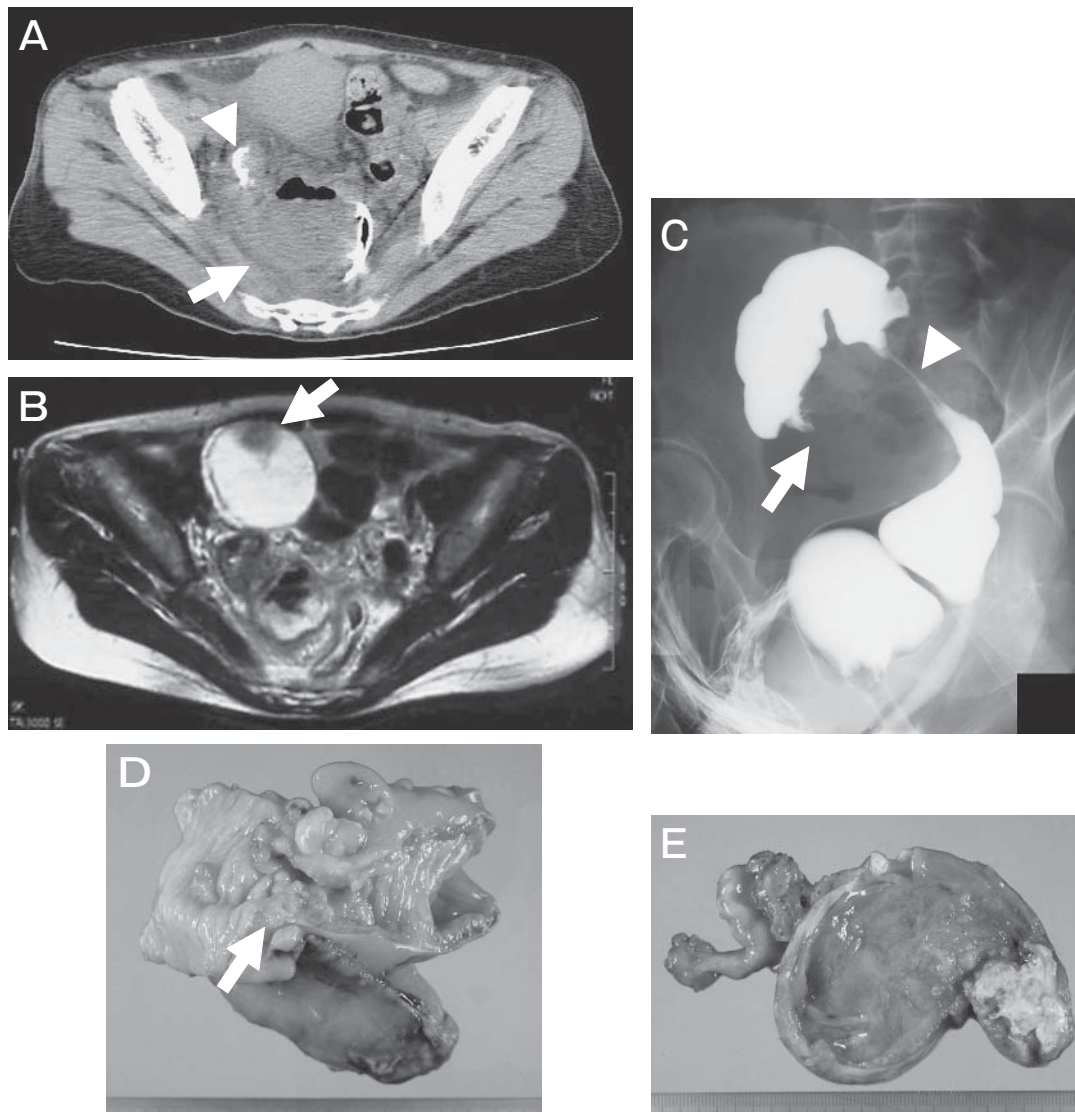


Fig. 3 Case III

A, An abscess in the pelvic cavity (arrow), and contrast medium was tapered off at the sigmoid colon with a thickened wall close to the abscess (arrowhead); B, A 7-cm-diameter cystic mass containing a solid component (arrow); C, An obstruction of the sigmoid colon (arrow) and a stenosis of the rectum (arrowhead) on X-ray examination; D, The sigmoid colon cancer involved the rectum (arrow); E, The right ovary became a cystic mass containing a solid tumor diagnosed with metastasis of the sigmoid colon cancer.

100 ml of light bloody peritoneal effusion, which contained no malignant cells. We found the sigmoid colon mass with perforation to the rectum and an abscess between the sigmoid colon and the rectum. The right ovary had become a 6-cm-diameter cystic mass. A Hartmann procedure with lymph node dissection and bilateral oophorectomy was performed. Examination of the resected specimen revealed a 5-by-3-cm tumor perforating the rectum (Fig. 3D). The right ovary contained a light-yellowish transparent fluid and a 4.5-by-3.8-cm solid tumor depicting metastasis of the sigmoid colon cancer by examination of the frozen specimen (Fig. 3E). Cultures of abscesses yielded α - and γ -*Streptococcus*, *Candida albicans*, and *Actinomyces viscosus*. A pathological examination showed a moderately differentiated adenocarcinoma, an ulcerated tumor with a clear margin with subserosal invasion, and no lymph node metastases. This case was classified as stage IV: T3N0M1 according to the TNM classification. It was estimated that a subserosal abscess developed behind the ulcer of the tumor and was covered by both the sigmoid colon and the rectum. The postoperative course was uneventful, and the patient was discharged on the 15th POD. Two months after surgery, liver and peritoneal metastases were discovered by CT scan. However, the patient is alive 1 year after surgery, and has shown a partial response to chemotherapy with 5-fluorouracil and *l*-leucovorin.

Discussion

We have treated 2 patients with cecal cancer that induced appendicitis with abscess formation and 1 patient with sigmoid colon cancer that perforated the rectum with abscess formation in the pelvic cavity. One-third of patients with colon cancer have major complications, such as involvement of adjacent organs or structures, obstruction, or perforation [5]. Abscess formation, however, is rare, occurring in 0.3% to 4% of cases of colon cancer, but it is the second most common presentation of perforative lesions [6]. Michowitz *et al.* have proposed the following clinical classification of perforation-complicated carcinoma of the colon: 1) free perforation with leakage of the bowel contents into the peritoneal cavity; 2) covered perforation with local abscess formation; 3) perforation into one of the neighboring

organs or formation of a fistula [7]. Perforation in colon cancer occurs commonly, due either to direct perforation from tumor necrosis or to proximal colon blow-out from an obstructed tumor and a competent ileocecal valve producing a closed loop [8]. Although the mechanism of abscess formation remains unclear, by outstripping the blood supply, tumor growth may contribute to abscess production in the presence of enteric organisms [3]. Suppuration due to the leakage of bowel contents from perforated tumors may lead to various unusual presentations, such as retroperitoneal, subcutaneous, and perinephric abscess; perirectal abscess or fistula; and acute appendicitis and appendicular abscess [1].

Acute appendicitis with or without abscess formation is a common disease. Luminal obstruction by a fecalith or lymphoid hypertrophy is the most common factor precipitating acute appendicitis in children and young adults [9]. Cecal cancer rarely presents as acute appendicitis [10], but many clinicians believe that acute appendicitis in an elderly patient strongly suggests an underlying cecal cancer, as first described by Shears in 1906 [11]. Several papers suggest that 10% to 25% of elderly patients presenting with acute appendicitis have an underlying cecal cancer as its proximate cause [12, 13].

The accurate preoperative diagnosis of abscess formation related to colon cancer is considered difficult. Nevertheless, the surgeon must determine the source of any abscess as quickly as possible. In history-taking or during a physical examination, the hallmarks of abscess formation are the presence of fever, pain, a palpable mass, or leukocytosis [3], and a malignant neoplasm should be suspected in patients with an atypical history of prolonged symptoms, a palpable mass, weight loss, or anemia [14]. In laboratory data, tumor markers may be also useful for detecting colon cancer, but elevations of such markers are not unique to colon cancer and are not recommended to be used to screen asymptomatic patients [15]. In conventional radiographic studies, roentgenograms detect indirect signs, such as displacement of the ureter, alteration of the psoas margin, scoliosis, ileus, abnormal masses, and extraluminal gas [3, 16], or a barium enema may demonstrates the neoplasm, a fistulous tract, or an abscess cavity [3]. Colonoscopy is useful for direct objective investigation of the tumor features, but in our cases,

under emergency and debilitated conditions, we did not perform colonoscopy because of the possibility of insufficient irrigation or the increased leakage of bowel contents. CT scanning, because of its exquisite imaging capabilities, is an ideal tool for evaluating suspected abscesses, and colorectal cancer appears as a discrete mass or focal wall thickening. Although these are nonspecific findings [17], CT is useful for providing valuable staging information for the preoperative assessment of colorectal cancer [18] rather than as a primary diagnostic tool in the detection of colonic cancer. Even though abscesses were diagnosed, conventional radiographic imaging diagnosis has limitations. These nonspecific signs and symptoms do not allow us to diagnose the causes of abscesses, especially the presence of cancer, and may contribute to a significant delay in diagnosis. In fact, we were able to locate the tumor preoperatively in only one case III. Especially, when acute inflammation of the appendix and carcinoma of the cecum coexist, accurate diagnosis is extremely difficult [11]. In cases I and II, we had to evaluate the presence of malignancy intraoperatively. The exact diagnosis must often depend on intraoperative examinations in an urgent operative setting. During the operation, thorough evaluation of the colorectum by palpation and visualization is required. However, because of a limited surgical field or difficulty in exploring inflamed areas, a malignant tumor may be missed even during surgery if we do not initially suspect that the existence of a malignant tumor has caused abscess formation. Especially, the inflammatory reaction and the associated colorectal induration may conceal the presence of a colorectal mass. When it is impossible to differentiate a fibrotic mass from a neoplasm with the naked eye, microscopic examination of frozen sections may be useful. Various combinations of these methods are usually needed to establish a definitive diagnosis. In fact, the coexistence of cecal cancer and acute appendicitis is relatively rare, but it should be kept in mind in elderly patients with persistent appendicitis. When preoperative diagnosis is uncertain, we recommend carefully evaluating and palpating the colon intraoperatively. If the tumor induced inflammation, the abscess was absolutely formed close to the tumor in the inflamed colon. Nevertheless, since an accurate diagnosis is uncertain, we recommend immediately resecting the

inflamed colon and evaluating the specimen. Actually we performed colectomy in all cases and successfully identified colon cancer intraoperatively.

Patients with colorectal cancer who present with major complications are generally considered to have lower crude survival and higher operative mortality rates [5]. Michowitz *et al.* have reported operative mortality and 5-year survival rates of 50% and 20%, respectively, in a small study of patients with colon cancer complicated by local abscess [7]. No large studies have evaluated operative mortality, morbidity, and prognosis in patients with colorectal cancer complicated by peritoneal abscess. This unfavorable prognosis may contribute to a high operative mortality rate due to sepsis, locally advanced malignancy, and a higher incidence of distant metastasis at presentation. Complete resection of the colon cancer and the abscess wall is preferable, but the patients are usually old and a poor operative risk, and most surgeons have often wavered in judging whether to perform a minimal procedure and postpone a major procedure until the patient's condition improves or to perform major procedure immediately in light of the operative risk [7]. Unless surgery is contraindicated by the patient's general condition, percutaneous aspiration and indwelling catheter drainage combined with antibiotic therapy may be immediately started without further diagnostic work-up. However, the drainage procedure may alleviate much of the toxemia, and concomitant resection should be carried out if possible to eradicate the source of sepsis [3]. In extensive sepsis, anastomosis of the colon may be risky, and a staged procedure is often recommended. Freeman *et al.* have recommended that perforative colon cancer with abscess formation is best treated with a preliminary totally diverting colostomy and local drainage of the abscess with the use of appropriate antibiotics; otherwise, perforated cecal cancer is not amenable to a proximal diverting colostomy, in which case, primary resection of the right colon with adequate drainage is recommended [19]. With recent advances, factors such as perforation, peritonitis, and pus are not contraindications to primary operation. Primary resection and anastomosis for perforated left colon lesion can also be safely performed even in the presence of peritonitis in selected patients [20]. Even when patients survive surgery, incomplete tumor clearance may increase

the risk of local recurrence in advanced cases. Actually, we could have performed complete excision of the tumor lesion, but all 3 cases were advanced and had a high risk of recurrence. Peritoneal recurrence developed in case III, and liver metastasis developed in cases I and III after the operation. On the other hand, there was no recurrence in case II. Case III already had synchronous ovarian metastasis, and recurrence was perhaps inevitable. The severity of inflammation may not be related to the prognosis. Smothers *et al.* in a small study reported that the negative effect of emergency surgery on outcome may be limited to the perioperative period and in the overall survival for patients who survived surgery, the survival rate for patients undergoing emergency surgery was equivalent to that for patients undergoing elective surgery [21]. In addition, the survival time is not influenced by the type of perforation but is influenced by the stage of tumor invasion [7]. If possible, a major procedure for complete resection should be performed.

In conclusion, we have treated three cases of colon cancer with unusual abscess formation. Accurate preoperative diagnosis of these entities is extremely difficult despite recent developments in imaging techniques. However, it is important to focus on a differential diagnosis, including colon cancer by combinations of diagnostic modalities, to some extent preoperatively. Especially, CT scans revealed all aspects of colon lesions and were useful for assessing the status of abscesses, but exact diagnoses were possible only during surgery after all, and we recommend resecting the inflamed colon and immediately evaluating the specimen. In patients with persistent abscess formation, the concomitant presence of colon cancer must be considered. In the light of high invasiveness, radical treatment is recommended as early as possible if there are no distant metastases or peritoneal disseminations.

References

1. Panwalker AP: Unusual infections associated with colorectal cancer. *Rev Infect Dis* (1988) 10: 347-364.
2. Muir EG: The diagnosis of carcinoma of the colon and rectum: a review of 714 cases. *Br J Surg* (1956) 44: 1-7.
3. Welch JP: Unusual abscesses in perforating colorectal cancer. *Am J Surg* (1976) 131: 270-274.
4. Maglente DDT and Pollack HM: Retroperitoneal abscess: a presentation of colon carcinoma. *Gastrointest Radiol* (1983) 8: 177-181.
5. Kelley WE Jr, Brown PW, Lawrence W Jr and Terz JJ: Penetrating, obstructing, and perforating carcinomas of the colon and rectum. *Arch Surg* (1981) 116: 381-384.
6. Peterson CM, Allison JG and Lu CC: Psoas abscess resulting from perforating carcinoma of the sigmoid colon: Report of a case. *Dis Col and Rect* (1983) 26: 390-392.
7. Michowitz M, Avnieli D, Lazarovici I and Solowiejczyk M: Perforation complicating carcinoma of colon. *J Surg Oncol* (1982) 19: 18-21.
8. Mandava N, Kumar S, Pizzi WF and Aprile IJ: Perforated colorectal carcinomas. *Am J Surg* (1996) 172: 236-238.
9. Collins DC: Etiologic factors in acute appendicitis based upon study of 3,400 cases. *Surgery* (1939) 5: 267-270.
10. Armstrong CP, Ahsan Z, Hinchley G, Prothero DL and Brodribb AJM: Appendectomy and carcinoma of the caecum. *Br J Surg* (1989) 76: 1049-1053.
11. Burt CAV: Carcinoma of the cecum complicated by appendicitis or para-cecal abscess. *Surg Gynecol Obst* (1949) 88: 501-508.
12. Patterson JF Jr and Deaver JM: Carcinoma of the cecum. *Am J Surg* (1951) 81: 618-621.
13. Hellsten H and Ramstorm S: Coexistent cecal cancer and appendicular abscess. *Arch Surg* (1951) 62: 112-117.
14. Ramsay JA, Rose TH and Ross T: Colonic carcinoma presenting as an appendical abscess in a young woman. *Can J Surg* (1996) 39: 53-56.
15. American society of clinical oncology: Clinical practice guidelines for the use of tumor markers in breast and colorectal cancer. *J Clin Oncol* (1996) 14: 2843-2877.
16. Llauger J, Perez C, Andreu J and Palmer J: Psoas abscess demonstrated by CT as the first evidence of carcinoma of the colon. *Comput Radiol* (1987) 11: 259-261.
17. Thoeni RF: Colorectal cancer. Radiologic staging. *Radio Clin Nor Am* (1997) 35: 457-485.
18. Johnson CD: Computed tomography of the large bowel and appendix. *Mayo Clin Proc* (1989) 64: 1276-1283.
19. Freeman HP, Oluwole SF and Ganepola GAP: Unusual presentations of carcinoma of the right colon. *Cancer* (1979) 44: 1533-1537.
20. Umbach TM and Dorazio RA: Primary resection and anastomosis for perforated left colon lesions. *Am Surg* (1999) 65: 931-933.
21. Smothers L, Hynan L, Fleming J, Turnage R, Simmang C and Anthony T: Emergency surgery for colon carcinoma. *Dis Colon Rectum* (2003) 46: 24-30.

1. Panwalker AP: Unusual infections associated with colorectal can-