

Acta Medica Okayama

Volume 37, Issue 3

1983

Article 10

JUNE 1983

Central fibroma of the jaw bone: a case report.

Hironobu Tamura*

Katsumi Nishijima†

Shunichiro Nagahata‡

Toshichika Takahashi**

*Okayama University,

†Okayama University,

‡Okayama University,

**Okayama University,

Central fibroma of the jaw bone: a case report.*

Hironobu Tamura, Katsumi Nishijima, Shunichiro Nagahata, and Toshichika Takahashi

Abstract

Central fibromas developing from within the jaw bone are comparatively rare in contrast to fibromatoid lesions in other parts of the oral region. We report a 13-year-old girl with a central fibroma which developed in the jaw bone.

KEYWORDS: central fibroma, non-odontogenic tumor, lower margin of mandible, periosteal origin

Acta Med. Okayama 37, (3), 265—267 (1983)

— BRIEF NOTE —

CENTRAL FIBROMA OF THE JAW BONE: A CASE REPORT

Hironobu TAMURA, Katsumi NISHIJIMA, Shunichiro NAGAHATA
and Toshichika TAKAHASHI

*First Department of Oral and Maxillofacial Surgery, Okayama University Dental
School, Okayama 700, Japan (Director: Prof. Nishijima)*

Received January 7, 1983

Abstract. Central fibromas developing from within the jaw bone are comparatively rare in contrast to fibromatoid lesions in other parts of the oral region. We report a 13-year-old girl with a central fibroma which developed in the jaw bone.

Key words: central fibroma, non-odontogenic tumor, lower margin of mandible, periosteal origin.

Fibromatoid lesions in the oral region occur in the tongue, gingiva, oral mucosa and jaw bone, some developing inside the jaw bone and others from the periosteum (1-3). Central fibromas developing inside the jaw bone are somewhat rare (1-4) and the majority of them are considered to be of odontogenic origin. Non-odontogenic fibromas derived from the periosteum or perineurium have been reported (1, 2). We describe a central fibroma which developed in the lower left margin of the mandible.

A case report. A 13-year-old girl visited our department on December 26, 1979, complaining of a painless swelling of the lower left margin of the mandible which was first noticed about 3 months, and began to grow rapidly about a month before her visit.

Past and family histories revealed nothing in particular. She appeared physically normal and well nourished, although her face was slightly asymmetric. A thumb-sized, bone-like hard swelling was found on the lower left margin of the mandible, without swelling or tenderness of the left submandibular lymph nodes. The oral cavity was clean with a congenital anodontia of $\bar{5}$. Roentgenograms revealed a thumb-sized, well-defined and round radiolucent area on the lower left margin of the mandible where the bone was thin and bulged (Fig. 1). Laboratory examinations, including blood, urine, electrocardiogram, and chest X-ray, were normal. Local puncture proved the lesion to be solid. On January 22, 1980, a tumor was enucleated from the left mandible under general anesthesia. The tumor was well-defined without any adhesion to surrounding bone. The post-operative course has been satisfactory without recurrence.

The tumor was $20 \times 20 \times 20$ mm, elastic-hard, encapsulated, and grayish-

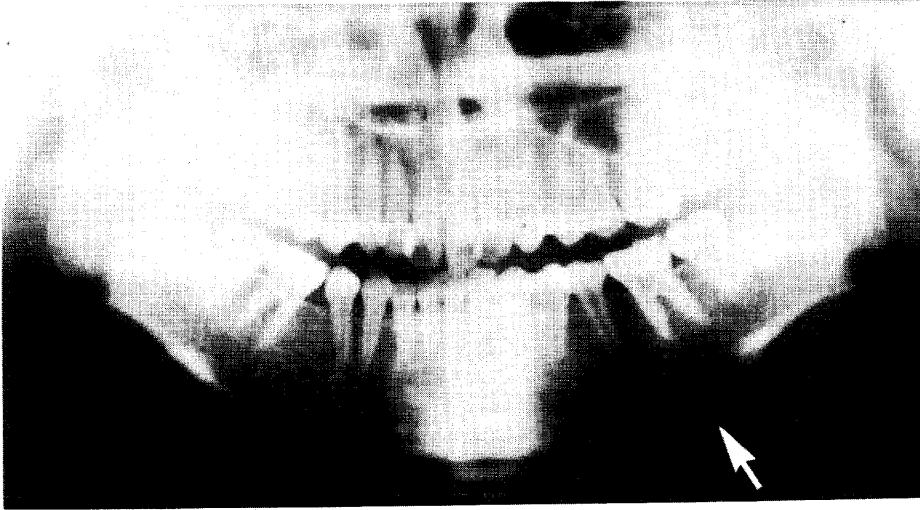


Fig. 1. Well-defined, thumb-sized radiolucent area on the lower left margin of the mandible.

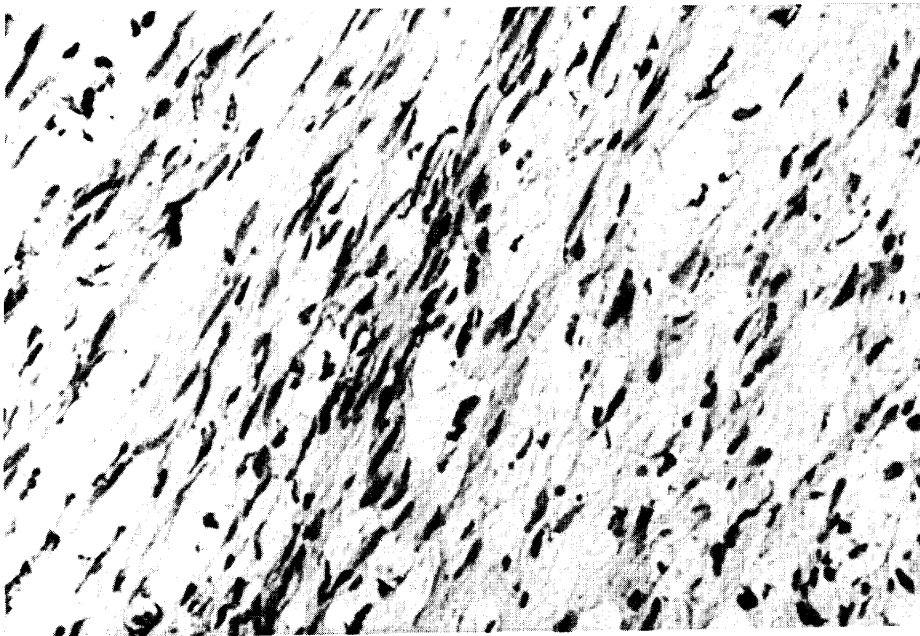


Fig. 2. Often observed fusiform cells with rich in chromatin.

white on both the exterior and cut surfaces. Microscopically, the tumor consisted of fusiform cells rich in chromatin. The tumor cells were arranged regularly in some parts and irregularly in others (Fig. 2). No mucosal epithelium or odontogenic cellular and calcium components were present.

Discussion. The jaw bone can have fibrous tumors of various pathogeneses, but central fibromas developing from within the jaw bone are rare (4) and usually considered to be odontogenic (1). Such central fibromas often develop in the mandible (1, 5-7), without sexual difference (1, 8, 9) and among relatively young people (1, 5-7). The chief complaint is bulging of the jaw bone (1), and X-ray examination shows a well-defined radiolucent area in most cases (1, 5). Histologically, among the fibromas described, there are simple fibromas, which are rare, and slightly calcified fibromas (1, 10). The tumors can be classified into odontogenic and non-odontogenic forms, pathogenetically. Ishikawa and Akiyoshi (1) have reported that odontogenic fibromas are derived from the dental papilla, dental sac or periodontal membrane, which are mesodermal, and histologically, resemble dental papilla. On the other hand, non-odontogenic fibromas are derived from the periosteum or perineurium and histologically, resemble desmoids though differentiation is difficult in most cases. As for treatment, Bernier (1955) (11), Thoma (6) and Cahn (1965) (12) have recommended the complete excision or enucleation of the tumor, or cauterization after enucleation (13).

Acknowledgment. The authors wish to express their deep gratitude to Prof. Katsuo Ogawa, Second Department of Pathology, Okayama University Medical School, for his valuable instruction in pathohistology.

REFERENCES

1. Ishikawa, G. and Akiyoshi, M.: *Oral Pathology* II, a revised ed., Nagasue Shoten, Kyoto, pp. 489-491, 536-539, 1982 (in Japanese).
2. Awasawa, Y.: *New Oral Pathology*. The Last Volume, 2nd ed., Kanahara Shuppan, Tokyo, pp. 94-95, 1979 (in Japanese).
3. Nakamura, H.: *The Newest Oral Surgery*. Ishiyaku Shuppan, Tokyo, p. 601, 1978 (in Japanese).
4. Suzuki, S.: Pathological studies of fibrous tumors originated inside the jaw bone. *Kokubyo*. **26**, 298-316, 1958 (in Japanese).
5. Moro, M.: Clinico-pathological studies on central fibrous tumor and fibrous dysplasia in the jaw bone. *Nihon Univ. Dent. J.* **41**, 389-432, 1967 (in Japanese).
6. Thoma, K.H. and Goldman, H.M.: *Oral Pathology*, 5th ed., C.V. Mosby Co., St. Louis, pp. 1256-1273, 1960.
7. Pindborg, J.J. and Clausen, F.: Classification of odontogenic tumors. *Acta Odontol. Scand.* **16**, 293-301, 1958.
8. Zimmerman, D.C. and Dahlin, D.C.: Myxomatous tumor of the jaws. *Oral Surg. Oral Med. Oral Pathol.* **11**, 1069-1080, 1958.
9. Hamner, E., Gamble, J.K. and Gallegos, G.J.: Odontogenic fibroma. *Oral Surg. Oral Med. Oral Pathol.* **21**, 113-119, 1966.
10. Fujioka, Y.: The various phases of central fibroma of the jaw bone. *J. Jpn. Stomat. Soc.* **9**, 323-333, 1960 (in Japanese).
11. Bernier, J.L.: *The Management of Oral Disease*. C.V. Mosby Co., St. Louis, pp. 548-638, 1955.
12. Cahn, L.R. and Tiecke, R.W.: *Odontogenic Tumors*. McGraw Hill Book Co., New York, pp. 213-225, 1965.
13. Kegel, R.F.C.: Central tumors of the lower jaw. *Radiology* **16**, 216-223, 1931.