

Acta Medica Okayama

Volume 61, Issue 3

2007

Article 7

JUNE 2007

Ileal substitution of a radiologically injured duplex female ureter via novel antireflux technique

Alexander Ivanov Hinev*

Stoyan Milanov Paunov†

Boyan Dobrev Balev‡

*Varna Medical University,

†Varna Medical University,

‡Varna Medical University,

Ileal substitution of a radiologically injured duplex female ureter via novel antireflux technique*

Alexander Ivanov Hinev, Stoyan Milanov Paunov, and Boyan Dobrev Balev

Abstract

A 34-year-old female patient underwent total hysterectomy and pelvic irradiation for uterine malignancy, which led to iatrogenic fibrotic injury of the distal ureter. Reconstructive surgery was performed, and the ureter was replaced by an isolated ileal segment. Ureteroileal anastomosis was created using the antireflux serous-lined extramural tunnel technique, while the distal end of the isolated ileal segment was widely anastomosed with the bladder. Within a 1-year follow-up, excellent results were achieved, with complete recovery of the patient's renal function and previous quality of life. This technique could be a viable option when large ureteral defects are encountered.

KEYWORDS: ureter, ileum, ureteral stricture, reconstruction

*Copyright (C) OKAYAMA UNIVERSITY MEDICAL SCHOOL PMID: 17593955 [PubMed - in process]

Case Report

Ileal Substitution of a Radiologically Injured Duplex Female Ureter via Novel Antireflux Technique

Alexander Ivanov Hinev^{a*}, Stoyan Milanov Paunov^a, and Boyan Dobrev Balev^b

^aDepartment of Surgery, Division of Urology, and ^bDepartment of Radiology,
"St. Marina" University Hospital, Varna Medical University,
Varna 9010, Bulgaria

A 34-year-old female patient underwent total hysterectomy and pelvic irradiation for uterine malignancy, which led to iatrogenic fibrotic injury of the distal ureter. Reconstructive surgery was performed, and the ureter was replaced by an isolated ileal segment. Ureteroileal anastomosis was created using the antireflux serous-lined extramural tunnel technique, while the distal end of the isolated ileal segment was widely anastomosed with the bladder. Within a 1-year follow-up, excellent results were achieved, with complete recovery of the patient's renal function and previous quality of life. This technique could be a viable option when large ureteral defects are encountered.

Key words: ureter, ileum, ureteral stricture, reconstruction

Radiotherapy is an established and effective method of adjuvant treatment of gynecological malignancies. However, irradiation of the female pelvis may cause obstructive urological complications due to the formation of stenosis of the distal ureter(s). The Lich-Gregoir technique, psoas-hitch technique, Boari flap, and transureteroureterostomy are the most popular surgical techniques currently used to manage damages to the distal ureter. When large defects are encountered, ureteral substitution by an isolated intestinal segment (ileum, colon, or appendix) may become the preferred option.

We present a case of iatrogenic injury to the distal ureter following total hysterectomy with subsequent pelvic irradiation for uterine malignancy in a 34-year-old female patient with a duplex kidney. The

damaged distant ureter was replaced by an isolated ileal segment. Ureteroileal anastomosis was created in an antireflux manner by implementation of the serous-lined extramural tunnel technique, originally described in orthotopic bladder substitutes.

Case Report

A 34-year-old white female (MVT, medical record 21812/10.11.2004) presented in our clinic with the following medical history. In November 2003, the patient underwent pelvic surgery for cancer of the uterine cervix. A radical hysterectomy using the Wertheim-Meigs technique was performed. The histological result (Nos. 1554-61) confirmed differentiated, at some sites moderately differentiated, squamous cell carcinoma infiltrating the whole depth of the uterine cervix, with tumor emboli in the blood vessels. At surgery, 12 lymph nodes were removed, 2 of which were found to be metastatic.

Received August 16, 2006; accepted December 18, 2006.

*Corresponding author. Phone: +359-878-266125; Fax: +359-52-302884
E-mail: alexander_hinev@yahoo.com (A. Hinev)

In January, and later in March 2004, the patient underwent 2 consecutive courses of external beam radiotherapy, the first one applied to the pelvis and to the upper half of the vagina (2Gy daily dose, 50Gy total dose, realized in 25 sessions), and the second one applied to the paraaortic lymphatic chain (2Gy daily dose, 40Gy total dose, realized in 20 sessions).

In June 2004, the patient first complained of dull pains at the right lumbar region, loss of appetite, nausea, and vomiting. In August 2004, she first consulted a urologist. Laboratory tests performed at that time revealed high levels of urea and creatinine in the serum. The US examination confirmed the presence of hydronephrosis of the right kidney, grade II-III. The CT examination, using contrast medium (c.m.) for image enhancement, revealed lack of excretion of the right kidney until the 12th hour following the c.m. administration. On August 27, 2004, right percutaneous nephrostomy was placed and the patient was directed to the Division of Urology for surgical treatment.

The physical examination at admission showed a satisfactory patient common condition. The respiratory and cardio-vascular systems were without any pathological changes. The patient's blood pressure was 115/70 mmHg, and her pulse frequency was 72 bpm. A scar from a previous laparotomy was clearly visible on the abdomen. A right percutaneous nephrostomy was also seen; the kidney excreted 500–800 ml urine per 24 h. The liver and spleen were without any pathological changes. Succussio renalis was positive to the right.

Laboratory results: Hb 137g/l; Hct 0.35; WBC 5.4 GI/l; urea 6.2 mmol/l; creatinine 103 μ mol/l; glucose 4.6 mmol/l; AST 18U/l; ALT 19U/l; alkaline phosphatase 90U/l; Na⁺ 144 mmol/l; K⁺ 4.2 mmol/l; Cl⁻ 105 mmol/l.

Urinalysis: protein (+); nitrite (+); Microscopy: 50–60 WBC/HPF, bacteria. Urine culture: *Pseudomonas aeruginosa* 10⁵.

Preoperative antegrade pyelography confirmed hydronephrotic transformation of the duplex kidney to the right caused by a marked stenosis of the distal ureter (Fig. 1).

The protocol concerning the management of the reported case was discussed and approved by the institutional human research review board of "St.

Marina" University Hospital within which the surgery was undertaken. All procedures were carried out with the adequate understanding and written consent of the subject.

The patient underwent surgical exploration on November 11, 2005 (operative protocol No 81). The damaged distant end of the right ureter was replaced by an isolated 25cm long ileal segment. The proximal end of the isolated ileal segment was folded and fixed close to its mesenteric border by a running sero-serosal 3-0 silk suture. The ureter was passed via a window in the mesoradix, and the intestine was opened along the suture by a diathermy knife to form 2 lateral flaps for the construction of the extramural serous-lined tunnel. This tunnel should be neither too tight, to prevent stenosis, nor too loose, to prevent reflux. For the same reason, it should have enough length, at least 2cm. Following this rule, the

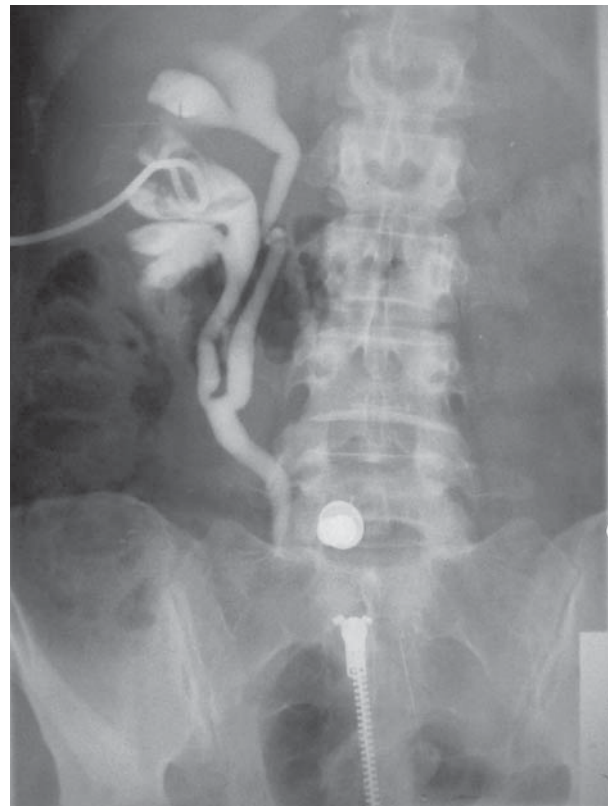

Fig. 1 Preoperative antegrade pyelography showing hydronephrotic transformation of a duplex kidney to the right caused by a marked stenosis of the distal ureter, which starts immediately below the ureteral bifurcation at the level of the pelvic entry (L5-S1).

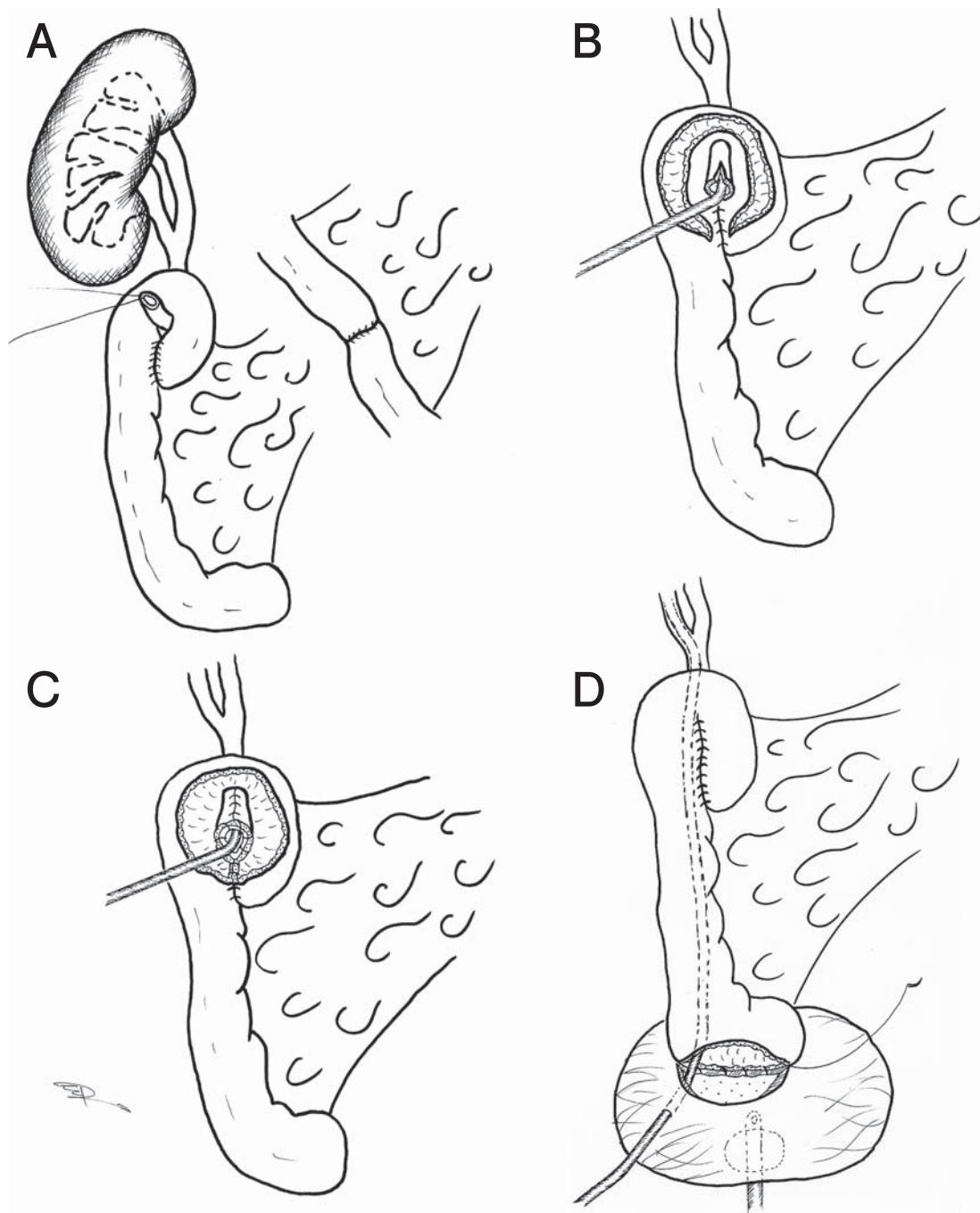


Fig. 2 Surgical technique: **A**, Isolation of a 25cm segment from the distal ileum. The proximal end of the intestinal segment is folded and fixed by a running sero-serosal suture and the ureter is passed via a window in the mesoradix; **B**, The intestine is opened along the suture to form two flaps for the construction of the extramural serous-lined tunnel; **C**, The 2 intestinal flaps are closed over the ureter, which remains outside of the reservoir (in a serous-lined, extramural position); **D**, Definite closure of the proximal end of the intestinal segment. The distal end of the ileal segment is anastomosed widely with the bladder. The ureteral tube is brought out via the anterior bladder wall.

2 flaps were tailored according to the caliber of the ureter; the breadth of each flap was adjusted to be equal to the outer diameter of the ureter. The mucosal edges of the 2 flaps were approximated over the ureter by a continuous 3-0 polyglactin suture. A mucosa-to-mucosa anastomosis between the stented spatulated end of the ureter and the intestinal mucosa at the distal end of the trough was then performed.

After definite closure of the proximal end of the intestinal segment, its distant end was anastomosed widely (in a reflux manner) with the bladder. The 7Fr plastic tube used for ureteral stenting was brought out via the anterior bladder wall. A 22Fr indwelling Foley catheter was inserted into the bladder.

The basic steps of the surgical technique applied are presented in Fig. 2 and Fig. 3.

The early postoperative period ran smoothly and uneventfully, without any major complications. The surgical wound healed primarily. The ureteral intubation was removed on the 7th day, and the nephrostomic tube was removed on the 8th day after surgery. Postoperative antegrade pyelography confirmed

the recovered passability of the right ureter (Fig. 4A), and retrograde cystography confirmed the unidirectional (antireflux) flow of urine (Fig. 4B). The urethral catheter was removed on the 10th day after surgery, and the patient was discharged from the hospital on November 23, 2005.

The patient was closely followed-up 1 year after surgery. At follow-up, the patient's laboratory results remained within normal ranges. An insignificant asymptomatic bacteriuria/*Ps. aeruginosa* 10^4 /persisted on the first month after surgery, but it was easily overcome by Amikacin.

Postoperative IVP performed on the 3rd month confirmed a complete recovery of renal function and unobstructed upper urinary tracts (Fig. 4C), with this result persistent 12 months after surgery.

Discussion

Small intestine was first used for ureteral substitution by Schoemaker in 1906, but this procedure was not widely popularized and spread within the urologic community until Goodwin's report in the late

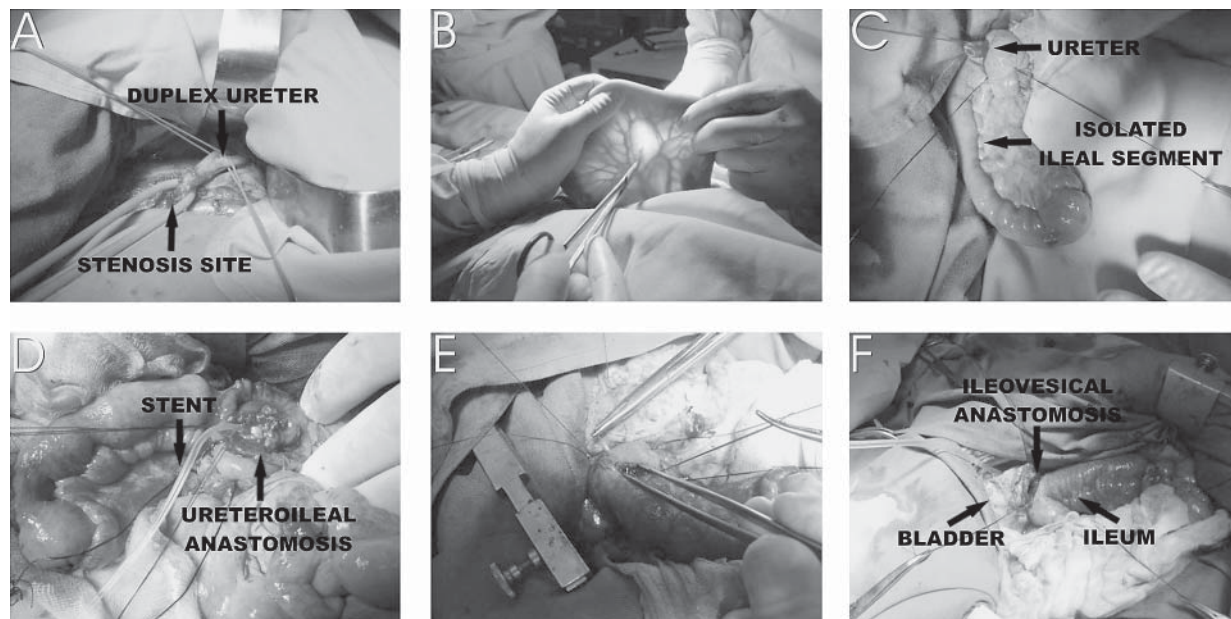


Fig. 3 Main steps of the surgical procedure: **A**, The duplex right ureter is mobilized to the stenosis site; **B**, The distal ileum is checked to determine the site of the intestinal and mesoradix incision; **C**, The proximal end of the isolated intestinal segment is folded and fixed by a running sero-serosal suture. The ureter is passed via a window in the mesoradix of the intestine; **D**, The intestine is opened and the ureter is reimplanted via a serous-lined extramural tunnel; **E**, Closure of the intestinal wall by a 3-0 polyglactin running suture; **F**, The isolated ileal segment is widely anastomosed with the bladder. The ureteral tube is brought out via the anterior bladder wall.

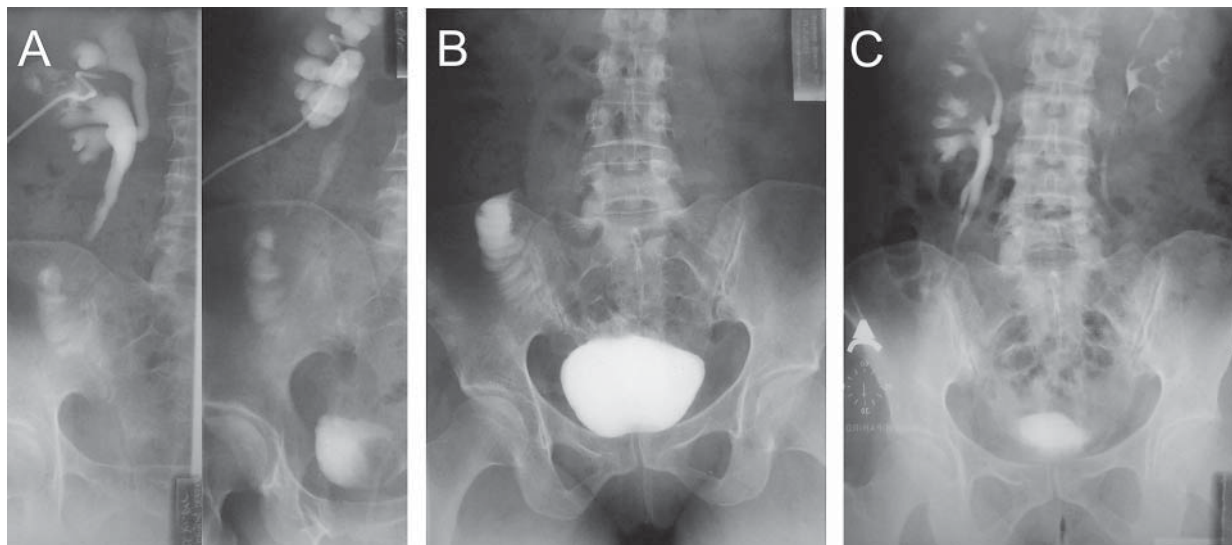


Fig. 4 A, Postoperative antegrade pyelography, confirming the recovered passability of the right ureter; B, Postoperative retrograde cystography, confirming the unidirectional (antireflux) flow of urine; C, Postoperative IVP, confirming a complete recovery of the renal function and unobstructed upper urinary tracts.

1950s [1]. The increasing use of intestine in reconstructive urology currently led to a renaissance in the use of intestinal segments for ureteral substitution. However, the optimal method of intestinal ureteral substitution remains to be defined [2–5].

Construction of the ureteroileal anastomosis is crucial for the success of the surgical procedure. Accumulated evidence from experimental and clinical studies shows that both urinary reflux and obstruction at the anastomotic site can be detrimental to the kidney. Hence, to permanently preserve renal function, a well-performed ureteroileal anastomosis should be unidirectional (antireflux) and nonobstructive.

The serous-lined extramural tunnel technique, as an antireflux procedure, was first proposed by Abol-Enein and Ghoneim in 1994 [6]. Initially used in orthotopic neobladders, the scope of this technique's clinical application soon expanded and was further applied in recto-sigmoid pouches [7], continent ileal reservoirs [8], ileum conduits [9], and most recently, in bladder augmentation [10].

We applied the serous-lined extramural tunnel technique in ureteral substitution using an isolated ileal segment. Within a 1-year follow-up, excellent results were obtained, with a complete recovery of

renal function and the patient's previous quality of life. These results demonstrate that the proposed surgical technique is an efficient method of providing an unobstructed unidirectional flow of urine.

In conclusion, ureteral substitution by an isolated ileal segment via antireflux ureteroileal and reflux ileovesical anastomosis could be a viable option when large defects of the distal ureter are encountered.

References

1. Goodwin WE, Winter CC and Turner RD: Replacement of the ureter by small intestine: clinical application and results of the ileal ureter. *J Urol* (1959) 81: 406–418.
2. Kato H, Abol-Enein H, Igawa Y, Nishizawa O and Ghoneim MA: A case of ileal ureter with proximal antireflux system. *Int J Urol* (1999) 6: 320–323.
3. Gill IS, Savage SJ, Senagore AJ and Sung GT: Laparoscopic ileal ureter. *J Urol* (2000) 163: 1199–1202.
4. Ali-el-Dein B and Ghoneim MA: Bridging long ureteral defects using the Yang-Monti principle. *J Urol* (2003) 169: 1074–1077.
5. Chung BI, Hamawy KJ, Zinman LN and Libertino JA: The use of bowel for ureteral replacement for complex ureteral reconstruction: long-term results. *J Urol* (2006) 175: 179–184.
6. Abol-Enein H and Ghoneim MA: A novel uretero-ileal reimplantation technique: the serous lined extramural tunnel. A preliminary report. *J Urol* (1994) 151: 1193–1197.
7. el Mekresh MM, Hafez AT, Abol-Enein H and Ghoneim MA: Double folded rectosigmoid bladder with a new ureterocolic antireflux technique. *J Urol* (1997) 157: 2085–2089.
8. Abol-Enein H and Ghoneim MA: Serous lined extramural ileal

- valve: a new continent urinary outlet. *J Urol* (1999) 161: 786-791.
9. Turkolmez K, Baltaci S, Beduk Y, Gogus C and Gogus O: A nonrefluxing, serous lined extramural tunnel for ureteroileal anastomosis in ileal conduit urinary diversion: first clinical experience in 10 patients. *J Urol* (2001) 166: 898-901.
 10. Soygur T, Arıkan N, Zımrutbas AE and Gulpınar O: Serosal lined extramural tunnel (Ghoneim) principle in the creation of a catheterizable channel in bladder augmentation. *J Urol* (2005) 174: 696-699.