

# *Acta Medica Okayama*

---

*Volume 33, Issue 5*

1979

*Article 6*

OCTOBER 1979

---

## Vectorcardiogram of complete right bundle branch block with left axis deviation by the Frank and Kimura systems.

Masahiro Nakagawa\*

Daiji Saito<sup>†</sup>

Minoru Ueda<sup>‡</sup>

Hidenori Yoshida\*\*

Ritsuo Mae<sup>††</sup>

Kazuo Ioriya<sup>‡‡</sup>

Shoichi Haraoka<sup>§</sup>

\*Okayama University,

<sup>†</sup>Okayama University,

<sup>‡</sup>Okayama University,

\*\*Okayama University,

<sup>††</sup>Okayama University,

<sup>‡‡</sup>Okayama University,

<sup>§</sup>Okayama University,

# Vectorcardiogram of complete right bundle branch block with left axis deviation by the Frank and Kimura systems.\*

Masahiro Nakagawa, Daiji Saito, Minoru Ueda, Hidenori Yoshida, Ritsuo Mae, Kazuo Ioriya, and Shoichi Haraoka

## Abstract

Vectorcardiogram (VCG) recorded by both the Frank and Kimura systems were examined in 45 patients with complete right bundle branch block (RBBB) and left axis deviation (LAD) to investigate the relationship seen on electrocardiogram (ECG) between RBBB with LAD and bilateral bundle. The sample included: 13 cases of type SI, SII, SIII, SaVF; 21 cases of type SI, SII, SIII, aVF; and 11 cases of types SI, SII, SIII. VCG recorded by the Frank system were classified into seven types according to the QRS loop pattern on the frontal plane and into three types according to the horizontal plane. The main findings were: (a) In the Frank system the QRS loop in the frontal plane showed a variety of patterns in RBBB with LAD. (b) On VCG of complete RBBB judged complicated by a left anterior hemiblock by the Frank system, the main portion of the QRS loop extended to the left superior or merely to the left in the frontal plane. The direction of rotation and position on the horizontal plane were not consistent. (c) The results of this study suggest the usefulness of the Kimura system as an auxiliary diagnostic technique.

**KEYWORDS:** right bundle branch block, left axis deviation, bilateral bundle branch block, vectorcardiography, Frank system, Kimura system

---

\*PMID: 160186 [PubMed - indexed for MEDLINE]

Acta Med. Okayama **33**, (5), 395—404 (1979)

**VECTORCARDIOGRAM OF COMPLETE RIGHT BUNDLE  
BRANCH BLOCK WITH LEFT AXIS DEVIATION  
BY THE FRANK AND KIMURA SYSTEMS**

Masahiro NAKAGAWA, Daiji SAITO, Minoru UEDA,  
Hidenori YOSHIDA, Ritsuo MAE, Kazuo IORIYA  
and Shoichi HARAOKA\*

*First Department of Internal Medicine, Okayama University Medical School,  
Okayama 700, Japan and \*Central Laboratory, Okayama University  
Hospital, Okayama 700, Japan*

*Received May 30, 1979*

*Abstract.* Vectorcardiogram (VCG) recorded by both the Frank and Kimura systems were examined in 45 patients with complete right bundle branch block (RBBB) and left axis deviation (LAD) to investigate the relationship seen on electrocardiogram (ECG) between RBBB with LAD and bilateral bundle. The sample included: 13 cases of type SI, SII, SIII, SaVF; 21 cases of type SI, SII, SIII, aVF; and 11 cases of types SI, SII, SIII. VCG recorded by the Frank system were classified into seven types according to the QRS loop pattern on the frontal plane and into three types according to the horizontal plane. The main findings were: (a) In the Frank system the QRS loop in the frontal plane showed a variety of patterns in RBBB with LAD. (b) On VCG of complete RBBB judged complicated by a left anterior hemiblock by the Frank system, the main portion of the QRS loop extended to the left superior or merely to the left in the frontal plane. The direction of rotation and position on the horizontal plane were not consistent. (c) The results of this study suggest the usefulness of the Kimura system as an auxiliary diagnostic technique.

*Key words:* right bundle branch block, left axis deviation, bilateral bundle branch block, vectorcardiography, Frank system, Kimura system

In recent years, a relationship between right bundle branch block (RBBB) with left axis deviation (LAD) and intraventricular trifascicular block has become evident from ECG findings with blockage of both the right bundle branch and the left anterior branch (bilateral bundle branch block) (1-3). However, the variety of QRS loops obtained from vectorcardiograms (VCG) of RBBB and LAD makes diagnosis difficult. In this study here the relationship between RBBB with LAD and bilateral bundle branch block is examined in VCG patterns of LAD by the Frank and Kimura systems (4).

## MATERIALS AND METHODS

The subjects of this study were patients of the Okayama University Hospital, Sakakibara Juzen Hospital, and Okayama Adult Disease Center. Each patient was diagnosed with a standard 12 lead ECG as having a complete RBBB. The ECG indicated an S wave greater than the R wave in the aVF lead. In some patients, the S waves of QRS complexes in Leads I, II and III were all deep. Patients with myocardial infarction were excluded.

Table 1 shows the age and sex distribution of the subjects. The group consisted of 34 males and 11 females, with an average age of 61 years for males and 58 years for females.

TABLE 1. AGE AND SEX DISTRIBUTION OF PATIENTS

Age (yr.)	0-9	10-19	20-29	30-39	40-49	50-59	60-69	70-79	80-89	Total
Sex										
Male	1				5	9	10	8	1	34
Female			1		2	1	4	3		11
Total	1		1		7	10	14	11	1	45

The equipment used in this investigation was vectorcardiograph Model VA-3C5 and VA-3D (Fukuda Electronics Co.). The VCG were taken with the patient supine. The horizontal electrodes were placed on the fifth intercostal space, and recordings were taken during shallow expiration.

Frank method VCGs (5) were classified according to the patterns of the frontal and horizontal QRS loops. These patterns were also compared with patterns of QRS loops by the Kimura system (6-9).

## RESULTS

*QRS Complex and QRS Loop.*

*QRS loops recorded by the Frank system.* The frontal QRS loops recorded by the Frank system were classified into seven types according to the direction of rotation, the size of left and right components, and the position of the main portion of the QRS loop (Fig. 1). Type F-1 showed clockwise rotation of the QRS loop, and the loop was prolonged from left inferior to right superior. Type F-2 and type F-3 showed counterclockwise rotation of QRS loops, and the loops were prolonged from left inferior to right superior. In type F-2, the right component was larger than the left, whereas in type F-3 the reverse was the case. Type F-4 was a flat loop of which the main portion extends to the left. Type F-5 was a loop that protruded to the left and right superior direction. Type F-6 was a loop that protruded to the left superior direction and type F-7 was a loop that was largely deviated in the left superior direction.

The horizontal QRS loops recorded by the Frank system were classified into three basic patterns according to Tokunaga (10), as shown in Fig. 2. Type

PATTERNS OF FRONTAL QRS LOOP ( FRANK SYSTEM )




Fig. 1. Classification of frontal QRS loop patterns recorded by the Frank system. The classification comprises of seven patterns according to the direction of rotation, the size of the left and right components, and the position of the main portion of the QRS loop.

PATTERNS OF HORIZONTAL QRS LOOP ( FRANK SYSTEM )

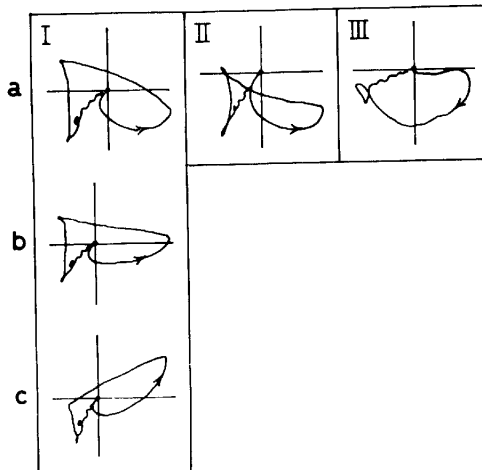


Fig. 2. Classification of horizontal QRS loop patterns recorded by the Frank system. They are classified into three basic patterns according to Tokunaga. —Type I was further divided into three subtypes, a, b and c, according to the position of the main portion of the QRS loop.



tween the depth of S waves in the ECG limb lead and the VCG frontal QRS loop patterns recorded by the Frank system. Cases with pattern  $s_I, s_{II}, S_{III}, SaV_F$  on ECG belonged to types F-2, F-3, F-4, F-5 and F-6; those with pattern  $s_I, S_{II}, S_{III}, SaV_F$  belonged to types F-1, F-4, F-5, F-6 and F-7; those with pattern  $S_I, S_{II}, S_{III}, SaV_F$  belonged to types F-1, F-2, F-3 and F-5. No particular relationship was apparent among the three groups. Fig. 4 shows the relationship of the electric axis of ECG, the depth of S waves of QRS complexes, and the frontal QRS loop patterns on the Frank system. There was no difference in the electric axis for cases with pattern  $s_I, s_{II}, S_{III}$ , and  $s_I, S_{II}, S_{III}$ , nor was there any relationship between the electric axis and the QRS loop pattern.

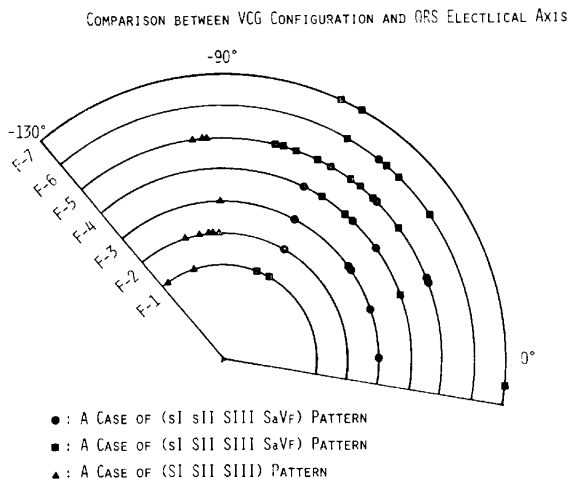


Fig. 4. Relationships between the electric axis of ECG, the depth of S waves in limb leads, and the frontal QRS loop patterns on VCG. Abbreviation: See Fig. 1.

*VCG recorded by the Kimura system.* In a previous paper (4), VCG recorded by the Frank and Kimura systems in patients with marked LAD ( $-30^\circ$  to  $-90^\circ$ ) and with QRS intervals of less than 0.12 seconds were compared. Counterclockwise rotation of the frontal QRS loop that was prolonged from the right inferior to left superior and had a ratio of 3:2 or more between the maximum upper component and the maximum lower component in the Kimura system was designated as  $ccw(L)a$ . It was considered as a pattern of left anterior hemiblock (4). The study here attempts to determine the corresponding VCG pattern in the Frank system (Table 3).

Of 37 patients, 13 showed a  $ccw(L)a$  pattern in the main portion of the QRS loop recorded by the Kimura system. In cases of VCG recorded by the Frank system, this pattern was not observed in types F-1, F-2, and F-3 of frontal QRS loops but was present in part of type F-4, F-5, and F-6 and in all cases

TABLE 3. CLASSIFICATION OF QRS-LOOPS RECORDED BY THE FRANK SYSTEM

Horizontal plane	Frontal plane							Total
	F-1	F-2	F-3	F-4	F-5	F-6	F-7	
I a	1	1	1	2( 2 <sup>b</sup> )	6(1 <sup>a</sup> 4 <sup>b</sup> )	1( 1 <sup>b</sup> )	1(1 <sup>a</sup> )	13(2 <sup>a</sup> 7 <sup>b</sup> )
b			3	1( 1 <sup>b</sup> )	2(2 <sup>a</sup> )			6(2 <sup>a</sup> 1 <sup>b</sup> )
c					3(3 <sup>a</sup> )	1(1 <sup>a</sup> )		4(4 <sup>a</sup> 0 <sup>b</sup> )
II		1		1(1 <sup>a</sup> )	1		1(1 <sup>a</sup> )	4(2 <sup>a</sup> 0 <sup>b</sup> )
III	2	2	2	1(1 <sup>a</sup> )	1(1 <sup>a</sup> )	1( 1 <sup>b</sup> )	1(1 <sup>a</sup> )	10(3 <sup>a</sup> 1 <sup>b</sup> )
Total	3(0 <sup>a</sup> 0 <sup>b</sup> )	4(0 <sup>a</sup> 0 <sup>b</sup> )	6(0 <sup>a</sup> 0 <sup>b</sup> )	5(2 <sup>a</sup> 3 <sup>b</sup> )	13(7 <sup>a</sup> 4 <sup>b</sup> )	3(1 <sup>a</sup> 2 <sup>b</sup> )	3(3 <sup>a</sup> 0 <sup>b</sup> )	37(13 <sup>a</sup> 9 <sup>b</sup> )

Number in parentheses indicates the number of CCW(L)a and CCW(R')a by the Kimura system.

Abbreviation: The same as Fig. 1. and Fig. 2.

a CCW(L)a, an elongated loop orienting right-inferiorly to left-superiorly with counterclockwise rotation.

b CCW(R')a, a loop widely orienting right-inferiorly to left-superiorly with counterclockwise rotation and the terminal vector deviates to the right.

of type F-7. However, no consistent tendency was seen in horizontal QRS loop patterns. The ccw(R')a pattern of frontal QRS loop obtained with the Kimura system was characterized by a relatively large left superior component similar to that in the ccw(L)a pattern. It was indicative of left anterior hemiblock. There was a counterclockwise rotation of the frontal QRS loop which passed in a wide loop from right inferior to left superior with the terminal vector deviating to the right side. A ratio of at least 3 : 2 was present between the maximum upper component and the maximum lower component. This ccw(R')a pattern was not observed in patients with type F-1, F-2, or F-3 frontal QRS loops (Frank system) but was noted in those with types F-4, F-5 and F-6.

### Case Studies

*Case 1.* A 62-year-old man, had complete RBBB accompanied by intermittent LAD. A type F-5 frontal QRS loop pattern with slight upper deviation was recorded by the Frank system at the time of LAD with a right bundle branch block (Fig. 5).

*Case 2.* A 78-year-old man treated for hypertension and ischemic heart disease, had a type F-5 frontal QRS loop pattern with the Frank system. The frontal QRS loop with the Kimura system belonged to the ccw(L)a pattern, suggesting complication by a left anterior hemiblock (Fig. 6).



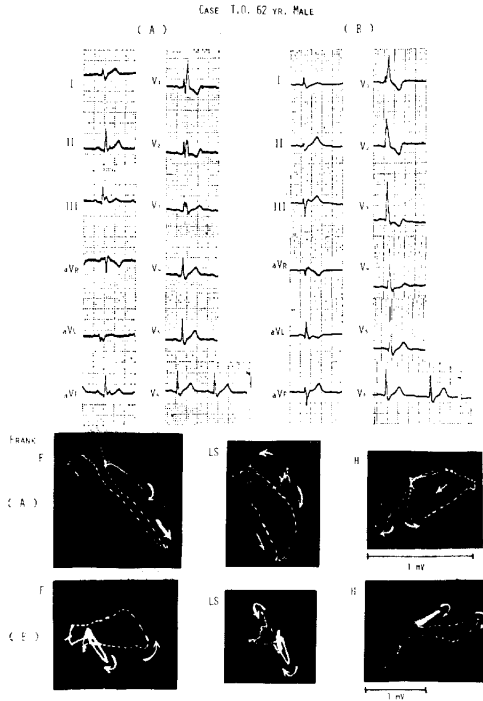


Fig. 5. Case 1, 62-year-old man. (A) is complete RBBB only (B) indicates complete RBBB accompanied by intermittent LAD of type F-5 with slight upper deviation of the QRS loop.

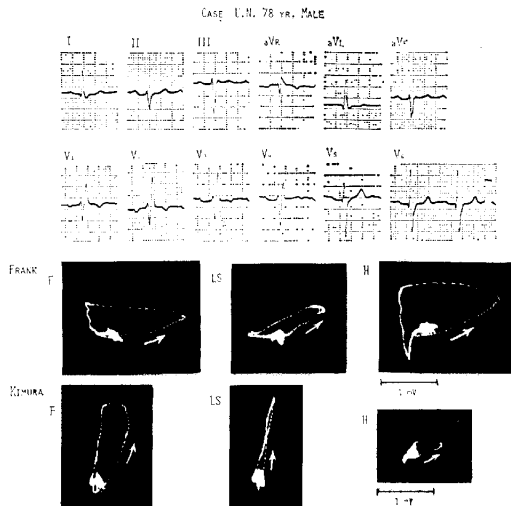


Fig. 6. Case 2, 78-year-old man. Note that the frontal QRS loop of the Kimura system shows a ccw(L) a type QRS loop markedly prolonged in the left superior direction.

DISCUSSION

ECG of complete RBBB shows right axis deviation due to a delay in right ventricular excitation caused by the block itself. However, on rare occasions this may also be due to LAD. This phenomenon has attracted attention as an unusual type of Wilson block (11-12). The pathological findings of the variation (13-15) are thought to arise from disturbances of the conduction system affecting both the right and left bundles. These disturbances may develop into complete atrioventricular heart block. At present, the block of the right bundle branch and the left anterior branch are interpreted using the trifascicular system concept (1-3).

Recently, Kulbertus (16) using epidemiologic data questioned the validity of previous investigations pointing out that RBBB with LAD on ECG did not develop into complete atrioventricular heart block. Therefore, it is essential to make a differential diagnosis of bilateral bundle branch block in patients with both RBBB and LAD. The  $q_i$ ,  $S_{III}$  type ECG with right bundle branch block and left axis deviation from  $-60^\circ$  to  $-120^\circ$  is considered to be RBBB accompanied by left anterior hemiblock (3). All subjects in the present study had the  $q_i$ ,  $S_{III}$  type accompanied by a variety of VCG patterns on the Frank system. As diagnosis by ECG criteria alone is limited, it becomes necessary to examine the QRS loop patterns on VCG.

The change in VCG due to left anterior hemiblock was mainly characterized by left upper deviation in the mid-portion of the QRS loop and was insignificant even when conduction time was prolonged. This suggests that the change due to left anterior hemiblock was in the first two-thirds of the total excitation period and was mainly represented by changes in the main portion of the QRS loop, even when a complete RBBB was accompanied by left anterior hemiblock. That is why in the present study frontal QRS loop patterns recorded by the Frank system were mainly classified by observations of the main portion.

Tokunaga (10) analyzed QRS loops (Frank system) obtained from cases of isolated complete RBBB. Tokunaga's type A belongs to the above mentioned type F-1, F-2, or F-3. The fact that types F-1, F-2, and F-3 shows unmistakable LAD on ECG is hard to explain by left anterior hemiblock, since the VCG indicated that LAD is part of the change in the terminal portion of the QRS loop.

Saltzman *et al.* (17) classified RBBB with LAD by analyzing VCG findings. They classified QRS loops into types A and B. Type A was characterized by counterclockwise rotation from an anterior to posterior position in the horizontal plane. It was mainly located in the superior position and had a flat, somewhat round counterclockwise rotation in the frontal plane. Type B was mainly in

the anterior position with clockwise rotation in the horizontal plane. It had counterclockwise rotation of the frontal plane and had a predominant superior extension. According to Saltzman *et al.*, type B clinically suggests a broader myocardial lesion and an unfavorable prognosis. Mashima *et al.* (18) described four cases of complete atrio-ventricular block or of complaints of symptoms consistent with such a diagnosis, but who were diagnosed as atypical bundle branch block on ECG. The sinus rhythms in these VCG closely resembled those of type B.

Comparisons of Saltzman *et al.* classification with our proposed classification show that their type A is equivalent to type I in the horizontal plane and type F-5 in the frontal plane, whereas type B coincides with type III in the horizontal plane and type F-7 in the frontal plane.

Saltzman *et al.* described an intermediate type between type A and B, but types F-1, F-2, F-3, and F-4 do not fit their classification scheme, even when such an intermediate type is taken into account. In their classification, importance is attached to the pattern and rotational direction of QRS loops in the horizontal plane. In the present study, however, no relationship was observed between QRS loops in the frontal and horizontal planes.

As previously reported (4), VCG recorded by the Kimura system are useful in the differential diagnosis of LAD. The recordings also appear to be of value in diagnosis of types F-4, F-5, and F-6 which do not show marked left upward deviation of the QRS loop and are ambiguously complicated by left anterior hemiblock with the Frank system.

#### REFERENCES

1. Rosenbaum, M. B., Elizari, M. V., Lazzari, J. O., Nau, G. J., Levi, R. J. and Halpern, M. S.: Intraventricular trifascicular block. The syndrome of right bundle branch block with intermittent left anterior and posterior hemiblock. *Am. Heart J.* **78**, 306-317, 1969.
2. Rosenbaum, M. B., Elizari, M. V., Lazzari, J. O., Nau, G. J., Levi, R. J. and Halpern, M. S.: Intraventricular trifascicular blocks. Review of the literature and classification. *Am. Heart J.* **78**, 450-459, 1969.
3. Rosenbaum, M. B., Elizari, M. V. and Lazzari, J. O.: New concepts of intraventricular conduction based on human anatomical, physiological, and clinical studies, In *The Hemiblocks*, Tampa Tracings Oldsmar, Florida, 1970.
4. M. Nakagawa: Studies on vectorcardiography. II. Vectorcardiographic studies on left axis deviation by comparison of the Frank lead system with Kimura lead system. *Okiyama Igakkai Zasshi* **89**, 1267-1283, 1977 (in Japanese).
5. Frank, E.: An accurate, clinically practical system for spatial vectorcardiography. *Circulation* **13**, 737-749, 1956.
6. N. Kimura: Studies of cardiac function by vectorcardiogram. *Jpn. Circ. J.* **5**, 177-178, 1939 (in Japanese).
7. N. Kimura: Vectorcardiogram. *Jpn. Circ. J.* **13**, 312-317, 1949.
8. N. Kimura: Vectorcardiogram. *Jpn. Circ. J.* **14**, 28-33, 1950 (in Japanese).
9. M. Nakagawa: Studies on vectorcardiography. I. Basic studies on vectorcardiography

- by the Kimura system with special reference to the Frnak system. *Okayama Igakkai Zasshi* **88**, 363-371, 1976 (in Japanese).
10. Tokunaga, T.: Electrocardiogram and vectorcardiogram in isolated complete right bundle branch block. I. Clinical studies. *Jpn. Circ. J.* **37**, 941-956, 1973.
  11. Wilson, F. N., Johnston, F. D., Hill, I. G. W. and Barker, P. S.: The significance of electrocardiograms characterized by an abnormally long QRS interval and by broad S-deflections in lead I. *Am. Heart J.* **9**, 459-471, 1934.
  12. Wilson, F. N., Johnston, F. D. and Barker, P. S.: Electrocardiograms of an unusual type in right bundle branch block. *Am. Heart J.* **9**, 472-479, 1934.
  13. Unger, P. N., Lesser, M. E., Kugel, V. H. and Lev, M.: The concept of "masquerading" bundle branch block. An electrocardiographic-pathologic correlation. *Circulation* **17**, 397-409, 1958.
  14. Lenegre, J.: Contribution a l'Etude des Blocs de Branche. J.-B. Bailliere et fils, Paris, 1958.
  15. Sugiura, M., Okada, R., Hiraoka, K. and Ohkawa, S.: Histological studies on the conduction system in 14 cases of right bundle branch block associated with left axis deviation. *Jpn. Heart. J.* **10**, 121-132, 1969.
  16. Kulbertus, H. E.: Reevaluation of the prognosis of patients with LAD-RBBB. *Am. Heart J.* **92**, 665-667, 1976.
  17. Saltzman, P., Linn, H. and Pick, A.: Right bundle branch block with left axis deviation. *Br. Heart J.* **28**, 703-708, 1966.
  18. Mashima, S., Harumi, K., Sato, C., Yanai, Y. and Ueda, H.: Atypical bundle branch block—Report of four cases with vectorcardiographic observation. *Jpn. Heart J.* **4**, 303-312, 1963.