

# *Acta Medica Okayama*

---

*Volume 21, Issue 5*

1967

*Article 3*

OCTOBER 1967

---

## Treatment of hepatic cancer patients with a gluconeogenic diet: report of a case with hepatic metastases of malignant melanoma

Kazuhisa Taketa\*

Eiichi Miyata<sup>†</sup>

Kiyowo Kosaka<sup>‡</sup>

\*Okayama University,

<sup>†</sup>Okayama University,

<sup>‡</sup>Okayama University,

# Treatment of hepatic cancer patients with a gluconeogenic diet: report of a case with hepatic metastases of malignant melanoma\*

Kazuhisa Taketa, Eiichi Miyata, and Kiyowo Kosaka

## Abstract

A case of malignant melanoma with metastases mainly to the liver and the right ilium was treated with a gluconeogenic diet. The carbohydrate content of the diet was finally reduced to 5~10 g per day and the remaining calories were derived from protein and fat. Increased blood citrate and NEFA concentrations, increased ketone body formation and the maintenance of a reasonable level of blood sugar confirmed the attainment of a gluconeogenic metabolic state. Definite improvements in size of a hepatic tumor, serum alkaline phosphatase activity and the general condition were observed transiently during the dietary therapy. Growth of the tumor resumed despite the continued gluconeogenic therapy, and the patient died of cardiac failure. Concentrations of gluconeogenic enzymes, fructose-1, 6-diphosphatase, glutamic oxaloacetic transaminase and glutamic pyruvic transaminase, were all found to be very low in the tumor tissue as expected.

Acta Med. Okayama 21, 213—226 (1967)

**TREATMENT OF HEPATIC CANCER PATIENTS WITH  
A GLUCONEOGENIC DIET: REPORT OF A CASE  
WITH HEPATIC METASTASES OF  
MALIGNANT MELANOMA**

Kazuhisa TAKETA, Eiichi MIYATA\* and Kiyowo KOSAKA

*The First Department of Internal Medicine  
Okayama University Medical School  
Okayama, Japan  
Director: Prof. K. Kosaka*

*Received for publication, August 23, 1967*

This study is an extension of a dietary therapy of a rat hepatoma<sup>1</sup> to human hepatomas and has been carried out in cooperation with Dr. POGELL and his collaborators\*\*. The principle of the therapy is to place the patient on a gluconeogenic diet and is based on their observation that a selective inhibition of the growth in liver of the Novikoff hepatoma has been observed when rats are either starved or placed on a gluconeogenic diet<sup>1</sup>. A minimum justification to extend the experimental studies on animals directly to clinical materials is that the inoperable hepatoma is still a fatal disease even with current chemotherapy and also the possibility of placing a man on a gluconeogenic diet has been shown by LIEB<sup>2</sup>.

The present report describes the first case of hepatic tumor treated with a gluconeogenic diet. Although the patient was treated as a primary hepatoma, the postmortem examination revealed hepatic metastases of malignant melanoma. In this study transient but definite subjective and objective improvements have been obtained through the dietary therapy and the results of metabolic studies on this case afford necessary information for future studies of the dietary therapy of primary hepatoma cases.

MATERIALS AND METHODS

Practical techniques of placing a hepatoma patient on a gluconeogenic diet were essentially those suggested by GEORGE MANN<sup>3</sup> and those appeared in the report by LIEB<sup>2</sup>. The carbohydrate content of the diet was gradually reduced and the remaining calories were derived from protein and fat. No synthetic diet was used in this study. The actual amounts of diet taken were checked for every meal and the daily intakes of carbohydrate, protein, fat and total calory

---

\* Attending physician.

\*\* Department of Biochemistry, Albany Medical College, Albany, New York.

were calculated by means of a food composition table<sup>4</sup>.

The effect of changing the dietary composition on general metabolic state was followed by measurement of the metabolite levels in the blood and/or urine. These included blood sugar<sup>5</sup>, urinary urea nitrogen and total ketone bodies<sup>6</sup>, serum NEFA\*<sup>7</sup>, citrate<sup>8</sup>, lactate<sup>9</sup>, pyruvate<sup>10</sup> and  $\alpha$ -ketoglutarate<sup>11</sup>. U-Ni-Graph from Warner-Chilcott Laboratories was used for determination of urea nitrogen. Other chemical tests were done by routine clinical laboratory methods. The curative effect of the dietary regimen was checked by measurement of liver size including tumor by palpation, the mid-abdominal circumference and serum enzyme levels including alkaline phosphatase<sup>12</sup>, glutamic oxaloacetic transaminase<sup>13</sup> and glutamic pyruvic transaminase<sup>13</sup>.

Enzymatic analyses of hepatic tumors were done on the autopsy specimens obtained five hours after the death. To minimize the postmortem change in liver or tumor enzymes, the liver was cooled by placing ice bags over the upper abdomen immediately after death. Necropsied tissues were homogenized in 9 volumes of ice-cold, alkaline, isotonic potassium chloride solution<sup>14</sup> per g of tissue and centrifuged for 60 minutes at 30,000  $xg$  at 0°C. The supernatant was used as enzyme sources. FDPase\* and G6PDH\* activities were determined spectrophotometrically. FDPase assay was performed according to the method described by TAKETA and POGELL<sup>15</sup>. The assay system for G6PDH contained 50 mM glycylglycine buffer (pH 7.5), 2.5 mM G6P\*, 0.15 mM TPN<sup>+</sup>, 20 mM MgCl<sub>2</sub> and the supernatant. The system minus G6P served as a blank. The spectrophotometric assays were conducted at 37°C with a Hitachi Model 139 spectrophotometer. Glutamic oxaloacetic and glutamic pyruvic transaminase activities of the supernatant were determined colorimetrically<sup>13</sup>.

Fructose 1, 6-diphosphate, glucose 6-phosphate and TPN<sup>+</sup> were obtained as the sodium salts from Sigma Chemical Company. Purified preparations of glucose-6-phosphate dehydrogenase, phosphohexoisomerase, lactic dehydrogenase and glutamic dehydrogenase were obtained from C. F. Boehringer & Soehne GmbH.

## OBSERVATIONS

### Clinical History

K. KAWAZOE, a 34 year old married sailor, was noted by a doctor to have hepatic enlargement in July, 1966, when he had a high temperature of four days' duration. He gradually lost weight in spite of his good appetite. He was admitted to Okayama Rosai Hospital in November, 1966 for investigation of

\* The abbreviations used are: NEFA, non-esterified fatty acids; FDPase, fructose-1,6-diphosphatase; G6PDH, glucose-6-phosphate dehydrogenase; and G6P, glucose 6-phosphate.

low back pain, about which he had complained occasionally since he had blows on both thighs in 1965. After admission he had an occasional fever and right upper abdominal pains and was noted to have marked enlargement of the left hepatic lobe. The presence of hepatic tumor was suspected by liver scanning performed on February 1, 1967 (Fig. 1). A diagnosis of primary hepatoma\* was made by laparotomy and liver biopsy performed on February 3, 1967.




Fig. 1 Filling defect on the liver scintillogram

The patient was transferred to Okayama University Hospital on February 28, 1967 for treatment of hepatoma with a gluconeogenic diet. At the time of admission, he was emaciated and in apparent discomfort. He had a slight fever in the afternoon and his appetite was slightly reduced. He complained of excessive perspiration at all times, general weakness and a continuous pain over the right ilium.

His past medical history revealed an infection of the right eyeball in 1963 and loss of vision (right eye) since then. He had no particular dietary habits.

#### Physical Findings

Physical examination revealed blood pressure, 105/60 mm Hg; pulse, 86 and regular; temperature, 36.5°C; weight 42.5 Kg; and height 161 cm. The right eye had a scar formation and the pupil did not react to light and accom-

\* The final diagnosis of hepatic metastases of malignant melanoma was established by postmortem examination.

modation. Conjunctivas were slightly anemic and scleras not icteric. The heart was slightly enlarged to the left. The lung-liver border was in the 5th intercostal space, and the excursion of the lung was slightly depressed. A slight epigastric distention was noted. The liver was enlarged, firm and tender with palpable nodules (Fig. 2). Swelling and tenderness over the right iliac crest were noted (Fig. 2). The remainder of the physical findings were within normal limits.

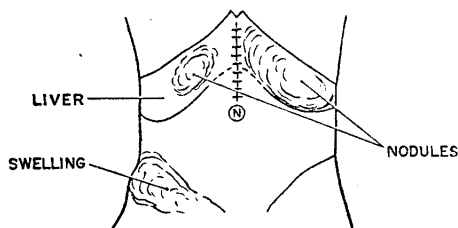


Fig. 2 Hepatic tumors and swelling of the right iliac crest at the time of admission to Okayama University Hospital

#### Laboratory Findings

The hemoglobin concentration was 9.6 g per 100 ml; hematocrit value, 29%; erythrocytes, 3,390,000/mm<sup>3</sup>, with a reticulocyte count of 1.4%; leucocytes, 7,900/mm<sup>3</sup>, with 79 polymorphonuclear cells, 3 stab cells, 12 lymphocytes, and 6 monocytes per 100 cells; and platelets, 542,000/mm<sup>3</sup>. There was no hemorrhagic tendency. Sedimentation rate was 112 mm in one hour. The results of urinalysis, stool examination, chest roentgenogram and electrocardiogram were normal. X-ray films of the right ilium disclosed an area of abnormal bone architecture suggestive of a tumor metastasis. The serum bilirubin, cholesterol, uric acid, creatine, creatinine, Na, Cl, Ca, and K were all normal. The urinary excretion of creatine was 120 mg a day. The Millon reaction of urine was positive in most of occasions. The result of the oral glucose tolerance test was slightly diabetic. Fasting levels of blood citrate was 0.22 mM;  $\alpha$ -ketoglutarate, 0.021 mM, lactate, 1.2 mM; pyruvate, 0.089 mM; and NEFA, 0.64 mM. The citrate level dropped to 0.056 mM in 60 minutes following 30 g oral glucose administration. Non-specific serum-protein flocculation tests were normal except for the cobaltous chloride reaction of R<sub>1</sub><sup>16</sup>. The total serum protein was 6.8 g per 100 ml, with 31% albumin, 7%  $\alpha_1$ -globulin, 17%  $\alpha_2$ -globulin, 16%  $\beta$ -globulin and 29%  $\gamma$ -globulin. The serum alkaline phosphatase was 16.6 Bessey units; lactic dehydrogenase, 2,100 Wroblewsky units; cholinesterase, 0.85  $\Delta$  pH; and glutamic oxaloacetic transaminase and glutamic pyruvic transaminase, 56 and 36 Karmen units, respectively.

## Clinical Summaries

The patient was placed on a regular hospital diet during the period of control examination. Thereafter, the carbohydrate content of the diet was gradually lowered and the amount of protein and fat increased; his daily intake of total calory being slightly increased. The daily carbohydrate content was finally reduced to 5~10 g, which was inherent as a result of the intake of glycogen-containing meat. The conclusive gluconeogenic diet chiefly consisted of beef, pork, ham, cheese, eggs, fish, mayonnaise, gelatin, and less than 40 g per day of tomato, cucumber or lettuce. Artificial flavor and sweetening agent (sodium cyclamate) were also used. The dietary regimen used for the therapy is summarized in Fig. 3. Drip infusion of Ringer solution with 10 mg of vitamin B<sub>2</sub>, 10 mg pyridoxal phosphate, 500 mg of vitamin C and 20 mg of vitamin K<sub>1</sub> and oral administration of daily doses of 1 to 2 g Vitaplex\* with additional 6 mg vitamin B<sub>2</sub>, 30 to 60 mg pyridoxal phosphate, 30 mg vitamin B<sub>6</sub>, 30 mg nicotinamide, 200 mg calcium pantothenate and 50 mg  $\alpha$ -tocopherol were continued throughout the therapy. Two g of calcium lactate and 6 to 9 tablets of Eizym\*, a digestive enzyme preparation, were also used.

The patient lost 3 kg in weight in one week after hospitalization, and no further loss in weight was seen thereafter. After the carbohydrate content of the diet was reduced to 100 g per day, he complained of hunger feeling and thirsty, and complete satiety did not result after eating. By increasing the

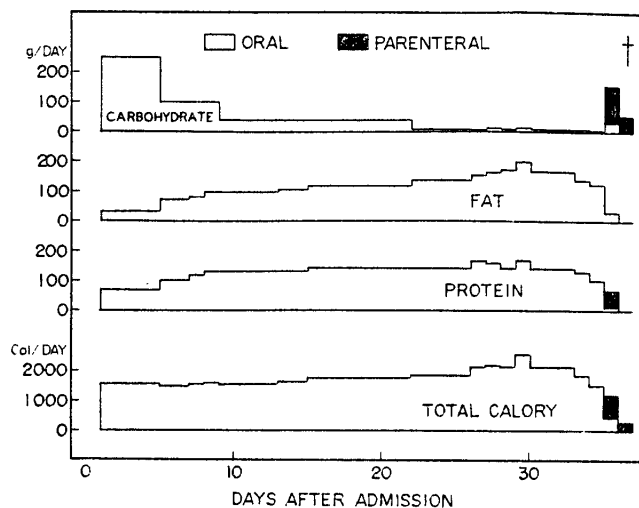


Fig. 3 Daily intake of carbohydrate, fat, protein and total calory during the entire course of the dietotherapy

\* Eisai Pharmaceutical Co.

amount of fat and protein in the diet, the hyperhydrosis and general weakness were partially removed and his appetite increased. The patient could well tolerate a considerably large amount of fat. His general condition was even slightly improved from 12 to 20th hospital days. The swelling observed on the anterior part of the right ilium also became less marked in this period, but the pain persisted. A frequent block of right femoral and sciatic nerves with xylocaine was effective in relieving the pain.

A positive test for urinary acetone bodies was always obtained after the daily carbohydrate intake was reduced below 40 g. The result of quantitative estimation of urinary total ketone bodies is given in Fig. 4 together with the

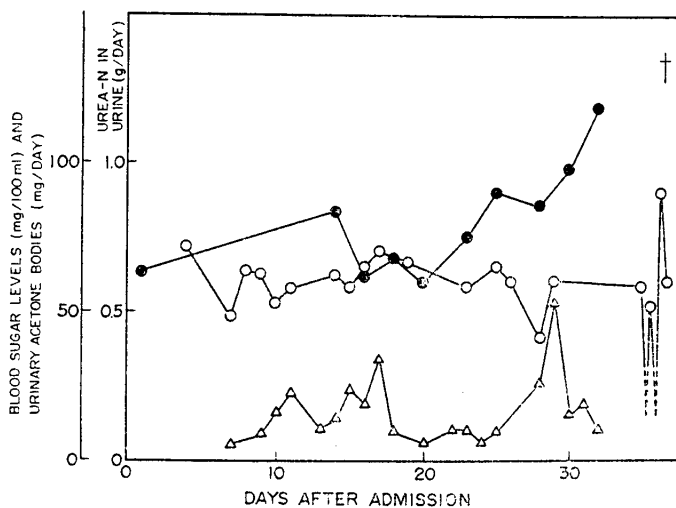


Fig. 4 Blood sugar levels and urinary excretions of urea and total ketone bodies during the therapy with the gluconeogenic diet

○—○, blood sugar; ●—●, urinary urea-N; and △—△, urinary total ketone bodies.

results on the urinary secretion of urea and the blood sugar. Further reduction of carbohydrate content as low as 5~10 g per day did not result in an increased ketone body secretion. The fasting blood sugar levels were relatively low but well maintained around 60 mg per 100 ml throughout the period of gluconeogenic diet except for the last two days before his death, when he developed hypoglycemia. Postprandial rises in the blood sugar with gluconeogenic diets were minor as compared with the rises after oral administration of larger amounts of glucose (Fig. 5).

The levels of citrate and NEFA in the blood increased markedly after the carbohydrate content in the diet was reduced to 40 g per day. The citrate increased further but transiently after reduction of the carbohydrate content to 5



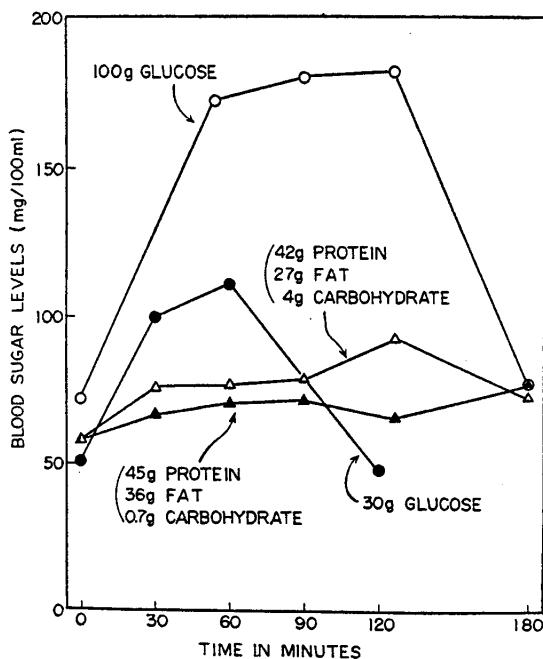


Fig. 5 Blood sugar levels after oral glucose administrations in the control period compared with those after meals during the dietotherapy

~10 g per day. The blood pyruvate, lactate and  $\alpha$ -ketoglutarate levels were slightly lower when the citrate and NEFA concentrations were high. The course of these metabolite changes in the blood is summarized in Fig. 6. The size of

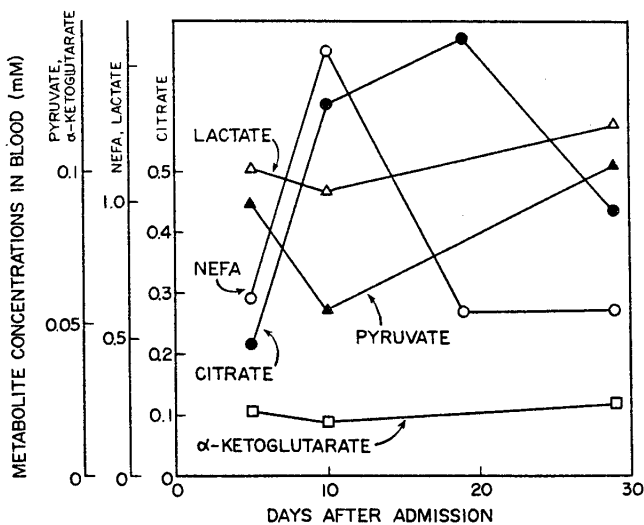


Fig. 6 Effects of the gluconeogenic diet on metabolite concentrations in the blood

the right lobe of liver and the alkaline phosphatase activity of serum decreased slightly when the citrate level was high and an improvement in his general conditions was noted (Figs. 7 and 8). The left lobe of liver did not change in size.

After about three weeks of hospitalization, the patient began to complain

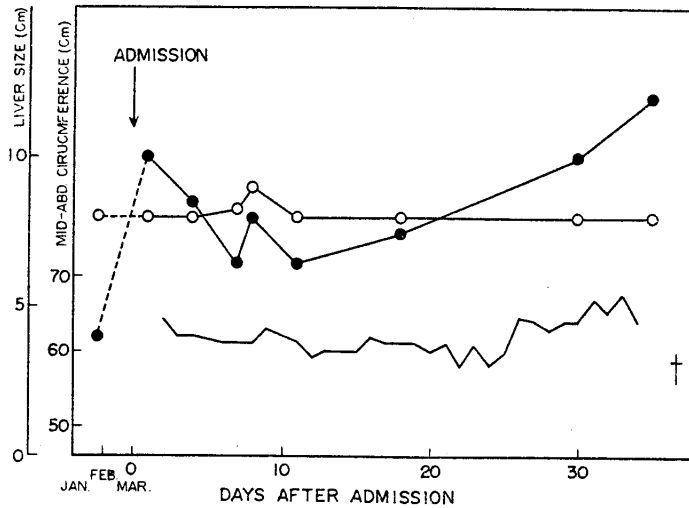


Fig. 7 Changes in liver size and mid-abdominal circumference during the therapy with the gluconeogenic diet  
Liver sizes below the costal margin: ●—●, on the right mammillary line; ○—○, on the left mammillary line. —, Mid-abdominal circumference.

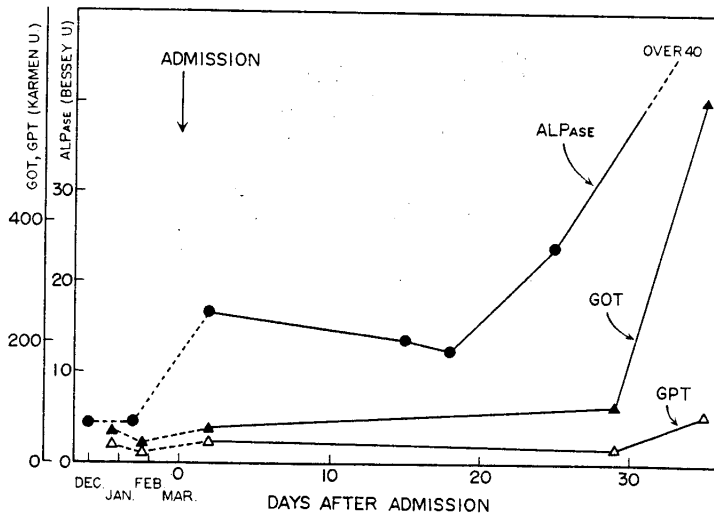


Fig. 8 Serum enzyme activities during the therapy with the gluconeogenic diet  
ALPase, alkaline phosphatase; GOT, glutamic oxaloacetic transaminase; and GPT, glutamic pyruvic transaminase

of intractable general weakness, and tachypnea and tachycardia were noted. The result of the heart examination by electrocardiogram and phonocardiogram revealed Hegglin's syndrome, suggesting the presence of myocardial damage related to metabolic disturbances<sup>17</sup>. Intravenous administration of 1 g potassium aspartate, 1 g magnesium aspartate, 20 mg adenosine triphosphate, 30 mg thiamine pyrophosphate, 25 mg  $\alpha$ -lipoic acid and 20 mg flavin adenine dinucleotide in the Ringer solution was instituted in an attempt to correct the myocardial damage.

At this time the presence of a metabolic acidosis was evident from the increased blood citrate and urinary ketone bodies, but the total carbon dioxide content in the blood was not reduced. Since the acidosis was not progressive, the daily carbohydrate content was further reduced to 5~10 g and the total calory increased by giving more fat. With the conclusive gluconeogenic diet, the general weakness, hunger feeling, tachypnea and tachycardia did not seem to increase further.

Around the 30th hospital day, an increasing distension in the epigastrium was noted and a new solid tumor became palpable. An increase in size of the right liver lobe was also noted and the blood enzyme activities markedly increased again (Figs. 7 and 8). He complained of sense of fullness in the epigastrium and his appetite reduced. The blood citrate tended to decline and the NEFA returned normal (Fig. 6). By this time, most of the subcutaneous adipose tissue seemed exhausted.

On the 35th day he developed hypoglycemia, which necessitated a frequent intravenous infusion of glucose solution and administration of ACTH. Although the hypoglycemia could be corrected by the parenteral glucose administration, the pulse pressure became small and the patient died of cardiac failure on 36th day.

#### Postmortem Examination

The main pathological diagnosis was a widely disseminated malignant melanoma. No melanomatous tumor was detectable on the skin and the primary lesion could not be disclosed. The autopsy findings revealed a large metastatic tumor formation at the right hip joint and a compression of the right femoral artery, vein and nerve. Metastases to the following organs were also found: lung (bilateral), liver, kidney (bilateral), right adrenal, pancreas, serosa of the rectum, bone marrow of thoracic vertebrae, and several lymph nodes.

The liver was markedly enlarged (4,600 g) due to massive metastasis of melanoma, leaving apparently intact liver tissue as small as ten per cent of the total. The left lobe was almost replaced by a solid melanotic tumor mass. The tumor mass in the right liver lobe was partly amelanotic (Fig. 9). Microscopi-

cally the tumor cells varied largely in cell type and showed pleomorphism and pronounced atypia with varying amounts of melanin pigment (Fig. 10). The staining characteristics of the pigmented material<sup>18</sup> and the darkening of a less pigmented tumor mass upon exposure to the air substantiate that the pigment is melanin rather than bile or iron.

A generalized atrophy of adipose tissue was marked and the tissue was microscopically similar to that of a new born baby. Pathological findings of the cardiovascular system were dilatations of the right atrium and left ventricle and slight atrophy and fibrosis of myocardium. The cause of death is subacute cardiac failure.

The activities of hepatic tumor fructose-1, 6-diphosphatase, glucose-6-phosphate dehydrogenase, glutamic oxaloacetic transaminase and glutamic pyruvic transaminase measured with the autopsy material are given in Table 1. Activi-

Table 1 Enzyme activities in hepatic tumor tissues

Enzyme	FDPase m $\mu$ moles/min. /mg protein	GOT Karmen U. /mg protein	GPT Karmen U. /mg protein	G6PDH m $\mu$ moles/min. /mg protein
Intact liver (right lobe)	83	1050	450	15
Amelanotic tumor (right lobe)	38	670	190	31
Melanotic tumor (right lobe)	46	750	220	40
Melanotic tumor (left lobe)	2.6	28	10	40

Abbreviations used for enzymes: see the legend to Fig. 8 and the foot-note in the text.

ties of the three gluconeogenic enzymes were all very low in a melanotic tumor tissue of the left lobe, which showed no appreciable change in size during the dietotherapy, and slightly reduced in both melanotic and amelanotic tumors of the right lobe, which grew rapidly at the end of the dietotherapy. A microscopical examination of the counterpart of the tissues used for enzyme assay disclosed that the tumor tissue from the left lobe was not contaminated with liver parenchymal cells but the rapidly growing right-lobe tumor tissues, with or without melanin, retained some intact liver parenchymal cells. The activities of glucose-6-phosphate dehydrogenase were rather high in the tumor tissues.

#### COMMENTS

Since in the original report of HUBBARD and POGELL the curative effect of carbohydrate deprivation on the growth of Novikoff hepatoma has been shown to be limited to the hepatic tumor<sup>1</sup>, the most pertinent subject to be tested in

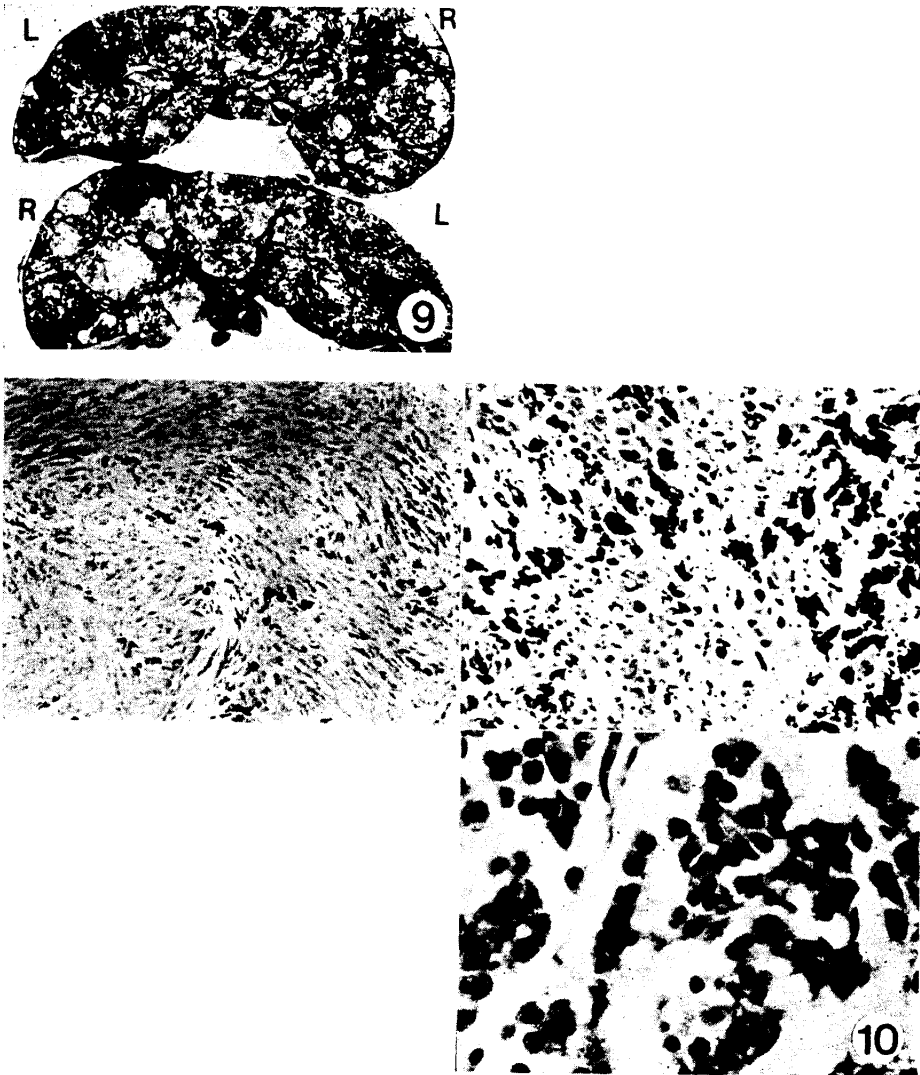


Fig. 9 Cross-sections of the liver, indicating intermingled melanotic and amelanotic tumor masses. R, right liver lobe; L, left liver lobe.

Fig. 10 Microscopic findings of tumor tissues showing pleomorphism and atypia of melanoma cells.

extension of the rat hepatoma studies to clinical materials is naturally a primary hepatoma. The present case treated as a primary hepatoma was unfortunately proved to be malignant melanoma, which is notorious for its malignancy, and its metastases to the liver. A case with a similar difficulty in diagnosis has been reported where an apparent metastatic melanoma to the liver behaved clinically and histologically as a hepatocarcinoma<sup>19</sup>. Even with these unfavorable situations, considerable improvements in general conditions, hepatic tumor size and serum alkaline phosphatase activity were seen transiently during the gluconeogenic dietary therapy. Causes of the exacerbation observed in the latter stage with the even more strict gluconeogenic diet are not known. It is hard to speculate that the tumor cells became resistant to the unfavorable metabolic conditions caused by carbohydrate deprivation. A spontaneous cessation of tumor growth might be seen transiently in the natural course of tumor development. However, in the present case the growth of the right hepatic tumor and the increase in the serum alkaline phosphatase activity had been so rapid until the gluconeogenic diet was instituted that it leaves little possibility for the spontaneous arrest of the tumor growth.

Although no idea of biochemical mechanism of the inhibition of tumor growth by carbohydrate deprivation is available at present, one possible explanation has been suggested by HUBBARD and POGELL<sup>1</sup>, namely, the inhibition of phosphofructokinase, and hence the active glycolysis of tumor cells by citrate. The concentration of this metabolite is known to increase under gluconeogenic conditions<sup>20</sup>. Increased free fatty acids in the fasting blood are also known to suppress glucose utilization<sup>21</sup>. The inhibition of active tumor glycolysis by citrate and free fatty acids would curtail the utilization by tumor of glucose which is produced by intact liver cells as a result of gluconeogenesis and would block the unfavorable metabolic interaction between normal and tumor cells. This is an attractive idea in view of the fact that the tumor growth of the right hepatic lobe ceased when the citrate and NEFA levels in the blood were high, and the tumor resumed to grow rapidly when the citrate tended to decline and the NEFA returned normal. From the fact that the patient developed hypoglycemia in the latter stage, it is evident that the utilization of glucose by the tumor or peripheral tissues was markedly enhanced at the lower citrate and NEFA concentrations. The complete exhaustion of peripheral adipose tissue and the development of hypoglycemia despite the intake of tremendously large amounts of fat suggest that in carbohydrate deprivation the requirement of fat for the tumor-bearing subject is much greater than that for a healthy man<sup>2</sup>.

Insufficient production of glucose by the intact liver is also very probable, because the amount of apparently intact surviving liver tissue was as small as ten per cent of the total hepatic tumor mass. The presence of an impaired utili-

zation of fatty acid by the liver is not evident, because a considerable amount of ketone bodies were produced throughout the dietotherapy, and no fat accumulation in the liver was found in necropsy.

The ketone body formation is thought to be an index of enhanced gluconeogenesis<sup>22</sup>, and it may not be harmful as far as it does not cause a severe metabolic acidosis, because the peripheral tissues can utilize ketone bodies as an energy source. In fact, the ketone body concentration in the blood or the amount excreted in the urine in the present case did not increase with the increasing intake of dietary fat. This could be interpreted as a result of adaptive mechanism of ketone body-utilizing tissue metabolism rather than a limited production of ketone bodies. On the other hand, the incomplete breakdown of fatty acid to acetoacetate would reduce the caloric efficiency of fat oxidation in the liver, and extra energy required for the increased gluconeogenesis must be supplied by ATP formation in  $\beta$ -oxidation of fatty acids. This would explain the necessity of giving extraordinary large amounts of fat in gluconeogenic diet, and actually the patient could take fat as high as 200 g per day. It is not known, however, whether the predominant utilization of fatty acids in the heart muscle is associated with the myocardial damage, which was the direct cause of death in the present case.

#### SUMMARY

A case of malignant melanoma with metastases mainly to the liver and the right ilium was treated with a gluconeogenic diet. The carbohydrate content of the diet was finally reduced to 5~10 g per day and the remaining calories were derived from protein and fat.

Increased blood citrate and NEFA concentrations, increased ketone body formation and the maintenance of a reasonable level of blood sugar confirmed the attainment of a gluconeogenic metabolic state. Definite improvements in size of a hepatic tumor, serum alkaline phosphatase activity and the general condition were observed transiently during the dietary therapy. Growth of the tumor resumed despite the continued gluconeogenic therapy, and the patient died of cardiac failure.

Concentrations of gluconeogenic enzymes, fructose-1, 6-diphosphatase, glutamic oxaloacetic transaminase and glutamic pyruvic transaminase, were all found to be very low in the tumor tissue as expected.

#### ACKNOWLEDGEMENT

The authors wish to express their thanks to Dr. POGELL for affording us a valuable opportunity of testing clinically his interesting observation on experimental animals and also for his revision of the manuscript. Grateful acknowledgement is also due to Miss Keiko NISHIMURA, the chief nutritionist in Okayama University Hospital, for her active cooperation in carrying out

the present dietary therapy. Pathological examinations of the postmortem materials were done by Dr. K. Sogabe, Department of Pathology, Okayama University Medical School.

## REFERENCES

1. HUBBARD, J. D. and POGELL, B. M. : Differential effect of carbohydrate deprivation on growth of Novikoff hepatoma in liver and peritoneum. *Proc. Amer. Assoc. Cancer Res.* 8, 32d, 1967
2. LIEB, C. W. : The effects on human beings of a twelve months' exclusive meat diet. *J. Amer. Med. Ass.* 93, 20, 1929
3. MANN, G. : Personal communication through Pogell, B.M., February 8, 1967
4. RESOURCE COUNCIL OF SCIENCE and TECHNOLOGY AGENCY: *Nutritional Analysis of Japanese Foods Latest Edition*, Ishiyaku Publishers, Inc., Tokyo, 1965 (in Japanese)
5. SOMOGYI, M. : Notes on sugar determination. *J. Biol. Chem.* 195, 19, 1952
6. NATELSON, S. : *Microtechniques of Clinical Chemistry*. 2nd Ed., p. 87, Charles C. Thomas, Publishers, Springfield, 1961
7. ITAYA, K. and UI, M. : Colorimetric determination of free fatty acids in biological fluids. *J. Lipid Res.* 6, 16, 1965
8. ETTINGER, R. H., GOLDBAUM, L. R. and SMITH, L. H., JR. : A simplified photometric method for the determination of citric acid in biological fluids. *J. Biol. Chem.* 199, 531, 1952
9. HOHORST, H. J. : L-(+)-Lactate, determination with lactic dehydrogenase and DPN. In *Methods of Enzymatic Analysis* (Ed. : Bergmeyer, H. U.). p. 266, Academic Press, New York, 1963
10. BÜCHER, TH., CZOK, R., LAMPRECHT, W. and LATZKO, E. : Pyruvate. In *Methods of Enzymatic Analysis* (Ed. : Bergmeyer, H. U.). p. 253, Academic Press, New York, 1963
11. BERGMAYER, H. U. and ERICH, B. :  $\alpha$ -Oxoglutarate. In *Methods of Enzymatic Analysis* (Ed. : Bergmeyer, H. U.). p. 324, Academic Press, New York, 1963
12. BESSEY, O. A., LOWRY, O. H. and BROCK, M. J. : A method for the rapid determination of alkaline phosphatase with five cubic millimeters of serum. *J. Biol. Chem.* 164, 321, 1964
13. REITMAN, S. and FRANKEL, S. : A colorimetric method for the determination of serum glutamic oxalacetic and glutamic pyruvic transaminases. *Am. J. Clin. Path.* 28, 56, 1957
14. POTTER, V. R. : The homogenate technique. In *Methods in Medical Research*. Vol. 1, p. 317, Year Book Publishers, Inc., Chicago, 1948
15. TAKETA, K. and POGELL, B. M. : Allosteric inhibition of rat liver fructose 1,6-diphosphatase by adenosine 5'-monophosphate. *J. Biol. Chem.* 240, 651, 1965
16. KUMO, T. : Colloid-chemical studies of serum in impaired liver functions: II. Serum coagulation reaction by cobaltous chloride. *Jikken-shokaki-byogaku* 17, 415, 1942 (in Japanese)
17. OTA, I. : Studies on Hegglin syndrome. *J. Jap. Soc. Internal Med.* 48, 1399, 1959 (in Japanese)
18. LILLIE, R. D. : *Histopathologic Technic and Practical Histochemistry*. p. 422, McGraw-Hill Book, Co., New York, 1965
19. Clinicopathologic Conference. *Proc. Mayo Clinic* 40, 260, 1965
20. DIXIT, P. K., DEVILLIERS, D. C., JR. and LAZAROW, A. : Citrate metabolism in diabetes. II. Tissue citrate content, citrate synthase and oxidation in alloxan-diabetic rat. *Metabolism* 16, 285, 1967
21. WEBER, G. : Feedback inhibition of key glycolytic enzymes in liver: Action of free fatty acids. *Science* 154, 1357, 1966
22. KREBS, H. A. : The regulation of the release of ketone bodies by the liver. In *Advances in Enzyme Regulation* (Ed. : Weber, G.). Vol. 4, p. 339, Pergamon Press, Oxford, 1966