

Acta Medica Okayama

Volume 58, Issue 5

2004

Article 2

OCTOBER 2004

Intrapulmonary lymph nodes: thin-section CT findings, pathological findings, and CT differential diagnosis from pulmonary metastatic nodules.

Tsuyoshi Hyodo*

Susumu Kanazawa†

Shuichi Dendo‡

Keita Kobayashi**

Hirohide Hayashi††

Yoshihiro Kouno‡‡

Mamoru Fujishima§

Yoshio Hiraki¶

*Okayama University,

†Okayama University,

‡Okayama University,

**Okayama University,

††Okayama Red Cross Hospital,

‡‡Fukuyama National Hospital,

§Tsuyama Central Hospital,

¶Okayama University,

Intrapulmonary lymph nodes: thin-section CT findings, pathological findings, and CT differential diagnosis from pulmonary metastatic nodules.*

Tsuyoshi Hyodo, Susumu Kanazawa, Shuichi Dendo, Keita Kobayashi, Hirohide Hayashi, Yoshihiro Kouno, Mamoru Fujishima, and Yoshio Hiraki

Abstract

We compared the thin-section CT findings of 11 intrapulmonary lymph nodes with pathological findings and evaluated the possibility of CT scan differential diagnosis from pulmonary metastatic nodules. First, we retrospectively reviewed CT scan and pathological findings of intrapulmonary lymph nodes. The median size of these nodules was 6.2 mm. The nodules appeared round (n=3) or angular (n=8) in shape with a sharp border, and they were found below the level of the carina. The median distance from the nearest pleural surface was 4.6 mm, and 3 of the 11 nodules were attached to the pleura. On thin-section CT scan, linear densities extending from the intrapulmonary lymph nodes were frequently visualized, and were pathologically proven to be ectatic lymphoid channels. We then compared the thin-section CT findings of 8 metastatic nodules less than 1 cm in diameter with those of the 11 intrapulmonary lymph nodes. The median size of these nodules was 6.8 mm, and the median distance from the nearest pleural surface was 16 mm. All nodules appeared round in shape. None of the nodules had linear densities extending from the nodules. The linear densities on thin-section CT scan may be the most useful characteristic of intrapulmonary lymph nodes, when differential diagnosis from metastatic nodules is necessary.

KEYWORDS: intrapulmonary lymph nodes, thin-section CT scan, pathological findings, pulmonary metastatic nodules

*PMID: 15666992 [PubMed - indexed for MEDLINE]

Copyright (C) OKAYAMA UNIVERSITY MEDICAL SCHOOL

Original Article

Intrapulmonary Lymph Nodes: Thin-Section CT Findings, Pathological Findings, and CT Differential Diagnosis from Pulmonary Metastatic Nodules

Tsuyoshi Hyodo^{a*}, Susumu Kanazawa^a, Shuichi Dendo^a, Keita Kobayashi^b, Hirohide Hayashi^c, Yoshihiro Kouno^d, Mamoru Fujishima^e, and Yoshio Hiraki^a

^aDepartments of Radiology and ^bPathology, Okayama University Graduate School of Medicine and Dentistry, Okayama 700-8558, Japan,

^cDepartment of Radiology, Okayama Red Cross Hospital, Okayama 700-8607, Japan,

^dDepartment of Radiology, Fukuyama National Hospital, Fukuyama 720-8520, Japan, and

^eDepartment of Radiology, Tsuyama Central Hospital, Tsuyama 708-0841, Japan

We compared the thin-section CT findings of 11 intrapulmonary lymph nodes with pathological findings and evaluated the possibility of CT scan differential diagnosis from pulmonary metastatic nodules. First, we retrospectively reviewed CT scan and pathological findings of intrapulmonary lymph nodes. The median size of these nodules was 6.2 mm. The nodules appeared round (n = 3) or angular (n = 8) in shape with a sharp border, and they were found below the level of the carina. The median distance from the nearest pleural surface was 4.6 mm, and 3 of the 11 nodules were attached to the pleura. On thin-section CT scan, linear densities extending from the intrapulmonary lymph nodes were frequently visualized, and were pathologically proven to be ectatic lymphoid channels. We then compared the thin-section CT findings of 8 metastatic nodules less than 1 cm in diameter with those of the 11 intrapulmonary lymph nodes. The median size of these nodules was 6.8 mm, and the median distance from the nearest pleural surface was 16 mm. All nodules appeared round in shape. None of the nodules had linear densities extending from the nodules. The linear densities on thin-section CT scan may be the most useful characteristic of intrapulmonary lymph nodes, when differential diagnosis from metastatic nodules is necessary.

Key words: intrapulmonary lymph nodes, thin-section CT scan, pathological findings, pulmonary metastatic nodules

The widespread use of CT scan in mass screening examinations for lung cancer and the development of chest roentgenogram and CT scan has increased the opportunity to detect small nodular shadows in peripheral lung fields [1, 2]. Intrapulmonary lymph nodes are frequently identified among these nodular shadows [3-10], and differential diagnosis is often difficult [11, 12].

In particular, in cancer patients it is clinically important to differentiate such nodules from pulmonary metastasis. Therefore, a definitive diagnosis of intrapulmonary lymph nodes is essential to avoid unnecessary surgery. Although thin-section CT scan of intrapulmonary lymph nodes has recently been reported [13-15], to our knowledge, thin-section CT findings have not previously been compared with pathological findings. We have surmised that a precise comparison of thin-section CT findings and pathological findings of intrapulmonary lymph nodes would be useful in clarifying the CT morphological charac-

Received January 21, 2004; accepted March 12, 2004.

*Corresponding author. Phone: +81-86-235-7313; Fax: +81-86-235-7316
E-mail: radiol@cc.okayama-u.ac.jp (T. Hyodo)

teristic of intrapulmonary lymph nodes. In the present study, we compared the thin-section CT findings of 11 intrapulmonary lymph nodes with the pathological findings. These CT findings were then compared with those of 8 metastatic nodules to evaluate the possibility of using CT scan in carrying out a differential diagnosis.

Materials and Methods

From October 1996 through June 2002, 150 patients with 168 lesions underwent video-assisted thoracic surgery (VATS) resection for pulmonary lesions at our institution and affiliated hospitals. All patients underwent CT scan prior to surgery. Fifty-five of the lesions were well-circumscribed peripheral pulmonary nodules, and the remaining lesions had ground-glass attenuation and spiculation, which are typically observed in primary lung cancer. Of these 55 well-circumscribed nodules, 18 (17 patients) were pathologically proven to be intrapulmonary lymph nodes. The other nodules included 12 pulmonary metastasis, 14 granulomas, 6 hamartomas, and 5 tuberculomas. In 11 of the 18 intrapulmonary lymph nodes, thin-section CT findings could be compared with the pathological findings of tissue on the same level as in CT scan. The other 7 nodules could not be sufficiently compared with the pathological findings because of tissue contusion during resection. We retrospectively reviewed the size, shape, internal texture, location, and distance from the nearest pleural surface of these 11 nodules. In addition, the appearance of the pulmonary parenchyma around the lesion was also analyzed, specifically the relationship between the intrapulmonary lymph nodes and

interlobular septa.

During the study period, 11 patients with 12 nodules who underwent VATS resection for pulmonary lesions were pathologically proven to have pulmonary metastasis. In these 12 nodules, 8 nodules were < 1 cm in diameter. The thin-section CT findings of these 8 nodules were compared with the intrapulmonary lymph nodes described above.

The CT instruments used were a HiSpeed Advantage (GE), a SOMATOM Pulse 4 (SIEMENS), or an Aquilion (Toshiba) unit. A conventional CT scan of whole lungs was performed contiguously with a slice thickness of 10 mm. Additional thin-section (1.0 or 3.0 mm collimation, pitch 1) scans were obtained at the site of the lesion.

Results

The thin-section CT findings of the intrapulmonary lymph nodes are summarized in Table 1. The patients included 6 men and 4 women, and their ages ranged from 51 to 71 years (median 60.2 years). All patients were asymptomatic. Six of the 10 patients were heavy smokers. One patient had two nodules, and the remaining 9 had a solitary nodule. The size of the nodules ranged from 3–9 mm (median 6.2 mm). The nodules appeared round ($n = 3$) or angular ($n = 8$) in shape with a sharp border. The nodules that appeared angular in shape had a straight border on all margins. On soft-tissue windows, the internal texture of all nodules was homogenous without any calcification. One nodule was located in the right middle lobe, 2 in the right lower lobe,

Table 1 Thin-section CT findings of intrapulmonary lymph nodes ($n = 11$)

Case	Age (years) / Sex	Smoking habits	Known malignancy	Number	Size (mm)	Location	Shape	Internal texture	Distant from pleura (mm)	Linear density
1	66/F	no	no	1	5	LLL	round	homogenous	5	no
2	66/F	no	renal cell carcinoma	1	3	RML	round	homogenous	0	no
3	58/M	yes	lung cancer	1	4	LLL	angular	homogenous	12	yes
4	51/M	yes	no	1	8	RLL	angular	homogenous	12	yes
5	62/F	no	no	1	6	RLL	angular	homogenous	7	yes
6	49/F	yes	no	1	9	LLL	angular	homogenous	1	yes
7	71/M	yes	lung cancer	1	5	LLL	angular	homogenous	0	yes
8	61/M	no	lung cancer	1	6	LLL	angular	homogenous	9	yes
9	55/M	yes	lung cancer	1	5	LLL	round	homogenous	0	yes
10	63/M	yes	lung cancer	2	8	LLL	angular	homogenous	2	yes
					9	LLL	round	homogenous	3	yes

LLL, left lower lobe; RLL, right lower lobe; RML, right middle lobe.

and 8 in the left lower lobe. The distance from the nearest pleural surface ranged from 0–12 mm (median 4.6 mm), and 3 nodules were attached to the pleura. On thin-section CT scan, the linear densities extending from the intrapulmonary lymph nodes were visualized in 9 nodules, while the remaining 2 nodules showed no linear densities. Three of these linear densities were thickened interlobular septa, 4 were thickened non-interlobular septa, and 2 were some of both on thin-section CT scan. Pathologically, all nodules exhibited anthracotic pigmentation without any calcification. Linear densities extending from the intrapulmonary lymph node were pathologically proven to be ectatic lymphoid channels in all 9 nodules when the specimens were compared at the same level as the CT scan (Fig. 1). However, of 2 nodules without linear densities on thin-section CT scan, one had ectatic lymphoid channels pathologically. The remaining nodule had neither linear density on thin-section CT scan nor ectatic lymphoid channels pathologically. In addition, 2 nodules had linear densities near the lung parenchyma of the nodule (Fig. 2). Because of the absence of specimens compared at the same level as the CT scan, they could

not be pathologically analyzed.

We also reviewed thin-section CT findings of the 8 metastatic nodules < 1 cm in diameter. The thin-section CT findings of the metastatic nodules are summarized in Table 2. The size of the nodules ranged from 3–9 mm (median 6.8 mm). The distance from the nearest pleural surface ranged from 2–31 mm (median 16 mm), and it was longer than that of the intrapulmonary lymph node with statistical significance (Mann-Whitney test, $P < 0.01$). Though 5 nodules were located in the lower or middle lobe, 3 nodules were located in the right or left upper lobe. All nodules appeared round in shape. None of the nodules had linear densities extending from the nodules or thickened interlobular septa near the lung parenchyma of the nodule. Though 2 nodules were attached to the interlobular septa, none of them had thickened interlobular septa (Fig. 3).

Discussion

Lymph nodes have been thought to exist in the vicinity of the hilar region of the lung and central bronchi, but not

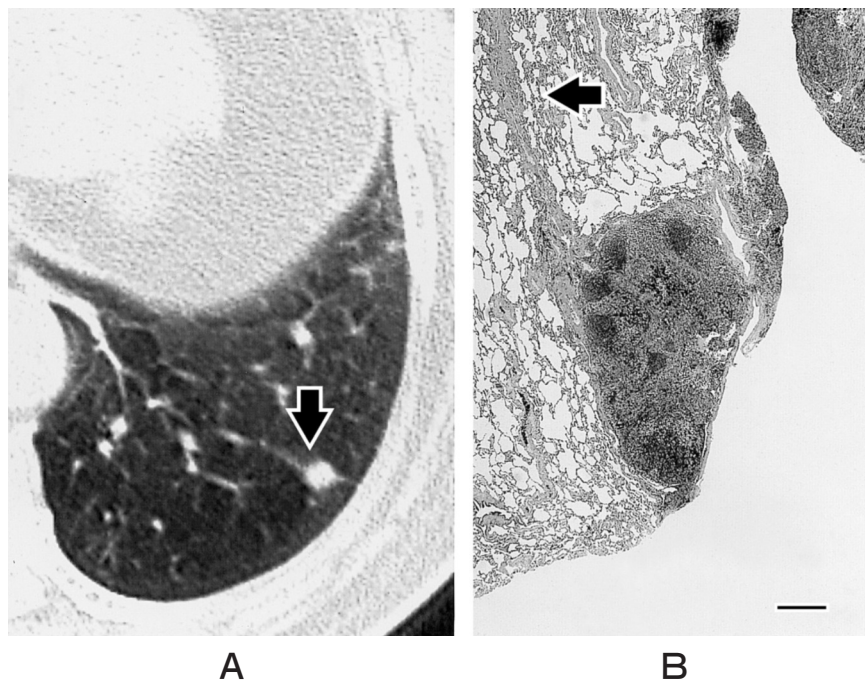


Fig. 1 Intrapulmonary lymph node in a 61-year-old man. **A**, The thin-section CT scan shows an angular nodule measuring 6 mm in diameter in the left lower lobe. Linear density (arrow) extending from the intrapulmonary lymph nodes is evident. **B**, Histological examination reveals a small lymph node with anthracosis, which has ectatic lymphoid channels (arrow) extending from the nodule (hematoxylin-eosin stain). Bar indicates 1 mm.

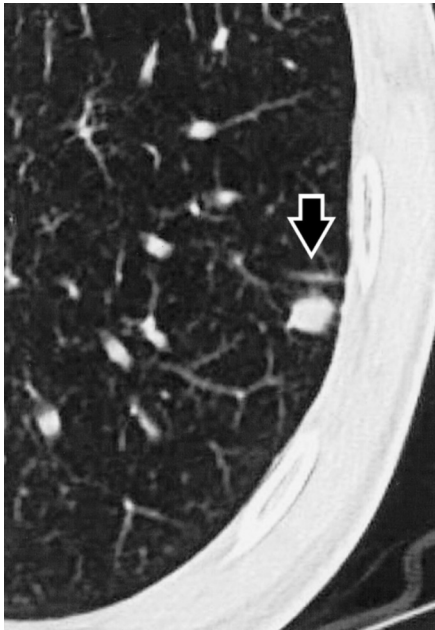


Fig. 2 Intrapulmonary lymph node in a 55-year-old man. The thin-section CT scan shows an angular nodule measuring 5 mm in diameter in the left lower lobe. Linear density (arrow) near the lung parenchyma of the intrapulmonary lymph node is evident, and is considered to be thickened interlobular septa.

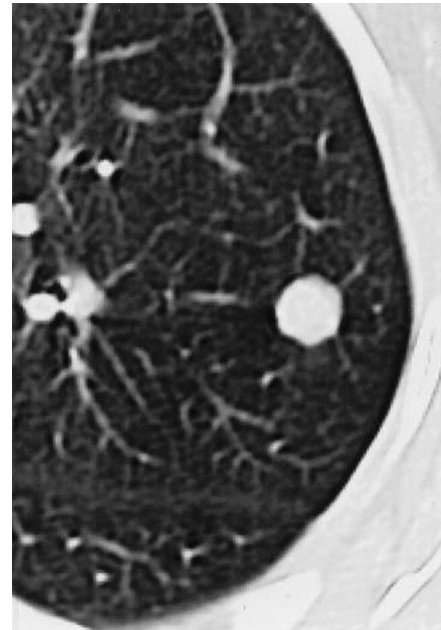


Fig. 3 Metastatic nodule in a 45-year-old man. The thin-section CT scan shows a round nodule measuring 9 mm in diameter in the left upper lobe. This nodule is attached to the interlobular septa, which is not thickened.

Table 2 Thin-section CT findings of metastatic nodes (n = 8)

Case	Age (years) /Sex	Smoking habits	Known malignancy	Number	Size (mm)	Location	Shape	Internal texture	Distant from pleura (mm)	Linear density
1	45/F	no	colon cancer	1	9	LUL	round	homogenous	9	no
2	47/F	no	gingival cancer	1	7	RUL	round	homogenous	2	no
3	66/M	yes	lung cancer	1	9	RLL	round	homogenous	21	no
4	59/M	yes	colon cancer	1	6	LLL	round	homogenous	31	no
5	59/M	no	colon cancer	1	6	RLL	round	homogenous	17	no
6	55/F	yes	thyroid cancer	1	3	RML	round	homogenous	20	no
7	54/F	no	breast cancer	1	8	LUL	round	homogenous	20	no
8	66/F	yes	colon cancer	1	3	RLL	round	homogenous	8	no

LLL, left lower lobe; LUL, left upper lobe; RLL, right lower lobe; RML, right middle lobe; RUL, right upper lobe.

after the fourth branching point [3-7]. However, using plain radiographic techniques, Trapnell [16] has demonstrated intrapulmonary lymph nodes distal to the fourth-order bronchi in 6 of 92 (7%) post-mortem lungs by injection of contrast medium into pleural lymphatic vessels. Clinically apparent intrapulmonary lymph nodes have been considered to be rare, but the widespread use and development of CT scan have increased the detection of peripheral small nodules. Intrapulmonary lymph nodes

are frequently identified among these nodules, and Bankoff *et al.* [17] have reported that the nodules in 17 (18%) of 96 patients with well-circumscribed peripheral pulmonary nodules on CT scan proved to be intrapulmonary lymph nodes. Therefore, differential diagnosis of intrapulmonary lymph nodes is clinically important [11].

According to the literature [11, 12], the clinical characteristics of intrapulmonary lymph nodes are as follows: they are (1) more frequently found in men, and

(2) more frequently found in heavy long-term smokers. The radiographic characteristics of intrapulmonary lymph nodes on conventional CT scan are as follows: (1) they are more frequently located in the subpleural area and below the level of the carina; (2) they are well-defined, homogenous, round or ovoid nodules and smaller than 12 mm in diameter, (3) sometimes more than one nodule is present. Pathologically, evidence of lymphoid follicles and anthracotic pigmentation are seen in most intrapulmonary lymph nodes. The present findings are compatible with those of previous studies. The median distance from the pleural surface was found to be only 4.6 mm, and 3 nodules were attached to the pleura in our series. Intrapulmonary lymph nodes in our series were found below the level of the carina. In our study, 3 nodules appeared round in shape. However, 8 nodules appeared angular in shape, and this finding is not compatible with previous reports. Though the exact cause for this difference remains uncertain, thin-section CT scan could demonstrate a more precise margin of nodules than can conventional CT scan. This advantage of thin-section CT scan could demonstrate the angular margin of intrapulmonary lymph nodes.

Intrapulmonary lymph nodes are considered to develop in response to antigenic stimuli, usually from inhaled dust [17]. The predominant occurrence of intrapulmonary lymph nodes in the lower lobe is explained by both the ventilation and lymphatic fluid production in the lower lung being larger than that in the upper lung, and the predominant occurrence of intrapulmonary lymph nodes in the subpleural region is explained by the rich distribution of lymphatics in this area [18]. In the present study, linear densities extending from the intrapulmonary lymph nodes were seen in 9 nodules on thin-section CT scan, which were pathologically proven to be ectatic lymphoid channels. Kardin *et al.* [8] have described intrapulmonary lymph nodes located adjacent to either pleura or interlobular septa. Oshiro *et al.* [15] have described that the linear density around the nodule is thickened interlobular septa, although the cause is unclear. We found that the thickened interlobular septa on CT scan were ectatic lymphoid channels by our pathological review. Although some previous reports have described intrapulmonary lymph nodes as sometimes accompanying spiculation or pleural indentation [11, 12], none of our patients demonstrated these characteristics. We surmise that those previous findings represent rather thickened interlobular septa and thickened non-interlobular septa by

our results. Two nodules had linear densities near the lung parenchyma of the nodule. Although we could not compare these linear densities near the lung parenchyma with the pathological findings, we speculate that the linear densities were thickened interlobular septa near the lung parenchyma and contained ectatic lymphoid channels, which are considered to develop in response to antigenic stimuli. Intrapulmonary lymph nodes are thought to be hyperplastic lymphoid nodules related to inhalation of irritant dust, and thus the growth of small collections of lymphoid tissue scattered throughout the septa occurs on lung parenchyma near the nodule.

There were 168 lesions resected by VATS during the study period. Because the lesions with ground-glass attenuation such as that seen in primary lung cancer are obviously differentiated from intrapulmonary lymph nodes, well-circumscribed nodules must be differentiated from intrapulmonary lymph nodes. Though those nodules included granuloma, hamartoma, and tuberculoma, *etc.*, we compared only metastatic nodules in the present study. The reasons for this decision were that the number of these benign nodules is generally smaller than that of metastatic nodules when VATS resection is considered as treatment, and that these benign nodules often show characteristic CT findings such as popcorn calcification and/or a fat component seen in hamartoma. Therefore, differential diagnosis from metastatic nodules is clinically important.

The distance from the pleural surface was significantly larger in metastatic nodules than in intrapulmonary lymph nodes in our series. However, we also found a metastatic nodule only 2 mm below the pleural surface. Though intrapulmonary lymph nodes are likely to be located near the pleural surface, we cannot neglect the existence of a metastatic nodule just below the pleura. On the other hand, intrapulmonary lymph nodes are likely to be located in the lower lobe in our series. It is possible to say that a small pulmonary nodule for which the linear density is not extended in the upper lobe will not become an intrapulmonary lymph node. Furthermore, an angular shape, which was observed in 8 intrapulmonary lymph nodes on thin-section CT scan, seems to be another characteristic of intrapulmonary lymph nodes. It was never, in the present study, observed in metastatic nodules. However, we have found no reports regarding the angular shape of intrapulmonary lymph nodes in based on past studies with conventional CT scans. As described above, a thin-section CT scan can demonstrate the shape of a nodule

more precisely than conventional CT scan. Further evaluation of the shapes of intrapulmonary lymph nodes on thin-section CT scan will be necessary. The most reliable evidence of intrapulmonary lymph nodes seems to be linear densities extending from the nodules. None of the metastatic nodules had linear densities extending from the nodules. In addition, the linear densities were pathologically proved to be ectatic lymphoid channels, which will never appear in metastatic nodules.

We consider that linear densities extending from intrapulmonary lymph nodes on thin-section CT scan are the most characteristic of intrapulmonary lymph nodes. If such a nodule is less than 1 cm and is located in the subpleural area and below the level of the carina, the diagnostic possibility of intrapulmonary lymph nodes will be quite high.

References

1. Siegelman SS, Khouri NF, Leo FP, Fishman EK, Braverman RM and Zerhouni EA: Solitary pulmonary nodule: CT assessment. *Radiology* (1986) 160: 307-312.
2. Remy-Jardin M, Remy J, Giraud F and Marquette CH: Pulmonary nodules: Detection with thick-section spiral CT versus conventional CT. *Radiology* (1993) 187: 513-520.
3. Greenberg HB: Benign subpleural lymph node appearing as a pulmonary 'coin' lesion. *Radiology* (1961) 77: 97-99.
4. Fellows KE Jr, Abell MR and Martel W: Intrapulmonary lymph node detected roentgenologically; case report. *Am J Roentgenol Radium Ther Nucl Med* (1969) 106: 601-603.
5. Blakely RW, Blumenthal BJ and Fred HL: Benign intrapulmonary lymph node presenting as coin lesion. *South Med J* (1974) 67: 1216-1218.
6. Rogers PM, Ayres SM and Ribaude CA: Intrafissural mid-zonal an-thracotic lymph node presenting as a coin lesion. *Chest* (1972) 61: 501-502.
7. Houk VN and Osborne DP: Subvisceral pleural lymph node presenting as an expanding intrapulmonary nodule. *Am Rev Respir Dis* (1965) 91: 596-599.
8. Kradin RL, Spirm PW and Mark EJ: Intrapulmonary lymph nodes. Clinical radiologic, and pathologic features. *Chest* (1985) 87: 662-667.
9. Rosenthal DS and Weg JG: Intrapulmonary lymph node presenting as a solitary pulmonary nodule. Report of a case. *Dis Chest* (1967) 51: 336-337.
10. Ehrenstein FI: Pulmonary lymph node presenting as an enlarging coin lesion. *Am Rev Respir Dis* (1970) 101: 595-599.
11. Yokomise H, Mizuno H, Ike O, Wada H, Hitomi S and Itoh H: Importance of intrapulmonary lymph nodes in the differential diagnosis of small pulmonary nodular shadows. *Chest* (1998) 113: 703-706.
12. Fujimoto N, Segewa Y, Takigawa N, Takata I, Hotta K, Mogami H, Nakata M, Mandai K and Eguchi K: Two cases of intrapulmonary lymph node presenting as a peripheral nodular shadow: Diagnostic differentiation from lung cancer. *Lung Cancer* (1998) 20: 203-209.
13. Awai K, Nishioka Y and Tachiyama Y: Intrapulmonary lymph node: Findings on high-resolution CT scans. *Am J Roentgenol* (1993) 161: 208-209.
14. Matsuki M, Noma S, Kuroda Y, Oida K, Shindo K and Kobashi Y: Thin-section CT features of intrapulmonary lymph nodes. *J Comput Assist Tomogr* (2001) 25: 753-756.
15. Oshiro Y, Kusumoto M, Moriyama N, Kaneko M, Suzuki K, Asamura H, Kondo H, Tsuchiya R and Murayama S: Intrapulmonary lymph node: Thin-section CT features of 19 nodules. *J Comput Assist Tomogr* (2002) 26: 553-557.
16. Trapnell DH: Recognition and incidence of intrapulmonary lymph nodes. *Thorax* (1964) 19: 44-50.
17. Bankoff MS, McEniff NJ, Bhadelia RA, Garcia-Moliner M and Daly BD: Prevalence of pathologically proven intrapulmonary lymph nodes and their appearance on CT. *Am J Roentgenol* (1996) 167: 629-630.
18. Goodwin RA and Des Prez M: Apical localization of pulmonary tuberculosis, chronic pulmonary histoplasmosis, and progressive massive fibrosis of the lung. *Chest* (1983) 83: 801-805.