

# *Acta Medica Okayama*

---

Volume 58, Issue 1

2004

Article 5

FEBRUARY 2004

---

## Usefulness of body surface mapping to differentiate patients with Brugada syndrome from patients with asymptomatic Brugada syndrome.

Kenichi Hisamatsu\*

Kengo Fukushima Kusano<sup>†</sup>

Hiroshi Morita<sup>‡</sup>

Shiho Takenaka\*\*

Satoshi Nagase<sup>††</sup>

Kazufumi Nakamura<sup>‡‡</sup>

Tetsuro Emori<sup>§</sup>

Hiromi Matsubara<sup>¶</sup>

Tohru Ohe<sup>||</sup>

\*Okayama University,

<sup>†</sup>Okayama University,

<sup>‡</sup>Okayama University,

\*\*Okayama University,

<sup>††</sup>Okayama University,

<sup>‡‡</sup>Okayama University,

<sup>§</sup>Okayama University,

<sup>¶</sup>Okayama University,

<sup>||</sup>Okayama University,

# Usefulness of body surface mapping to differentiate patients with Brugada syndrome from patients with asymptomatic Brugada syndrome.\*

Kenichi Hisamatsu, Kengo Fukushima Kusano, Hiroshi Morita, Shiho Takenaka, Satoshi Nagase, Kazufumi Nakamura, Tetsuro Emori, Hiromi Matsubara, and Tohru Ohe

## Abstract

We attempted to determine the usefulness of body surface mapping (BSM) for differentiating patients with Brugada syndrome (BS) from patients with asymptomatic Brugada syndrome (ABS). Electrocardiograms (ECG) and BSM were recorded in 7 patients with BS and 35 patients with ABS. Following the administration of Ic antiarrhythmic drugs, BSM was recorded in 5 patients with BS and 16 patients with ABS. The maximum amplitudes at J0, J20, J40 and J60 were compared between the 2 groups, as were 3-dimensional maps. The maximum amplitudes at J0, J20 and J60 under control conditions were larger in patients with BS than in patients with ABS ( $P < 0.05$ ). A three-dimensional map of the ST segments under control conditions in patients with BS showed a higher peak of ST elevation in the median precordium compared to that for patients with ABS. Increases in ST elevation at J20, J40 and J60 following drug administration were greater in patients with BS than in patients with ABS ( $P < 0.05$ ). Evaluation of the change in amplitude of the ST segment at E5 caused by Ic drug administration was also useful for differentiating between the 2 groups. In conclusion, BSM was useful for differentiating patients with BS from those with ABS.

**KEYWORDS:** body surface map, Brugada syndrome, asymptomatic Brugada syndrome, Ic antiarrhythmic drugs

---

\*PMID: 15157009 [PubMed - indexed for MEDLINE]

Copyright (C) OKAYAMA UNIVERSITY MEDICAL SCHOOL

*Original Article*

## Usefulness of Body Surface Mapping to Differentiate Patients with Brugada Syndrome from Patients with Asymptomatic Brugada Syndrome

Kenichi Hisamatsu\*, Kengo Fukushima Kusano, Hiroshi Morita,  
Shiho Takenaka, Satoshi Nagase, Kazufumi Nakamura,  
Tetsuro Emori, Hiromi Matsubara, and Tohru Ohe

*Department of Cardiovascular Medicine, Okayama University Graduate School of  
Medicine and Dentistry, Okayama 700–8558, Japan*

We attempted to determine the usefulness of body surface mapping (BSM) for differentiating patients with Brugada syndrome (BS) from patients with asymptomatic Brugada syndrome (ABS). Electrocardiograms (ECG) and BSM were recorded in 7 patients with BS and 35 patients with ABS. Following the administration of Ic antiarrhythmic drugs, BSM was recorded in 5 patients with BS and 16 patients with ABS. The maximum amplitudes at J0, J20, J40 and J60 were compared between the 2 groups, as were 3-dimensional maps. The maximum amplitudes at J0, J20 and J60 under control conditions were larger in patients with BS than in patients with ABS ( $P < 0.05$ ). A three-dimensional map of the ST segments under control conditions in patients with BS showed a higher peak of ST elevation in the median precordium compared to that for patients with ABS. Increases in ST elevation at J20, J40 and J60 following drug administration were greater in patients with BS than in patients with ABS ( $P < 0.05$ ). Evaluation of the change in amplitude of the ST segment at E5 caused by Ic drug administration was also useful for differentiating between the 2 groups. In conclusion, BSM was useful for differentiating patients with BS from those with ABS.

**Key words:** body surface map, Brugada syndrome, asymptomatic Brugada syndrome, Ic antiarrhythmic drugs

In 1992, Pedro Brugada and Joseph Brugada described eight cases of sudden cardiac death due to ventricular fibrillation (VF) without structural heart disease [1]. Electrocardiograms (ECG) of those patients were characterized by right bundle branch block with ST segment elevation in the right precordial leads (V1-V2).

Treatment with antiarrhythmic drugs is not effective for preventing cardiac events; only an implantable cardioverter-defibrillator (ICD) is effective for preventing

sudden death. However, the recommendation of ICD implantation for patients showing Brugada-type ECG characteristics but with no history of VF or syncope (asymptomatic Brugada syndrome) is controversial. Brugada and Brugada recently recommended ICD implantation for asymptomatic patients who had a spontaneously abnormal ECG, and in whom ventricular arrhythmias were inducible [2]. Priori *et al.* reported that information on the history of asymptomatic patients was important for quantifying the risk for sudden cardiac death, and for deciding whether an ICD should be used [3]. We reported that asymptomatic Brugada syndrome without an obvious family history of sudden cardiac death

Received May 28, 2003; accepted October 8, 2003.

\*Corresponding author. Phone: +81-86-235-7351; Fax: +81-86-235-7353  
E-mail: kenichi@cc.okayama-u.ac.jp (K. Hisamatsu)

was a relatively benign disease during a mean follow-up period of  $42.5 \pm 21.6$  months [4]. Thus, we believe that it is important to differentiate patients with Brugada syndrome from those with asymptomatic Brugada syndrome.

Recent studies have shown that body surface mapping (BSM) is useful for evaluating the characteristics of ST elevation in symptomatic patients with Brugada syndrome [5, 6]. The present study was therefore carried out to determine whether patients with Brugada syndrome and those with asymptomatic Brugada syndrome could be discriminated on the basis of ST elevation characteristics using body surface mapping (BSM).

## Materials and Methods

**Subjects.** Brugada-type ECG showed the typical electrocardiographic “Brugada sign,” which was defined previously [4]. We defined patients with asymptomatic Brugada syndrome as patients with Brugada-type ECG, and with no history of spontaneous VF or syncope before the examinations, regardless of a family history of sudden death. The subjects were 42 patients with Brugada-type ECG (including 7 patients with Brugada syndrome and 35 patients with asymptomatic Brugada syndrome). The clinical and electrocardiographic characteristics of the subjects are summarized in Table 1. The ages of the patients in the 2 groups were not significantly different ( $48 \pm 7$  vs.  $47 \pm 8$  years old). Four of the 7 patients with Brugada syndrome and 1 of the 35 patients with asymptomatic Brugada syndrome had family histories of sudden death. However, this single asymptomatic patient’s family history was not an obvious family history of sudden cardiac death due to Brugada syndrome and VF. No statistically significant differences were observed between the 2 groups with regards to each parameter. The results of physical examination, chest X-ray, exercise ECG and echocardiogram showed no evidence of structural heart disease in any of the patients.

**Body Surface Mapping.** The ECG and BSM recording were performed in the 7 patients with Brugada syndrome and in the 35 patients with asymptomatic Brugada syndrome.

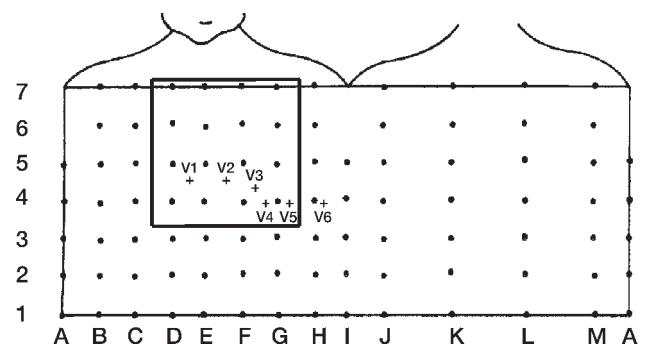
BSM was performed using a VCM-3000 (Fukuda Denshi Co., Tokyo, Japan). During sinus rhythm, unipolar electrocardiograms were recorded simultaneously from 87 lead points. Of these, 59 leads were located on the anterior region of the chest (A-I), and 28 were leads

located on the back (J-M) (Fig. 1). Row 6 coincided with the level of the parasternal second intercostal space. Row 4 coincided with the mid-clavicular fifth intercostal space. Row 5 was between rows 6 and 4, and rows 7, 3, 2 and 1 were located vertically at equal intervals. Columns A and I were located on the right and left mid-axillary lines, respectively. Column E was located on the midsternal line. Columns C and G corresponded to the right and left mid-clavicular lines, respectively.

**Table 1** Clinical and electrocardiographic characteristics

	Patients with Brugada syndrome	Patients with asymptomatic Brugada syndrome	P
Total, n	7	35	
Age, y	$48 \pm 7$	$47 \pm 8$	NS
VF/syncope, n	7	0	
Family history of sudden death, n	4	1	
ECG			
PR interval, msec	$179.2 \pm 25.7$	$164 \pm 20.6$	NS
QTc, msec	$429.7 \pm 46.3$	$412.6 \pm 42.8$	NS
SAECG			
f-QRS, msec	$120.0 \pm 10.8$	$116.8 \pm 9.2$	NS
LAS40, msec	$47.7 \pm 12.7$	$40.7 \pm 10.7$	NS
RMS40, $\mu$ V	$12.2 \pm 7.3$	$18.2 \pm 9.5$	NS

ECG, electrocardiograms; f-QRS, filtered QRS duration; LAS40, duration of low-amplitude-signals of  $< 40 \mu$ V; QTc, corrected QT interval; RMS40, root-mean-square voltage of the terminal 40 msec of the filtered QRS complex; SAECG, signal-averaged electrocardiograms; VF, ventricular fibrillation.



**Fig. 1** Eighty-seven lead points. During sinus rhythm, unipolar electrocardiograms were recorded simultaneously from the 87 lead points. The location of D-G, 4-7, shown as an open square in this figure, indicates the median precordium. Crosses indicate the standard positions of precordial leads V1 to V6.

The J point was determined by the J point of H4. The amplitudes of the ST segment 20 msec (J20), 40 msec (J40) and 60 msec (J60) after the J point were measured in the 87 leads in order to construct potential maps of each point.

**Three-dimensional Mapping.** To visualize the spatial distribution of ST elevation, we constructed a 3-dimensional map (3D map) using potential mapping data.

**Administration of Antiarrhythmic Drugs.** The drug challenge test was performed while the patient was being continuously monitored with a defibrillator in the coronary care unit, because the administration of Ic antiarrhythmic drugs to patients with Brugada syndrome can cause serious and life-threatening arrhythmias, such as VF.

Following the administration of pilsicainide, BSM was performed in 5 patients with Brugada syndrome and in 16 patients with asymptomatic Brugada syndrome. Pilsicainide (1 mg/kg), which is a pure sodium channel blocker and has a relatively short half-life compared to other Ic agents, was infused intravenously over a period of 10 min. BSM was performed at baseline and at 5 min after the infusion of the drug.

**Analysis of Data.** Data are expressed as means  $\pm$  SD. Student's *t*-test was used to analyze differences between the patients with Brugada syndrome

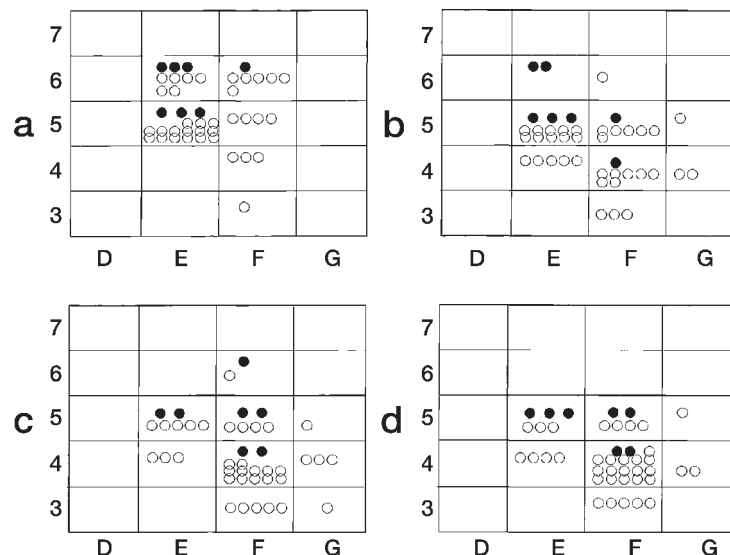
and those with asymptomatic Brugada syndrome.  $P < 0.05$  was considered statistically significant. All calculations were done using StatView-J 5.0 (SAS Institute Inc., Cary, NC, USA).

## Results

**Body Surface Potential Mapping.** The maximum amplitudes at J0, J20 and J60 were larger in patients with Brugada syndrome than in those with asymptomatic Brugada syndrome ( $2.17 \pm 1.20$  vs.  $1.26 \pm 0.98$  mV,  $P < 0.05$ ;  $2.08 \pm 1.20$  vs.  $1.03 \pm 0.79$  mV,  $P < 0.05$ ;  $1.67 \pm 0.76$  vs.  $1.07 \pm 0.64$  mV,  $P < 0.05$ , respectively). No statistically significant differences were observed between the 2 groups with regards to the maximum amplitude at J40.

The maximum amplitudes at J0, J20, J40 and J60 in the Brugada syndrome group were located at the high median precordium (E-F, 5-6) in 7 of the 7 patients (100%), 6 of the 7 patients (85.7%), 5 of the 7 patients (71.4%) and 5 of the 7 patients (71.4%), respectively (Fig. 2). In the asymptomatic Brugada syndrome group, the maximum amplitudes at the same J points were located at the high median precordium in 31 of the 35 patients (88.6%), 17 of the 35 patients (48.6%), 10 of the 35 patients (28.6%) and 7 of the 35 patients (20%), respectively.

It has been reported that 16-lead electrograms (D-G,



**Fig. 2** Locations of maximum ST elevation on body surface maps (D-G, 3-7) in 7 patients with Brugada syndrome (solid circles) and in 35 patients with asymptomatic Brugada syndrome (open circles) under control conditions. Figs. a-d show the locations at J0, J20, J40 and J60, respectively.

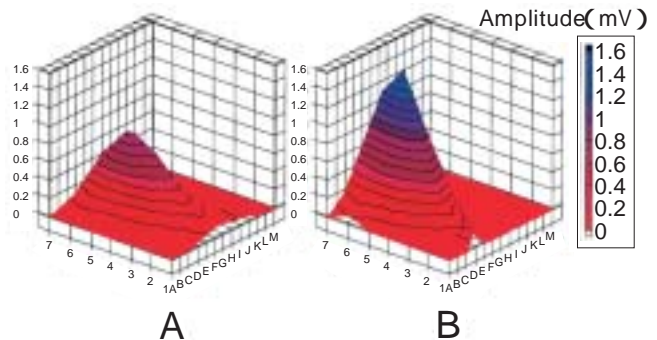
4-7) can be expected to reflect the potentials of the right ventricular outflow tract (RVOT) [5]. Our results showed that the maximum amplitude was located in a narrower region of the RVOT in patients with Brugada syndrome than in patients with asymptomatic Brugada syndrome.

**Three-dimensional Maps.** The 3D maps showed that the Brugada syndrome group had a higher peak at the median precordium, especially at E5, than did the asymptomatic Brugada syndrome group (Fig. 3). Fig. 3B shows that the blue area at the top of the 3D map was coincident with the right ventricular outflow tract (RVOT) area.

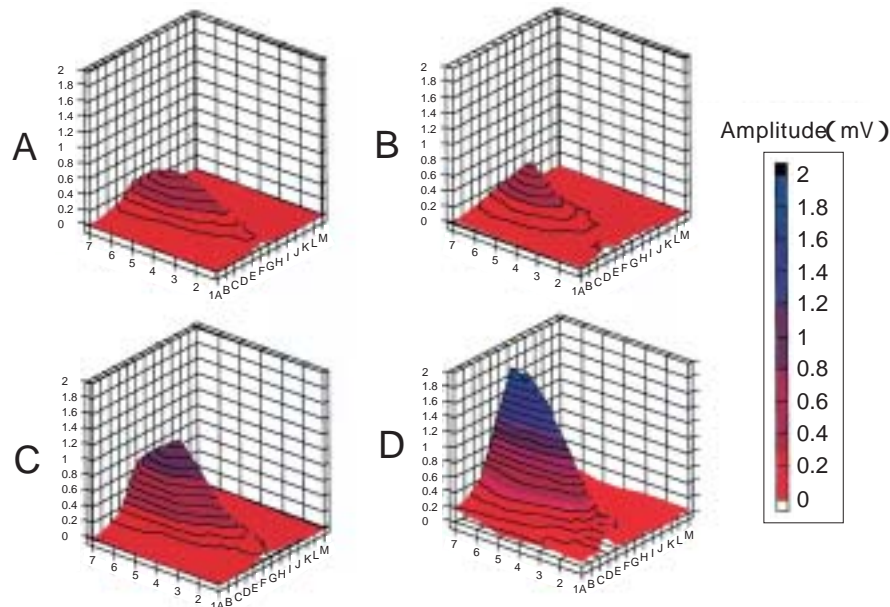
**Administration of Ic Antiarrhythmic Drugs.** Statistically significant differences between the 2 groups were observed in the degree of amplitude increase (post-pre / pre) caused by drug administration at J20, J40 and J60 ( $1.93 \pm 1.20$  vs.  $0.63 \pm 1.02$ ,  $2.00 \pm 1.00$  vs.  $0.56 \pm 0.89$ ,  $2.11 \pm 0.89$  vs.  $0.66 \pm 0.99$ , respectively).

Following the drug administration, ST elevation increased in extent and magnitude in both patient groups. However, the increased extent and magnitude were greater in symptomatic than asymptomatic Brugada syn-

drome, resulting in the higher and sharper peak on the 3D map, located at E5, for the symptomatic Brugada syndrome (Fig. 4). Fig. 4D shows that the blue area at the



**Fig. 3** Three-dimensional maps of the ST segment at J20. To visualize the spatial distribution of the ST elevation, a 3D map was constructed using potential mapping data. The Z-axis indicates the amplitude of the ST level, and the X and Y-axes indicate the recording sites. These 3D maps were produced by grouping data of potential mapping from the 2 groups (asymptomatic Brugada syndrome patients,  $n = 35$ ; Brugada syndrome patients,  $n = 7$ ). Patients with Brugada syndrome (B) have a higher peak at the median precordium than do patients with asymptomatic Brugada syndrome (A).



**Fig. 4** Three-dimensional maps of the ST segment at J20 before administration of an Ic antiarrhythmic drug (A, B) and after administration (C, D). The left traces (A, C) are data from patients with asymptomatic Brugada syndrome ( $n = 16$ ), and the right traces (B, D) are data from patients with Brugada syndrome ( $n = 5$ ). The post-administration 3D maps show that patients with Brugada syndrome have a higher peak at the median precordium than do patients with asymptomatic Brugada syndrome.

top of the 3D map was coincident with the RVOT area.

**Criteria for Differentiating Patients with Brugada Syndrome from Patients with Asymptomatic Brugada Syndrome.** From the results described above, we applied the following criteria for separating patients with Brugada syndrome from patients with asymptomatic Brugada syndrome: (1) patients with the coved-type ECG at E5 after Ic drug administration, and (2) patients with an amplitude at E5 > 1.5 mV after Ic drug administration, or (3) a degree of amplitude increase (post-pre / pre) at E5 of > 2.0. These criteria had a sensitivity of 100%, a specificity of 69%, a positive predictive value of 50%, and a negative predictive value of 100% (Table 2).

During a mean follow-up period of  $47 \pm 20$  months, an ICD was implanted due to VF in one of the 5 patients with asymptomatic Brugada syndrome who fully fulfilled these criteria. However, one asymptomatic Brugada syndrome patient with a family history of sudden death of unknown cause did not fulfill these criteria and had no syncopal episode due to VF during the follow-up period.

## Discussion

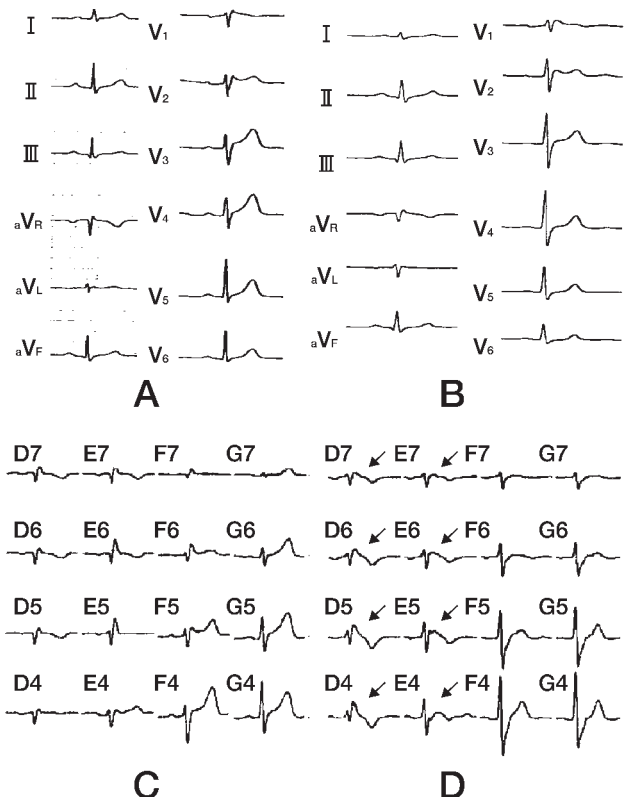
The characteristics of patients with Brugada syndrome are ST elevation in the right precordial leads (V1-V2) of the ECG and a past history of sudden cardiac death due to VF without structural heart disease. Treatment with antiarrhythmic drugs is not effective in preventing the occurrence of cardiac events in patients with Brugada syndrome. Thus, ICD implantation is usually used to treat patients with Brugada syndrome.

We have often observed Brugada syndrome-type characteristics in the ECGs of patients who have no Brugada syndrome symptoms and are considered to be healthy (Figs. 5A-B). Thus, it is necessary to identify those patients who have latent Brugada syndrome, and it

is important to predict whether cardiac events will occur in the future in patients with asymptomatic Brugada syndrome.

Recently, a molecular abnormality in the cardiac sodium channel gene, SCN5A, was reported to be the genetic basis of Brugada syndrome [7]. Following the publication of that report, relationships have been reported between Brugada syndrome and mutations of SCN5A [8-11]. Priori *et al.* described appropriate management strategies for patients showing Brugada-type ECGs based on the concept that this syndrome was a novel cardiac ion channel disease [3].

However, it is difficult to perform gene analysis in all patients showing Brugada-type ECGs. Thus, we attempted to differentiate the characteristics of ST elevation in patients with Brugada syndrome from those in



**Fig. 5** Twelve-lead ECG obtained under control conditions (A, B) and from 16-lead electrocardiograms (D-G, 4-7) selected from the 87-lead ECG (C, D). The left traces (A, C) are data from a patient with asymptomatic Brugada, and the right traces (B, D) are data from a patient with Brugada syndrome. Arrows indicate the remarkable differences in ST segment elevation in a patient with Brugada syndrome.

**Table 2** Comparison of results obtained on the basis of the new criteria

Results	Patients with Brugada syndrome	Patients with asymptomatic Brugada syndrome	Number
Positive	5	5	10
Negative	0	11	11
Number	5	16	21

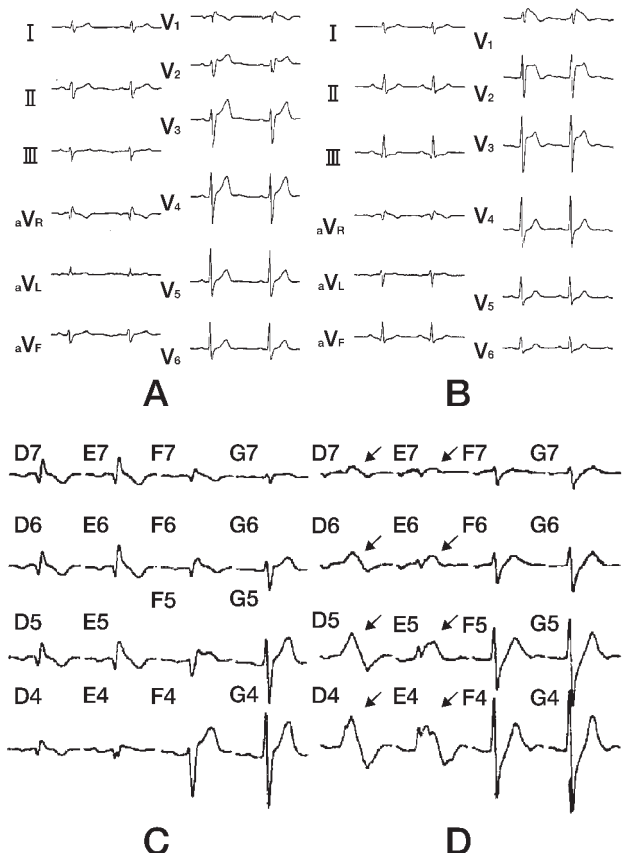
patients with asymptomatic Brugada syndrome by BSM before and after pharmacological challenge tests with pilsicainide.

BSM, which is a noninvasive and simple method, was superior to 12-lead ECG in demonstrating spatial distribution (Figs. 5C-D). BSM could therefore be a useful method for diagnosing Brugada syndrome. Di Diego *et al.* reported the possible mechanisms of the appearance of ST segment elevation only in the right precordial leads in patients with Brugada syndrome [12]. Shimizu *et al.* compared their findings in patients with Brugada syndrome with those in healthy subjects, and demonstrated using BSM that the location of the maximal amplitude in Brugada syndrome patients was in an area of the RVOT (D-G, 4-7) [5]. In the present study, we obtained similar results in comparison with patients with asymptomatic Brugada syndrome. Our results also showed that the maximum amplitude was located in a narrower region of the median precordium (E-F, 5-6) in patients with Brugada syndrome in comparison with Shimizu *et al.*'s recent results.

The results of challenge tests using Ic antiarrhythmic drugs have been reported to be helpful in the diagnosis of Brugada syndrome [13-17]. Our results showed that the administration of Ic antiarrhythmic drugs made it easier to differentiate patients with Brugada syndrome from those with asymptomatic Brugada syndrome (Figs. 6A-B). Even in cases in which it was difficult to differentiate the 2 groups using BSM under control conditions, differentiation by BSM was possible following the administration of Ic antiarrhythmic drugs (Figs. 6C-D).

We reported that the change in amplitude of the ST segment at lead V2, not lead V1, after drug administration was useful for differentiating asymptomatic Brugada syndrome patients with inducible VF from asymptomatic Brugada syndrome patients without inducible VF by programmed electrical stimulation [16]. E5 is located between V1 and V2, and above V1 and V2. E5 is also expected to reflect the potentials of the nearer RVOT. Thus, since the peak amplitude of ST elevation in symptomatic Brugada syndrome was located in a quite narrow area of the anterior chest observed in this study, the amplitude at E5 was more sensitive than that at V2 for evaluating abnormal electrical activity in RVOT. This higher sensitivity allowed us to separate the patients with symptomatic Brugada syndrome from those with asymptomatic Brugada syndrome using the criteria described above.

It is well known that the ECG in Brugada syndrome patients differs from day to day, and that the autonomic nervous system affects the modulation of ST segment elevation in Brugada syndrome patients [18-20]. However, each examination was performed only once in each patient. The patients in this study were also examined as a group, not individually. Thus, based only on our results, it is not possible to determine whether only BSM provides sufficient information for predicting the occurrence of future cardiac events in patients with asymptomatic Brugada syndrome. Follow-up and investigation using combinations of BSM with other examina-



**Fig. 6** Twelve-lead ECG (A, B) and 16-lead electrocardiograms after administration of an Ic antiarrhythmic drug (D-G, 4-7) (C, D). The left traces (A, C) are data from a patient with asymptomatic Brugada and the right traces (B, D) are data from a patient with Brugada syndrome. Administration of an Ic antiarrhythmic drug made it easier to differentiate a patient with Brugada syndrome from one with asymptomatic Brugada syndrome. Arrows indicate the remarkable changes in ST segment elevation after the administration of an Ic antiarrhythmic drug in a patient with Brugada syndrome.



tions are needed in order to further evaluate the reproducibility of these findings and the individual outcomes. However, it is possible that these methods might provide improved means of differentiating symptomatic and asymptomatic Brugada patients noninvasively.

In conclusion, BSM was useful for differentiating patients with Brugada syndrome from those with asymptomatic Brugada syndrome. The results of this study suggest that patients with Brugada syndrome had a higher elevation of the ST segment at the median precordium than patients with asymptomatic Brugada syndrome, and that differentiation of patients with Brugada syndrome from those with asymptomatic Brugada syndrome was easier if an Ic antiarrhythmic drug was administered. Evaluation of the amplitude of the ST segment at E5 and evaluation of the change in amplitude of the ST segment at E5 caused by Ic drug administration were also useful for differentiating symptomatic patients from asymptomatic Brugada syndrome patients.

## References

1. Brugada P and Brugada J: Right bundle branch block, persistent ST segment elevation and sudden cardiac death: A distinct clinical and electrocardiographic syndrome. A multicenter report. *J Am Coll Cardiol* (1992) 20: 1391-1396.
2. Brugada J, Brugada R, Antzelevitch C, Towbin J, Nademanee K and Brugada P: Long-term follow-up of individuals with the electrocardiographic pattern of right bundle-branch block and ST-segment elevation in precordial leads V1 to V3. *Circulation* (2002) 105: 73-78.
3. Priori SG, Napolitano C, Gasparini M, Pappone C, Della Bella P, Giordano U, Bloise R, Giustetto C, De Nardis R, Grillo M, Ronchetti E, Faggiano G and Nastoli J: Natural history of Brugada syndrome: Insights for risk stratification and management. *Circulation* (2002) 105: 1342-1347.
4. Takenaka S, Kusano KF, Hisamatsu K, Nagase S, Nakamura K, Morita H, Matsubara H, Emori T and Ohe T: Relatively benign clinical course in asymptomatic patients with brugada-type electrocardiogram without family history of sudden death. *J Cardiovasc Electrophysiol* (2001) 12: 2-6.
5. Shimizu W, Matsuo K, Takagi M, Tanabe Y, Aiba T, Taguchi A, Suyama K, Kurita T, Aihara N and Kamakura S: Body surface distribution and response to drugs of ST segment elevation in Brugada syndrome: Clinical implication of eighty-seven-lead body surface potential mapping and its application to twelve-lead electrocardiograms. *J Cardiovasc Electrophysiol* (2000) 11: 396-404.
6. Bruns HJ, Eckardt L, Vahlhaus C, Schulze-Bahr E, Haverkamp W, Borggrefe M, Breithardt G and Wichter T: Body surface potential mapping in patients with Brugada syndrome: Right precordial ST segment variations and reverse changes in left precordial leads. *Cardiovasc Res* (2002) 54: 58-66.
7. Chen Q, Kirsch GE, Zhang D, Brugada R, Brugada J, Brugada P, Potenza D, Moya A, Borggrefe M, Breithardt G, Ortiz-Lopez R, Wang Z, Antzelevitch C, O'Brien RE, Schulze-Bahr E, Keating MT, Towbin JA and Wang Q: Genetic basis and molecular mechanism for idiopathic ventricular fibrillation. *Nature* (1998) 392: 293-296.
8. Bezzina C, Veldkamp MW, van Den Berg MP, Postma AV, Rook MB, Viersma JW, van Langen IM, Tan-Sindhunata G, Bink-Boelkens MT, van Der Hout AH, Mannens MM and Wilde AA: A single Na<sup>+</sup> channel mutation causing both long-QT and Brugada syndromes. *Circ Res* (1999) 85: 1206-1213.
9. Deschenes I, Baroudi G, Berthet M, Barde I, Chalvidan T, Denjoy I, Guicheney P and Chahine M: Electrophysiological characterization of SCN5A mutations causing long QT (E1784K) and Brugada (R1512W and R1432G) syndromes. *Cardiovasc Res* (2000) 46: 55-65.
10. Rook MB, Bezzina Alshinawi C, Groenewegen WA, van Gelder IC, van Ginneken AC, Jongsma HJ, Mannens MM and Wilde AA: Human SCN5A gene mutations alter cardiac sodium channel kinetics and are associated with the Brugada syndrome. *Cardiovasc Res* (1999) 44: 507-517.
11. Roden DM and Wilde AA: Drug-induced J point elevation: A marker for genetic risk of sudden death or ECG curiosity? *J Cardiovasc Electrophysiol* (1999) 10: 219-223.
12. Di Diego JM, Sun ZQ and Antzelevitch C: I<sub>to</sub> and action potential notch are smaller in left vs. right canine ventricular epicardium. *Am J Physiol* (1996) 271: H548-561.
13. Priori SG, Napolitano C, Schwartz PJ, Bloise R, Crotti L and Ronchetti E: The elusive link between LQT3 and Brugada syndrome: The role of flecainide challenge. *Circulation* (2000) 102: 945-947.
14. Fujiki A, Usui M, Nagasawa H, Mizumaki K, Hayashi H and Inoue H: ST segment elevation in the right precordial leads induced with class IC antiarrhythmic drugs: Insight into the mechanism of Brugada syndrome. *J Cardiovasc Electrophysiol* (1999) 10: 214-218.
15. Krishnan SC and Josephson ME: ST segment elevation induced by class IC antiarrhythmic agents: Underlying electrophysiologic mechanisms and insights into drug-induced proarrhythmia. *J Cardiovasc Electrophysiol* (1998) 9: 1167-1172.
16. Morita H, Takenaka-Morita S, Fukushima-Kusano K, Kobayashi M, Nagase S, Kakishita M, Nakamura K, Emori T, Matsubara H and Ohe T: Risk stratification for asymptomatic patients with Brugada syndrome. *Circ J* (2003) 67: 312-316.
17. Nagase S, Kusano KF, Morita H, Fujimoto Y, Kakishita M, Nakamura K, Emori T, Matsubara H and Ohe T: Epicardial electrogram of the right ventricular outflow tract in patients with the Brugada syndrome. Using the epicardial lead. *J Am Coll Cardiol* (2002) 39: 1992-1995.
18. Miyazaki T, Mitamura H, Miyoshi S, Soejima K, Aizawa Y and Ogawa S: Autonomic and antiarrhythmic drug modulation of ST segment elevation in patients with Brugada syndrome. *J Am Coll Cardiol* (1996) 27: 1061-1070.
19. Kasanuki H, Ohnishi S, Ohtuka M, Matsuda N, Nirei T, Isogai R, Shoda M, Toyoshima Y and Hosoda S: Idiopathic ventricular fibrillation induced with vagal activity in patients without obvious heart disease. *Circulation* (1997) 95: 2277-2285.
20. Brugada J and Brugada P: Further characterization of the syndrome of right bundle branch block, ST segment elevation, and sudden cardiac death. *J Cardiovasc Electrophysiol* (1997) 8: 325-331.