

# *Acta Medica Okayama*

---

*Volume 55, Issue 5*

2001

*Article 1*

NOVEMBER 2001

---

## Comparative studies of MRI and operative findings in rotator cuff tear.

Seigo Yamakawa\*      Hiroyuki Hashizume<sup>†</sup>      Norikazu Ichikawa<sup>‡</sup>  
Eichi Itadera\*\*      Hajime Inoue<sup>††</sup>

\*Kochi Prefectural Aki Hospital,

<sup>†</sup>Okayama University,

<sup>‡</sup>Kochi Prefectural Aki Hospital,

\*\*Kochi Prefectural Aki Hospital,

<sup>††</sup>Okayama University,

# Comparative studies of MRI and operative findings in rotator cuff tear.\*

Seigo Yamakawa, Hiroyuki Hashizume, Norikazu Ichikawa, Eichi Itadera, and Hajime Inoue

## Abstract

A prospective study was performed to determine the accuracy of magnetic resonance imaging (MRI) compared with operative findings in the evaluation of patients associated with rotator cuff tears. Fifty-four of 60 shoulders (58 patients) examined by MRI were confirmed as full-thickness tears and 6 as partial-thickness tears at the time of surgery. The oblique coronal, oblique sagittal, and axial planes of T2-weighted images with the 0.5 tesla MRI system were obtained preoperatively and compared with operative findings. MRI correctly identified 46 of 54 full-thickness rotator cuff tears and 5 of 6 partial-thickness tears. A comparison of MRI and operative findings in full-thickness cuff tears showed a sensitivity of 85%, a specificity of 83%, and a positive prospective value (PPV) of 99%. A comparison of partial-thickness tears showed a sensitivity of 83%, a specificity of 85%, and PPV of 39%. Linear regression analysis showed an excellent correlation between the MRI assessment and measurement at the time of surgery ( $r = 0.90$ ,  $P < 0.01$ ). MRI was useful in evaluating large and medium-sized rotator cuff tears, but less useful in distinguishing small full-thickness tears from partial-thickness tears.

**KEYWORDS:** rotator cuff tear, magnetic resonance imaging, diagnosis

---

\*PMID: 11688948 [PubMed - indexed for MEDLINE]

Copyright (C) OKAYAMA UNIVERSITY MEDICAL SCHOOL

Original Article

## Comparative Studies of MRI and Operative Findings in Rotator Cuff Tear

Seigo Yamakawa<sup>a\*</sup>, Hiroyuki Hashizume<sup>b</sup>, Norikazu Ichikawa<sup>a</sup>,  
Eichi Itadera<sup>a</sup>, and Hajime Inoue<sup>b</sup>

<sup>a</sup>Department of Orthopaedic Surgery, Kochi Prefectural Aki Hospital, Kochi 784-0027, Japan, and

<sup>b</sup>Department of Orthopaedic Surgery, Okayama University Medical School,  
Okayama 700-8558, Japan

A prospective study was performed to determine the accuracy of magnetic resonance imaging (MRI) compared with operative findings in the evaluation of patients associated with rotator cuff tears. Fifty-four of 60 shoulders (58 patients) examined by MRI were confirmed as full-thickness tears and 6 as partial-thickness tears at the time of surgery. The oblique coronal, oblique sagittal, and axial planes of T2-weighted images with the 0.5 tesla MRI system were obtained preoperatively and compared with operative findings. MRI correctly identified 46 of 54 full-thickness rotator cuff tears and 5 of 6 partial-thickness tears. A comparison of MRI and operative findings in full-thickness cuff tears showed a sensitivity of 85%, a specificity of 83%, and a positive prospective value (PPV) of 99%. A comparison of partial-thickness tears showed a sensitivity of 83%, a specificity of 85%, and PPV of 39%. Linear regression analysis showed an excellent correlation between the MRI assessment and measurement at the time of surgery ( $r = 0.90$ ,  $P < 0.01$ ). MRI was useful in evaluating large and medium-sized rotator cuff tears, but less useful in distinguishing small full-thickness tears from partial-thickness tears.

**Key words:** rotator cuff tear, magnetic resonance imaging, diagnosis

**S**houlder pain is one of the most frequent complaints made to physicians, and a disorder of the rotator cuff is one of the most common etiologies.

Arthrography has been considered to be an accurate imaging technique for demonstrating full-thickness tears of the rotator cuff. It has the disadvantage, however, of being invasive and insensitive to partial-thickness tears involving the bursal side or the intratendinous portion of the cuff.

Ultrasonography, a noninvasive tool, has an accuracy similar to that of arthrography for the diagnosis of the

rotator cuff tears. However, it is an operator-dependent technique that does not allow for full visualization of the rotator cuff.

Magnetic resonance imaging (MRI) has become a primary diagnostic method in evaluation of the shoulder by virtue of its superior soft-tissue contrast, non invasive nature, and ability to outline structure in multiple planes [1, 2]. However there have been few reports comparing MRI findings with operative findings. The purpose of this study is to evaluate the efficacy of MRI in the diagnosis of rotator cuff tears.

### Materials and Methods

This study included 60 shoulders of 58 patients who

Received March 21, 2000; accepted February 23, 2001.

\*Corresponding author. Phone: +81-888-44-1921; Fax: +81-888-44-4478

underwent MRI of the shoulder and subsequent surgery. MRI were obtained for 28 right and 32 left shoulders. The 43 men and 15 women ranged in age from 40 to 80 years (mean age, 57 years). All patients were preoperatively evaluated by means of MRI and arthrography of the affected shoulder after failure of a trial of conservative treatment for shoulder pain or dysfunction.

Of the 60 shoulders, 54 were confirmed full-thickness rotator cuff tears, 6 were partial thickness tears that included 4 bursal-side tears, 2 joint-side tears, and no intratendinous tears at surgery. Fifteen additional patients were included as a normal control group. They consisted of 6 frozen shoulders, 3 recurrent dislocations of the shoulder, 3 ruptures of the long head of the biceps tendon, and 3 fractures of the glenoid rim. All of these patients also underwent preoperative MRI studies, which resulted in no abnormal findings in the rotator cuff, as was also surgically demonstrated.

MRI examinations were performed on an MRVectra 0.5-tesla (Yokogawa Medical Ltd. Co. Tokyo Japan) with surface coils. Patients were examined in the supine position with the relevant arm in neutral rotation. Imaging was performed in the oblique coronal, oblique sagittal, and axial planes for all patients. The parameters for T2-weighted images were as follows: the repetition time (TR) was 3,000 msec, the echo time (TE) was 100 msec, the thickness was 5 mm, the section gap was 1 mm, and the matrix size was  $224 \times 160$ . The field of view was 200 mm, and the average number of signals was four.

A full-thickness tear of the rotator cuff was diagnosed if the MRI demonstrated a full-thickness defect with signal intensity on T2-weighted images comparable to the signal intensity of the fluid, or a complete discontinuity of the cuff on one or more sections. A partial-thickness tear was diagnosed if there was partial high intensity for the rotator cuff or if there was slight increase in signal intensity in the cuff without a definite defect. When a full-thickness tear was diagnosed, the size of the tear was measured in both the mediolateral and anteroposterior directions.

At surgery, direct measurements were made of the anteroposterior and mediolateral dimensions of all patients with full-thickness rotator cuff tears. All measurements were made before any rotator cuff debridement. The sizes of the torn cuffs as assessed by MR imaging, were compared with those determined at surgery. Complete rotator cuff tears were defined by Post as small ( $< 1$  cm), medium-sized (1–3 cm), large (3–5 cm), and massive

( $> 5$  cm) [3].

Effusion of the subacromial bursa and glenohumeral joint was assessed in the oblique coronal plane or in the axial plane on T2-weighted images.

Arthrography was performed preoperatively in all cases by the single positive contrast method.

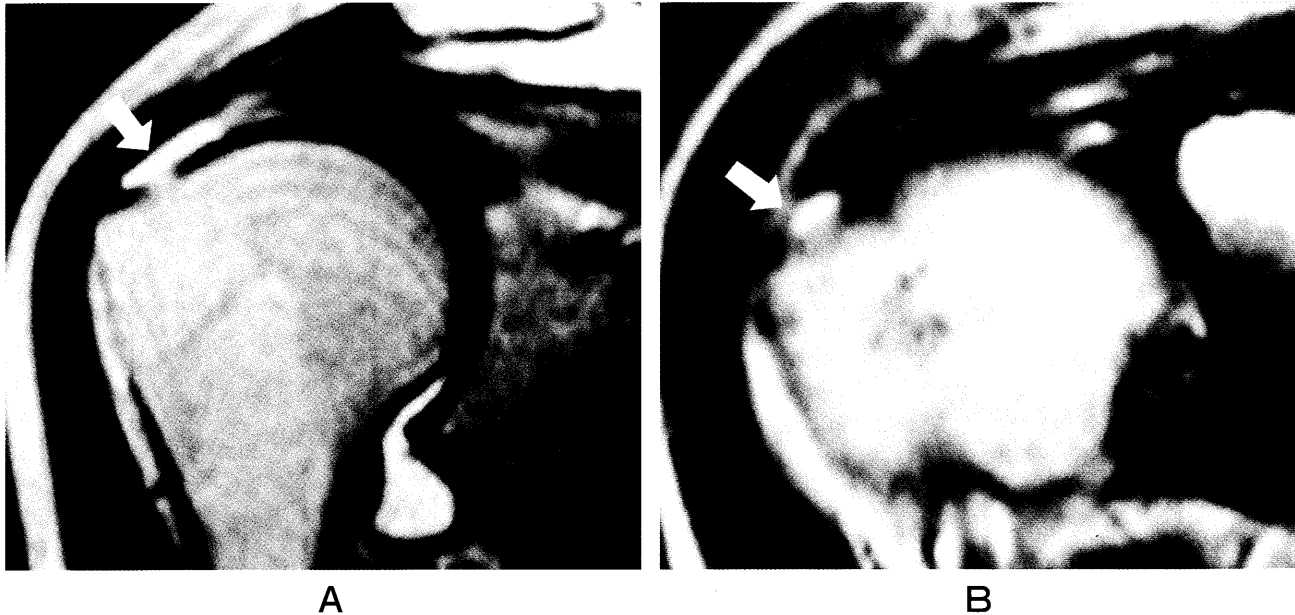
The MRI were reviewed by the author alone, and the examiner was blinded to clinical history as well as arthrographic and surgical results.

**Statistical Analysis.** Sensitivity is calculated by dividing the number of true-positive results by the total number of true-positive and false-negative results. Specificity is calculated by dividing the number of true-negative results by the total number of true-negative and false-positive results. Accuracy is calculated by dividing the total number of true-positive and true-negative results by the total number of shoulders examined. The positive predictive value (PPV) was calculated by dividing the total number of true-positive results by the total number of true-positive and false-positive results. The Mann-Whitney *U* test was performed to explore the association between the presence of positive MR finding of effusion and the presence of a full-thickness tear at surgery.

## Results

In the 60 shoulders, MR imaging correctly identified 46 of 54 full-thickness rotator cuff tears proved surgically. In addition, 5 of 6 partial-thickness tears proved surgically were correctly diagnosed on MRI (Fig. 1). All cases in the control group were correctly diagnosed as having no cuff tear (Table 1). In the diagnosis of full-thickness tears of the rotator cuff, sensitivity was 88%, specificity was 95%, accuracy was 88%, and PPV was 98%. In the case of a partial-thickness tear, sensitivity was 83%, specificity was 88%, accuracy was 88%, and PPV was 38% (Table 2). Eight full-thickness tears proved surgically were misidentified as partial-thickness tears by MRI, with the sizes of all of these being confirmed as less than 1 cm at surgery (Fig. 2). One partial-thickness tear proved surgically was missed entirely by MRI (Fig. 3).

A linear regression analysis showed an excellent correlation for the size of the tears between MR imaging and surgical findings ( $r = 0.90$ ,  $P < 0.01$ ) (Fig. 4). In the case of full-thickness rotator cuff tears, fluid of the subacromial bursa and glenohumeral joints had increased both their frequency and volume in proportion to the size



**Fig. 1** (A) Full-thickness rotator cuff tear. Oblique coronal T2-weighted image. A medium-sized full-thickness tear is delineated by a high signal discontinuity in the rotator cuff (arrow). (B) Partial-thickness rotator cuff tear. Oblique coronal T2-weighted image. High signal fluid fills the partial rotator cuff tear on the bursal side of the supraspinatus tendon (arrow).

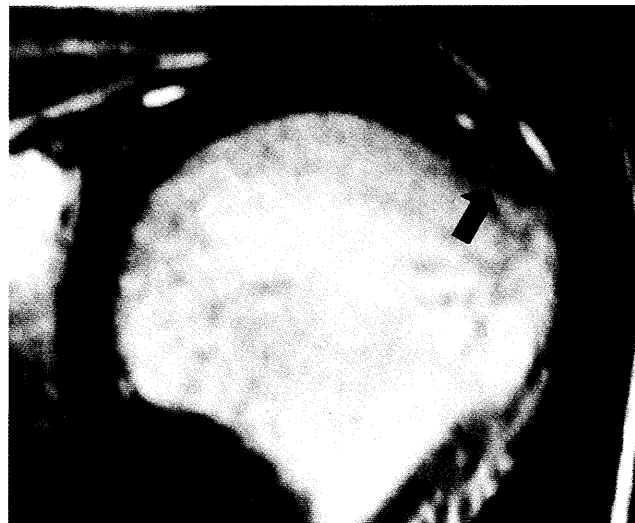
**Table 1** Comparison of MRI and surgical findings

		Operative Findings		
		Full-thickness	Partial	No tear
MRI Findings	Full-thickness	46	1	0
	Partial	8	5	0
	No tear	0	0	15

Numbers refer to the number of shoulders.

**Table 2** Accuracy of MRI in the detection of rotator cuff tears

	Full-thickness	Partial-thickness
Sensitivity	0.88	0.83
Specificity	0.95	0.88
Accuracy	0.88	0.88
PPV	0.98	0.38



**Fig. 2** Full-thickness rotator cuff tear. Oblique coronal T2-weighted image. The image shows an increased signal intensity that is less than the full-thickness of the tendon (arrow), but this case was confirmed to be a small (1 × 1 cm) full-thickness tear at surgery.

of the tear ( $P < 0.01$ ) (Table 3).

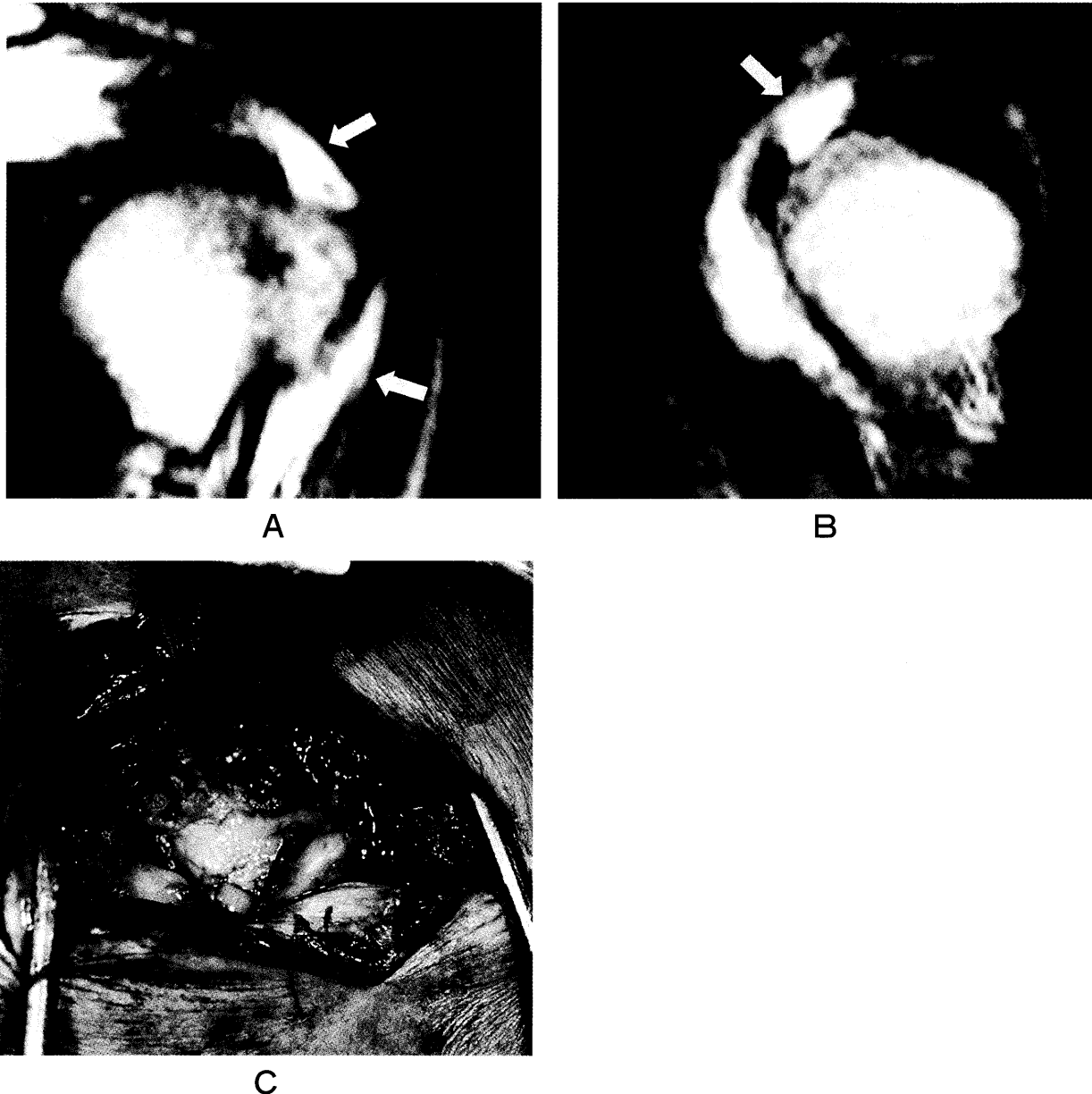
Three isolated ruptures of the subscapularis tendon were included in this series, all of them which be diagnosed preoperatively by MRI [4].

Arthrography was performed in all cases. All 54 full-thickness tears and 2 joint side tears were correctly

diagnosed preoperatively by arthrography.

### Discussion

Previous studies have shown that MRI is reliable in the detection of rotator cuff tears [5-14]. Our study,



**Fig. 3** Partial-thickness tear. Oblique coronal (A) and sagittal (B) T2-weighted image shows full-thickness discontinuity of the supraspinatus tendon (arrows), but this case was confirmed to be a bursal side tear at surgery. (C) This case was a bursal-side tear with a large amount of subacromial effusion, and the torn cuff was penetrated more than half way through the depth of the tendon.

however, showed that it is difficult to accurately distinguish between small full-thickness tears and partial-thickness tears.

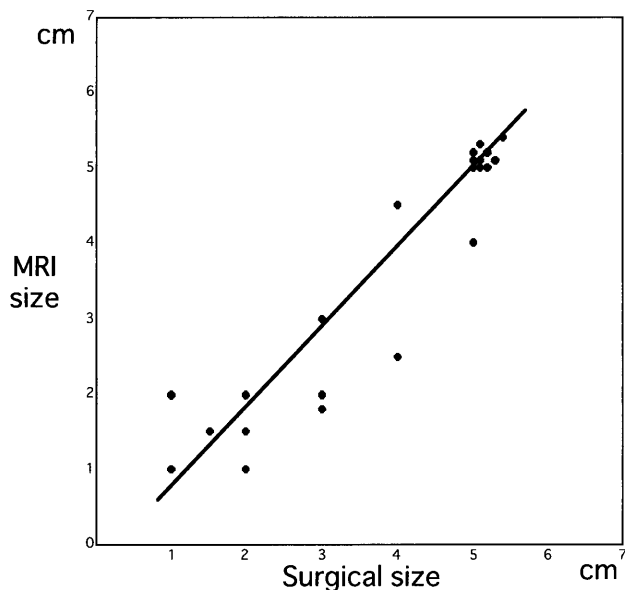
The exact cause of pain in the shoulder is often difficult to identify, thus the ongoing search for more accurate non-invasive methods of identification of the etiology of such pain. Diagnostic imaging using arthrography, ultrasonography, and MRI is an important part of the evaluation of patients with shoulder pain [15].

Arthrography and computerized tomographic arthrography have provided direct evidence of full-thickness tears and joint side tears, also making it possible to visualize abnormalities of the glenoid labrum and irregularities of the articular cartilage [16]. Mink *et al.* [17] have

reported 99% accuracy in the diagnosis of tears in 152 surgically proved cases. Arthrography is a highly accurate method of detecting rotator cuff tears against which the other newer techniques must be compared by arthrography. Arthrography is well-established and simple to perform, but this technique is still invasive, has a high rate of delayed morbidity, and is time-consuming [18].

Ultrasonography is an operator-dependent technique that has been shown by a few experienced examiners to be almost as accurate as arthrography in the detection of rotator cuff tears. It is non-invasive, but requires a significant learning curve to obtain adequate results. Mack *et al.* [19] have reported an accuracy of 94% in 47 surgically proved cases, and Middleton *et al.* [20] have reported an accuracy of 87% in 39 arthrographically proved cases. Unfortunately, these results have been difficult for other examiners to reproduce. Large tears are relatively easily detected due to their marked asymmetry when compared with the contralateral side. However, small or partial-thickness tears in which a defect in the cuff cannot be shown may be missed because of the limited contrast resolution of the technique.

MRI has considerable potential for the evaluation of rotator cuff disease, due to its ability to directly image the entire cuff in a noninvasive fashion. Evanco *et al.* [6] have compared the results of MRI in 31 patients with those of arthroscopy in 19 patients and arthrography in 12, reporting a sensitivity and specificity of 0.80 and 0.94



**Fig. 4** Linear regression plot of the size of the ruptured cuff at MR imaging versus that found at surgery in the mediolateral dimension. ( $r = 0.90$ ,  $P < 0.01$ ).

**Table 3** Evaluation of effusion in the subacromial bursa

		*	
		Effusion (+)	Effusion (-)
Size of Tear	Large	22	6
	Medium-sized	6	5
	Small	5	8

\* $P < 0.01$ , compared to the values for effusion (+) and effusion (-) by Mann-Whitney *U* test.

**Table 4** Comparison of MRI and Arthrography

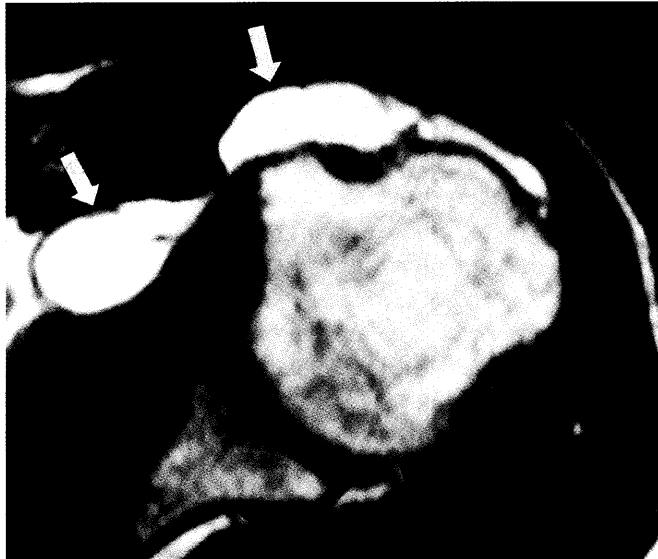	MRI		Operation		Arthrography
1	Partial (P)	≠	Full-thickness (F)	=	Leak (+)
2	P	≠	F	=	(+)
3	P	≠	F	=	(+)
4	P	≠	F	=	(+)
5	P	≠	F	=	(+)
6	P	≠	F	=	(+)
7	P	≠	F	=	(+)
8	P	≠	F	=	(+)
9	F	≠	P		(-)*
10	P	=	P		(-)
11	P	=	P		(-)
12	P	=	P		(-)
13	P	=	P	=	(-)**
14	P	=	P	=	(-)**

Small full-thickness tears (less than 1 cm) and all partial thickness tears were selected.

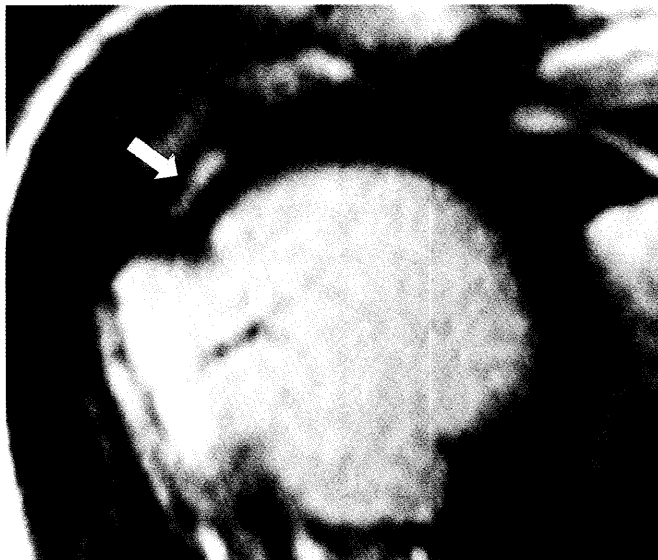\*, bursal side tear; \*\*, joint side tear; =, equal; ≠, not equal.

for full-thickness tears and 0.69 and 0.94 for all tears (partial and full-thickness tears). Zlatkin *et al.* [7] have reported an MR imaging sensitivity and specificity of 0.91 and 0.88 in 40 arthrographically and surgically proved cases, and Burk *et al.* [8] have reported a sensitivity and specificity of 0.88 and 1.00 in 16 surgically proved

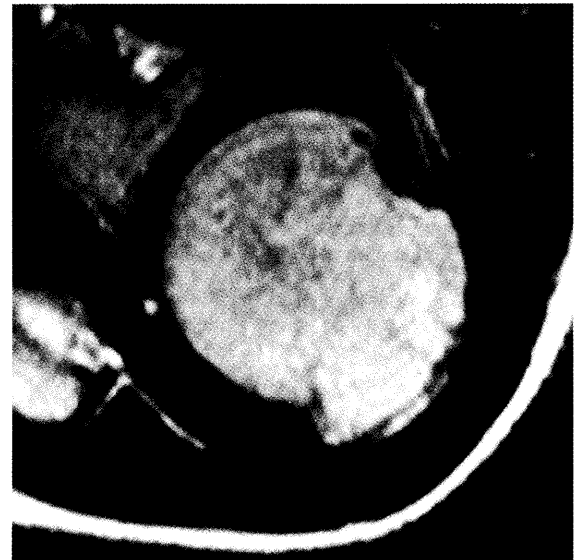cases. Iannotti *et al.* [9] have reported a sensitivity and specificity of 0.88 and 1.00 in 16 surgically proved cases, while Rafii *et al.* [10] have reported a sensitivity and specificity of 0.97 and 0.94 in 16 surgically proved cases. Farley *et al.* [11] have reported a sensitivity and specificity of 0.70 and 0.96 in 112 arthroscopically and



A



B



C

**Fig. 5** (A) Case 1. Axial T2-weighted image of a bursal-side tear. This is the same case as that shown in Fig. 3. A large amount of fluid is seen in the subacromial bursa (arrows). (B) Case 2. Joint-side tear. Oblique coronal T2-weighted image shows a high signal intensity in the distal aspect of the supraspinatus tendon extending from the joint surface (arrow). (C) Case 2. Axial T2-weighted image shows no fluid in either the subacromial bursa or the glenohumeral joint.



surgically proved cases, and they have also reported a sensitivity and specificity for small tears (less than 2 cm) of 0.40 and 0.96. The fat-suppression technique has several theoretical advantages over non-fat suppressed imaging, and several studies have demonstrated the usefulness of this technique [12-14], with Reinus *et al.* [13] reporting a sensitivity and specificity of 1.00 and 0.87, and Quinn *et al.* [14] a sensitivity and specificity of 0.84 and 0.97 by means of a fat suppression technique.

These studies have shown high sensitivity and specificity in detection of full-thickness tears of the rotator cuff, and our study showed comparable results with a sensitivity of 0.88 and a specificity of 0.95. Our data, however, also showed markedly poor detection of small full-thickness (less than 1 cm) tears and partial-thickness tears.

In our study, all 8 full-thickness tears diagnosed by MRI as partial-thickness tears were less than 1 cm, and only 2 of 10 small full-thickness tears (less than 1 cm) proved surgically were correctly diagnosed preoperatively by MRI. All, however, were diagnosed preoperatively as full-thickness tears by arthrography because of extravasation into the subacromial space (Table 4). MRI is decidedly not as accurate for small full-thickness tears and partial-thickness tears. Although there are few studies in which all cases have preoperatively undergone both arthrography and MRI examination, our present results indicate that MRI is more valuable in the diagnosis of small full-thickness tear and partial-thickness tears in combination with arthrography.

In all 4 partial-thickness tears of the bursal side, a significant amount of fluid was detected in the subacromial bursa without any intraarticular effusion. In contrast, there was no fluid in the subacromial bursa in any joint side tears (Fig. 5). These differences may be helpful in diagnosing partial-thickness rotator cuff tears with partial defects at MRI.

Our results revealed a high sensitivity and specificity of MRI in the diagnosis of rotator cuff tears. There are, however, some limitations to this study. The patients were not fully representative of the spectrum of those with suspected rotator cuff tears. Rather, the patients represented only a group having symptoms or disabilities requiring surgery. In addition, our 15 control subjects made up a small and not age-matched group. Therefore, the efficacy of MRI must be confirmed in a larger study including a broader population of patients with a larger, age-matched control group.

MRI was found to provide very useful preoperative information regarding full-thickness rotator cuff tears. The size and extent of torn cuffs could also be depicted. However, it was difficult to distinguish small (less than 1 cm) full-thickness tears from partial-thickness tears.

## References

1. Recht MP and Resnick D: Magnetic resonance-imaging studies of the shoulder. Diagnosis of lesions of the rotator cuff. *J Bone Joint Surg Am* (1993) **75**, 1244-1253.
2. Zlatkin MB and Falchok FS: Magnetic resonance pathology of the rotator cuff. *Top Magn Reson Imaging* (1994) **6**, 94-120.
3. Post M, Silver R and Singh M: Rotator cuff tear. Diagnosis and treatment. *Clin Orthop* (1983) **173**, 78-91.
4. Gerber C, Hersche O and Farron A: Isolated rupture of the subscapularis tendon. *J Bone Joint Surg Am* (1996) **78**, 1015-1023.
5. Kneeland JB, Middleton WD, Carrera GF, Zeuge RC, Jesmanowicz A, Froncisz W and Hyde JS: MR imaging of the shoulder: Diagnosis of rotator cuff tears. *AJR* (1987) **149**, 333-337.
6. Evancho AM, Stiles RG, Fajman WA, Flower SP, Macha T, Brunner MC and Levy DW: MR imaging diagnosis of rotator cuff tears. *AJR* (1988) **151**, 751-754.
7. Zlatkin MB, Iannotti JP, Roberts MC, Esterhai JL, Dalinka MK, Kressel HY, Schwartz JS and Lenkinski RE: Rotator cuff tears: Diagnostic performance of MR imaging. *Radiology* (1989) **172**, 223-229.
8. Burk DL Jr, Karasick D, Kurtz AB, Mitchell DG, Rifkin MD, Miller CL, Levy DW, Fenlin JM and Bartolozzi AR: Rotator cuff tears: Prospective comparison of MR imaging with arthrography, sonography, and surgery. *AJR* (1989) **153**, 87-92.
9. Iannotti JP, Zlatkin MB, Esterhai JL, Kressel HY, Dalinka MK and Spindler KP: Magnetic resonance imaging of the shoulder: Sensitivity, specificity and predictive value. *J Bone Joint Surg Am* (1991) **73**, 17-29.
10. Rafii M, Firooznia H, Sherman O, Minkoff J, Weinreb J, Golimbu C, Gidumal R, Schinella R and Zaslav K: Rotator cuff lesions: Signal Patterns at MR imaging. *Radiology* (1990) **177**, 817-823.
11. Farley TE, Neumann CH, Steinbach LS, Jahnke AJ and Petersen SS: Full-thickness tears of the rotator cuff of the shoulder: Diagnosis with MR imaging. *AJR* (1992) **158**, 347-351.
12. Mirowitz SA: Normal rotator cuff: MR imaging with conventional and fat-suppression techniques. *Radiology* (1991) **180**, 735-740.
13. Reinus WR, Shady KL, Mirowitz SA and Totty WG: MR diagnosis of rotator cuff tears of the shoulder: Value of using T2-weighted fat-saturated images. *AJR* (1995) **164**, 1451-1455.
14. Quinn SF, Sheley RC, Demlow TA and Szumowski J: Rotator cuff tendon tears: Evaluation with fat-suppressed MR imaging with arthroscopic correlation in 100 patients. *Radiology* (1995) **195**, 497-500.
15. Nelson MC, Leather GP, Nirschl RP, Petrone FA and Freedman MT: Evaluation of the painful shoulder. A prospective comparison of magnetic resonance imaging, computerized tomographic arthrography, ultrasonography, and operative findings. *J Bone Joint Surg Am* (1991) **73**, 707-716.
16. Deutsch AL, Resnick D, Mink JH, Berman JL, Cone RO III, Resnik CS, Danzig L and Guerra J Jr: Computed and conventional arthrography of the glenohumeral joint: Normal anatomy and clinical experience. *Radiology* (1984) **153**, 603-609.
17. Hall FM, Rosenthal DI, Goldberg RP and Wyshak G: Morbidity from shoulder arthrography: Etiology, incidence, and prevention. *AJR* (1981)

- 136, 59-62.
18. Mink JH, Harris E and Rappaport M: Rotator cuff tears: Evaluation using double-contrast shoulder arthrography. *Radiology* (1985) **157**, 621-623.
  19. Mack LA, Matsen FA IIIrd, Kilcoyne RF, Davies PK and Sickler ME: US evaluation of the rotator cuff. *Radiology* (1985) **157**, 205-209.
  20. Middleton WD, Reinus WR, Totty WG, Melson CL and Murphy WA: Ultrasonographic evaluation of the rotator cuff and biceps tendon. *J Bone Joint Surg Am* (1986) **68**, 440-450.