

# *Acta Medica Okayama*

---

*Volume 46, Issue 6*

1992

*Article 7*

DECEMBER 1992

---

## Kimura's disease: clinical, histological and immunohistochemical studies.

Makoto Motoi\*

Syariffudin Wahid†

Yasushi Horie‡

Tadaatsu Akagi\*\*

\*Tottori University,

†Hasanuddin University,

‡Tottori University,

\*\*Okayama University,

# Kimura's disease: clinical, histological and immunohistochemical studies.\*

Makoto Motoi, Syariffudin Wahid, Yasushi Horie, and Tadaatsu Akagi

## Abstract

In the present study, 14 cases of Kimura's disease were clinicopathologically studied. The disease occurred at ages ranging from 5 to 75 years. The average age was 37.8 years. Sexes were about equally affected. The most common sites were the subcutis of head and neck, and parotid gland. Simultaneous involvement of lymph nodes occurred in 5 cases. Laboratory findings revealed eosinophilia in almost all the patients, but serum IgE levels were not elevated in 2 patients. Lesions were surgically removed and the clinical course thereafter was favorable for all but one case. Histologically, lesions were characterized by lymphoid follicles, granulation tissue with infiltration by many eosinophils, lymphocytes, plasma cells, mast cells and histiocytes, proliferation of blood vessels and fibrosis. Immunohistochemically, IgE reacted strongly in germinal centers, showing a reticular pattern. IgG-, IgA- and lysozyme-positive cells were scattered mainly in interfollicular granulomatous areas. Pathogenesis of this disease is briefly discussed.

**KEYWORDS:** Kimura's disease, clinicopathology, immunohistochemistry

---

\*PMID: 1485539 [PubMed - indexed for MEDLINE]

Copyright (C) OKAYAMA UNIVERSITY MEDICAL SCHOOL

## Kimura's Disease: Clinical, Histological and Immunohistochemical Studies

Makoto Motoi\*, Syariffudin Wahid<sup>a</sup>, Yasushi Horie<sup>b</sup> and Tadaatsu Akagi<sup>c</sup>

*Department of Pathology, Tottori University School of Medicine, Yonago 683, <sup>a</sup>Department of Pathology, Faculty of Medicine, Hasanuddin University, Ujung Pandang, Indonesia, <sup>b</sup>Department of Clinical Laboratory Medicine, Tottori University School of Medicine, Yonago 683 and <sup>c</sup>Department of Pathology, Okayama University Medical School, Okayama 700, Japan*

In the present study, 14 cases of Kimura's disease were clinicopathologically studied. The disease occurred at ages ranging from 5 to 75 years. The average age was 37.8 years. Sexes were about equally affected. The most common sites were the subcutis of head and neck, and parotid gland. Simultaneous involvement of lymph nodes occurred in 5 cases. Laboratory findings revealed eosinophilia in almost all the patients, but serum IgE levels were not elevated in 2 patients. Lesions were surgically removed and the clinical course thereafter was favorable for all but one case. Histologically, lesions were characterized by lymphoid follicles, granulation tissue with infiltration by many eosinophils, lymphocytes, plasma cells, mast cells and histiocytes, proliferation of blood vessels and fibrosis. Immunohistochemically, IgE reacted strongly in germinal centers, showing a reticular pattern. IgG-, IgA- and lysozyme-positive cells were scattered mainly in interfollicular granulomatous areas. Pathogenesis of this disease is briefly discussed.

**Key words :** Kimura's disease, clinicopathology, immunohistochemistry

In 1948, Kimura *et al.* first described some peculiar subcutaneous nodules in a paper (1). Since then, what appeared to be nearly identical disease processes were reported mainly in Asian and, rarely, in Western countries under different terminologies, *i. e.*, eosinophilic lymphadenitis and eosinophilic lymphoid granuloma (2), lymphoid hyperplasia with eosinophilia (3), eosinophilic lymphomatosis (4), angiolymphoid hyperplasia with eosinophilia (ALHE) (5-8), pseudo or atypic pyogenic granuloma (9), papular angioplasia (10), angioblastic lymphoid hyperplasia

with eosinophilia (11), eosinophilic lymphofollicular granuloma (12, 13), histiocytoid hemangioma (14) and eosinophilic lymphofolliculoid granuloma (15). In 1959, Iizuka (2) advocated that the disease should be named as Kimura's disease in honor of the first reporter of the disease. Thereafter, the disease was widely designated as Kimura's disease in Japan and as ALHE (Kimura's disease) in Western countries.

Patients usually present tumor-like nodules of the subcutis of head and neck or of the salivary gland in young adults, often associated with regional lymphadenopathy (15). Histologically, the nodule is characterized by lymphoid follicles

\* To whom correspondence should be addressed.

and by granulation tissue with infiltration of eosinophils, lymphocytes, mast cells, plasma cells and histiocytes, and vascular proliferation (15).

The etiology of Kimura's disease is not well-understood, although some allergic disorder is suspected. The nature of this disease is supposed to be an inflammatory or a reactive process rather than a neoplastic one. We have examined the cases of 14 patients with typical Kimura's disease clinically, histologically and immunohistochemically in an attempt to further characterize pathologic features.

### Subjects and Methods

The cases examined were of 14 patients whose specimens had been submitted for pathological diagnosis to the Second Department of Pathology, Okayama University Medical School, from 1978 to 1985. All the clinical data were obtained from clinicians who sent the materials to us.

Tumors and involved lymph nodes obtained from biopsy or surgically removed materials were fixed in 10% formalin, embedded in paraffin and stained with hematoxylin-eosin, Giemsa stain and silver impregnation.

The immunohistochemical study was carried out for IgG, IgA, IgM, IgD, IgE, lysozyme and C<sub>3</sub> with the peroxidase antiperoxidase (PAP) method on paraffin sections (16). Sections were deparaffinized, and trypsinized by a solution containing 0.1% trypsin and 0.1% CaCl<sub>2</sub> (17). Endogenous peroxidase activity was blocked by 3% H<sub>2</sub>O<sub>2</sub>-methanol. Sections were then sequentially incubated with a) normal sheep serum (undiluted, 10 min), b) rabbit antiserum (DAKO, Copenhagen, Denmark) for human IgG, IgA, IgM, IgD, IgE, lysozyme and C<sub>3</sub> (diluted × 100, 30 min), c) sheep antirabbit IgG serum (DAKO, Copenhagen, Denmark, diluted × 40, 30 min) and d) rabbit PAP (DAKO, Copenhagen, Denmark, diluted × 20, 30 min). Peroxidase activity was demonstrated by a 3,3'-diaminobenzidine reaction. All the reactions were carried out at room temperature.

### Results

*Clinical and laboratory findings.* Details of

clinicopathological findings in the 14 cases are presented in Table 1. Two patients were children, 5 and 10 years old, and the remaining 12 were adults, ranging from 18 to 75 years old. Eight patients were females and 6 were males. Nodules were located in the subcutis of head and neck (7 cases), chest (2 cases), abdominal wall (1 case) and the extremities (2 cases), and in the parotid gland (2 cases). Either single or multiple nodules were present, and multiple nodules were adherent to one another. One subcutaneous nodule (Case 10) had involved the surrounding muscles. Simultaneous lymph node enlargement occurred in 5 cases. Nodules ranged from 1-5 cm in diameter. Duration of symptoms ranged from 1 week to 10 years. All the cases were surgically extirpated, and recurrence was recorded in only one case.

Laboratory data were obtained in only 7 cases. White blood cell count was normal in 5 and abnormal (> 10,000/ $\mu$ l) in 2. Eosinophilia examined prior to excisions were found in 3 of 4 cases. Elevation of serum immunoglobulin levels was not found in 2 cases examined. A patient (Case 11) had a subcutaneous tumor in the neck associated with proteinuria (10 mg/dl).

*Histopathological findings.* Nodules were characterized by a proliferation of lymphoid follicles with or without well-developed germinal centers, and granulomatous lesions in the interfollicular area consisting of marked infiltration of eosinophils, varying numbers of plasma cells, lymphocytes, mast cells and histiocytes, proliferation of blood vessels and fibrosis (Figs. 1, 2 and 3). Proliferating blood vessels were comprised of thick-walled, well-developed vessels and thin-walled vessels lined by plump endothelial cells that frequently projected into their irregular lumina. Elastic fibers were absent in the thin-walled blood vessels.

Involved lymph nodes showed generally the same pathological features as subcutaneous nodules. Lymph node structure was well-preserved; marked follicular hyperplasia with large germinal centers and infiltration of eosinophils in interfollicular areas and marginal sinuses were found.

**Table 1** Clinical data of 14 patients with Kimura's disease

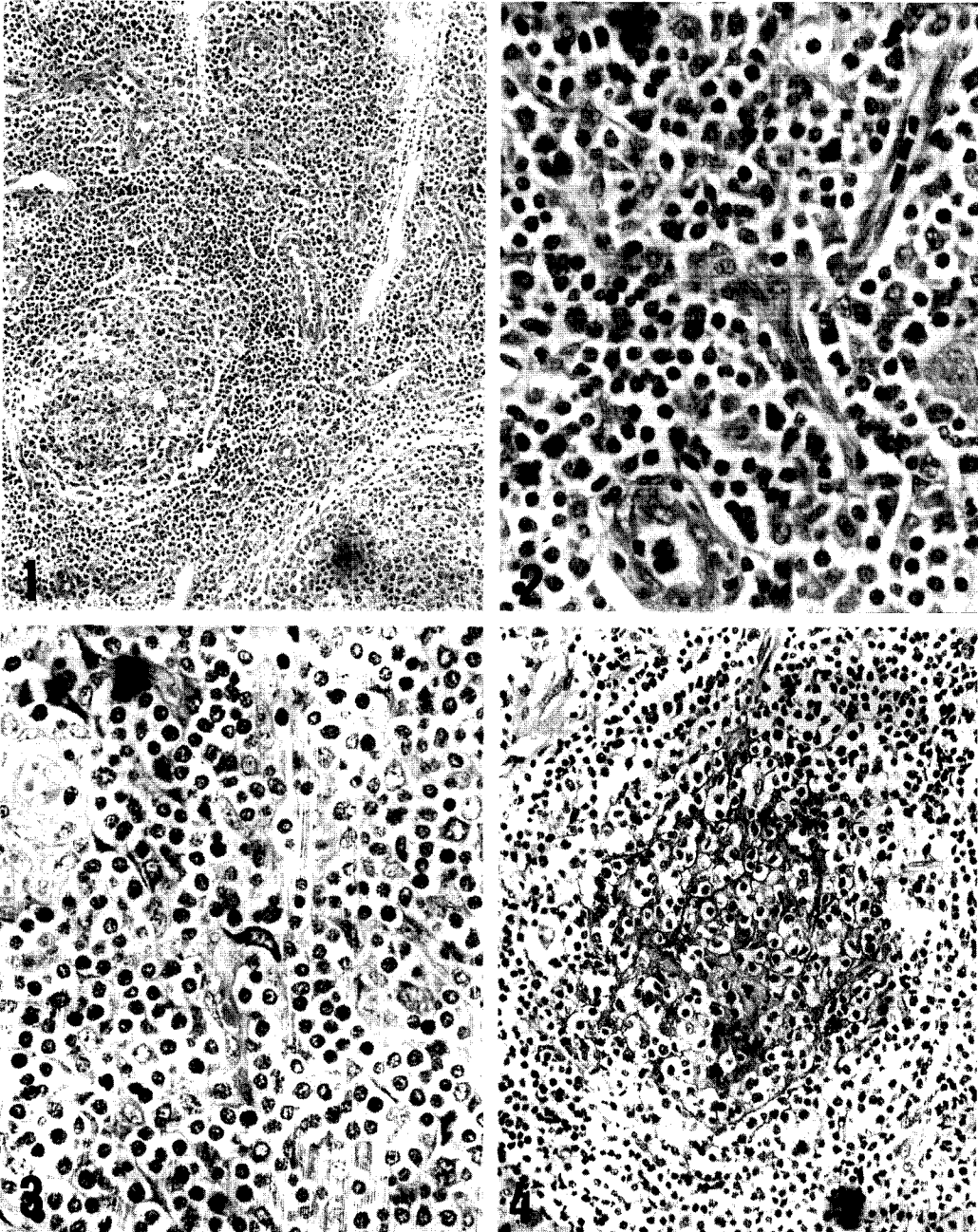
Case No.	Age (yrs)	Sex	Site	Histologic location	Duration of symptoms	Numbers and size of lesions	Treatment	Outcome
1.	38	F	Head	Parotid gland	10 yrs	n. i.	Excision	n. i.
2.	38	F	Chest	Skin lymph node	1 yr	Single n. i.	Excision	n. i.
3.	65	F	Neck	Subcutis	2 wks	Multiple 2.3 × 1.3 × 0.5 cm	Excision, chemotherapy	9 mos no recurrence
4.	27	M	Head	Subcutis	A few wks	Multiple 1.5 × 0.5 × 0.5 cm	Excision	2 yrs no recurrence
5.	61	F	Neck	Subcutis lymph node	1 wk	Single 1 × 1.5 × 1.5 cm	Excision	n. i.
6.	52	M	Neck	Subcutis lymph node	8 mos	Multiple 3.5 × 4.1 cm	Excision	n. i.
7.	75	F	Chest	Subcutis	3 wks	Multiple 1.9 × 1 × 1 cm 1.6 × 0.8 × 0.8 cm	Excision	10 mos no recurrence
8.	5	M	Abdomen	Skin	4 wks	Single 1 × 0.5 × 0.5 cm	Excision	11 mos
9.	33	F	Neck	Parotid gland	Several wks	n. i.	Excision	n. i.
10.	10	M	Neck	Subcutis and muscle	3 yrs	Single 3 × 3 cm	Excision	3 yrs twice recurrence
11.	37	M	Head	Skin	2 yrs	Single 0.5 × 0.5 cm	Excision	5 yrs no recurrence
12.	30	M	Neck	Subcutis lymph node	n. i.	Single 2.5 × 2 cm	Excision	n. i.
13.	18	F	Groin	Subcutis	1 wk	Single n. i.	Excision	n. i.
14.	41	F	Thigh	Subcutis lymph node	3 yrs	Single n. i.	Excision	n. i.

n. i.: no information

**Table 2** Immunohistochemical examinations of Kimura's disease

Case No.	Ig <sup>a</sup> G		IgA		IgM		IgD		IgE		Lysozyme		C <sub>3</sub>		
	I.F. <sup>b</sup>	E.F. <sup>c</sup>	I.F.	E.F.	I.F.	E.F.	I.F.	E.F.	I.F.	E.F.	I.F.	E.F.	I.F.	E.F.	
1.	-	+	-	-	-	-	-	-	+	(76)	-	+	(8)	+	-
2.	-	+	-	+	-	-	-	-	-	-	-	-	+	-	
3.	-	+	-	+	-	-	-	-	-	-	-	-	+	-	
4.	-	+	-	-	-	-	-	-	+	(75)	-	-	+	-	
5.	-	-	-	-	-	-	-	-	-	-	-	-	+	-	
6.	+	(4)	+	-	-	-	-	-	+	(84)	+	-	+	-	
7.	+	(6)	+	(10)	+	-	-	-	-	-	-	-	+	-	
8.	-	+	-	-	-	-	-	-	-	-	+	-	+	-	
9.	+	(8)	+	-	-	-	-	-	+	(78)	-	-	+	-	
10.	-	+	-	+	-	-	-	-	+	(90)	+	-	+	-	
11.	-	+	-	-	-	-	-	-	+	(72)	-	-	+	-	
12.	-	+	-	-	-	-	-	-	+	(80)	+	-	+	-	
13.	-	+	-	-	-	-	-	-	-	-	+	-	+	-	
14.	+	(5)	+	-	-	-	-	-	+	(85)	+	-	+	-	

a: Ig, immunoglobulin; b: I.F., intrafollicular; c: E.F., extrafollicular. -: negative, +: a few positive cells, #: between + and ##, ##: many positive cells. Numbers in parentheses show percentages of positive-stained follicles.



**Fig. 1** A lymphoid follicle and granulomatous changes with proliferation of blood vessels. Hematoxylin-eosin,  $\times 50$ .  
**Fig. 2** Proliferation of capillary vessels and infiltration of eosinophils, lymphocytes and plasma cells. Hematoxylin-eosin,  $\times 400$ .  
**Fig. 3** Marked, diffuse infiltration of eosinophils, lymphocytes, plasma cells and mast cells (in the center of figure). Giemsa,  $\times 400$ .  
**Fig. 4** Reticular IgE network in a germinal center, PAP method,  $\times 200$ .

*Immunohistochemical findings.* Immunohistochemical findings are summarized in Table 2. Positive IgE was detected in the intercellular matrix of follicles in all the cases and formed a reticular network between germinal center cells (Fig. 4). A similar but weaker IgG, IgA and lysozyme positivity was observed in germinal centers in 3, 1 and 1 case, respectively. Reaction for IgE was much stronger and the frequency of IgE-positive follicles was apparently higher than other immunoglobulin heavy chains. IgE-, IgG-, IgA- and lysozyme-positive cells scattered mainly in extrafollicular areas. Few IgM-, IgD- and C<sub>3</sub>-positive cells were found in all the cases.

## Discussion

The majority of subcutaneous tumor-like nodules in our cases were located in the head and neck, and some nodules were found also in the parotid gland. This location corresponds well with other previous reports (5, 6, 13-15, 18-20). However, a nodule involving muscles such as our Case 10 was only rarely reported (6). The sex ratio of Kimura's disease is generally preponderant in males, but there is greater incidence in females in some reports (18, 19). Our incidence is about equally divided between males and females. Kimura's disease occurs at any age. The average age in our 14 cases was 37.8 years, although the incidence was relatively high in young adults in the majority of previous reports (15, 18, 19). A 5-year-old patient (Case 8) might be the youngest patient hitherto reported.

Eosinophilia and elevation of serum IgE are other well-known characteristics of Kimura's disease (1, 21). In our report, eosinophilia was also found in almost all the patients whose laboratory data were obtained. However, serum immunoglobulin levels were not elevated in 2 patients. We hesitate to discuss the laboratory data at length, because our laboratory information is far from satisfactory.

Kimura's disease is usually a localized process

without systemic manifestations, with the exception of a renal disease as the only reported associated condition (22, 23). We identified a patient (Case 11) with proteinuria; unfortunately, we could not confirm the cause of his proteinuria by renal biopsy. Konishi *et al.* (22) reported a case complicated by a renal disease showing glomerular deposition of IgE, IgG, IgM and complement components. Proteinuria in that case might be related to Kimura's disease, representing a systemic manifestation.

Histologically, the nodules are characterized by the formation of lymphoid follicles and granulation tissue with marked infiltration of eosinophils and vascular proliferation (1). ALHE resembles Kimura's disease because of the similar clinical and pathologic findings (5). Especially in the Western literature, Kimura's disease is often considered identical to ALHE, a variant of ALHE or a different stage of ALHE (5, 11, 24-27). However, some investigators (14, 15, 23, 28, 29) indicate that the above conditions differ in pathologic changes of the blood vessel component. More comprehensive and comparative studies will be required to distinguish Kimura's disease from ALHE.

Kimura's original report (1) described only lesions of soft tissue and did not mention similar changes in the lymph nodes. Subsequent reports indicate lymph node involvement in 67-100 % of the cases (20, 29, 30). Broad clinicopathological features of Kimura's disease include a) sole subcutaneous or salivary gland lesions, b) the same lesions with lymph node involvement and c) sole lymph node lesions (23, 27, 28). Regional lymph nodes were enlarged in 5 out of 14 of our cases. Histology showed lymph nodes with hyperplasia; prominent germinal centers, eosinophils infiltrating in interfollicular areas and sinuses, and proliferating blood vessels. Therefore, we consider Kimura's disease to be essentially subcutaneous or salivary gland lesions with occasional lymph node involvement.

The immunohistochemical study showed that granulomatous lesions with lymphoid follicles had

a characteristic reticular staining for IgE, and that IgG-, IgA-, IgE- and lysozyme-positive cells scattered in extrafollicular areas, where cells bearing immunological functions, such as eosinophils, lymphocytes, plasma cell, mast cells and histiocytes, were located. The same IgE staining pattern has been reported not only in subcutaneous lesions (15, 19, 31), but also in lymph node lesions (25, 28). It should be noted that a reticular staining-pattern for IgE is not specific to Kimura's disease (15, 32). The percentage of IgE-positive follicles is much higher than that of IgG or IgM positivity, or of positivity in other reactive conditions.

IgE deposition in germinal centers and elevated serum IgE and eosinophilia in Kimura's disease suggest that the disease is atopic in nature (13). Levels of IgE and IgE antibody against *Candida albicans* in serum in Kimura's disease are elevated; the specific granules of eosinophils in involved tissues show changes in appearance similar to those in atopic diseases (19). Ishikawa et al. (15) pointed out that the absence of degranulation in IgE-coated mast cells could not explain the rarity of Type I hypersensitivity in patients with Kimura's disease.

In conclusion, we have described clinicopathologic findings of Kimura's disease. The disease has distinct clinical characteristics; strong reaction against IgE, and proliferation of mast cells as well as eosinophils, which play an important role in allergic phenomena. However, we were not able to satisfactorily correlate histological and immunological findings. To elucidate the pathogenesis of Kimura's disease, further investigations will be necessary.

## References

- Kimura T, Yoshimura S and Ishikawa E: On the unusual granulation combined with hyperplastic changes of lymphoid tissue. *Trans Soc Pathol Jpn* (1948) **37**, 179-190 (in Japanese).
- Iizuka S: Eosinophilic lymphadenitis and eosinophilic lymphoid granuloma: A proposal of a new concept on disease of the lymph node and its surrounding tissue. *Nihon Univ Med J* (1959) **18**, 900-908 (in Japanese).
- Wells GC and Summerly R: Subcutaneous lymphoid hyperplasia with eosinophilia. *Proc R Soc Med* (1963) **56**, 728-735.
- Morinaga T, Yoshizaki T and Ishihara Y: Eosinophilic lymphomatosis (Kimura's disease). *Jpn J Clin Med* (1965) **23**, 2001-2011 (in Japanese).
- Wells GC and Whimster IW: Subcutaneous angiolymphoid hyperplasia with eosinophilia. *Br J Dermatol* (1969) **81**, 1-15.
- Buchanan R, Sworn MJ and Mousley JM: Angiolymphoid hyperplasia with eosinophilia involving skeletal muscle. *Histopathology* (1980) **4**, 197-204.
- Bostad L and Petterson W: Angiolymphoid hyperplasia with eosinophilia involving the orbit: A case report. *Acta Ophthalmol* (1982) **60**, 419-426.
- Hidayat AA, Cameron JD, Font RL and Zimmerman, LE: Angiolymphoid hyperplasia with eosinophilia (Kimura's disease) of the orbit and ocular adnexa. *Am J Ophthalmol* (1983) **96**, 176-189.
- Wilson JE and Bleehe SS: Inflammatory angiomatous nodules with abnormal blood vessels occurring about the ears and scalp (pseudo or atypical pyogenic granuloma). *Br J Dermatol* (1969) **81**, 804-816.
- Wilson JE and Marks R: Papular angioplasia: Vascular papules of the face and scalp stimulating malignant vascular tumors. *Arch Dermatol* (1970) **102**, 422-427.
- Reed RJ and Terazakis N: Subcutaneous angioblastic lymphoid hyperplasia with eosinophilia (Kimura's disease). *Cancer* (1972) **29**, 489-497.
- Arakawa M, Kitajima K and Shinata S: Eosinophilic lymphofollicular granuloma (Kimura's disease): Report of case. *Med J Kawasaki Hosp* (1972) **4**, 173-181 (in Japanese).
- Miyamoto Y and Tani T: Eosinophilic lymphofollicular granuloma in parotid gland (Kimura's disease): A report of two cases. *Kawasaki Med J* (1977) **3**, 15-27.
- Rosai J, Gold J and Landy R: The histiocytoid hemangiomas: A unifying concept embracing several previously described entities of the skin, soft tissue, large vessels, bone and heart. *Hum Pathol* (1979) **10**, 707-730.
- Ishikawa E, Tanaka H, Kakimoto S, Takasaki S, Kirino T, Sakata A and Suzuki M: A pathological study on eosinophilic lymphofolliculoid granuloma (Kimura's disease). *Acta Pathol Jpn* (1981) **31**, 767-781.
- Sternberg LA, Hardy PH, Cuculis JJ and Meyer H: The unlabelled antibody enzyme method of immunohistochemistry. *J Histochem Cytochem* (1970) **18**, 315-333.
- Ordenez NG, Manning JT Jr and Brooks TE: Effect of trypsinization on the immunostaining of formalin-fixed, paraffin-embedded tissues. *Am J Surg Pathol* (1988) **12**, 121-129.
- Mehregan AH and Shapiro L: Angiolymphoid hyperplasia with eosinophilia. *Arch Dermatol* (1971) **103**, 50-57.
- Takenaka T, Okuda M, Usami A, Kawabori S, Ogami Y, Kubo K and Uda H: Histological and immunological studies



- on eosinophilic granuloma of soft tissue, so-called Kimura's disease. *Clin Allergy* (1976) **6**, 27-39.
20. Tham KT, Leung PC, Saw D and Gwi E: Kimura's disease with salivary gland involvement. *Br J Surg* (1981) **68**, 495-497.
  21. Okudaira H, Hongo O, Ogita T, Haida M, Yamauchi N and Miyamoto T: Serum IgE antibody levels in patients with bronchial asthma, atopic dermatitis, eosinophilic granuloma of the soft tissue (Kimura's disease) and other diseases. *Ann Allergy* (1983) **50**, 51-54.
  22. Konishi N, Tamura T, Kawai C and Shirai T: IgE associated nephropathy in a patient with subcutaneous eosinophilic lymphoid granuloma (Kimura's disease). *Virchows Arch (Pathol Anat)* (1981) **392**, 127-134.
  23. Kuo T-t, Shi L-Y and Chan H-L: Kimura's disease: Involvement of regional lymph nodes and distinction from angiolymphoid hyperplasia with eosinophilia. *Am J Surg Pathol* (1988) **12**, 843-854.
  24. Buchner A, Silverman S Jr, Wara WM and Hansen LS: Angiolymphoid hyperplasia with eosinophilia (Kimura's disease). *Oral Surg* (1980) **49**, 309-313.
  25. Eisenberg E and Lowlicht R: Angiolymphoid hyperplasia with eosinophilia: A clinico-pathological conference. *J Oral Pathol* (1985) **14**, 216-223.
  26. Olsen TG, Helwig EB: Angiolymphoid hyperplasia with eosinophilia: A clinicopathologic study of 116 patients. *J Am Acad Dermatol* (1985) **12**, 781-791.
  27. Suster S: Nodal angiolymphoid hyperplasia with eosinophilia. *Am J Clin Pathol* (1987) **88**, 236-239.
  28. Hui PK, Chan JKC, Kung ITM and Gwi E: Lymphadenopathy of Kimura's disease. *Am J Surg Pathol* (1989) **13**, 177-186.
  29. Chang TL and Ch'en CY: Eosinophilic granuloma of lymph nodes and soft tissues: Report of 21 cases. *Chinese Med J* (1962) **81**, 384-387.
  30. Kung ITM, Gibson JB and Banntyne PM: Kimura's disease: A clinicopathological study of 21 cases and its distinction from angiolymphoid hyperplasia with eosinophilia. *Pathology* (1984) **16**, 34-44.
  31. Maeda K and Jimbow K: Kimura's disease: Immunohistochemistry of infiltrating cells using monoclonal and polyclonal antibodies. *J Dermatol* (1986) **13**, 190-195.
  32. Sundaresan M, Rhodes T and Akosa AB: Immunoglobulin heavy chain patterns in reactive lymphadenopathy. *J Clin Pathol* (1991) **44**, 753-755.

Received May 14, 1992; accepted June 17, 1992.