

Acta Medica Okayama

Volume 33, Issue 3

1979

Article 6

JUNE 1979

A case of alcoholic liver injury with an unusual polyacrylamide-gel disc-electrophoretic pattern of serum lipoproteins.

Makoto Watanabe*

Kazuhisa Taketa†

Koukichi Fujii‡

Chiaki Fujii**

Hiroshi Kono††

*Okayama University,

†Okayama University,

‡Fujii Clinic,

**Chugoku Central Hospital,

††Kagawa University,

A case of alcoholic liver injury with an unusual polyacrylamide-gel disc-electrophoretic pattern of serum lipoproteins.*

Makoto Watanabe, Kazuhisa Taketa, Koukichi Fujii, Chiaki Fujii, and Hiroshi Kono

Abstract

An unusual lipoprotein pattern on polyacrylamide-gel disc-electrophoresis was observed in 37 year-old male diagnosed as alcoholic liver injury. The electrophoretic lipoprotein pattern consisted of a major band of pre-beta mobility and minor intermediate, fast-beta and slow-alpha bands. The normal beta band was virtually absent and the alpha band was diminished. The abnormal lipoprotein pattern was observed one week after discontinuing alcohol consumption when marked hypertriglyceridemia demonstrated earlier had already normalized leaving a moderate hypercholesterolemia with reduced esterified cholesterol and abnormal liver function tests. The lipoprotein abnormalities were completely normal one month later. The appearance of a major pre-beta band with normal triglyceride and high cholesterol levels is discussed in relation to the formation of larger triglyceride-rich LDL particles in recovery from alcoholic hepatitis.

KEYWORDS: alcoholic liver injury, hyperlipidemia, lipoproteins, polyacrylamide-gel disc-electrophoresis

*PMID: 227229 [PubMed - indexed for MEDLINE]

Copyright (C) OKAYAMA UNIVERSITY MEDICAL SCHOOL

**A CASE OF ALCOHOLIC LIVER INJURY WITH
AN UNUSUAL POLYACRYLAMIDE-GEL
DISC-ELECTROPHORETIC PATTERN
OF SERUM LIPOPROTEINS**

Makoto WATANABE, Kazuhisa TAKETA, Koukichi FUJII*,
Chiaki FUJII** and Hiroshi KONO***

*Department of Internal Medicine (Director: Prof. H. Nagashima),
Okayama University Medical School, Okayama 700, Japan; *Fujii
Clinic, Fukuyama 729-01, Japan; **Chugoku Central Hospital,
Fukuyama 721, Japan; and ***Kagawa University, Health Research
Center, Takamatsu 760, Japan*

Received January 18, 1979

Abstract. An unusual lipoprotein pattern on polyacrylamide-gel disc-electrophoresis was observed in 37 year-old male diagnosed as alcoholic liver injury. The electrophoretic lipoprotein pattern consisted of a major band of pre- β mobility and minor intermediate, fast- β and slow- α bands. The normal β band was virtually absent and the α band was diminished. The abnormal lipoprotein pattern was observed one week after discontinuing alcohol consumption when marked hypertriglyceridemia demonstrated earlier had already normalized leaving a moderate hypercholesterolemia with reduced esterified cholesterol and abnormal liver function tests. The lipoprotein abnormalities were completely normal one month later. The appearance of a major pre- β band with normal triglyceride and high cholesterol levels is discussed in relation to the formation of larger triglyceride-rich LDL particles in recovery from alcoholic hepatitis.

Key words: alcoholic liver injury, hyperlipidemia, lipoproteins, polyacrylamide-gel disc-electrophoresis

Increased levels of serum triglycerides and cholesterol are frequently encountered, although not consistently, in patients with alcoholic liver injury (1-3). What characterizes most their altered lipid metabolism is the decrease in esterified cholesterol level, which occurs with or without hyperlipidemia (3). Despite the association of such lipid abnormalities with acute alcoholic liver disease, the lipoprotein pattern has been little studied. Sabesin and others (3) reported the absence of α and pre- β lipoprotein bands and the presence of a single band of abnormal β mobility on agarose-gel electrophoresis of plasma from patients with alcoholic hepatitis. The major lipoprotein characterizing the abnormal band appears to be a triglyceride-rich LDL.

We experienced a case of alcoholic liver injury with an abnormal lipoprotein

pattern on polyacrylamide-gel (PAG) disc-electrophoresis in the initial stage of recovery from hyperlipidemia after the discontinuation of alcohol consumption. The abnormality was the presence of a major lipoprotein band of pre- β mobility despite normal triglyceride and increased cholesterol levels in serum. The present case is reported because of the unusual lipoprotein pattern associated with alcoholic liver injury. The relation to the triglyceride-rich LDL is discussed.

CASE REPORT

A 37 year-old male caterer, who had been a heavy drinker, visited Fujii clinic because of loss of appetite on August 23, 1977. Hypertension, hyperlipidemia (serum cholesterol 227 mg/dl, triglycerides 462 mg/dl and phospholipids 180 mg/dl) and slight hepatic dysfunction (bilirubin 1.1 mg/dl, GOT 38 Iu/l, GPT 58 Iu/l, Al-Pase 23.5 K-A u, LAP 365 G-R u and LDH 259 W u) were pointed out. Although the patient was advised to reduce alcohol consumption and placed under medication (isosterol 6 tablets and pantethine 3.0 g/day) and dietary regimen, he drank regularly a minimum of 135 g of alcohol as 'sake', occasionally amounting to over 270 g, and additional beer and whisky, and tended to miss regular meals. Hypertriglyceridemia and mild elevation of GOT, GPT, Al-Pase and LAP without hyperbilirubinemia continued thereafter as shown in Fig. 1.

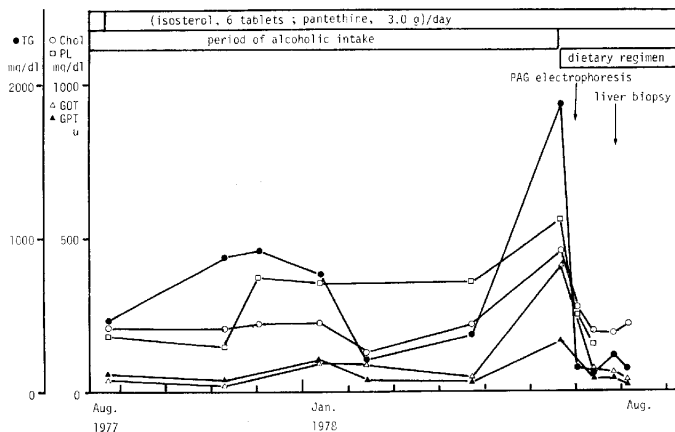


Fig. 1. Clinical course. Chol, cholesterol; TG, triglycerides and PL, phospholipids.

Agarose-gel electrophoresis of lipoproteins performed on December 1, 1977 gave distinct lipoprotein bands with well-retained α (26.7%), slightly reduced β (26.7%) and markedly increased pre- β (46.6%) fractions, a lipoprotein pattern compatible with hyperlipidemia (cholesterol 222 mg/dl, triglycerides 776 mg/dl

and phospholipids 354 mg/dl) in spite of the abnormal results of liver function tests (GOT 88 Iu/l, GPT 89 Iu/l, Al-Pase 20 K-A u, LAP 361 G-R u and LDH 442 W u). On June 20, 1978 marked hyperlipidemia (cholesterol 455 mg/dl, triglycerides 1,892 mg/dl and phospholipids 564 mg/dl) and moderate liver injury (bilirubin 2.5 mg/dl, GOT 410 Iu/l, GPT 167 Iu/l, Al-Pase 17.6 K-A u and LDH 509 W u) were found.

In order to control the hyperlipidemia, overweight (height 162 cm, weight 65 kg) and suspected alcoholic liver injury, the patient was placed on a low-fat diet (1,800 Cal) without alcoholic beverage with a favorable clinical course. The PAG disc-electrophoretic pattern of lipoproteins obtained on July 1, 1978 revealed an unusual distribution with a single major band with pre- β mobility, virtual absence of the usual β band, several discrete minor bands with intermediate and fast- β mobilities, slow-migrating α bands (4) and a faint α band (Fig. 2). In spite of the altered lipoprotein pattern, the abnormalities in serum

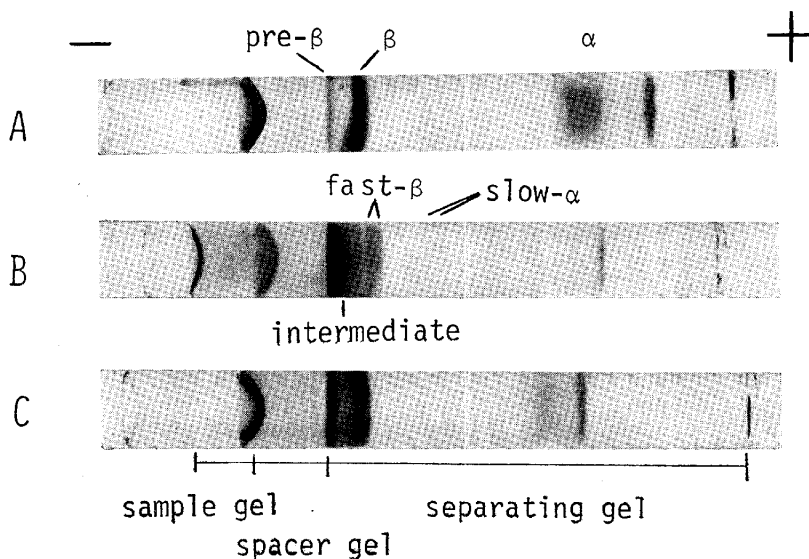


Fig. 2. PAG disc-electrophoretic patterns of serum lipoproteins. A, normal control; B, the present case (July 1, 1978); and C, the present case (September 8, 1978). The electrophoretic patterns were obtained with 3.6% PAG and pre-stained lipids by the method of Naito *et al.* (5).

lipid levels had improved partially by this time (cholesterol 271 mg/dl, triglycerides 150 mg/dl and phospholipids 249 mg/dl). However, hyperbilirubinemia (total 1.56 mg/dl, direct 0.89 mg/dl), markedly elevated γ -GTP (499 mu/ml) with normal Al-Pase (2.6 B-L u) and diminished esterified cholesterol (123 mg/dl) remained. On July 22, 1978, the patient was admitted to Chugoku Central

Hospital for further evaluation of the hepatic disorder.

There was no family history suggestive of familial hyperlipidemia and no contributory past history. Dietary habits and alcoholic consumption were as described above. Personal history was otherwise unremarkable.

Physical examination revealed no abnormalities except for an extended liver edge two fingerbreadths below the right costal margin with the upper limit of liver dullness at the 6th intercostal space. The liver was smooth, elastically hard, dull-edged and non-tender. The spleen was not palpable. His body weight had decreased to 58 kg. Xanthoma were not present. Blood pressure was 130/100 mm Hg with a normal electrocardiogram and Stage I (Keith-Wagener classification) fundoscopic findings.

Laboratory data on admission were: red cell count $402 \times 10^4/\text{mm}^3$; hemoglobin 14.1 g/dl; hematocrit 39.4%; reticulocyte count 0.8%; white cell count $7,000/\text{mm}^3$ with neutrophil 74 (stab 10, II 30, III 27 and IV 7)%, monocyte 2%, basophil 1% and lymphocyte 23 (large 16 and small 7)%; platelet count $25.1 \times 10^4/\text{mm}^3$; bleeding tendency, urinalysis and stool examination all negative; erythrocyte sedimentation rate 27 mm/1h, 46 mm/2h; CRP (-); serum bilirubin 0.7 mg/dl; GOT 58 Iu/l, GPT 49 Iu/l; Al-Pase 9.3 K-A u; LAP 257 G-R u; γ -GTP 136 mu/ml; Ch-Ease 1.01 Δ pH; ICG (15 min) 5.6%; protein 7.5 g/dl (alb. 62.4, α_1 3.5, α_2 11.1, β 14.7 and γ -glob. 8.1%); HB_s-Ag (-); HB_s-Ag (+) $\times 2^6$; other liver function tests within normal limits; indicating marked improvement in liver function tests and serum lipid levels except for γ -GTP and triglyceride values, which were still moderately increased. The lipoprotein pattern obtained by agarose-gel electrophoresis (Fig. 3) was also nearly normal, giving distinct α , β and pre- β bands with a slightly high pre- β fraction. The results of a 50 g GTT was of borderline type with a peak height of 200 mg/dl in 60 min and normal 0- and 120-min values. The IRI response was slightly reduced with a maximum of 16 $\mu\text{u/ml}$ in 90 min.

Peritoneoscopic examination performed on July 27, 1978 revealed soft, flat and dull-edged liver lobes without splenomegaly. A liver specimen biopsied from the right lobe disclosed microscopically widened portal triads with periblobular septum, hydropic swelling of hepatocytes in the central area, minimum fatty change and infiltration of eosinophil and neutrophil in the sinusoid and portal area, these findings being compatible with a resolving stage of acute alcoholic hepatitis (Fig. 4).

The patient was discharged on August 8, 1978 after the liver function tests and serum lipid levels were normalized. PAG disc-electrophoretic pattern of lipoproteins also confirmed the appearance of discrete α , β and pre- β bands (Fig. 2) with clinical recovery.

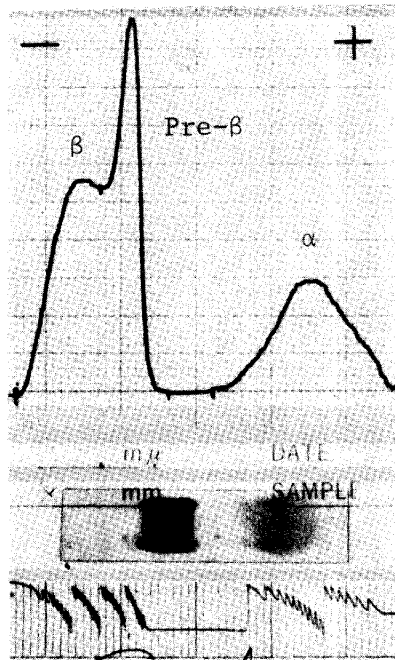


Fig. 3. Agarose-gel electrophoretic pattern of serum lipoproteins. α 29.7%, pre- β 37.0% and β 33.3% by densitometry.

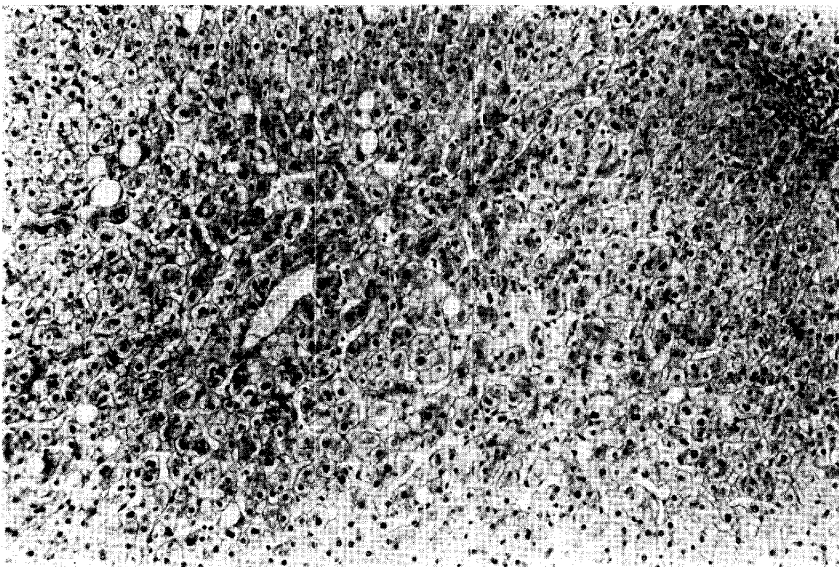


Fig. 4. Liver histology. H-E stain. $\times 250$.

DISCUSSION

The hyperlipidemia found in this case before abstinence from alcohol was characterized by predominant serum triglyceride elevation with an intense pre- β band on agarose-gel electrophoresis. This type of hyperlipemia is generally observed in cases with excessive alcoholic consumption and considered as resulting from an increased VLDL secretion (1, 2, 6-8). Dietary factors might have accelerated this process (9), since rapid normalization of hyperlipemia occurred after cessation of alcohol intake and the institution of a low-fat diet together with the correction of overweight. Individual variation in sensitivity to the hyperlipemic effects of ethanol should also be considered (10), although the patient had an abnormal GTT with low insulin response, which could be regarded as a predisposing factor (10).

The highest serum lipid levels occurred when the results of liver function tests were most abnormal, as is shown by the predominant elevation of GOT over GPT and marked rise in γ -GTP, both characterizing alcoholic liver injury. The patient had acute alcoholic hepatitis proven by histological examination of biopsied liver tissue. In his initial convalescent stage of alcoholic liver disease, the hyperlipidemia had been partially corrected, leaving only moderate hypercholesterolemia with a relative increase in unesterified cholesterol, unlike the reported secondary rise in esterified cholesterol (1). The abnormal lipoprotein pattern was evident at this time on PAG disc-electrophoresis. This indicates that the above mentioned metabolic effect of ethanol on lipoprotein, *i. e.*, increased lipoprotein production, including HDL (7, 11-13), had been eliminated by this time and that the effect of hepatic injury on lipoprotein had become apparent. The lipoprotein profile resulting from parenchymal liver injury is opposite to that caused by the direct action of ethanol: normal VLDL and HDL disappear and an abnormal β -migrating LDL emerges (3, 14). Thus, the analysis of lipoproteins in alcoholics may help detect hepatotoxic effects of ethanol. Vogelberg and others (14) reported the appearance of an electrophoretic subfraction of pre- β band together with the reduction of α -band in the convalescent stage of a chronic alcoholic liver injury with hyperlipidemia. The lipoprotein abnormalities persisted for many weeks after cessation of alcohol consumption (3).

The major abnormalities of lipoprotein pattern found in the present case at the time of early recovery from alcoholic liver injury were considerably different, however, from those mentioned above; namely, the presence of predominant pre- β -migrating band with the lack of normal β band despite the increased cholesterol and normal triglyceride levels in serum. Wada and Mise (15) observed a similar pre- β -migrating sole band in a case of myocardial ischemia with impaired hepatic function and marked hyperlipidemia. The main pathological change in lipoprotein metabolism in alcoholic hepatitis is reported by Sabesin *et al.* (3) to be

the appearance of a triglyceride-rich cholesteryl ester-poor LDL with abnormal β mobility as a single band on agarose-gel electrophoresis. This occurs in cases with hepatic injury of parenchymal (16) or obstructive (17, 18) type usually with hyperlipemia, but not necessarily so (3, 16, 19) as for the present study, possibly in relation to the decrease in activity of hepatic triglyceride lipase (20). Liver injury in this patient at the time of lipoprotein analysis is shown by markedly elevated γ -GTP activity even though alcohol consumption had been discontinued nearly ten days earlier. Accordingly, the unusual major lipoprotein found in the present case may be the triglyceride-rich LDL. Although the exact mobility of this LDL on PAG disc-electrophoresis is not available in the literature, pre- β mobility of the triglyceride-rich LDL seems very likely because of the large molecular sizes (3, 16) equivalent to those of VLDL. This waits further proofs, however, since the sera from patients with hepatic injuries due to alcohol, viral or other agents do not necessarily give a major band of pre- β mobility on PAG disc-electrophoresis (unpublished observation). Since the triglyceride-rich LDL is a remnant particle, it is more likely to form a mid-band (21). Although an intermediate band corresponding to the central mid-band of Mead and Dangerfield (21) was found in the present case, it was too minor a component to account for the entire lipoprotein alteration.

The significance of the fast- β -migrating bands of lipoprotein present in this patient is not clear at present. The slow-migrating α band has been characterized by Watanabe and Taketa (4) as representing a mild intrahepatic cholestasis. The presence of this pathological band in the present case would suggest the contribution of a cholestatic mechanism (22) to the pathogenesis of alcoholic liver injury. An obstructive lipoprotein, lipoprotein X (23, 24), is not likely to be increased in this case because of the absence of the β band, which corresponds to the mobility of lipoprotein X, even though the decreased cholesteryl ester suggestive of a diminished lecithin-cholesterol acyltransferase activity (3) was evident. Two α -lipoprotein bands appearing after alcoholic intoxication were described by Johansson and Laurell (25). Although these abnormal α -lipoproteins were not identified, they might represent a facet of complex α -lipoprotein abnormalities in alcoholic hepatitis as suggested by Sabesin and others (3).

Acknowledgment. The authors thank Prof. H. Nagashima for reviewing the manuscript and Dr. H. Endo for his suggestions on histological examination of liver tissue.

REFERENCES

1. Losowsky, M. S., Jones, D. P., Davidson, C. S. and Lieber, C. S.: Studies of alcohol hyperlipemia and its mechanism. *Am. J. Med.* **35**, 794-803, 1963.
2. Baumgartner, H. P. and Filippini, L.: Alkoholinduzierte Hyperlipoproteinämien. *Schweiz. Med. Wschr.* **107**, 1406-1411, 1977.
3. Sabesin, S. M., Hawkins, H. L., Kuiken, L. and Ragland, J. B.: Abnormal plasma lipoproteins and lecithin-cholesterol acyltransferase deficiency in alcoholic liver disease. *Gastro-*

- enterology* **72**, 510-518, 1977.
4. Watanabe, M. and Taketa, K.: Multiplicity of obstructive lipoprotein. *Proc. Jpn. Soc. Clin. Biochem. Metab.* **15**, 65-67, 1978 (in Japanese).
 5. Naito, H.K., Wada, M., Ehrhart, L. A. and Lewis, L. A.: Polyacrylamide-gel disc-electrophoresis as a screening procedure for serum lipoprotein abnormalities. *Clin. Chem.* **19**, 228-234, 1973.
 6. Isselbacher, K. J. and Greenberger, N. J.: Metabolic effects of alcohol on the liver. *N. Engl. J. Med.* **270**, 351-356, 1964.
 7. Baraona, E. and Lieber, C. S.: Effects of chronic ethanol feeding on serum lipoprotein metabolism in the rat. *J. Clin. Invest.* **49**, 769-778, 1970.
 8. Lieber, C. S.: Effects of ethanol upon lipid metabolism. *Lipids* **9**, 103-116, 1974.
 9. Baraona, E., Pirola, R. C. and Lieber, C. S.: The pathogenesis of postprandial hyperlipemia in rats fed ethanol-containing diets. *J. Clin. Invest.* **52**, 296-303, 1973.
 10. Mendelson, J. H. and Mello, N. K.: Alcohol-induced hyperlipidemia and beta lipoproteins. *Science* **180**, 1372-1374, 1973.
 11. Wilson, D. E., Schreibman, P. H., Brewster, A. C. and Arky, R. A.: The enhancement of alimentary lipemia by ethanol in man. *J. Lab. Clin. Med.* **75**, 264-274, 1970.
 12. Belfrage, P., Berg, B., Hägerstrand, I., Nilsson-Ehle, P., Tornquist, H. and Wiebe, Th.: Alterations of lipid metabolism in healthy volunteers during long-term ethanol intake. *Eur. J. Clin. Invest.* **7**, 127-131, 1977.
 13. Cattelli, W. P., Doyle, J. T., Gordon, T., Hames, C. G., Hjortland, M. C., Hulley, S. B., Kagan, A. and Zukel, W. J.: Alcohol and blood lipids. The cooperative lipoprotein phenotyping study. *Lancet* **i**, 153-155, 1977.
 14. Vogelberg, K. H., Gries, F. A., Miss, H. D. and Jahnke, K.: Die Hyperlipämie bei chronischem Alkoholabusus. *Dtsch. Med. Wschr.* **96**, 13-21, 1971.
 15. Wada, M. and Mise, J.: An investigation of serum lipoprotein disc electrophoresis. II. A simple method of human serum lipoprotein disc electrophoresis and identification of the resolved lipoproteins. *Jpn. Circ. J.* **36**, 335-347, 1972.
 16. Müller, P., Fellin, R., Lambrecht, J., Agostini, B., Wieland, H., Rost, W. and Seidel, D.: Hypertriglyceridemia secondary to liver disease. *Eur. J. Clin. Invest.* **4**, 419-428, 1974.
 17. Kostner, G. M., Laggner, P., Prexl, H. J. and Holasek, A.: Investigation of the abnormal low-density lipoproteins occurring in patients with obstructive jaundice. *Biochem. J.* **157**, 401-407, 1976.
 18. McIntyre, N., Harry, D. S. and Pearson, A. J. G.: The hypercholesterolemias of obstructive jaundice. *Gut* **16**, 379-391, 1976.
 19. Klör, U., Ditschuneit, H. H., Rakow, D. and Ditschuneit, H.: Further characterization of dyslipoproteinemia in hepatic disease. *Eur. Soc. Clin. Invest.* **2**, 291, 1972.
 20. Freeman, M., Kuiken, L., Ragland, J. B. and Sabesin, S. M.: Hepatic triglyceride lipase deficiency in liver disease. *Lipids* **12**, 443-445, 1977.
 21. Mead, M. G. and Dangerfield, W. G.: The investigation of "mid-band" lipoproteins using polyacrylamide gel electrophoresis. *Clin. Chim. Acta* **51**, 173-182, 1974.
 22. Glover, S. C., McPhie, J. L. and Brunt, P. W.: Cholestasis in acute alcoholic liver disease. *Lancet* **ii**, 1305-1306, 1977.
 23. Seidel, D., Alaupovic, P. and Furman, R. H.: A lipoprotein characterizing obstructive jaundice. I. Method for quantitative separation and identification of lipoprotein in jaundiced subjects. *J. Clin. Invest.* **48**, 1211-1223, 1969.
 24. Seidel, D., Alaupovic, P., Furman, R. H. and McConathy, W. J.: A lipoprotein characterizing obstructive jaundice. II. Isolation and partial characterization of the protein moieties of low density lipoproteins. *J. Clin. Invest.* **49**, 2396-2407, 1970.
 25. Johansson, B. G. and Laurell, C. B.: Disorders of serum alpha lipoproteins after alcoholic intoxication. *Scand. J. Clin. Lab. Invest.* **23**, 231-233, 1969.