

Acta Medica Okayama

Volume 61, Issue 4

2007

Article 8

AUGUST 2007

Coinfection of Invasive Pulmonary Aspergillosis and Pneumocystis Jiroveci Pneumonia in a Non-HIV Patient

Kyoichi Kaira*

Yasuyuki Shimoyama†

Yuga Takahashi‡

Tomohiro Iida**

Noriko Yanagitani††

Noriaki Sunaga‡‡

Takeshi Hisada§

Tamotsu Ishizuka¶

Masatomo Mori||

*Gunma University,

†Gunma University,

‡Gunma University,

**Gunma University,

††Gunma University,

‡‡Gunma University,

§Gunma University,

¶Gunma University,

||Gunma University,

Coinfection of Invasive Pulmonary Aspergillosis and Pneumocystis Jiroveci Pneumonia in a Non-HIV Patient*

Kyoichi Kaira, Yasuyuki Shimoyama, Yuga Takahashi, Tomohiro Iida, Noriko Yanagitani, Noriaki Sunaga, Takeshi Hisada, Tamotsu Ishizuka, and Masatomo Mori

Abstract

Invasive pulmonary aspergillosis (IPA) and pneumocystis jiroveci pneumonia (PCP) are life-threatening opportunistic infections that occur in immunocompromised hosts. Early diagnosis and treatment of these opportunistic infections is essential to the survival of immunocompromised patients. We report a 60-year-old man undergoing short-term steroid therapy after surgical resection of a brain tumor infected with combined invasive pulmonary aspergillosis and pneumocystis jiroveci pneumonia diagnosed by bronchoscopy with bronchoalveolar lavage. Our case demonstrated that short-term systemic steroid therapy in non-HIV patients with underlying chronic lung conditions and malignancies was a risk factor for IPA and PCP, and for a combination of these infections.

KEYWORDS: pneumocystis jiroveci pneumonia, invasive pulmonary aspergillosis, steroid therapy, pulmonary

Case Report

Coinfection of Invasive Pulmonary Aspergillosis and Pneumocystis Jiroveci Pneumonia in a Non-HIV Patient

Kyoichi Kaira*, Yasuyuki Shimoyama, Yuga Takahashi,
Tomohiro Iida, Noriko Yanagitani, Noriaki Sunaga,
Takeshi Hisada, Tamotsu Ishizuka, and Masatomo Mori

*Department of Medicine and Molecular Science, Gunma University Graduate
School of Medicine, Maebashi, Gunma 371-8511, Japan*

Invasive pulmonary aspergillosis (IPA) and pneumocystis jiroveci pneumonia (PCP) are life-threatening opportunistic infections that occur in immunocompromised hosts. Early diagnosis and treatment of these opportunistic infections is essential to the survival of immunocompromised patients. We report a 60-year-old man undergoing short-term steroid therapy after surgical resection of a brain tumor infected with combined invasive pulmonary aspergillosis and pneumocystis jiroveci pneumonia diagnosed by bronchoscopy with bronchoalveolar lavage. Our case demonstrated that short-term systemic steroid therapy in non-HIV patients with underlying chronic lung conditions and malignancies was a risk factor for IPA and PCP, and for a combination of these infections.

Key words: pneumocystis jiroveci pneumonia, invasive pulmonary aspergillosis, steroid therapy, pulmonary coinfection

Invasive pulmonary aspergillosis (IPA) is a life-threatening fungal infection that predominantly affects severely immunocompromised patients, particularly those with prolonged neutropenia, organ transplantation, or high-dose corticosteroid therapy [1, 2]. Pneumocystis jiroveci pneumonia (PCP) is also a life-threatening opportunistic infection which occurs in immunocompromised hosts, especially patients with acquired immunodeficiency syndrome (AIDS). PCP is increasing in frequency in other immunosuppressed patients, including organ transplant recipients and those with malignancy who are treated with steroids and chemotherapeutic regimens

[1, 3]. These opportunistic infections are usually diagnosed during an autopsy or when it is too late to treat them. A high degree of suspicion is necessary to diagnose these infections. Here, we describe a fatal case of combined IPA and PCP in a patient not infected with human immunodeficiency virus (HIV).

Case Report

A 60-year-old man was diagnosed with renal cell carcinoma and was treated with nephrectomy in Oct. 1997. For 8 years after the operation, he had been generally well without any signs of recurrence. The patient had a history of smoking and chronic obstructive respiratory disease (COPD). In Sept. 2005, he was diagnosed with a metastatic brain tumor of renal cell carcinoma by surgical resection. To improve the

Received October 13, 2006; accepted January 15, 2007.

*Corresponding author. Phone: +81-27-220-8136; Fax: +81-27-220-8136
E-mail: kkaira1970@yahoo.co.jp (K. Kaira)

cerebral edema after surgical resection of the brain tumor, we initiated corticosteroids (betamethasone 5 mg daily for 7 days, followed by betamethasone 2 mg daily for 14 days, and followed by betamethasone 1 mg daily for 14 days). He was then treated with radiation therapy. There was no evidence of disease other than the brain tumor. A computed tomographic (CT) scan of the chest revealed mild emphysematous changes but no bulla-like formations.

In Oct. 2005, the patient presented a cough, sputum, and high fever. On physical examination, he was comfortable and in no apparent distress. Laboratory data revealed a white blood cell count of 8,300 cells per mm³ with a differential of 78% neutrophils and 10% lymphocytes, and C-reactive protein (CRP) of 14.6 mg/dl. Chest radiography revealed infiltrative

shadow throughout the right lung field. A chest CT revealed multiple cystic lesions and alveolo-interstitial infiltrates in the right upper lobe (Fig. 1A). Empirical treatment with intravenous ceftazidime 2.0 g/day and minocycline 200 mg/day was initiated.

On hospital day 3, the patient was still febrile, and pulmonary infiltrates had increased. Thus, he was treated with intravenous meropenem 1.0 g/day and ciprofloxacin 600 mg/day. Sputum was repeatedly negative for malignant cells, acid-fast bacilli, aspergillus, and candida. Bacteriological investigation of blood culture also did not reveal any microorganism. An enzyme-linked immunosorbent assay (ELISA) test for HIV was negative. However, an aspergillus antigen test in the serum done with an ELISA revealed positive results. The antifungal therapy of micafungin

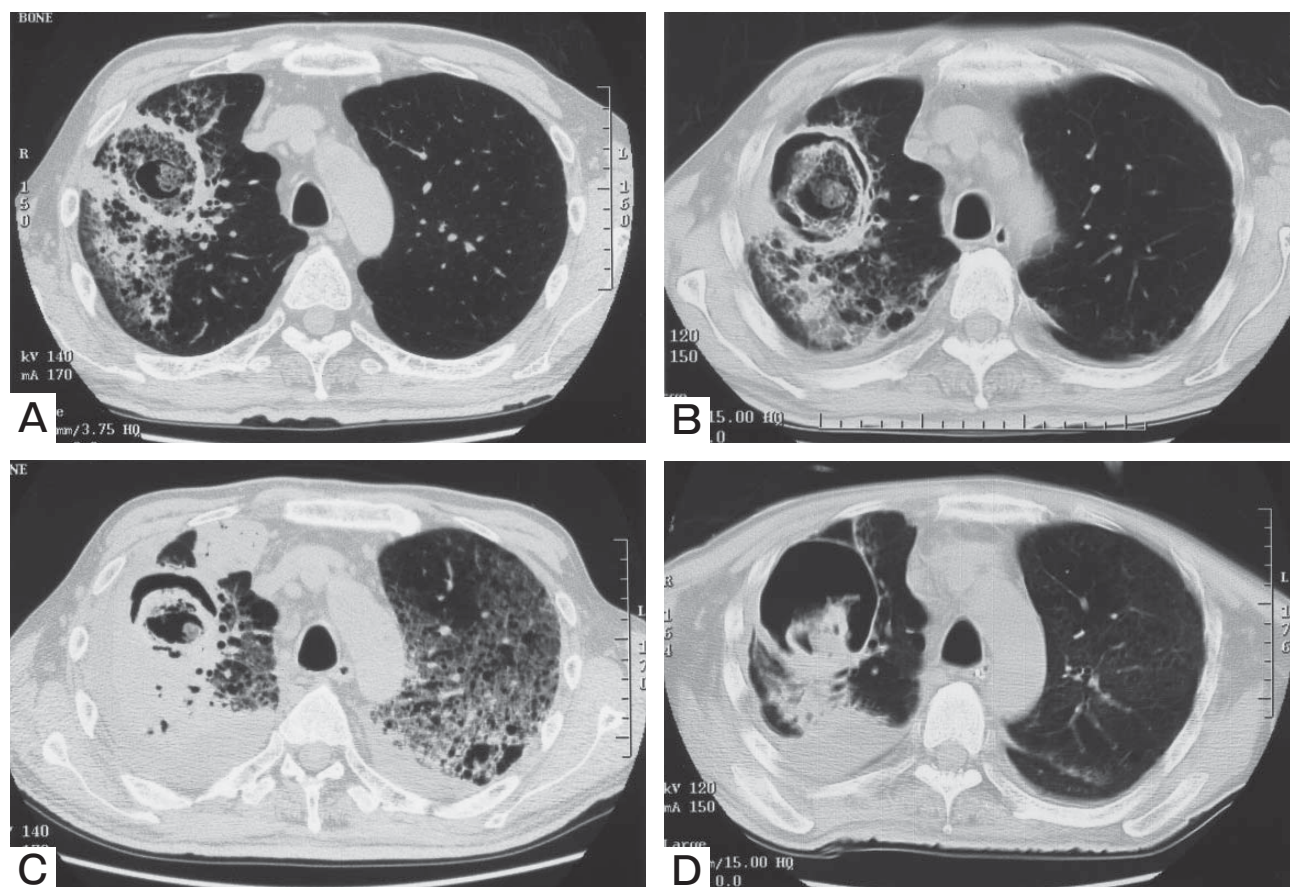


Fig. 1 Chest CT scan showing cystic lesions and alveolo-interstitial infiltrates (A), air-space consolidation with air crescent sign and ground glass attenuation after 10 days (B), rapid progression of pulmonary infiltrates after 14 days (C), and a thick-walled cavitary lesion suggestive of aspergilloma after 31 days (D).

August 2007

Pulmonary Aspergillosis and Pneumocystis Pneumonia 237

150 mg/day was started, because it was unclear whether the pulmonary infection was secondary to invasive pulmonary aspergillosis.

On hospital day 10, the patient was still febrile, and a chest CT revealed air-space consolidation with air crescent sign (Fig. 1B). Micafungin was discontinued, and voriconazol was started. On hospital day 14, the patient had persistent fever, dyspnea, and hypoxemia (PaO₂:50 mmHg, measured with nasal oxygen 5 L/min). Chest radiographic findings revealed rapid progression of pulmonary infiltrates (Fig. 1C). He developed an acute respiratory distress syndrome requiring mechanical ventilation and was transferred to the intensive care unit (ICU).

Voriconazol 300 mg/day was continued, and an intravenous corticosteroid (methylprednisolone 1.0 g/day) was started. Transbronchial lung biopsy revealed necrotizing pneumonitis and numerous fungal hyphae. Septate fungal hyphae were identified extending into normal lung parenchyma. *Aspergillus fumigatus* was isolated from a fungal culture of lung tissue. Moreover, the diagnosis of pneumocystis jiroveci was made by bronchoalveolar lavage (BAL). Combined IPA and PCP were diagnosed on hospital day 19. Thus, trimethoprim/sulfamethoxazole 1,200 mg/day and an adjunctive corticosteroid (prednisolone 40 mg/day) were initiated.

On hospital day 31, chest CT revealed aspergilloma formation with a thin-walled cavity and improvement of pulmonary infiltrates (Fig. 1D), but the patient continued to require intubation. His condition deteriorated, and laboratory tests revealed the following: creatinine, 3.5 mg/dl; urea nitrogen, 79 mg/dl; white blood cell count, 22,000/ μ l, and C-reactive protein, 22.1 mg/dl. On hospital day 58, the patient died of multiple organ failure and sepsis. His family declined permission for a post-mortem examination.

Discussion

The patient received short-term low doses of a steroid, although brain metastasis due to renal cell carcinoma was controlled by the surgical resection and whole brain radiation therapy. He was a non-HIV and cancer patient with COPD, but there was no evidence of recurrence other than the brain tumor. In the present case, therefore, the major predisposing factors for IPA and PCP were considered to be steroid therapy.

Rello *et al.* described rapid progression of IPA in patients with COPD receiving low doses or a brief course of steroid therapy [4]. Cornet *et al.* described that short-term systemic corticosteroid therapy in immunocompetent patients with underlying chronic lung conditions was a risk factor for IPA and, furthermore, for its rapid evolution [5]. The number of cases reported among patients receiving brief steroid therapy has recently increased as awareness of the increased risk of IPA in these patients has grown [4, 5].

In a retrospective analysis of the Mayo Clinic Rochester medical record registry [3], among 30 patients with acute respiratory failure due to non-HIV-related PCP, 8 patients had received systemic corticosteroids only and 15 had received a combination of both corticosteroids and chemotherapy. The median prednisone-equivalent dose and duration of corticosteroid use prior to diagnosis of PCP was 40 mg (range, 5 to 200 mg) and 4.5 months (range, 12 days to 25 months), respectively. Hematologic malignancies, inflammatory diseases, and solid malignancies were the primary diagnoses present in the majority of patients, accounting for 90% of the underlying immunosuppressive conditions. No patient was receiving prophylactic medications for PCP prior to the onset of pneumonia. In addition to pneumocystis, aspergillus was detected in 2 of the 30 patients but was deemed to be secondary to microorganism colonization or a latent infection rather than an active disease. Twenty-nine of the 30 patients required intubation, and 20 patients did not survive to discharge from the hospital, yielding a mortality of 66.6%. The authors concluded that the delay in intubation on admission to the ICU was associated with a higher hospital mortality rate and that PCP prophylaxis should be strongly considered for all non-HIV immunosuppressed patients receiving prolonged systemic corticosteroid therapy.

Coinfection with aspergillus and pneumocystis jiroveci has been reported as a nosocomial complication in patients admitted to the ICU [1, 3]. In the present case, both proven invasive microorganisms were community acquired. However, it was unclear whether pulmonary infection by aspergillus occurred prior to pneumocystis jiroveci. The radiographic evaluation revealed pulmonary aspergillosis; however, it was difficult to make the radiographic diagnosis of com-

bined IPA and PCP. Early bronchoscopy with BAL should be considered in order to diagnose these opportunistic infections promptly.

Our case demonstrated that short-term systemic steroid therapy in non-HIV patients with underlying chronic lung conditions and malignancies was a risk factor for IPA and PCP, and for a combination of these infections. In such patients, physicians should be alert to the fact that a high degree of suspicion is necessary for the diagnosis of these opportunistic infections.

Conflicts of interest statement. All of the authors declare that we have no financial or personal relationships with other people or organisations that could inappropriately influence our work.

References

1. Marinosa M, Soler A, Nogues X and Pedro-Botet J: Pulmonary coinfection by pneumocystis carinii and aspergillus fumigatus in a seronegative arthritis patient treated with low-dose methotrexate. *Clin Rheumatol* (2004) 23: 555–556.
2. Kenney HH, Agrons GA and Shin JS: Invasive pulmonary aspergillosis: radiologic and pathologic findings. *Radiographics* (2002) 22: 1507–1510.
3. Festic E, Gajic O, Limper AH and Aksamit TR: Acute respiratory failure due to pneumocystis pneumonia in patients without human immunodeficiency virus infection: outcome and associated features. *Chest* (2005) 128: 573–579.
4. Rello J, Esandi ME, Mariscal D, Gallego M, Domingo C and Valles J: Invasive pulmonary aspergillosis in patients with chronic obstructive pulmonary disease: report of eight cases and review. *Clin Infect Dis* (1998) 26: 1473–1475.
5. Cornet M, Mallat H, Somme D, Guerot E, Kac G, Mainardi L, Fornes P, Gutmann L and Lavarde V: Fulminant invasive pulmonary aspergillosis in immunocompetent patients—a two-case report. *Clin Microbiol Infect* (2003) 9: 1224–1227.