

Case Report

Chiari Malformation with Thick Occipital Bone

Takao Yasuhara*, Yasuyuki Miyoshi, and Isao Date

*Department of Neurological Surgery, Okayama University Graduate School of Medicine,
Dentistry and Pharmaceutical Sciences, Okayama 700-8558, Japan*

A case of a Chiari malformation with an extraordinarily thick occipital bone is described. The thick occipital bone might make the posterior fossa narrow with consequent herniation of the cerebellar tonsils to the foramen magnum and formation of a syrinx. At dural plasty, well-developed marginal and occipital sinuses should be deliberately handled with the preservation of normal venous drainage. This case gives us the essence of the occurrence mechanisms of Chiari malformation and foramen magnum decompression.

Key words: Chiari malformation, dural plasty, foramen magnum decompression, syrinx, venous drainage

Chiari malformation (CM) is characterized by herniation of the cerebellar tonsils into the foramen magnum, usually associated with syrinx formation [1]. Foramen magnum decompression (FMD) with C1 laminectomy is useful, although there is controversy regarding the necessity of dural plasty and other surgical techniques [2, 3]. In this manuscript a rare case of CM with an extraordinarily thick occipital bone is shown, along with what it demonstrates about the essence of CM treatment.

Case Report

A 34-year-old woman presented with progressive pain at the right flank, left hemiparesis and numbness over the course of 18 years. She was diagnosed with CM at age 16, but since the risks of surgical treatment were considered very high, she was treated medically. She visited a primary care doctor with severe pain in her right flank in September, 2009 and

was referred to our clinic. In addition to the pain, she presented with left hemiparesis (hand grip: right 21, left 16 kg), numbness, dysdiadochokinesia and left side-dominant muscular atrophy of her hands. The tendon reflex of her lower limbs was elevated, but her gait was normal. She had no abnormality in biochemical exams, psychomotor development and other skeletal/visceral structures, except for mild scoliosis and occipital-dominant hyperostosis (Fig. 1A, B). Magnetic resonance imaging (MRI) revealed CM with a large syrinx from the lower medulla oblongata to the lower thoracic spine (Fig. 1C, D). Enhanced computed tomography (CT) clarified a thick occipital bone and narrow posterior fossa with fully developed marginal and occipital sinuses (Fig. 1E). We thought that surgery should be considered, although the thick bone (30-mm-thick) and developed sinuses introduced high risks. FMD with C1 laminectomy was performed. At surgery, the occipital bone was so thick that the perforator drill stalled in the midst of the cancellous bone. We used high-speed drills to achieve FMD and C1 laminectomy. Intense bleeding occurred from the cancellous bone and emissary veins. We used bone wax to stop the bleeding keeping in mind that too much

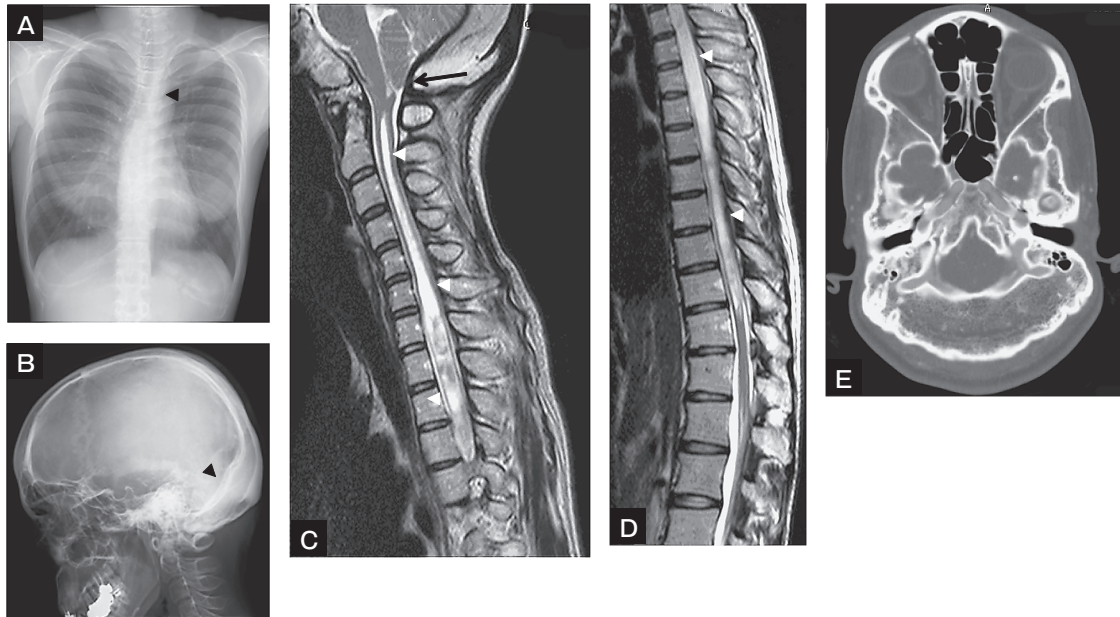


Fig. 1 Neuroradiological images demonstrating CM with thick occipital bone. Chest X-ray demonstrated mild scoliosis (arrowhead, **A**). A lateral view of the skull X-ray demonstrated hyperostosis of the cranium, especially at the occiput (arrowhead, **B**). T2-weighted images on MRI clarified the herniation of tonsils (black arrow) and syrinx formation (white arrowheads, **C**, **D**). Enhanced CT demonstrated well-developed marginal and occipital sinuses with a narrow posterior fossa due to an extraordinarily thick occipital bone (**E**).

bone wax should be avoided to preserve normal venous drainage to the jugular vein. A left side-deviated linear incision of the dura with hemoclips was used to minimize bleeding from the marginal and occipital sinuses. Subsequently, a dural plasty was made with a spindle-shaped GoreTex[®] sheet. Immediately after the surgery, the pain in her right flank disappeared. Gradually, the numbness of her left extremities decreased to around half the level before surgery, and the unequal motor function of upper limbs slightly ameliorated (hand grip: right 22, left 18 kg at 7 days after the surgery) with no change in the elevated tendon reflex of her lower limbs. MRI obtained 7 days after the surgery revealed a reduction of the syrinx size with an enlarged posterior fossa (Fig. 2A, B). CT demonstrated that the area of the FMD was adequate with preservation of normal venous drainage (Fig. 2C, D). The removed bone was pathologically diagnosed as normal bone tissue. She was discharged 8 days after surgery and followed as an outpatient. Her symptoms have been improving for over 6 months with the reduction of the syrinx size (Fig. 2E, F).

Discussion

CM with a thick occipital bone has rarely been reported. We found a few cases in the literature of craniometaphyseal dysplasia (CMD), which is a rare genetic disorder characterized by cranial bone hyperostosis and deformity of the metaphyses of the long bones [4-6]. CMD might occur sporadically, although it is usually divided into 2 major types, autosomal dominant and recessive. Craniofacial abnormalities are prominent: namely frontonasal bossing, prognathous mandible and hypertelorism. In our case, the patient had no systemic disorders and lacked the typical features of CMD, although the posterior fossa was congenitally narrow with a thick occipital bone. One of the occurrence mechanisms of CM is obliteration of the subarachnoid space by herniated cerebellar tonsils at the foramen magnum with consequent functional separation between cranial and spinal compartments and syrinx formation [1]. As for CM with craniosynostosis, a disproportion between the hindbrain growth and the narrow posterior fossa might be one of the critical causes [7]. In our case, the absolutely narrow posterior fossa by extraordinarily thick

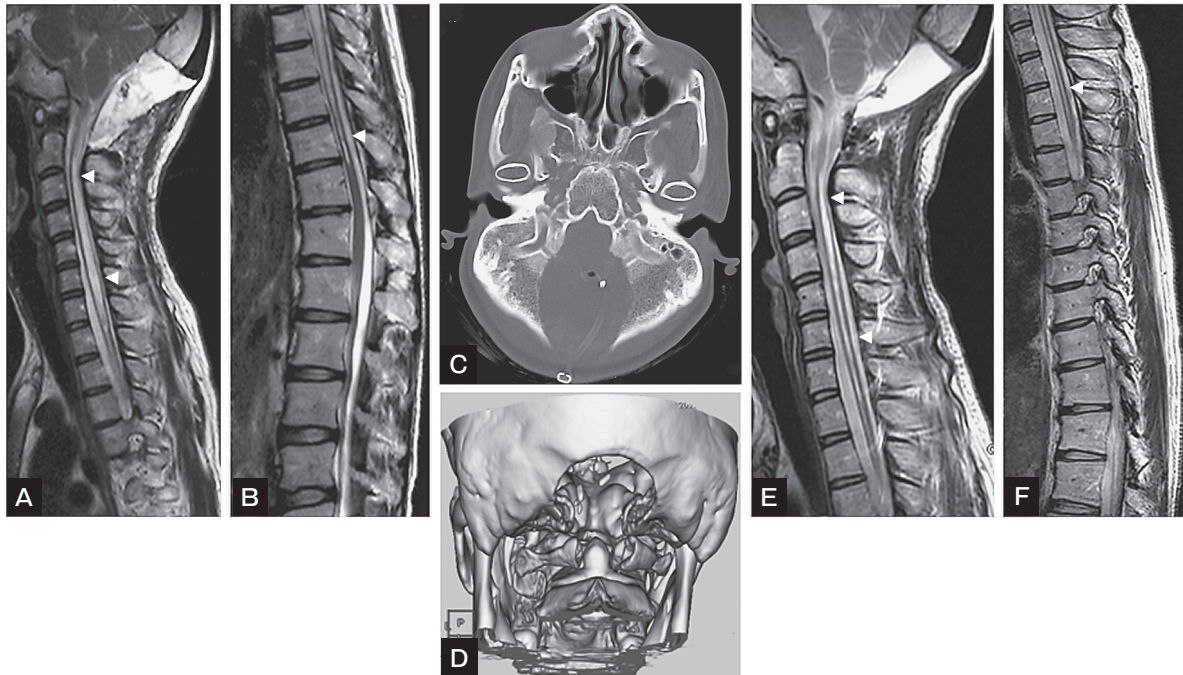


Fig. 2 Postoperative neuroradiological images T2-weighted images on MRI demonstrated shrinkage of the syrinx at 7 days and 3 months after the surgery (arrowheads, **A, B & E, F**). Plain CT revealed that the normal venous drainage through the jugular foramen was preserved (**C**). 3D-CT showed the area of the FMD and C1 laminectomy (**D**).

occipital bone might lead to the herniation of tonsils with subsequent syrinx formation. Additionally, at the dural plasty, damage to the venous drainage can sometimes cause catastrophic results including acute brain swelling due to venous congestion [8]. In our case, the bilateral jugular foramen was connected with the developed marginal sinus. We paid close attention to the preservation of normal venous drainage and minimization of sinus damage by the left side-deviated linear dural incision, preserving the occipital and right marginal sinuses. In conclusion, this case gives us suggestions about the occurrence mechanisms of CM including a narrow posterior fossa and the importance of venous drainage preservation at surgery to prevent venous congestion.

References

1. Novegno F, Caldarelli M, Massa A, Chieffo D, Massimi L, Pettorini B, Tamburrini G and Di Rocco C: The natural history of the Chiari Type I anomaly. *J Neurosurg Pediatr* (1973) 2: 179-187.
2. Caldarelli M, Novegno F, Vassimi L, Romani R, Tamburrini G and Di Rocco C: The role of limited posterior fossa craniectomy in the surgical treatment of Chiari malformation Type I: experience with a pediatric series. *J Neurosurg* (2007) 106(3 Suppl): 187-195.
3. McGirt MJ, Attenello FJ, Dato G, Gathinji M, Atiba A, Weingart JD, Carson B and Jallo GI: Intraoperative ultrasonography as a guide to patient selection for duraplasty after suboccipital decompression in children with Chiari malformation Type I. *J Neurosurg Pediatr* (2008) 2: 52-57.
4. Cai C, Zhang Q, Shen C, Sun G and Wang C: Chiari malformation caused by craniometaphyseal dysplasia: case report and review of literature. *Eur J Pediatr Surg* (2008) 18: 198-201.
5. Day RA, Park TS, Ojemann JG and Kaufman BA: Foramen magnum decompression for cervicomedullary encroachment in craniometaphyseal dysplasia: case report. *Neurosurg* (1997) 41: 960-964.
6. Sewell MD, Akram H and Wadlay J: Foramen magnum decompression and expansile duroplasty for acquired Chiari type I malformation in craniometaphyseal dysplasia. *Br J Neurosurg* (2008) 22: 83-85.
7. Cinalli G, Spennato P, Sainte-Rose C, Arnaud E, Aliberti F, Brunelle F, Cianciulli E and Renier D: Chiari malformation in craniosynostosis. *Childs Nerv Syst* (2005) 21: 889-901.
8. Sandberg DI, Navarro R, Blanch J and Ragheb J: Anomalous venous drainage preventing safe posterior fossa decompression in patients with chiari malformation type I and multisutural craniosynostosis. Report of two cases and review of the literature. *J Neurosurg* (2007) 106(6 Suppl): 490-494.