

# *Acta Medica Okayama*

---

*Volume 64, Issue 3*

2010

*Article 5*

JUNE 2010

---

## Infant Hip Joint Diagnostic Support System Based on Clinical Manifestations in X-ray Images

Mitsugi Honda\*

Seizaburo Arita<sup>†</sup>

Shigeru Mitani<sup>‡</sup>

Yoshihiro Takeda\*\*

Toshifumi Ozaki<sup>††</sup>

Keiji Inamura<sup>‡‡</sup>

Susumu Kanazawa<sup>§</sup>

\*Radiological Technology, Graduate School of Health Sciences, Okayama University,

<sup>†</sup>Faculty of Life and Medical Sciences, Doshisha University,

<sup>‡</sup>Department of Bone and Joint Surgery, Kawasaki Medical School,

\*\*Radiological Technology, Graduate School of Health Sciences, Okayama University,

<sup>††</sup>Department of Orthopaedic Surgery, Okayama University Graduate School of Medicine, Dentistry and Pharmaceutical Sciences,

<sup>‡‡</sup>Central Division of Radiology, Okayama University Hospital,

<sup>§</sup>Department of Radiology, Okayama University Graduate School of Medicine, Dentistry and Pharmaceutical Sciences,

Copyright ©1999 OKAYAMA UNIVERSITY MEDICAL SCHOOL. All rights reserved.

# Infant Hip Joint Diagnostic Support System Based on Clinical Manifestations in X-ray Images

Mitsugi Honda, Seizaburo Arita, Shigeru Mitani, Yoshihiro Takeda, Toshifumi Ozaki, Keiji Inamura, and Susumu Kanazawa

## Abstract

Plain X-ray radiography is frequently used for the diagnosis of developmental dislocation of the hip (DDH). The aim of this study was to construct a diagnostic support system for DDH based on clinical findings obtained from the X-ray images of 154 female infants with confirmed diagnoses made by orthopedists. The data for these subjects were divided into 2 groups. The Min-Max method of nonlinear analysis was applied to the data from Group 1 to construct the diagnostic support system based on the measurement of 4 items in X-ray images: the outward displacement rate, upward displacement rate, OE angle, and alpha angle. This system was then applied to the data from Group 2, and the results were compared between the 2 groups to verify the reliability of the system. We obtained good results that matched the confirmed diagnoses of orthopedists with an accuracy of 85.9%.

**KEYWORDS:** X-ray image, developmental dislocation of the hip, acetabular dysplasia, nonlinear multivariate analysis, infant hip joint diagnostic support system

Original Article

## Infant Hip Joint Diagnostic Support System Based on Clinical Manifestations in X-ray Images

Mitsugi Honda<sup>a,e,\*</sup>, Seizaburo Arita<sup>b</sup>, Shigeru Mitani<sup>c</sup>, Yoshihiro Takeda<sup>a</sup>,  
Toshifumi Ozaki<sup>d</sup>, Keiji Inamura<sup>e</sup>, and Susumu Kanazawa<sup>f</sup>

<sup>a</sup>Radiological Technology, Graduate School of Health Sciences, Okayama University,

Departments of <sup>d</sup>Orthopaedic Surgery, and <sup>f</sup>Radiology, Okayama University Graduate School of Medicine,  
Dentistry and Pharmaceutical Sciences, <sup>e</sup>Central Division of Radiology, Okayama University Hospital, Okayama 700-8558, Japan,

<sup>b</sup>Faculty of Life and Medical Sciences, Doshisha University, Kyotanabe, Kyoto 610-0394, Japan,

<sup>c</sup>Department of Bone and Joint Surgery, Kawasaki Medical School, Kurashiki, Okayama 701-0192, Japan

Plain X-ray radiography is frequently used for the diagnosis of developmental dislocation of the hip (DDH). The aim of this study was to construct a diagnostic support system for DDH based on clinical findings obtained from the X-ray images of 154 female infants with confirmed diagnoses made by orthopedists. The data for these subjects were divided into 2 groups. The Min-Max method of nonlinear analysis was applied to the data from Group 1 to construct the diagnostic support system based on the measurement of 4 items in X-ray images: the outward displacement rate, upward displacement rate, OE angle, and  $\alpha$  angle. This system was then applied to the data from Group 2, and the results were compared between the 2 groups to verify the reliability of the system. We obtained good results that matched the confirmed diagnoses of orthopedists with an accuracy of 85.9%.

**Key words:** X-ray image, developmental dislocation of the hip, acetabular dysplasia, nonlinear multivariate analysis, infant hip joint diagnostic support system

**D**evelopmental dislocation of the hip (DDH) is the most common cause of coxarthrosis and accounts for more than 80% of the cases in Japan. Complete recovery from DDH by the initiation of treatment at an early stage is preferable; otherwise, coxarthrosis can develop with aging, and concomitant progressive pain and dysbasia can affect patients and limit their daily activities. When symptoms progress further, surgical treatment such as arthroplasty is necessary. As the mean life expectancy of the world population continues to increase, coxarthrosis is

becoming an increasingly important issue.

The severity of DDH is likely to be reduced by the use of a Pavlik harness within 6 months after birth, and use of such a harness can lead to improved hip joint morphology after infancy, which demonstrates the significance of early diagnosis [1-4].

Ultrasonography and MRI have recently been used for the diagnosis of DDH, but the simplest system, plain X-ray radiography, is the most commonly used [5-8]. However, the hip joints of early infants are mostly comprised of cartilage, and thus the interpretation of images remains difficult until the ossification center of the proximal femoral epiphysis appears at about 6 months after birth, presenting a difficulty for the orthopedists involved [9-11]. Although many

Received October 28, 2009; accepted December 17, 2009.

\*Corresponding author. Phone: +81-86-223-7151; Fax: +81-86-235-7723

E-mail: mhonda@hp.okayama-u.ac.jp (M. Honda)

measurement indices of X-ray images of the hip joint have been reported, there are no clear differential diagnostic criteria between DDH and subluxation of the hip (SDH) or between SDH and acetabular dysplasia, and orthopedists are currently required to make a subjective diagnosis. Since the incidence of these cases has decreased, orthopedists do not experience a sufficient number of cases to ensure a high level of accuracy in X-ray radiographic diagnosis [9].

Therefore, we have attempted to develop an infant hip joint diagnostic support system employing nonlinear multivariate analysis based on multivariate clinical findings from X-ray radiography, such as displacement of the proximal metaphysis of the femur and the degree of acetabular formation.

### Patients and Methods

Plain X-ray images of the bilateral hip joints of 154 female infants aged 3–6 months obtained at Okayama University Hospital between 1963 and 1995 were examined. There were 28 infants with DDH, 44 with SDH, 55 with acetabular dysplasia, and 27 with normal joints. The original data (154 subjects) were classified into 2 groups: Group 1 (76 subjects) for system construction and Group 2 (78 subjects) for application of the system. The assignment of subjects into groups was random.

Confirmed diagnoses were made by orthopedists on the basis of clinical examinations, such as click tests, X-ray images, and soft tissue analysis using ultrasonography or hip joint arthrography.

The diagnostic support system measures 4 items that correspond to 4 diagnoses: DDH, SDH, acetabular dysplasia, and normal state. For the construction of the system, we employed the Min-Max method of nonlinear multivariate analysis. We constructed the system using the data from Group 1, applied the system to the data from Group 2, and compared the results between the 2 groups to verify the reliability of the system. We calculated the rate of agreement between the results obtained using the system and the confirmed diagnoses made by orthopedists. The statistical method of two-sample test for equality of proportions was used for analyzing the difference in the accuracy rate of the 2 groups. The significance level was set at  $\alpha = 0.05$ .

This study was approved by the Ethics Committee

of Okayama University Graduate School of Medicine, Dentistry and Pharmaceutical Sciences.

**Measurement of 4 items.** For the interpretation of plain X-ray images of the bilateral hip joint, the position of the proximal metaphysis of the femur was observed relative to the dislocation and the acetabular developmental condition. For the discrimination of DDH on the basis of clinical findings from X-ray images, we employed the measurement of 4 items: outward displacement rate, upward displacement rate, OE angle, and  $\alpha$  angle.

**Outward displacement rate ( $a/R$ ) and upward displacement rate ( $b/R$ ).** The line passing through the lowest iliac ends in contact with the bilateral triradiate cartilages in Fig. 1 is regarded as the X axis, and the line oriented perpendicularly to the X axis drawn from the lowest iliac end is the Y axis. The coordinates of the middle point of the proximal metaphyseal border of the femur from the point of intersection, (a) and (b), were measured [12, 13]. A hypothetical vertical line was drawn from the middle point of the pubic symphysis to the X axis, and the distance (R) between the point of intersection and the lowest iliac end on the affected side was determined.

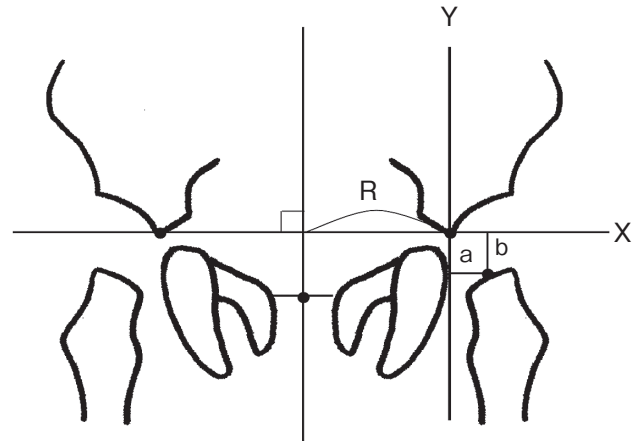


Fig. 1 Determination of the outward and upward displacement rates. The X axis is a line connecting the lowest iliac ends in contact with the bilateral triradiate cartilages. The Y axis is a vertical line drawn from the lowest iliac end to the X axis. The coordinates of the middle point of the proximal metaphyseal border of the femur from the point of intersection of the X and Y axes were designated a and b. A vertical line was drawn from the middle point of the pubic symphysis to the X axis, and the distance between the point of intersection and the lowest iliac end on the affected side was designated R.

The outward displacement rate was measured as (a/R). The upward displacement rate was measured as (b/R).

**OE angle.** The angle formed by a line connecting the middle point of the proximal metaphyseal border of the femur and the lateral edge of the acetabulum and a vertical line drawn from the X axis to the middle point of the proximal metaphyseal border of the femur was designated as the OE angle (Fig. 2) [14].

**$\alpha$  angle.** The angle formed by a line connecting the lowest iliac end and the lateral edge of the acetabulum and the X axis was designated as the  $\alpha$  angle (Fig. 3) [13, 14].

**Rationale of the diagnostic support system.**

We developed a diagnostic support system for infant hip joints by using a nonlinear multivariate analysis based on clinical findings obtained from X-ray images and diseases (Fig. 4). Multivariate analyses are used for the statistical analysis of multivariate data, and are either linear or nonlinear. Discriminant analysis [15, 16] is one of the types of linear multivariate analysis, while types of nonlinear multivariate analysis include the fuzzy theory [17-22] and the neural network theory [23, 24].

We employed a nonlinear multivariate analysis of the Min-Max method with attribute probability functions to produce the diagnostic support system.

**Attribute probability function.** We con-

structed attribute probability functions for 4 groups — the DDH ( $Y_1$ ), SDH ( $Y_2$ ), acetabular dysplasia ( $Y_3$ ), and normal case ( $Y_4$ ) groups — based on the distribution of data for 4 items: the outward displacement rate ( $X_1$ ), upward displacement rate ( $X_2$ ), OE angle ( $X_3$ ), and  $\alpha$  angle ( $X_4$ ). These functions correspond to membership functions [17, 20-22] of the fuzzy theory. We optimized the functions to maximize the accuracy of the simulation. The distribution of the attribute probability function of the OE angle is shown as an example in Fig. 5.

**Min-Max method.** For the diagnostic support system, all possible pairings were made using 2 of the 4 items (the outward displacement rate ( $X_1$ ), upward displacement rate ( $X_2$ ), OE angle ( $X_3$ ), and  $\alpha$  angle ( $X_4$ )), resulting in the 6 combinations ( $X_1, X_2$ ), ( $X_1, X_3$ ), ..., ( $X_3, X_4$ ). The attribute probabilities for each disease from the combinations were determined using the Min-Max method.

We designated the attribute probability function to find  $X_i$  as  $f(X_i)$ , and the attribute probability for disease  $Y$  as  $P_i$ , where

$$P_i = f(X_i).$$

We described the attribute probabilities of diseases (A, B, C, D) based on ( $X_i, X_j$ ) of the 4 variates ( $X_1, X_2, X_3, X_4$ ) as  $P_A, P_B, P_C,$  and  $P_D$ , respectively. The attribute probability  $P_A$  for disease A is formulated as follows:

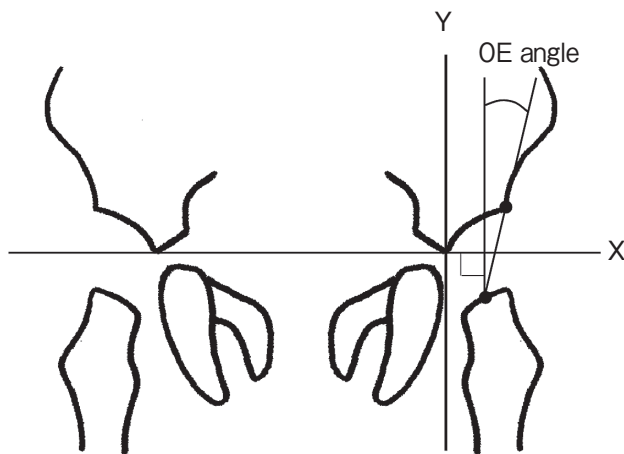


Fig. 2 Measurement of the OE angle. The OE angle is formed by a line connecting the middle point of the proximal metaphyseal border of the femur and the lateral edge of the acetabulum and a vertical line drawn from the X axis to the middle point of the proximal metaphyseal border of the femur.

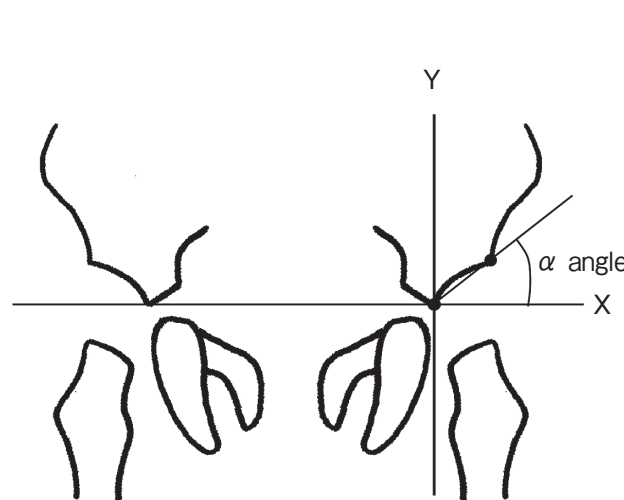
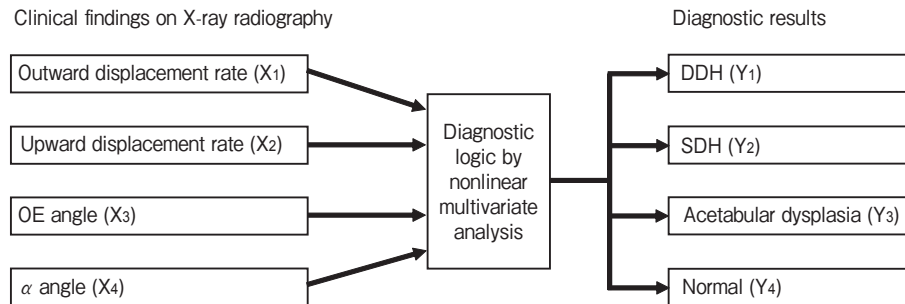
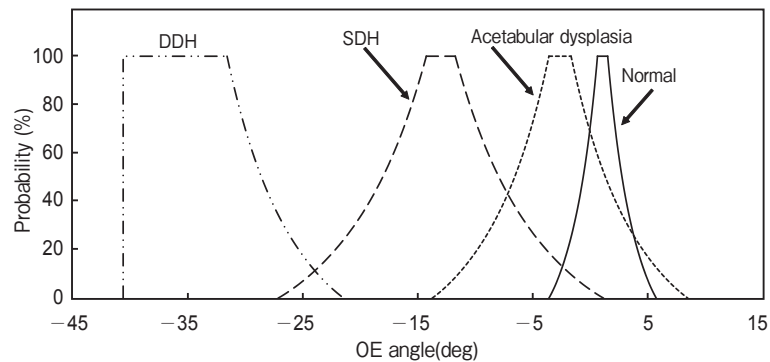


Fig. 3 Measurement of the  $\alpha$  angle. The  $\alpha$  angle is formed by a line connecting the lowest iliac end and the lateral edge of the acetabulum and the X axis.



**Fig. 4** Diagnostic support system for DDH, SDH, Acetabular dysplasia, and Normal state. The diagnostic support system relates the outward displacement rate ( $X_1$ ), upward displacement rate ( $X_2$ ), OE angle ( $X_3$ ), and  $\alpha$  angle ( $X_4$ ) to the diagnostic results: DDH ( $Y_1$ ), SDH ( $Y_2$ ), acetabular dysplasia ( $Y_3$ ), or a normal hip joint ( $Y_4$ ). To assess these, multivariate analysis was performed regarding the clinical findings ( $X_1$ - $X_4$ ) as input data and diagnostic results ( $Y_1$ - $Y_4$ ) as output data.



**Fig. 5** Attribute probability function of the OE angle. The distribution of the attribute probability function of the OE angle for the disease groups is presented.

$$P_A = \text{Max} \{ \text{Min} (P_1, P_2), \text{Min} (P_1, P_3), \dots, \text{Min} (P_i, P_j), \dots, \text{Min} (P_3, P_4) \}.$$

In this Min-Max method, the minimum values (Min) for the two-item combination of ( $P_i, P_j$ ) were calculated, and the maximum value (Max) among the 6 probabilities was determined as the probability of exhibiting the disease. We designated the final judgment of the attribution based on the variates ( $X_1, X_2, X_3, X_4$ ) as  $Y$ , where

$$Y = \text{Max} (P_A, P_B, P_C, P_D).$$

## Results

By applying this diagnostic support system to the data for the 78 subjects in Group 2, we obtained the results of classification and recorded their agreement with the confirmed diagnoses made by orthopedists, as shown in Table 1. The rate of agreement with the confirmed diagnoses by orthopedists was designated

the accuracy rate. Overall, the accuracy rate of the diagnostic support system was 85.9% ( $(14 + 19 + 23 + 11)/78$ ).

Table 1 also shows that the system diagnosed DDH in 14 of 14 cases, SDH in 19 of 22, acetabular dysplasia in 23 of 28, and a normal state in 11 of 14. Moreover, the accuracy rate for DDH and SDH with this system was 91.7% ( $(14 + 19)/(14 + 22)$ ).

**Misdiagnosis.** This system showed that 14.1% ( $(3 + 4 + 1 + 3)/78$ ) of cases were misdiagnosed in Table 1. Specifically, 3 SDH cases were misdiagnosed as cases of acetabular dysplasia, 5 acetabular dysplasia cases were misdiagnosed as either SDH (4 cases) and or a normal state (1 case), and 3 cases of a normal state were misdiagnosed as acetabular dysplasia.

**System verification.** We also examined the reliability of the system by comparing the accuracy rates for Group 1 (the data used for system construc-

**Table 1** Results of the diagnostic support system employing the Min-Max method

Case	Results of diagnostic support employing the Min-Max method				Total
	DDH	SDH	Acetabular dysplasia	Normal	
DDH	14	0	0	0	14
SDH	0	19	3	0	22
Acetabular dysplasia	0	4	23	1	28
Normal	0	0	3	11	14
Total	14	23	29	12	78

**Table 2** Cases misdiagnosed by the systems employing Min-Max and discriminant analysis

Case	No.	Min-Max system		Discriminant analysis system	
SDH	19	Acetabular dysplasia	×	Acetabular dysplasia	×
SDH	26	Acetabular dysplasia	×	Acetabular dysplasia	×
SDH	28	Acetabular dysplasia	×	Acetabular dysplasia	×
SDH	27	SDH	○	Acetabular dysplasia	×
Acetabular dysplasia	45	SDH	×	SDH	×
Acetabular dysplasia	46	SDH	×	SDH	×
Acetabular dysplasia	57	SDH	×	SDH	×
Acetabular dysplasia	55	Normal	×	Normal	×
Acetabular dysplasia	59	SDH	×	Acetabular dysplasia	○
Acetabular dysplasia	52	Acetabular dysplasia	○	SDH	×
Acetabular dysplasia	49	Acetabular dysplasia	○	Normal	×
Acetabular dysplasia	60	Acetabular dysplasia	○	Normal	×
Acetabular dysplasia	63	Acetabular dysplasia	○	Normal	×
Acetabular dysplasia	64	Acetabular dysplasia	○	Normal	×
Normal	75	Acetabular dysplasia	×	Acetabular dysplasia	×
Normal	72	Acetabular dysplasia	×	Normal	○
Normal	76	Acetabular dysplasia	×	Normal	○
Total: 17 cases		×		×	

Misdiagnoses made by the systems employing the Min-Max method and discriminant analysis. An “×” indicates an inconsistent case, and an “○” illustrates a consistent case.

tion) and Group 2 (the data used for application of the system). The accuracy rate for Group 1 was 89.5% (68/76) and that for Group 2 was 85.9% (67/78), with no significant difference between the groups ( $p = 0.499 > 0.05$ ). This demonstrated the reliability of the infant hip joint diagnostic support system.

#### **System employing discriminant analysis.**

The diagnostic support system employing discriminant analysis, a method of linear multivariate analysis, was applied to the data of Group 2. The accuracy rate using this system was 82.1% (64/78). The accuracy rate achieved with the system employing discriminant

analysis and that achieved with the system using the Min-Max method were compared using two-sample test for equality of proportions, but no significant difference was observed ( $p = 0.512 > 0.05$ ).

**Inconsistent cases.** We demonstrated the cases in which the diagnoses made by the 2 systems (the system using the Min-Max method and the system using discriminant analysis) were inconsistent with those made by orthopedists, as shown in Table 2. Both systems misdiagnosed some cases of SDH, some cases of acetabular dysplasia, and some cases of normal state.



## Discussion

We measured the outward and upward displacement rates and OE and  $\alpha$  angles on plain X-ray images of the bilateral hip joints of infants that had been definitely diagnosed with DDH, SDH, acetabular dysplasia, or a normal hip joint, and developed an infant hip joint diagnostic support system based on these measurements employing the Min-Max method of nonlinear multivariate analysis. The diagnostic accuracy rate by the Min-Max method was 85.9%. Otherwise, the results in Table 1 showed that there was an inconsistency between the diagnoses by orthopedists and those by the diagnostic support system.

In the therapeutic policy of Okayama University Hospital for infants aged 3–6 months, a Pavlik harness should be applied for 3 months in cases of SDH in which the concentricity of the hip joint has been slightly lost depending on the position, and for 4 months in cases of DDH in which the joint is completely dislocated regardless of the position. For acetabular dysplasia without dislocation, orthotic treatment is not applied, and only guidance in daily activities is provided. Therefore, the identification of DDH and SDH for orthotic treatment is important, and the accuracy rate for these diseases was 91.7%, which is a favorable result.

The percentage of cases misdiagnosed by the Min-Max method was 14.1% (11/78) and that by discriminant analysis was 17.9% (14/78). In Table 2, the number of inconsistent cases marked “×” by the Min-Max method was 11 and that by discriminant analysis was 14 for 17 inconsistent cases which were misdiagnosed by one system or both systems.

Table 2 also shows the classification of inconsistent cases from the point of view of SDH cases, acetabular dysplasia cases, and normal cases. Among the 22 SDH cases, 3 cases were misdiagnosed as acetabular dysplasia by both the system using the Min-Max method and that using discriminant analysis. Moreover, the 4 SDH cases were misdiagnosed as acetabular dysplasia by discriminant analysis. Among the 28 acetabular dysplasia cases, 4 were misdiagnosed by both systems. The Min-Max method misdiagnosed 5 acetabular dysplasia cases, while the discriminant analysis misdiagnosed 9 acetabular dysplasia cases. With respect to the 14 normal cases, however, the Min-Max method misdiagnosed 3 normal cases as

cases of acetabular dysplasia, while discriminant analysis misdiagnosed only 1 normal case.

There are several possible causes of these joint misdiagnoses by both systems. First, fluctuation in the measurement data influences the systems. Since the 3-dimensional structures are shown in 2 dimensions in X-ray images, positioning-induced changes in the concentricity cause fluctuations of the data. For example, movement of the proximal metaphysis of the femur toward the acetabulum improves the concentricity in X-ray radiography [25, 26]. Secondly, there are no distinct diagnostic criteria for SDH and acetabular dysplasia using X-ray images of the hip joint [9]. Thirdly, about 90% of cases of DDH and SDH are complicated by acetabular dysplasia, which makes diagnosis difficult.

SDH is complicated by acetabular dysplasia in many cases. Moreover, internal rotation induced by abduction of the leg during the positioning for X-ray imaging moves the proximal metaphysis of the femur toward the acetabulum and improves the concentricity, which may lead to misdiagnosis as acetabular dysplasia.

Acetabular dysplasia is complicated by SDH in many cases. Moreover, anteversion of the pelvis in X-ray radiography decreases the acetabular angle, reducing the degree of acetabular dysplasia, which may lead to misdiagnosis as SDH. Forced parallel positioning of the femoris in X-ray radiography leads to a loss of concentricity, which may also lead to misdiagnosis as SDH. In acetabular dysplasia, when the influence of the position is added to pelvic anteversion in X-ray radiography, the proximal metaphysis of the femur is moved toward the acetabulum, improving the concentricity, which may lead to misdiagnosis as a normal case.

In normal cases, pelvic retroversion induced by positioning for X-ray radiography widens the acetabular angle, which may lead to misdiagnosis as acetabular dysplasia.

In contrast, the diagnosis of DDH was 100% consistent with that made by orthopedists because in these cases the joint was completely dislocated in any position, and was thus independent from the positioning in X-ray radiography.

Therefore, close attention must be paid to the positioning of the hip joint in X-ray radiography. Since mild flexion contracture is present in most infants, forced extension of the hip joint causes pelvic



anteversion. Thus, mild abduction of the leg with flexion of the hip joint to a degree that does not cause pelvic anteversion is recommended [9]. The pelvis is likely to tilt laterally in the presence of limited flexion on abduction (frog-leg position), which should also be taken into consideration.

It is difficult to establish a diagnostic logic that outputs several groups from input data involving many items because of the complex interactions among the items, which results in a complex system. Since this complex system relies on data derived from multiple items and fluctuations within the items, the data distributions of the items are biased. We adopted the Min-Max method of nonlinear multivariate analysis to analyze the relationship between the input of many items and the multiple output, and developed a diagnostic logic based on the results of this analysis. One problem in regard to the diagnostic logic is that an attribute probability function has to be set for each disease using the data distribution. We optimized the attribute probability functions by computer simulation so as to maximize the accuracy using the data for system construction. However, no systematic method for this procedure has been established, and, as such, we are planning to design one.

Palpation, lateral differences in the femoral skin, and click signs on hip joint movement are taken into consideration for comprehensive diagnosis during actual clinical practice [27]. These items that are subjectively judged by orthopedists can be readily added to the diagnostic logic employing nonlinear multivariate analysis, and the addition of new input items may increase the accuracy. The development of an accurate diagnostic support system can improve the quality of imaging information and reduce the burden of X-ray imaging diagnosis of infant hip joints that is currently placed on orthopedists.

In conclusion, to support the diagnosis of hip joints in infants, we measured 4 items—the outward and upward displacement rates, and the OE and  $\alpha$  angles—in clinically obtained X-ray images of female infants of 3–6 months of age, and developed an infant hip joint diagnostic support system to diagnose DDH, SDH, acetabular dysplasia, or a normal hip joint, employing a newly designed Min-Max method of nonlinear multivariate analysis. By the application of this system to 78 cases, we obtained a good result with an accuracy rate of 85.9%.

**Acknowledgments.** We are grateful to Dr. Yoshiharu Azuma, Radiological Technology, Graduate School of Health Sciences, Okayama University, for help in the data measurement using X-ray images, and Mr. Tastuya Inoue, Central Division of Radiology, Okayama University Hospital, for his useful advice.

## References

- Haga N: Current state and future prospects of treatment for congenital dislocation of the hip: 1) Riemenbügel method. *Seikeigeka (Orthopedic Surgery)* (2005) 56: 603–607 (in Japanese).
- Shimomura T: Current state and future prospects of treatment for congenital dislocation of the hip: 2) Riemenbügel method. *Seikeigeka (Orthopedic Surgery)* (2005) 56: 609–614 (in Japanese).
- Ramsey PL, Lasser S and MacEwen GD: Congenital dislocation of the hip. Use of the Pavlik harness in the child during the first six months of life. *J Bone Joint Surg Am* (1976) 58: 1000–1004.
- Pavlik A: The functional method of treatment using a harness with stirrups as the primary method of conservative therapy for infants with congenital dislocation of the hip. 1957. *Clin Orthop Relat Res* (1992) 281: 4–10.
- Roposch A, Moreau NM, Uleryk E and Doria AS: Developmental dysplasia of the hip: quality of reporting of diagnostic accuracy for US. *Radiology* (2006) 241: 854–860.
- Woolacott NF, Puhan MA, Steurer J and Kleijnen J: Ultrasonography in screening for developmental dysplasia of the hip in newborns: systematic review. *BMJ* (2005) 330: 1413–1415.
- Graf R: The diagnosis of congenital hip-joint dislocation by the ultrasonic Compound treatment. *Arch Orthop Trauma Surg* (1980) 97: 117–133.
- Graf R: Fundamentals of sonographic diagnosis of infant hip dysplasia. *J Pediatr Orthop* (1984) 4: 735–740.
- Akazawa H and Mitani S: Congenital dislocation of the hip. *M B Orthop* (2008) 21: 21–28 (in Japanese).
- Haga N: Developmental dysplasia of the hip. *J Pediatr Prac* (2008) 71: 709–713 (in Japanese).
- Haga N: Early treatment of congenital dislocation of the hip. *Japan Medical Journal* (2002) 4091: 9–13 (in Japanese).
- Yamamuro T and Chene SH: A radiological study on the development of the hip joint in normal infants. *Nippon Seikeigekagakkai zasshi (J Jpn Orthop Assoc)* (1975) 49: 421–439 (in Japanese).
- Boniforti FG, Fujii G, Angliss RD and Benson MK: The reliability of measurements of pelvic radiographs in infants. *J Bone Joint Surg Br* (1997) 79: 570–575.
- Ohmori T, Endo H, Mitani S, Minagawa H, Tetsunaga T and Ozaki T: Radiographic prediction of the results of long-term treatment with the Pavlik harness for developmental dislocation of the hip. *Acta Med Okayama* (2009) 63: 123–128.
- Tanaka Y and Wakimoto K: Methods of multivariate statistical analysis. *Gendai Sugakusha, Kyoto* (1985) pp 101–136 (in Japanese).
- Okuno T, Kume H, Haga T and Yoshizawa T: Method of multivariate analysis. *Nichikagiren, Tokyo* (1981) pp 259–321 (in Japanese).
- Zadeh LA: Fuzzy sets. *Information and Control* (1965) 8: 338–353.
- Zadeh LA: Toward a theory of fuzzy information granulation and its centrality in human reasoning and fuzzy logic. *Fuzzy Sets and Systems* (1997) 90: 111–127.
- Zadeh LA: Toward a perception-based theory of probabilistic reasoning with imprecise probabilities. *J Stat Plan Inference* (2002)

- 105: 233–264.
20. Arita S: Diagnosis for the carcinoma based on ultrasonographs using a fuzzy inference. *Journal of Japan Society for Fuzzy Theory and Systems* (1991) 3: 527–539 (in Japanese).
  21. Arita S, Yoneda M and Hori Y: Supporting system for the diagnosis of diabetes mellitus based on glucose tolerance test responses using a fuzzy inference. *Fuzzy Logic*, Lowen R and Roubens M eds, Kluwer Academic Publishers, Dordrecht (1993) pp 301–310.
  22. Tsutsui T and Arita S: Fuzzy-logic control of blood pressure through enflurane anesthesia. *J Clin Monit* (1994) 10: 110–117.
  23. Hopfield JJ: Neural networks and physical systems with emergent collective computational abilities. *Proc Natl Acad Sci USA* (1982) 79: 2554–2558.
  24. Rosenblatt F: The perceptron: A probabilistic model for information storage and organization in the brain. *Psychol Rev* (1958) 65: 386–408.
  25. Suzuki S, Kasahara Y, Futami T, Ushikubo S and Tsuchiya T: Ultrasonography in congenital dislocation of the hip. Simultaneous imaging of both hips from in front. *J Bone Joint Surg Br* (1991) 73: 879–883.
  26. Suzuki S and Yamamuro T: The mechanical cause of congenital dislocation of the hip joint. Dynamic ultrasound study of 5 cases. *Acta Orthop Scand* (1993) 64: 303–304.
  27. Yanagisako Y: Diagnosis and treatment of congenital dislocation of the hip. *Japan Medical Journal* (2002) 4060: 33–36 (in Japanese).