

Case Report

Intraoral Vertical Ramus Osteotomy Improved the Stomatognathic Function in an Elderly Patient with Mandibular Protrusion: A Case Report

Yoshihito Ishihara^a, Shingo Kuroda^b, Noriaki Kawanabe^a,
Teruko Takano-Yamamoto^c, and Takashi Yamashiro^{a*}

^aDepartment of Orthodontics, Okayama University Graduate School of Medicine, Dentistry and Pharmaceutical Sciences, Okayama 700-8558, Japan, ^bDepartment of Orthodontics and Dentofacial Orthopedics, The University of Tokushima Graduate School of Oral Sciences, Tokushima 770-8504, Japan, and ^cDivision of Orthodontics and Dentofacial Orthopedics, Tohoku University Graduate School of Dentistry, Sendai 980-8575, Japan

This article reports the successful surgical-orthodontic treatment of an elderly patient with dentofacial deformity and signs and symptoms of temporomandibular disorder (TMD). The patient was a 63-year-old woman with a concave profile due to mandibular protrusion. To correct skeletal deformities, the mandible was posteriorly repositioned by employing intraoral vertical ramus osteotomy (IVRO) following presurgical orthodontic treatment. After active treatment for 31 months, the facial profile was significantly improved and satisfactory occlusion was achieved. In addition, TMD symptoms of clicking sounds on the left side and difficulty in mouth opening were resolved. Regarding the findings of magnetic resonance imaging, anterior disc displacement in the opening phase was improved in the temporomandibular joint on the left side. Furthermore, stomatognathic functions were also improved without any aggravation of age-related problems. In conclusion, surgical repositioning of the mandible using IVRO leads to both morphological and functional improvements even in elderly patients.

Key words: elderly patient, orthodontics, temporomandibular disorder, intraoral vertical ramus osteotomy

Orthodontic treatment for older adults has become much more commonplace, and the number of adult patients seeking orthognathic surgeries to improve facial aesthetics and occlusion is also increasing. In this context, it is worth noting that adult patients with dentofacial deformity often show combined gnathological problems, *e.g.*, limitation of mandibular movements or symptoms of temporomandibular disorder (TMD) [1, 2]. Several previous studies

have reported that orthodontic treatment in combination with orthognathic surgery significantly reduced TMD symptoms [3, 4]. However, in elderly patients, it is still unclear whether these functional disorders are improved after orthognathic surgery as there are limited reports [5].

In this report, we present the case of an elderly patient with mandibular protrusion and a history of TMD who showed improvement of the condylar path and articular disc position after intraoral vertical ramus osteotomy (IVRO).

Received April 8, 2010; accepted June 30, 2010.

*Corresponding author. Phone: +81-86-235-6692; Fax: +81-86-235-6694

E-mail: yamataka@md.okayama-u.ac.jp (T. Yamashiro)

Case Report

An elderly woman, aged 63 years and 5 months, was examined in the outpatient clinic of Okayama University Hospital. Her chief complaints were a protrusive chin and anterior crossbite (Fig. 1A and 2A). She had a concave profile due to the protruding chin, and showed circumoral musculature strain on lip closure. She recalled having observed signs and symptoms of TMD over the previous 10 years, and complained of spontaneous pain and clicking sounds in the temporomandibular joint (TMJ) on the left side. She also complained of difficulty in mouth opening. Although spontaneous pain had been absent for 3 years, the clicking sound and difficulty in mouth opening persisted. The incisal path was unstable during the opening-and-closing jaw movement based on analysis with a 6 degrees-of-freedom jaw movement recording system (Fig. 3A) (Gnathohexagraph system Ver. 1.31; Ono Sokki Ltd., Kanagawa, Japan). A limitation of condylar movement on the left side during opening-and-closing or lateral movement was also observed (Fig. 3A). The interincisal distance on maximal opening without pain was 35mm. The TMJ disc position on sagittal sectioning of magnetic resonance images (MRI) showed anterior disc displacement without reduction on the left side (Fig. 4A). When compared with Japanese norms [6], cephalometric analysis showed skeletal mandibular protrusion (Fig. 1A). An anterior crossbite was observed with an overjet of -5.4 mm. The patient was diagnosed with Angle Class III malocclusion, with a skeletal Class III jaw base relationship, and TMD. The treatment objectives were to correct the prognathic facial appearance,

achieve acceptable occlusion, establish an ideal overjet and overbite, and reduce the TMD symptoms.

After 19 months of presurgical orthodontic treatment using multi-bracket appliances, the mandible was set back 6mm at the pogonion with IVRO. Intermaxillary fixation with stainless steel wires was maintained for 10 days, and occlusal rehabilitation was performed for 3 months using intermaxillary elastics and an occlusal splint. The total active treatment period was 31 months. After treatment, the protrusive chin and concave profile were significantly improved, and an Angle Class I molar relationship with normal overjet and overbite was achieved. Posttreatment cephalometric evaluation showed an increase in the ANB angle, and a skeletal Class I jaw relationship was achieved (Fig. 1B and 1C). The mandible was set back 7.0mm at the pogonion, and the mandibular body length was decreased by 6.0mm.

The TMD symptoms, including clicking, joint pain, and difficulty in mouth opening disappeared after surgery. The interincisal distance on maximal opening without pain was increased to 48mm. On evaluation using a 6-degrees-of-freedom jaw movement recording system, it was found that smooth and stable motion was achieved during maximal mouth opening and closing jaw movements (Fig. 3B). Increases in the range of maximum opening and closing jaw movements and lateral excursion were also observed (Fig. 3B). MRI findings after IVRO indicated improvement of the pathological disc position relative to the left condyle (Fig. 4B). Schüller's temporomandibular joint radiography showed no change in condylar position on the left side between pre- and post-surgery (Fig. 4C). After 3 years retention, the patient had not experienced any

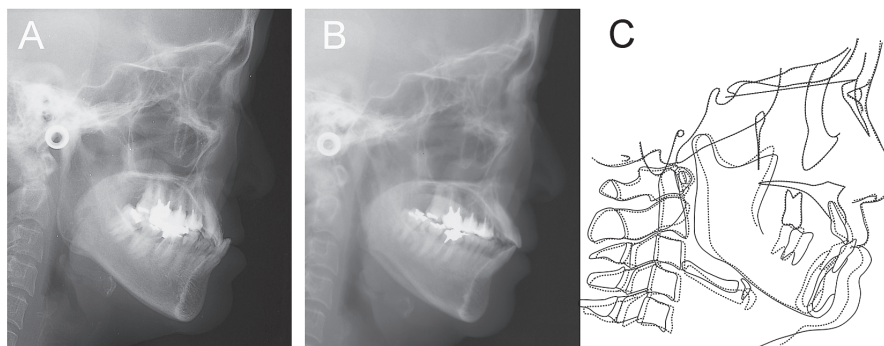


Fig. 1 Cephalometric radiograph. **A**, Pretreatment; **B**, Posttreatment; **C**, Superimposed cephalometric tracings show changes from the pretreatment (solid line) to posttreatment (dotted line) stages.

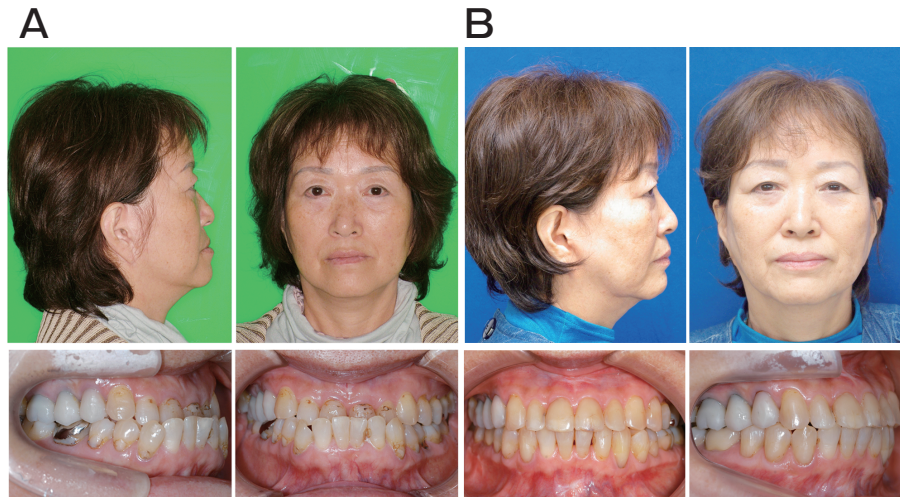

Fig. 2 Facial and intraoral photographs. **A**, Pretreatment; **B**, Postretention. [The patient provided informed consent for the presentation of all photographs.]

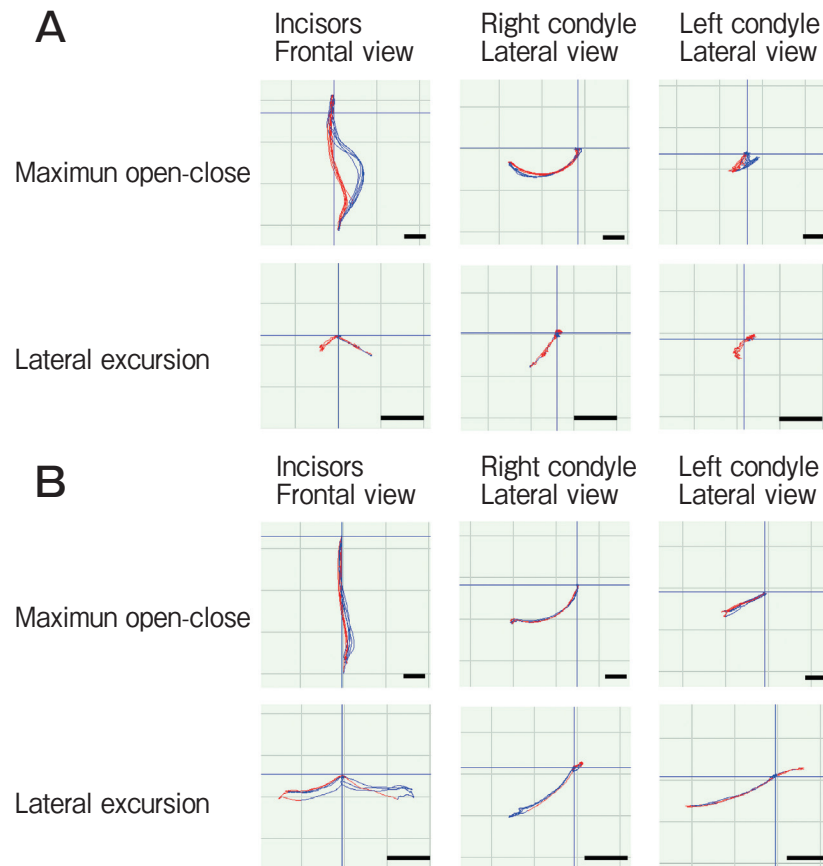


Fig. 3 Condylar movement and incisal paths as detected using a 6-degrees-of-freedom jaw movement recording system. The red line shows the opening phase, and the blue line indicates the closing phase. **A**, Pretreatment; **B**, Posttreatment. Bar: 5mm

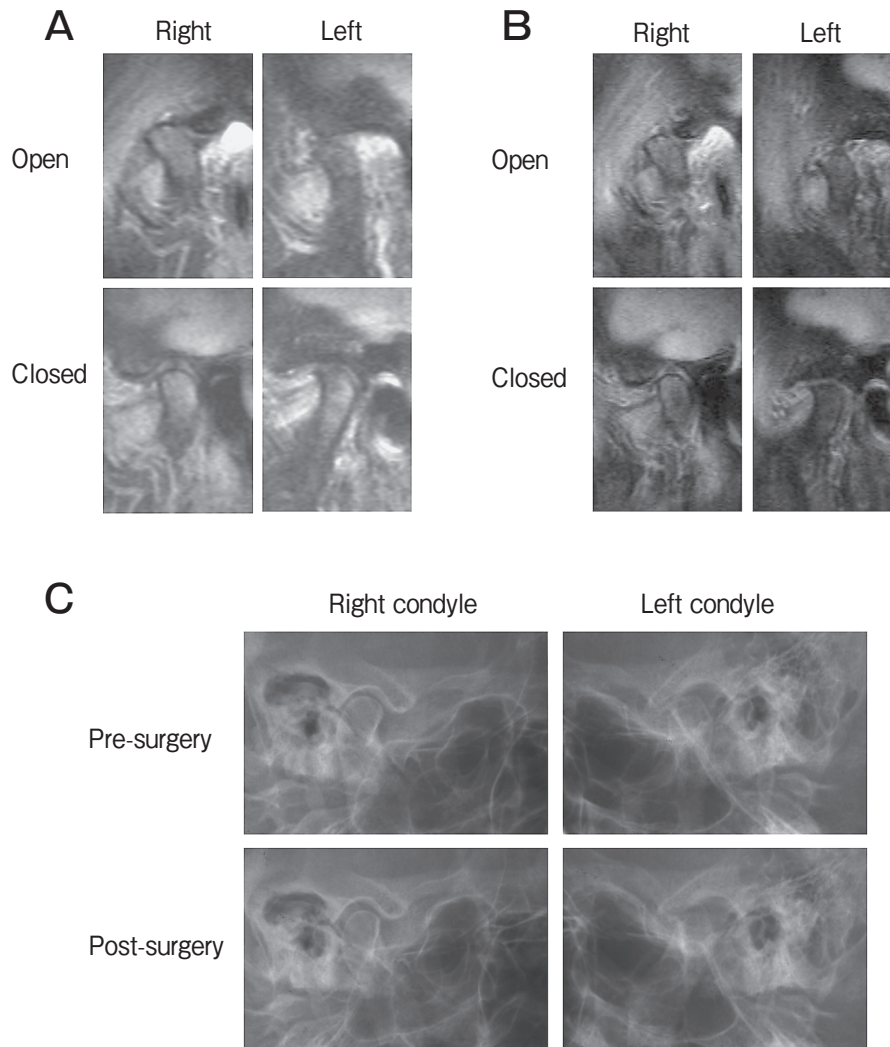


Fig. 4 Sagittal oblique proton-density-weighted magnetic resonance imaging (TR/TEeff, 2000/14). Section thickness: 3mm. **A**, Pretreatment; **B**, Posttreatment; **C**, Schüller's temporomandibular joint radiography of the position of the condyle during centric occlusion.

further TMD symptoms and was satisfied with the results of treatment (Fig. 2B). Her occlusion has become stable, and a favorable facial profile had been maintained.

Discussion

In general, two surgical methods: sagittal split ramus osteotomy (SSRO) and IVRO, are used for backward mandibular movements. In older adult patients, bone segments should be firmly fixed in orthognathic surgery due to physical complications

such as poor bone metabolism [7]. Therefore, SSRO might be recommended in elderly patients. However, the present patient had symptoms of TMD. Several previous reports have suggested that IVRO is more likely to improve TMD symptoms and temporomandibular joint function with internal derangement [3, 4]. In addition, IVRO also has the advantage of causing a lower incidence of inferior alveolar nerve damage and bleeding [3], and requires a shorter operation time [8]. Therefore, we selected IVRO in view of the physical status and TMD symptoms in the present case.

After surgical-orthodontic treatment, the patient's TMJ pain and difficulty in mouth opening disappeared, and her maximum mouth opening and lateral excursion were also increased. The motion of the left condyle was improved, and that observed during maximum mouth opening and closing jaw movements was indicated to be stable by gnathological analysis. MRI findings suggested that the disc-condyle relationship had been favorably modified by posterior repositioning of the articular disc during treatment. These findings indicate that IVRO effectively improved TMD symptoms in this case.

It is widely believed that IVRO improves the pathological position of the articular disc, and the following mechanism has been proposed [9]: 1) the masseter, temporalis, and medial pterygoid muscles are detached; 2) the condyle temporarily moves in the inferior and anterior directions; 3) under the influence of the lateral pterygoid muscle, the anteriorly displaced disc can be retracted and moved to an appropriate position relative to the condyle. Additionally, the condyle tends to move in superior and posterior directions as the healing process progresses after IVRO and the jaw function is restored [8]. As shown by the present case, these successive changes might occur even in senior TMD patients. However, this report is only one case observation. Aging is considered to cause morphologic and functional impairment of stomatognathic functions. For instance, osteoarthrotic degeneration in the TMJ is commonly associated with aging. Several experimental studies have suggested that aging might limit functional adaptation in both the condyle and articular discs [10]. Other epidemiological study has showed that TMJ crepitation or tenderness of the jaw muscles increases with age [11]. Therefore, not all elderly patients with TMD may respond as favorably to IVRO as the present patient. Further research is needed to clarify the effect of IVRO on TMD symptoms, especially in elderly patients.

Conclusion. This article reports the successful surgical-orthodontic treatment of an elderly female

patient with dentofacial deformity and signs and symptoms of TMD. Surgical repositioning of the jaw using IVRO leads to both morphological and functional improvements, even in elderly patients.

Acknowledgments. The authors thank Dr. Akiyoshi Nishiyama and Dr. Akira Sasaki at the Department of Oral and Maxillofacial Surgery and Biopathology at Okayama University Medical and Dental Hospital for performing the orthognathic surgery. The authors also thank Dr. Hirotaka Iwata at the Department of Periodontal Science at Okayama University of Medical and Dental Hospital for performing periodontal maintenance and the treatment of chronic caries.

References

1. Laskin DM: Age: a barrier to oral surgery? *Int Dent J* (1983) 33: 313-318.
2. Natrass C and Sandy JR: Adult orthodontics: a review. *Br J Orthod* (1995) 22: 331-337.
3. Hall HD and McKenna SJ: Further refinement and evaluation of intraoral vertical ramus osteotomy. *J Oral Maxillofac Surg* (1987) 45: 684-688.
4. Ueki K, Marukawa K, Nakagawa K and Yamamoto E: Condylar and temporomandibular joint disc positions after mandibular osteotomy for prognathism. *J Oral Maxillofac Surg* (2002) 60: 1424-1432.
5. Moenning JE, Bussard DA, Lapp TH and Garrison BT: Average blood loss and the risk of requiring perioperative blood transfusion in 506 orthognathic surgical procedures. *J Oral Maxillofac Surg* (1995) 53: 880-883.
6. Wada K, Matsushima K, Shimazaki S, Miwa Y, Hasuike Y and Sunami R: An evaluation of a new case analysis of a lateral cephalometric roentgenogram. *J Kanazawa Med Univ* (1981) 6: 60-70.
7. Berger JL, Pangrazio-Kulbersh V, Bacchus SN and Kaczynski R: Stability of bilateral sagittal split ramus osteotomy: rigid fixation versus transosseous wiring. *Am J Orthod Dentofacial Orthop* (2000) 118: 397-403.
8. Ghali GE and Sikes JW Jr: Intraoral vertical ramus osteotomy as the preferred treatment for mandibular prognathism. *J Oral Maxillofac Surg* (2000) 58: 313-315.
9. Hall HD and McKenna SJ: Further refinement and evaluation of intraoral vertical ramus osteotomy. *J Oral Maxillofac Surg* (1987) 45: 684-688.
10. Bouvier M: Effects of age on the ability of the rat temporomandibular joint to respond to changing functional demands. *J Dent Res* (1988) 67: 1206-1212.
11. Agerberg G and Bergenholz A: Craniomandibular disorders in adult populations of West Bothnia, Sweden. *Acta Odontol Scand* (1989) 47: 129-140.