

Acta Med. Okayama, 2012
Vol. 66, No. 6, pp. 499-502

Copyright©2012 by Okayama University Medical School.

Acta Medica
Okayama

<http://escholarship.lib.okayama-u.ac.jp/amo/>

Case Report

Surgical Treatment for Congenital Kyphosis Correction Using Both Spinal Navigation and a 3-dimensional Model

Yoshihisa Sugimoto*, Masato Tanaka, Ryuichi Nakahara, Haruo Misawa,
Toshiyuki Kunisada, and Toshifumi Ozaki

Department of Orthopaedic Surgery, Okayama University Hospital, Okayama 700-8558, Japan

An 11 year-old girl had 66 degrees of kyphosis in the thoracolumbar junction. For the purpose of planning for kyphosis correction, we created a 3-D, full-scale model of the spine and consulted spinal navigation. Three-dimensional models are generally used as tactile guides to verify the surgical approach and portray the anatomic relations specific to a given patient. We performed posterior fusion from Th10 to L3, and vertebral column resection of Th12 and L1. Screw entry points, directions, lengths and diameters were determined by reference to navigation. Both tools were useful in the bone resection. We could easily detect the posterior element to be resected using the 3D model. During the anterior bony resection, navigation helped us to check the disc level and anterior wall of the vertebrae, which were otherwise difficult to detect due to their depth in the surgical field. Thus, the combination of navigation and 3D models helped us to safely perform surgery for a patient with complex spinal deformity.

Key words: congenital scoliosis, kyphosis, navigation, 3-dimensional models

Surgery for congenital scoliosis with hemivertebra is difficult, because of the asymmetry of the spine and complexity of the spinal deformity. Recently, surgical support tools such as spinal navigation systems and 3-dimensional (3D) models have been developed to help surgeons perform these operations safely [1-4]. Several authors have reported surgical techniques using either navigation or a 3D model [3, 4-8]; however, technical reports using both tools are rare.

In this study, we describe our experience surgically treating a child with congenital spinal deformity due to hemivertebra using both navigation and a 3D

model. The benefits of each are discussed.

Case Report

The patient and her parents were informed that data concerning the case would be submitted for publication, and consented. An 11 year-old girl visited our hospital with congenital spinal deformity. She had 66 degrees of kyphosis in the thoracolumbar junction (Fig. 1). She had no neurological deficits.

For the purpose of planning the kyphosis correction, we created a 3-D, full-scale model of the spine using the rapid prototyping technique (Fig. 2). Rapid prototyping is an advanced manufacturing technology that makes it possible to generate an actual 3D model from virtual 3D renderings [1]. Digital Imaging and Communications in Medicine (DICOM) data was

Received May 16, 2012; accepted August 20, 2012.

*Corresponding author. Phone: +81-86-235-7273; Fax: +81-86-223-9727
E-mail: sugi.ort@gmail.com (Y. Sugimoto)

obtained from CT, with 1-mm slices. The data was used to make the 3D model and create the navigation images on the Stealth Station (Medtronic Surgical Navigation Technologies, Louisville, CO, USA). 3D models are used as tactile guides to verify the surgical approach and anatomic relations; using them, surgeons can understand a patient's anatomy directly without having to mentally reconstruct multiple 2D images [9]. In our case, the model was useful for both preoperative planning and as an intraoperative guide.

We performed the operation using a posterior

approach. After spinal posterior element exposure, the 3D model helped us to roughly determine the proper pedicle screw entry point (Fig. 2). A dynamic reference arc was attached to the spinous process at the insertion. Optimal screw entry points, directions, lengths and diameters were determined with reference to the navigation (Fig. 3A). The reference arc was not detached after screw insertion, because navigation was also used for bone resection.

In the bone resection, both tools were useful. We could easily detect the necessary posterior-element

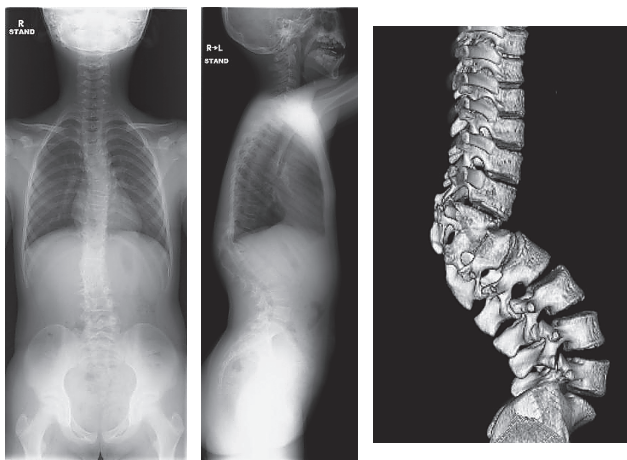


Fig. 1 Preoperative radiographs and 3-D CT.

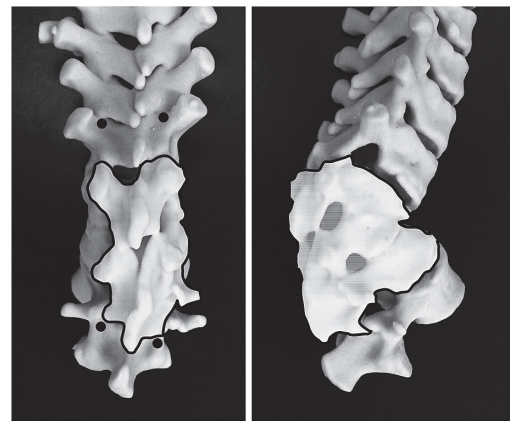


Fig. 2 The 3D full-scale model of the spine allowed us to plan pedicle screw insertion and bony resection. Black dots, pedicle screw insertion point; white area, bony resection planning.

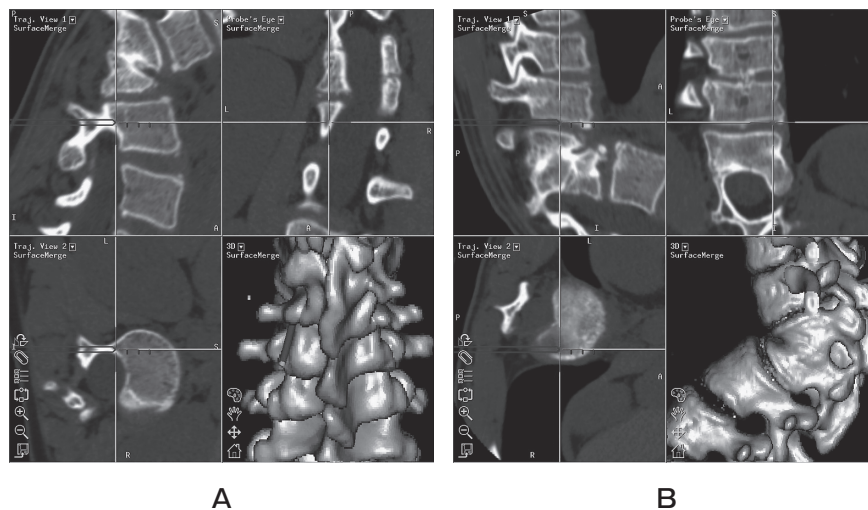


Fig. 3 Spinal navigation. **A**, Screws entry points, directions, lengths and diameters were determined by reference to the navigation; **B**, During anterior bony resection, navigation helped us to check the disc level and anterior wall of the vertebra.

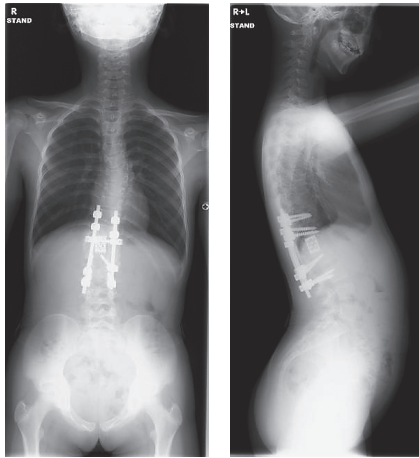


Fig. 4 Postoperative radiographs.

bone to be resected using the 3D model. During the anterior bony resection, navigation helped us to check the disc level and anterior wall of the vertebra, which would have otherwise been difficult to detect due to their depth in the surgical field (Fig. 3B).

We performed posterior fusion from Th10 to L3, and vertebral column resection of Th12 and L1. A titanium cage was inserted from the posterior for the purpose of anterior support. Motor-evoked potential monitoring was done for neural monitoring. Postoperative CT showed no screw misplacement. Six days after operation, the patient could walk without any support. She wore a fitted hard corset for 3 months. At final follow up, she had no neurological deficit, and bony union had been achieved. Local kyphosis at the thoracolumbar junction was improved from 66 degrees to 31 degrees (Fig. 4).

Discussion

Surgery for congenital scoliosis is difficult, because of the abnormal anatomies of such parts as the laminae and pedicles. Recently surgical support tools such as spinal navigation systems and 3D models have been developed to help surgeons perform these operations safely [1-4]. Several authors have reported their experience using either navigation or a 3D model [3, 4-8]; however, technical reports using both tools are rare. The purpose of this study was to describe our experience using both tools in the surgical treatment of a child with congenital spinal deformity and to dis-

cuss their usefulness.

There are several reasons why surgery on patients with congenital scoliosis is difficult. The first problem is the invisibility factor. During pedicle screw insertion we cannot look inside the bone. This is compounded by the patient's abnormal anatomy. Since we cannot look inside the vertebra, we must insert a screw into the spine based on anatomical images. However, mental reconstruction of multiple images is particularly difficult in congenital complex spinal deformity. For these reasons, navigation and 3D models are important support tools for congenital scoliosis surgery.

The development of reconstruction CT and 3D-CT greatly advanced the assessment and surgical treatment of congenital scoliosis [9]. These modalities help surgeons to recognize complex spinal deformities [9]. However so-called "3D-CT" provides only 2D images, because 2D monitors are used to display DICOM's 3D data. Shadows are expressive of concavity and convexity. By contrast, a 3D model is an actual, tactile 3D display.

The first benefit of using a 3D model as a tactile 3D display is that the operator can rotate it with his hands and directly visualize the anatomical relations between anterior and posterior elements. By contrast, if an assistant rotates 3D-CT images on a computer monitor, mental reconstruction of these images during the operation can be very difficult. The second benefit is its use in surgical planning for screw insertion and corpectomy [1, 3, 4, 10]. The 3D model was especially useful for deciding the amount of corpectomy at preoperative planning. After exposure of the spinal posterior element, the 3D model helped us to roughly determine the pedicle screw entry point intraoperatively. Several authors also have reported that the operator was able to assess the rod contour with 3D model planning [4, 10]. The third benefit is that the 3D model provides patients with a facsimile of their disorders and enhances patient education [2].

Recently, many authors have reported on the usefulness of a spinal navigation system for spinal disorders [5-8]. In the present case, the most useful aspect of the navigation system was its help with pedicle screw placement. The navigation system helped us to recognize the pedicle screw insertion point, and the appropriate length and diameter of each screw. We could also visualize the orientation of the

anterior vertebral wall and disc, which were located deep within the operative field and were difficult to see. Another benefit is reducing radiation exposure. If we had not used navigation, we would have had to check radiographs or make frequent use of an image intensifier to determine the screw direction or range of vertebral bone resection.

Some disadvantages of this technique include the high cost of navigation and the longer time required for navigation-based surgery [7]. Also, if there is intervertebral instability, we must register each vertebra separately across the unstable disc [7]. A prospective controlled study with larger samples is required to verify the usefulness of the combination of spinal navigation and a 3D model in reconstruction surgery for congenital spinal deformity.

References

1. Brown GA, Firoozbakhsh K, DeCoster TA, Reyna JR Jr and Moneim M: Rapid prototyping: the future of trauma surgery? *J Bone Joint Surg Am* (2003) 85-A Suppl 4: 49–55.
2. D'Urso PS, Askin G, Earwaker JS, Merry GS, Thompson RG, Barker TM and Effeney DJ: Spinal biomodeling. *Spine* (1999) 24: 1247–1251.
3. Yamazaki M, Okawa A, Kadota R, Mannoji C, Miyashita T and Koda M: Surgical simulation of circumferential osteotomy and correction of cervico-thoracic kyphoscoliosis for an irreducible old C6–C7 fracture dislocation. *Acta Neurochir (Wein)* (2009) 151: 867–872.
4. Mizutani J, Matsubara T, Fukuoka M, Tanaka N, Iguchi H, Furuya A, Okamoto H, Wada I and Otsuka T: Application of full-scale three-dimensional models in patients with rheumatoid cervical spine. *Eur Spine J* (2008) 17: 644–649.
5. Kotani Y, Abumi K, Ito M and Minami A: Improved accuracy of computer-assisted cervical pedicle screw insertion. *J Neurosurg* (2003) 99: 257–263.
6. Sugimoto Y, Ito Y, Tanaka M, Tomioka M, Hasegawa Y, Nakago K, Yagata Y and Ozaki T: Cervical cord injury in patients with ankylosed spines: progressive paraplegia in two patients after posterior fusion without decompression. *Spine (Phila Pa 1976)* (2009) 34: E 861–863.
7. Ito Y, Sugimoto Y, Tomioka M, Hasegawa Y, Nakago K and Yagata Y: Clinical accuracy of 3D fluoroscopy-assisted cervical pedicle screw insertion. *J Neurosurg Spine* (2008) 9: 450–453.
8. Tanaka M, Nakanishi K, Sugimoto Y, Misawa H, Takigawa T, Nishida K and Ozaki T: Computer navigation-assisted spinal fusion with segmental pedicle screw instrumentation for scoliosis with Rett syndrome: a case report. *Acta Med Okayama* (2009) 63: 373–377.
9. Kawakami N, Tsuji T, Imagama S, Lenke LG, Puno RM and Kuklo TR: Classification of congenital scoliosis and kyphosis: a new approach to the three-dimensional classification for progressive vertebral anomalies requiring operative treatment. *Spine (Phila Pa 1976)* (2009) 34: 1756–1765.
10. Yamazaki M, Akazawa T, Koda M and Okawa A: Surgical simulation of instrumented posterior occipitocervical fusion in a child with congenital skeletal anomaly: case report. *Spine (Phila Pa 1976)* (2006) 31: E 590–594.